

UNIVERSITY OF TORONTO





3 1761 01412369 9

Chun Carbon

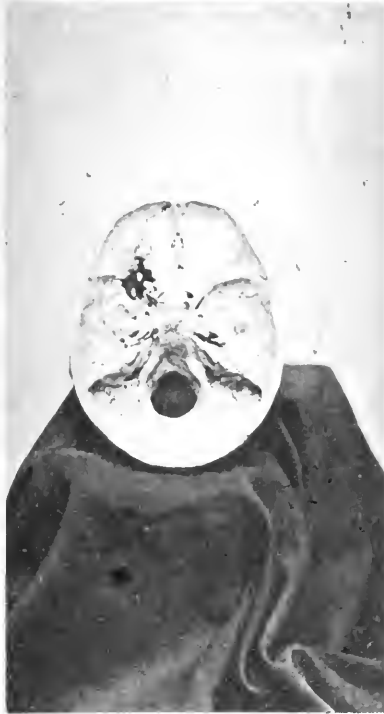
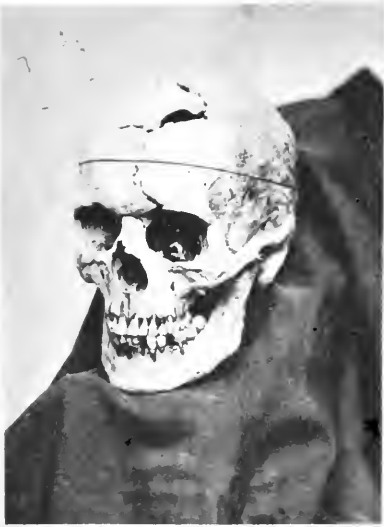From Dr. Hunter. 623.80

Duplicate





Digitized by the Internet Archive
in 2007 with funding from
Microsoft Corporation

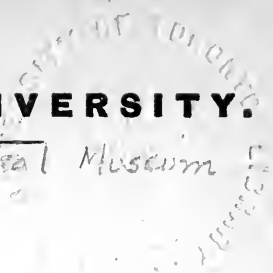

SEE NOS. 949, 3106.

MA
H

HARVARD UNIVERSITY.

Warren Anatomical Museum



DESCRIPTIVE CATALOGUE

OF THE

WARREN ANATOMICAL MUSEUM.

BY

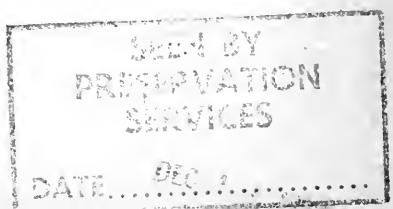J. B. S. JACKSON, M.D.,

**CURATOR OF THE MUSEUM; AND SHATTUCK PROFESSOR
OF MORBID ANATOMY.**

BOSTON:

A. WILLIAMS AND COMPANY.


1870.





Handwritten signature or initials, possibly reading "H. M. S." or similar, written in dark ink.

Psychological



INTRODUCTION.

THE Medical Department of Harvard University was established in the year 1782. In 1808 Dr. John C. Warren was appointed Adjunct Professor of Anatomy and Surgery; and, when that chair was vacated, in the year 1815, by the death of his father, Dr. W. was appointed to fill his place. How faithfully and honorably to himself, and to the College, he performed the duties of his office, and during a long period of years, is well known to the profession. The zeal with which he pursued his favorite studies, and with which he improved the opportunities that a very extensive professional practice afforded him, led to the collection of a great number of pathological and other specimens; and, on resigning his professorship, in 1847, the greater part of this collection was presented to the College, and with it the sum of \$6,000, for its preservation and increase. In acknowledgment of so valuable a donation, the Corporation of the University voted that the Museum should be called by the name of its founder. Unfortunately, Dr. W.'s time was so fully occupied by his professional practice, that but little was left to him for those records, or even references, upon which the value of the pathological portion of a museum so much depends. Before the transfer, however, was made to the College, Dr. W. had a record made of the specimens, from his dictation; but it was, for the most part, and excepting a few references, a mere enumeration. The tendency to preserve interesting specimens is very strong in so devoted an anatomist and surgeon as Dr. W. always had been; and the consequence was, that he collected a large number of what might essentially be called duplicates. Pathological specimens that resemble each other very closely are often preserved in reference to their clinical history; and the diver-

sity in regard to the symptoms, and the progress of two cases, when the anatomical appearances are nearly similar, is often a very interesting pathological fact. If, however, the history is wanting, and the duplicate must be preserved in spirit, it is an undesirable one; and accordingly many such were removed, after the collection came into the possession of the College.

Since Dr. Warren made his donation, the collection has steadily increased from year to year; and it still continues to, as shown in part by the number of specimens that has been added since the printing of the catalogue was commenced last August, and that could not be introduced in their proper place; many others having been added, and that were so introduced. It would be impossible to enumerate the many individuals who have shown an active interest in the Museum, and to whom the College is greatly indebted; specimens having often been sent in from the country, and even from distant parts of the country, as well as from our immediate neighborhood. Some of our contributors, however, deserve especial notice. The late Dr. George Hayward, who occupied the chair of Surgery and Clinical Surgery, for a period of ten years (1840-50), made a collection of Thibert's models when he was in Europe, and for the illustration of his lectures. They amounted altogether to one hundred and sixty specimens, and in 1847 he presented them to the College. The late Dr. John Ware, also, Professor of the Theory and Practice of Medicine, collected ninety-one models by the same artist, and for the same purpose; and these he presented to the College in 1849. Prof. O. W. Holmes has made a great many valuable preparations, to illustrate his department of healthy anatomy; and he has also, independently of the Museum, a large number of microscopical preparations, either made by himself, or obtained by correspondence, and that he uses annually in a special course to the medical class. Prof. H. J. Bigelow has collected a large number of specimens in the course of his surgical practice, and many of them are of very great practical and scientific value. A series of colored lithographs, illustrative of diseased structures, is very fine, and ought especially to be mentioned. They form a small portion of a large number of lithographs, that Prof. B. had taken many years ago, in connection with a proposed work on tumors, but which unfortunately was never

completed. Very exquisite drawings were made in water colors by a foreign artist, and from typical and recent specimens; these were then lithographed, and the copies that are shown in the Museum were colored by the same artist, after the originals. A collection of enlarged drawings in water colors, by the same artist, suitable for the lecture-room, and illustrative of surgical anatomy and pathology, may also be alluded to, though independent of the Museum. In this collection there are four hundred and twenty-six plates, and altogether nine hundred and sixty-seven figures; many of the drawings being from recent specimens, and showing the microscopic as well as the gross appearances. Some of the other departments are, also, illustrated more or less fully. Prof. R. M. Hodges has always shown a most active interest in the Museum since he was connected with the College as a student, and the large practice in which he has been engaged of late years has enabled him to secure for it very many specimens, and some of them of the greatest interest. His anatomical preparations, also, are very fine, and could hardly be surpassed for the freedom and beauty of the dissections. The most valuable specimen that has ever been added to the Museum, and probably ever will be, was given two years ago by Dr. John M. Harlow, of Woburn. It was the skull of the man through whose head a large iron bar passed, and who essentially recovered from the accident. For the professional zeal and the energy that Dr. H. showed, in getting possession of this remarkable specimen, he deserves the warmest thanks of the profession, and still more, from the College, for his donation. Unfortunately, and notwithstanding the evidence that Dr. H. has furnished, the case seems, generally, to those who have not seen the skull, too much for human belief.

The whole number of specimens now in the Museum amounts to three thousand six hundred and eighty-nine. The last specimen is numbered 3681; but thirteen were accidentally omitted, and afterwards added as the volume was being printed; and five were repeated. Of these, one thousand one hundred and sixteen specimens were given by Dr. Warren, including three hundred and thirteen phrenological casts; and one hundred and twenty-three specimens were paid for from the Museum Fund. The number of specimens preserved in spirit is nine

hundred and four; and of these, seven hundred and seven, with one or two exceptions, are separately displayed in glass jars. The rest, after being numbered and classified, are preserved together in large glass jars, from which they can be removed for study or demonstration.* Some of the dry preparations are also individually preserved under glass or in jars, for security when they are handled, and to make them more secure, also, than they can be when in the glazed cases alone; and, for the same reason, many, if not most, of the arterial preparations are mounted. Of the artistic specimens, there are two hundred and sixty-eight models by Thibert, and sixty-seven by Auzoux, of Paris. The casts in plaster amount to five hundred and seventy; but these include the phrenological collection, of which the number has been given above; twenty-one of the casts that were taken from recent specimens being colored somewhat after nature. There are also sixty photographs, and one hundred and three other specimens, including drawings, daguerreotypes, wax models, etc. As there are many dried specimens that are preserved, though essentially similar, so there are many others of great interest and of common occurrence, that are not generally preserved, except in regard to their external form, to the locality in which they are found, or their clinical history, — inasmuch as their appearances are entirely changed by any mode of preservation that is known.

A descriptive catalogue is essential in an anatomical museum; and one has been kept, in which the specimens that were given by Dr. Warren, and all that have since been added, have been entered as they were received. Many of them are simply enumerated; but the descriptions are often much detailed, though references are made, by volume and page, to the hospital records, and to the Medical Journal; it being understood that the Massachusetts General Hospital, and the Boston Medical and Surgical Journal are referred to, unless otherwise expressed. Lengthy as the descriptions sometimes are, however, they are almost always condensed from the original reports; and the liberty has always been taken of correcting errors, whenever such were known to exist. In the printed catalogue of Thibert's models many appearances are recorded that are not shown, and they are consequently not referred to. The donor's name, as a rule, is always given, whatever may be

* Designated by a mark (.) under the number.

his position, and if it is known, which is not always the case, though sometimes it is purposely withheld, and for various reasons; the donor being often the one who made the post-mortem examination, and not the one in whose practice the case occurred, and whose interest in it has not always disposed him to take any trouble in regard to the specimen. When the donor prepared the specimen, the fact has been or should be recorded. Many of the donors, and some of the best friends of the Museum, are now not living; but with a few exceptions, this does not appear. The specimens that are displayed in the cases are, of course, numbered to correspond with the descriptive catalogue; and a memorandum is kept of those that are preserved together, in spirit, and in the numbered jars. The specimens, also, as they have been entered in the catalogue, have been arranged according to a certain system, and briefly enumerated, with a repetition of the numbers and of the names of the donors.

The present volume has reached a most unexpected size, and would have been still larger if it had been as openly spaced throughout as it was at first. Figures, however, and other inelegant abbreviations are often used, for the sake of brevity; and much is generally left to be inferred in regard to the specimens,—as the mode of preparation, the exhibition of certain parts, the fact that the history of a case was wholly or partially unknown, and generally the fact that a specimen was from the dissecting room. The date of the donation being given at the end of each case, the year is sometimes not referred to in the record, when the case was of short duration; and, if very short, the days of the week only are sometimes mentioned. In printed catalogues, generally, the different series or divisions are designated by letters, and separately numbered; but it seems to be more convenient for reference, to number the specimens regularly onward, and from first to last.

Besides the formal collection, there is another that consists mostly of indifferent specimens, and of what may be called duplicates; and they are very generally preserved in spirit. These amount altogether to two hundred and seventy-two; and fifty-eight of them belonged to Dr. Warren's original collection. They are all entered in a second and separate catalogue,

though very much less fully than in the other, but with references and a systematic index.

The Museum contains, for its size, many specimens of interest, and some that can hardly be surpassed. But there are a great many deficiencies; and it is to be hoped that many of them will be supplied by the zeal of the young men who are coming forward, and that the profession generally will continue to contribute, as they have heretofore, until there is no common form of injury or disease that will not be represented in the collection.

Since the above was in type, a manuscript "Catalogue of Preparations, belonging to the Anatomical Cabinet of the Massachusetts Medical College," has been received from Dr. J. Collins Warren, the son of Dr. J. Mason Warren, and grandson of the founder of the Museum. The date of this catalogue, of which I had never before heard, is not given; but it bears the marks of age, and, if it could have been consulted whilst the present volume was being prepared, it would have been of little use, as very few of the specimens can be identified; many are certainly not now in the collection, and it gives very generally little more than a mere enumeration of the specimens.

APRIL 29, 1870.

TABLE OF CONTENTS.



FIRST DIVISION.—HEALTHY ANATOMY.

	Page
SERIES I. BONES,	1
I. Structure,	1
II. Development,	2
III. Adult,	6
IV. Comparative Anatomy,	6
V. Anatomical Varieties,	17
 SERIES II. SOFT PARTS ABOUT THE BONES,	 24
“ III. ORGANS OF CIRCULATION,	26
I. Heart,	26
II. Blood-vessels,	29
III. Malformations,	36
 SERIES IV. LACTEALS AND LYMPHATICS,	 43
I. Lacteals,	43
II. Lymphatics,	43
 SERIES V. CEREBRO-SPINAL SYSTEM,	 44
I. Membranes,	44
II. Brain,	45
III. Malformation of Brain,	45
IV. Spinal Marrow,	47
V. Nerves,	47
 SERIES VI. SKIN AND APPENDAGES,	 49
“ VII. EYE,	51
“ VIII. EAR,	53
“ IX. ELECTRICAL ORGANS,	54

	Page
SERIES X. MOUTH, NOSTRILS, ETC.,	55
I. Teeth,	55
II. Glands,	57
III. Tongue,	58
IV. Mouth,	58
V. Nostrils,	58
 SERIES XI. VOCAL AND RESPIRATORY ORGANS,	 59
I. Larynx,	59
II. Lungs, etc.,	60
 SERIES XII. ALIMENTARY CANAL,	 61
I. Œsophagus,	61
II. Stomach,	61
III. Intestine,	62
IV. Malformations,	64
 SERIES XIII. LIVER AND DUCTS,	 70
" XIV. URINARY ORGANS,	71
I. Kidneys,	71
II. Bladder,	71
III. Malformations,	72
IV. Product of Secretion,	73
 SERIES XV. MALE GENITAL ORGANS,	 73
" XVI. FEMALE "	77
" XVII. UTERO-GESTATION,	79
I. Parts Concerning the Mother,	79
II. Product of Conception,	81
 SERIES XVIII. MONSTROSITIES, WITH MALFORMA- TIONS NOT ELSEWHERE INCLUDED,	 86
I. By Deficiency,	86
II. By Excess,	114
 SERIES XIX. MISCELLANEOUS SPECIMENS,	 139

SECOND DIVISION.—MORBID ANATOMY.

	Page
SERIES XX. BONES,	141
I. Fractures,	141
II. Dislocations,	206
III. Diseases,	214
SERIES XXI. SOFT PARTS ABOUT THE BONES,	318
“ XXII. ORGANS OF CIRCULATION,	335
I. Pericardium,	335
II. Heart,	336
III. Arteries,	347
IV. Veins,	372
V. Lymphatics and Lacteals,	375
SERIES XXIII. NERVOUS SYSTEM,	381
I. Brain,	381
II. Membranes of Brain,	383
III. Spinal Cord and Membranes,	388
IV. Nerves,	389
SERIES XXIV. SKIN AND INTEGUMENTS,	390
“ XXV. EYE,	409
“ XXVI. EAR,	413
“ XXVII. NOSTRILS,	413
“ XXVIII. PARTS ABOUT THE MOUTH,	417
“ XXIX. VOCAL AND RESPIRATORY OR- GANS,	424
I. Air-passages,	432
II. Lungs,	432
SERIES XXX. ALIMENTARY CANAL,	439
I. Œsophagus,	439
II. Stomach,	443
III. Intestine,	466
IV. Foreign Bodies from the Alimentary Canal,	487
SERIES XXXI. PERITONEUM, AND THE SUBJACENT TISSUE,	491
“ XXXII. HERNIA,	495

	Page
SERIES XXXIII. LIVER AND DUCTS,	498
I. Liver,	498
II. Gall-bladder and Ducts,	504
III. Biliary Calculi,	507
 SERIES XXXIV. URINARY ORGANS,	 516
I. Kidneys,	516
II. Bladder,	524
III. Foreign Bodies from the Bladder,	531
IV. Calculi,	533
 SERIES XXXV. GENITAL ORGANS OF THE FEMALE,	 572
I. Ovaries,	572
II. Fallopian Tubes,	579
III. Uterus,	581
IV. External Organs,	600
V. Breast,	604
 SERIES XXXVI. GENITAL ORGANS OF THE MALE,	 609
I. Scrotum,	609
II. Testicle,	610
III. Prostate Gland,	612
IV. Penis,	617
V. Breast,	621
 SERIES XXXVII. UTERO-GESTATION,	 622
I. Parts Concerning the Mother,	622
II. Product of Conception,	626
 SERIES XXXVIII. TUMORS,	 632
" XXXIX. PARASITES,	671
" XL. MISCELLANEOUS SPECIMENS,	679
 THIRD DIVISION.— MISCELLANY.	
SERIES XLI. NATIONAL SKULLS,	699
" XLII. ZOOLOGY,	708
" XLIII. MEMENTOS,	707
" XLIV. PHRENOLOGICAL COLLECTION,	710
 APPENDIX,	 729

CATALOGUE OF THE MUSEUM.

E R R A T A .

- REPETITIONS. — Nos. 308, 1561, 1593, 2482, and 2555.
Nos. 770, 796, and 2729, should be marked by a period, to show that the specimens are in jars with others, and not separately mounted.
No. 187 — for *basse*, read *bass*. 427 — *carp*, for *calf*. 1365 — *osseuses*, for *ossenes*. 2074 — for *hip* (the last word), read *lip*.
Nos. 102, 158, 318, and 489-92, were given by Dr. R. M. Hodges.
Nos. 677, 2926, and 3068, read Dr. Waldo I. Burnett. 484 — Dr. Silas Durkee. 1308 — Dr. Henry I. Bowditch. 2354 — Dr. Elliott Coues. 2776 — Dr. F. F. Forsaith. 3078 — Dr. G. H. Dadd. 1788 — Crnveilhier and Rokitansky.
No. 2482 — for 3116, read 2790.
No. 322 — read *cœliac*.
Nos. 655-6 — read *cæcal*.
No. 909 — for 1855, read 1865.
No. 304 — omit “ and internal maxillary.”
Nos. 3248-9 — add S. and H.; and No. 3289 — add P. C.
Table of Contents, p. xii — refer Mementos to p. 708.
No. 3237 — the skeleton is in the Museum of the Boston Society of Natural History.
The photographs opposite the title-page are not referred to in the text, as they were added after the work was printed.

6. Bone very dense, from the jaw of a sperm whale; one of the surfaces being highly polished.

Dr. J. Wyman states that when he was in Labrador, some years ago, he saw upon the beaches numbers of jaws that had been cut up by the Esquimaux Indians, for sled-runners. 1861.

7. Portion of a long bone to show the laminated structure.
1866.

Dr. J. B. S. Jackson.

	Page
SERIES XXXIII. LIVER AND DUCTS,	498
I. Liver,	498
II. Gall-bladder and Ducts,	504
III. Biliary Calculi,	507
 SERIES XXXIV. URINARY ORGANS,	 516
.....	516

“

ALL MISCELLANEOUS SPECIMENS.

THIRD DIVISION. — MISCELLANY.

SERIES XLI. NATIONAL SKULLS,	699
“ XLII. ZOOLOGY,	708
“ XLIII. MEMENTOS,	707
“ XLIV. PHRENOLOGICAL COLLECTION,	710
 APPENDIX,	 729

CATALOGUE OF THE MUSEUM.

FIRST DIVISION.—HEALTHY ANATOMY.

SERIES I.—BONES.

I. STRUCTURE.

1. Scapula of an adult, from which the earthy matter has been removed by an acid; in spirit. 1849.
Dr. Jeffries Wyman.
2. Two fibulæ, similarly treated; tied in a knot, and dried. 1862.
Dr. David W. Cheever.
3. Burnt bone; animal matter removed. 1847.
Dr. John C. Warren.
4. Bones of a young pig colored by madder; in spirit. 1852.
Dr. J. Wyman.
5. Portions of dense and spongy bone, contrasted. 1862.
Dr. Oliver W. Holmes.
6. Bone very dense, from the jaw of a sperm whale; one of the surfaces being highly polished.
Dr. J. Wyman states that when he was in Labrador, some years ago, he saw upon the beaches numbers of jaws that had been cut up by the Esquimaux Indians, for sled-runners. 1861.
7. Portion of a long bone to show the laminated structure. 1866.
Dr. J. B. S. Jackson.

8. Portion of a femur, softened by an acid, and then stripped down to show the same. 1860.

Dr. J. B. S. Jackson.

9. Fœtal bone, minutely injected; in spirit. 1847.

Dr. J. C. Warren.

II. DEVELOPMENT.

10. Section of fœtal cartilage, injected; showing the vascularity when ossification is going on. 1847.

Dr. J. C. Warren.

- 11-17. Fœtal skeletons; about 3-9 months. 1847-1851.

Dr. J. C. Warren.

18. Fœtal bones, prepared to show the degree of ossification of each at the full term. From Paris, 1851.

Museum Fund.

19. Fœtal skull. The mother thought herself four and a half months pregnant. Weight of fœtus, $1\frac{1}{4}$ lbs.; length, $11\frac{1}{2}$ in., and spine, $5\frac{1}{4}$ in. 1861.

20. Ditto. Five months and twenty days since last menstruation; weight of fœtus, 1 lb. 9 oz.; length, $12\frac{7}{8}$ in., and spine, $5\frac{3}{8}$ in. 1861.

- 21-2. Ditto. About nine months. 1847.

Dr. J. C. Warren.

23. Ditto. About nine months. From Paris, 1858.

Museum Fund.

24. Ditto. Upper part cut away to show the interior; $4\frac{1}{2}$ months. Prepared by Dr. H. 1857.

Dr. Richard M. Hodges.

25. Ditto. The mother thought herself six months pregnant; weight of fœtus, $4\frac{1}{2}$ lbs.

The posterior fontanelle is entirely wanting; and this I believe, as the result of a careful examination of many specimens, is the normal condition of the cranium, and not merely at birth, but during the latter months of pregnancy, though exceptions to the rule are to be met with (see last specimen). The existence of this fontanelle is inferred, when the foetal head is examined, from the yielding of the parietal bones, and the firmness of the occipital; and one is often made when the skull is prepared, if it is not carefully stuffed. See *Medical Journal*, Vol. LXVI. p. 457.

1862.

Dr. J. B. S. Jackson.

26. Skeleton of a child, from a year to eighteen months old. A ligamentary preparation. 1847. *Dr. J. C. Warren.*
27. A second preparation, by Dr. Winslow Lewis. The subject was about seven years old. The three lower bones of the sternum are divided upon the median line, whilst those of the last, a younger subject, are not so. 1847.
Dr. J. C. Warren.
28. Imperfect skeleton of a child about fourteen years old; bones separated by maceration. 1853.
Dr. W. N. Lane, of Charlestown.
29. The same, of a child, about four years old. 1853.
Dr. Lane, of C.
- 30-1. Upper and lower extremities of a child, from five to ten years of age; ligamentary. 1847. *Dr. J. C. Warren.*
32. Cranium of a child, from a year to eighteen months old. 1847.
Dr. J. C. Warren.
33. A second, of about the same age. 1861.
Dr. R. M. Hodges.
34. A third, about three or four years old. 1847.
Dr. J. C. Warren.

35. A fourth, about six years old. 1853.
Dr. W. N. Lane, of Charlestown.
36. A fifth; age about seven or eight years. 1861.
Dr. R. M. Hodges.
37. Portion of the skull of an idiot, fourteen years of age. The frontal and sphenoidal sinuses, and the antrum are largely developed.
In connection with this case, Dr. H. referred to the remarks of Mr. Hilton (Guy's Hosp. Repts. Vol. viii. Part II. p. 362), that "the frontal sinuses do not make their appearance until fourteen or fifteen years of age, or even in many instances at a still later period." "The antrum and the sphenoidal cells, like the frontal sinuses, remain undeveloped during early life." 1856.
Dr. R. M. Hodges.
- 38-41. Four fœtal temporal bones, of different ages, and four sphenoid bones from the same subjects, to show the development. 1861.
Dr. J. B. S. Jackson.
- 42-5. Lower maxillary bones, from subjects of different ages. 1847.
Dr. J. C. Warren.
46. Second vertebra, from a fœtus at the term, to show the body and odontoid process. 1861.
Dr. J. B. S. Jackson.
47. First, second, and seventh cervical vertebræ, from the same subject as No. 33. In the first there is no appearance of ossification of the body, and in the seventh there was none in the costal portion of the transverse process. 1861.
48. The two first vertebræ of a calf, five or six weeks old, and showing that the first has a body, and the second an odontoid process; this last being fully formed, though yet separate. The odontoid is regarded by some anatomists as the body of the first vertebra. 1866.
Dr. J. B. S. Jackson.

49. Atlas from the same subject as No. 35. The body is in two lateral pieces, and all of the parts are as yet ununited by bone. 1861. *Dr. Lane, of C.*
50. Axis from the same; body and odontoid process ununited; body and laminæ beginning to unite, and the last firmly united posteriorly. 1861. *Dr. Lane, of C.*
51. Seventh cervical vertebra. The costal portion of the transverse processes is united upon each side to the laminæ, but not to the body of the bone. 1861. *Dr. Lane, of C.*
52. Two first cervical vertebræ, from a young adult; co-ossification of their parts incomplete. 1859. *Dr. R. M. Hodges.*
53. Sternum of a child, with the cartilages; five bones. 1847. *Dr. J. C. Warren.*
- The same. Each of the two lower pieces consists of two separate, lateral portions. See No. 27.
54. Sternum from a Flat-head Indian, aged twenty-two years. In four broad pieces, fully ossified, but entirely disconnected. 1860. *Museum Fund.*
55. Sacrum in separate pieces; age, five to ten years. 1847. *Dr. J. C. Warren.*
56. Spine and pelvis; probably from a foetus at the term; in spirit. 1847. *Dr. J. C. Warren.*
57. Portion of the spine of a child a few months old. 1847. *Dr. J. C. Warren.*
58. Most of the spine, with the pelvis and femora, from a child one or two years old. 1847. *Dr. J. C. Warren.*
59. Os innominatum from a child, about five to ten years

- of age, and showing the three bones of which it is composed. 1847. *Dr. J. C. Warren.*
60. A second specimen, from a child, and showing the bone that has been regarded as analogous to the marsupial; it is upon the inner surface of the acetabulum, and at the junction of the ilium and pubes. 1857. *Dr. R. M. Hodges.*
61. Femur of a fœtus at the term; in spirit, to show the cartilaginous head and condyles. 1847. *Dr. J. C. Warren.*
- 62-6. A collection of long bones, to show the relative development, and co-ossification of the epiphyses, with the shaft. 1847. *Dr. J. C. Warren.*
67. Sections of the long bones of a fœtus; long. and transverse. 1859. *Dr. J. B. S. Jackson.*

III, ADULT BONES.

68. Articulated skeleton, from Paris; male. 1858. *Museum Fund.*
69. Ditto. Female. 1868. *Museum Fund.*
70. Cranium, with the separated bones of the rest of the skeleton; adult. From Paris. 1852. *Museum Fund.*
71. Ditto. 1858. *Museum Fund.*
72. Model skull of a young female. 1856. *Dr. R. M. Hodges.*
73. Calvaria sawed off, to show the base of the skull internally. 1849.
74. Adult cranium disarticulated, and the bones separately mounted (Beau Chêne). Artery and vein of the upper and

lower jaw shown upon one side, and the nerve upon the other. From Paris. 1849. *Dr. J. C. Warren.*

75. Bones of the cranium separated. 1847. *Dr. J. C. Warren.*
76. Upper maxillary, portion of frontal bone, etc.; distinguished by different colors for anatomical demonstration. 1861. *Dr. O. W. Holmes.*
77. Posterior portion of occiput; surface for muscular attachment strongly marked. 1847. *Dr. J. C. Warren.*
- Styloid process. See hyoid bone.
78. An adult skull, sawed in various directions. From Paris. 1856. *Museum Fund.*
79. A second specimen. Internal ear also dissected. 1858. *Museum Fund.*
80. Bones of the face, separated and mounted. 1847. *Dr. J. C. Warren.*
81. Wooden model of a portion of the skull, greatly enlarged. 1847. *Dr. O. W. Holmes.*
82. Same, of the cornu sphenoidale. 1847. *Dr. O. W. Holmes.*
83. Spinal column articulated. 1847. *Dr. J. C. Warren.*
84. Spinal column, pelvis, and anterior half of cranium; ligamentary preparation. 1847. *Dr. J. C. Warren.*
85. Pelvis; ligamentary preparation. 1847. *Dr. J. C. Warren.*
86. The same. From Paris. 1858. *Museum Fund.*
87. Os innominatum; linea ilio-pectinea strongly marked. 1847. *Dr. J. C. Warren.*

88. The same. Process for the insertion of the tendon of the psoas parvus strongly marked. 1847.
Dr. J. C. Warren.
89. Bones of the hand separately mounted. 1849.
Dr. J. C. Warren.
90. The same, of the foot. 1849. *Dr. J. C. Warren.*
91. Wooden model, greatly enlarged, of the lower portion of the radius and ulna, carpus, one metacarpal bone, and three phalanges. 1847. *Dr. O. W. Holmes.*
- 92-9. Collections of lower maxillary bones, vertebræ, ribs, clavicles, ossa innominata, patellæ, sternal and sacral bones. 1847. *Dr. J. C. Warren.*
100. Vertical section, showing one lateral half of the cranium and trunk; also, a section that shows very perfectly the parts within the nasal cavity. From Paris, and mounted so as to revolve. 1862. *Museum Fund.*
101. Calvaria, from which the outer table has been rasped off, to show the diploe. *Dr. J. C. Warren.*
102. The same. Prepared by Dr. H. 1856.
Dr. O. W. Holmes.
103. Calvaria removed, and showing the frontal sinuses, which are very large. 1847. *Dr. J. C. Warren.*
104. Vertical section of a portion of the skull, from before, backwards, and upon one side of the median line; to show the sinuses. 1856.
105. Vertical section through the base of the skull, and cervical vertebræ; frontal and sphenoidal sinuses large. Cartilaginous septum of the nostrils shown. 1847.
Dr. J. C. Warren.

106. Horizontal section through sphenoid bone and orbits.
1847. *Dr. J. C. Warren.*
107. Cranium, showing a section through the bones of the face,
from side to side. 1847. *Dr. J. C. Warren.*
108. Portion of a skull, to show the nasal cavity. 1847.
Dr. J. C. Warren.
109. Ditto. Shows the frontal, æthmoid and sphenoid cells ;
the nasal duct, antrum High., and the Eustachian tube,
with their membranous portions. Carotid injected where
it passes through the bone. 1862.
Dr. O. W. Holmes.
110. Mate to the last ; macerated. Central lamella, with the vo-
mer, etc., shown. 1862. *Dr. O. W. Holmes.*
111. Sections of the neck of the femur, to show how its ana-
tomical structure explains the phenomena of extra-capsular
fracture, to which it is so liable ; made by Dr. Bigelow, and
described by him as follows : —
“To exhibit this structure, which has hitherto been un-
noticed, sections should be made in the following man-
ner : —
“A well-developed femur is to be secured, in a nearly
vertical position ; the axis of the neck being carefully
placed in the plane of the horizon. A thin slice is now
taken from the top of the neck, including at its extremities
the top of the head of the bone, and the top of the great
trochanter ; this section passing through the neck, in a
direction parallel with the plane of the horizon. A sec-
ond, third, and fourth slice, each one-fourth of an inch thick,
are now to be sawed from the neck, parallel with the first.
There will now remain, attached to the shaft of the femur,
only the lower part of the head, and a narrow lower isthmus
of the neck. On examining the cut surface of this last
section, it will be found that the anterior wall of the neck
is one-eighth of an inch thick, or more, while the posterior
wall is of a papery thickness only.

“It follows that in the usual impaction of the neck of the femur, the anterior wall refuses to be impacted. The posterior wall, on the contrary, is deeply imbedded into its own substance, offering little or no resistance to the force producing the fracture. The impaction, therefore, takes place exclusively on the posterior aspect of the neck, while the anterior and thick wall, acting as a hinge at the point of fracture, allows the outward rotation of the shaft, so constantly observed in these cases.

“In making these sections, another anatomical peculiarity will be observed, provided the bone is healthy, and well developed. This will be best seen in the new specimen. Let the small trochanter, the intertrochanteric line, and the back part of the great trochanter be removed with a fine saw, in one piece. By getting rid of this projecting mass, the back of the neck may be brought into a continuous curve with the back of the shaft. The part removed will be found to be merely a buttress of spongy tissue, built out for the attachment of the muscles, while the true neck of the femur will be discovered beneath the removed portion, uniting the back of the neck continuously with the true shaft below.

“This true neck may be demonstrated by lightly scraping out, with a rongeure, the cancellar structure, until the instrument is arrested by the firm wall beneath. This last is the true neck, and offers some slight resistance to the impaction of the posterior wall. On the last section, in the preparation first described, this true neck will be seen as a very thin line, continuous with the posterior wall of the neck, plunging beneath the intertrochanteric line, or buttress, and passing towards a point corresponding with the middle of the outside of the shaft. Before reaching this, however, it loses itself in radiating spokes or fibres, which, though quite slender, seem intended to contribute by their mechanical arrangement, a little towards the strength of the bone.

“After examining these preparations, it will be readily seen why the impaction is so exclusively upon the back of the neck, producing outward rotation, and why it not unfrequently splits off the small trochanter, and the intertro-

chanteric line, by means of the posterior wall of the neck, which is wedged beneath them.

“The impaction here described, is, doubtless, a very frequent accident; not uncommonly resulting in complete union at the end of a few months, more frequently occurring than the fracture within the capsule, and by no means so grave a lesion as certain authors have considered it. In fact, its only indications, in some cases, are persistent local pain, attended with a very slight shortening, and rotation outwards of the limb, and of course, without crepitus.

“An additional and important remark should be here made, in relation to the shortening of the limb, which rarely results, in these cases, from the separation of the fragments, but only from the obliquity of the anterior hinge. In illustrating this, it will be seen that, if this hinge were vertical, the neck, thus hinged upon the shaft, would merely rotate around the axis of the shaft, and there would be no shortening; but, as the hinge is placed at an angle of 45° , the neck rotates not only backwards, but downwards; or, which is the same thing, the shaft ascends, and the whole bone is shortened.”

Dr. H. J. Bigelow.

112. Femur, prepared by Dr. B., to show that the trochanters are superadded, and that the true neck passes beneath them. 1866.

Dr. H. J. Bigelow.

- 113-24. Sections of the vertebræ, sacrum, pelvis, scapula, femur, and metatarsal bone. 1847.

Dr. J. C. Warren.

125. The same, of the humerus, to show the thinness of the olecranon fossa. 1859.

Dr. R. M. Hodges.

126. The same. Os calcis. 1851.

Dr. O. W. Holmes.

IV. COMPARATIVE ANATOMY.

127. Skeleton of an African monkey (macacus). This specimen, and Nos. 155, 164-6, 168-71, 177-8, and 182, were

prepared, during his leisure hours, by Mr. Isaac Pierce, a constable of this city, and articulated and mounted in the most superior style. Purchased of him in 1862.

Museum Fund.

128. Cranium of a young monkey. 1869.
129. Skeleton of a bat, by Mr. H. 1854.
Mr. S. Foster Haven, med. student.
130. Clavicles of a leopard. The muscle, with which it was in connection, is dried with one of them. The external extremity is the smallest. 1862. *Dr. J. B. S. Jackson.*
131. Cranium of a jaguar. 1847. *Dr. O. W. Holmes.*
132. Skeleton of a cat. 1851. *Dr. O. W. Holmes.*
133. Cranium of a cat. 1847. *Dr. J. C. Warren.*
134. The same — longitudinal section. 1869.
135. The same. Bones separated, separately mounted, and marked according to Prof. Owen's system (Archetype and Homologies of the Vertebrate Skeleton). 1869.
Mr. Wm. P. Bolles, med. student.
136. Lig. skeleton of a dog (bull-terrier bitch); by Dr. B. 1856. *Dr. J. N. Borland.*
137. Cranium of a full-blooded Newfoundland dog, about eighteen months old, and accidentally killed. 1846.
Mr. Edward Sawyer, med. student.
138. Cranium of a dog that was brought to this country by Capt. Judkins, of the Cunard steamers; a mixture of the Newfoundland and St. Bernard breeds. 1850.
Dr. J. B. S. Jackson.
139. Cranium of an old English pointer, that died of a large post-pharyngeal abscess. 1868. *Dr. H. J. Bigelow.*

140. Cranium of a dog; bones separated by Dr. A. 1848.
Dr. Thomas Andrews, Jr., of R. I.
- 141-2. Cranium of a weasel and skunk. 1855.
Dr. O. W. Holmes.
143. Cranium of a harp seal (*Phoca Greenlandica*); brought
by Dr. S. from Labrador. 1858. *Dr. H. R. Storer.*
144. Skeleton of a raccoon (*Procyon lotor*). 1862.
Museum Fund.
145. Cranium of an American porcupine (*Hystrix dors*). 1847.
Dr. O. W. Holmes.
146. Skeleton of a squirrel. 1862. *Museum Fund.*
147. Skeleton of a woodchuck (*Arctomys monax*). 1851.
Dr. O. W. Holmes.
148. Cranium of the same. 1851. *Dr. O. W. Holmes.*
- Alpine marmot. Series xxvii.
149. Cranium of a fœtal calf; bones separated by Dr. H.
1855. *Dr. O. W. Holmes.*
150. Transverse section, through the horn of an ox, and the
process that supports it; shows the extension of the sinus-
es into this last. 1864. *Dr. J. B. S. Jackson.*
151. Cranium of a sheep; prepared by Dr. H. 1855.
Dr. O. W. Holmes.
152. Cranium of a sheep; bones separated by Dr. H. 1855.
Dr. O. W. Holmes.
153. Skeleton of a fawn, about eighteen months old, and from
Mexico; prepared by Mr. O. 1850.
Dr. Geo. Hayward, Sen.

154. Cranium of a deer; lower jaw wanting. 1847.
Dr. J. C. Warren.
155. Skeleton of a musk deer (*Moschus pygmæus*). Besides the extreme delicacy of this beautifully prepared and diminutive little skeleton, there are to be remarked the long, curved, and pointed canine teeth in the upper jaw, and in this, only, do they exist. The metacarpal and metatarsal bones, also, that support the dew-claws, are as long as those for the other toes. 1862. *Museum Fund.*
- 156-7. Cranium of a mare, and of a colt that belonged to Dr. H., and prepared by him. 1855.
Dr. O. W. Holmes.
158. Femur of a horse, in reference to No. 238.
Dr. C. M. Wood, Vet. Surgeon.
159. Cranium of a babyroussa, from Malacca. The upper tusks are said to exist only in the male, and to pass through the upper lip. 1865.
Dr. Henry C. Perkins, of Newburyport.
160. Portion of the sternum of an ostrich, showing the peculiar structure of the bones in birds. 1860.
Mr. Wm. B. Gibson.
161. Skeleton of an eagle. 1851. *Dr. O. W. Holmes.*
162. Skeleton of a bald-headed eagle. This bird was for many years in the possession of the first Dr. John Jeffries, of this city, and after its death was prepared, as it is now seen, by his son, the present Dr. Jeffries, Sen. The muscles are partially shown, with the trachea and œsophagus; and the heart is injected. One humerus is broken, and strongly but very irregularly united. 1847.
Dr. J. C. Warren.
163. Cranium of a hawk. 1855. *Dr. O. W. Holmes.*

164. Skeleton of an owl. The large bony plates in the sclerotic are shown. 1862. *Museum Fund.*
165. Skeleton of a kingfisher. 1862. *Museum Fund.*
166. Skeleton of a robin. 1862. *Museum Fund.*
167. Cranium of a crow. 1855. *Dr. O. W. Holmes.*
168. Skeleton of a parrot; orbit complete. 1862. *Museum Fund.*
169. Skeleton of a sickle-billed curlew. 1862. *Museum Fund.*
170. Skeleton of a duck. 1862. *Museum Fund.*
171. Ditto. Merganser duck; bill long and narrow, and the edge serrated. The trachea is shown, dilated midway; and the lower larynx is largely developed. 1862. *Museum Fund.*
172. Typical vertebra. The specimen consists of the dorsal vertebra of a crow, the rib upon each side, with its cartilage, and the corresponding portion of the sternum. (See Prof. Owen's Archetype and Homologies of the Vertebrate Skeleton; Fig. 15, p. 82). Prepared by Dr. H. 1855. *Dr. O. W. Holmes.*
173. Bill of an albatross. 1862. *Museum Fund.*
174. Skeleton of a small tortoise (*Emys insculpta*). *Dr. O. W. Holmes.*
175. Bones of the plastron of a tortoise (*Emys picta*) separated and mounted by Dr. H. 1855. *Dr. O. W. Holmes.*
176. Gopher, from the Southern States. Head and bones of the extremities separated, and the long articular processes

- of the last cervical and first dorsal vertebræ are remarkable. 1847. *Dr. J. C. Warren.*
177. Skeleton of a tortoise, from Madagascar (*Testudo radiata*). As in the tortoises generally, as distinguished from the turtles, it either wants the metacarpal and the metatarsal bones, or one phalanx from each toe. 1862. *Museum Fund.*
- 177½. Box-tortoise; skeleton imperfect. 1862. *Museum Fund.*
178. Skeleton of a snapping-turtle (*Emysaurus serpentina*). 1862. *Museum Fund.*
179. A second specimen, prepared by Dr. H. 1855. *Dr. O. W. Holmes.*
180. Cranium of a loggerhead turtle. 1851. *Dr. O. W. Holmes.*
181. Cranium of a green turtle; longitudinal section. 1851. *Dr. O. W. Holmes.*
182. Skeleton of an alligator, from Florida (*Crocodylus lucius*). Posterior ribs connected with the transverse processes of the vertebræ, and the anterior with these processes and the bodies. Shows the cervical and abdominal ribs; the scapula and coracoid bone, but no clavicle; one opening into the pharynx from the two Eustachian tubes. 1862. *Museum Fund.*
183. Skeleton of an African serpent (*Python bivittatus*) that measured 9½ feet in length. Five or six of the ribs upon one side are nearly wanting, but whether from disease, or from an arrest of development, does not appear. 1861. *Museum Fund.*
184. Skeleton of a striped snake (*Sutalis coluber*); by Dr. H. 1855. *Dr. O. W. Holmes.*

185. Skeleton of a frog; prepared by insects; the great divisions being displayed separately upon a black-board. Shows the absence of ribs; the transverse processes of the vertebræ; the formation of the body of the scapula in two pieces; the large coracoid bones meeting upon the median line; the slender clavicles; the fusion of the radius and ulna, and of the tibia and fibula. 1862.

Mr. Wm. Andrews, Janitor of the College.

186. Ligamentary skeleton of same; by Mr. P. 1860.

Mr. Henry S. Plympton, med. student.

187. Ligamentary skeleton of a striped basse (*Labrax lineatus*); by Dr. H. 1855. *Dr. O. W. Holmes.*

188. Cranium of a large cod; lig'y preparation, by Dr. H. 1855. *Dr. O. W. Holmes.*

189. A second specimen, prepared by Dr. H., to show the vertebral formation. 1855. *Dr. O. W. Holmes.*

190. A third specimen. The numerous bones have been separated, attached to a black-board, and numbered and labelled to correspond to Prof. Owen's system (*Archetype and Homologies of the Vertebrate Skeleton*). 1855.

Dr. O. W. Holmes.

V. ANATOMICAL VARIETIES.

191. Interparietal bone. 1847. *Dr. J. C. Warren.*

192. A second, very large. 1847. *Dr. J. C. Warren.*

193. A third, confined to the left side. 1847.

Dr. J. C. Warren.

194. Wormian bone, of the size of the finger-nail, and about the middle of the sagittal suture — an unusual situation. From a child four or five years of age. There is also a want

of symmetry in the skull, so far as it is preserved. 1852.

195. Skull, showing a persistence of the frontal suture. 1869.

Dr. Francis Minot.

196. Parietal bones, from a new-born child, that died from no very obvious cause; preserved in connection, and generally well developed; but toward the sagittal suture are several deficiencies of bone of considerable size, and such as are occasionally seen in hydrocephalic skulls. 1857.

Dr. H. R. Storer.

A third articular surface, upon the anterior edge of the foramen magnum, and corresponding with the apex of the odontoid process; the *condylus tertius* of Meckel. Shown in a deformed cranium; No. 1551.

197. A portion of the frontal bone, showing a thin ridge of bone upon the median line, internally. It commences one-fourth of an inch in front of the crista galli, extends about 2 in. upwards, and is gradually lost; width at the base, $\frac{1}{2}$ in. From a man, æt. 25. 1860. *Dr. Calvin Ellis.*

Large parietal foramina; see No. 961.

198. Atlas ununited upon the posterior median line; from a Sandwich Islander. 1856. *Dr. R. M. Hodges.*

199. Cast in plaster of the atlas of an adult that was purchased in Paris, by Prof. R. D. Mussey, and regarded as a case of non-union of the odontoid process. This last was of full size, and ankylosed firmly to the atlas; the base of the process being smooth. The wings of the vertebra were ununited posteriorly, as in the last specimen, but otherwise there was nothing unusual in the bone. 1852.

Museum Fund.

200. The two first cervical vertebræ of an adult subject; met with in Dr. W.'s dissecting-room by Dr. B. Joy Jeffries,

and prepared by him. The odontoid process is fully developed, and forms a perfectly distinct bone.

In the Proc. of the London Pathological Society (Vol. ix. p. 346), a case is reported and figured of separation of the odontoid process and axis; but from disease, as it was supposed.

In this and the last specimen there is no appearance either of disease or fracture. 1858. *Dr. J. Wyman.*

201. Atlas; six specimens, to show the development of a foramen for the passage of the vertebral arteries over the wings and behind the articulating processes; in one there is not even a groove. 1849. *Dr. O. W. Holmes.*
202. Spine of an adult; six lumbar vertebræ. 1847. *Dr. J. C. Warren.*
203. Sacrum; four bones. 1850. *Dr. O. W. Holmes.*
204. Sacrum; a small bone is connected with the last vertebra, and from these two there stand off three other coccygeal bones, at an angle of about 45°. 1857. *Dr. R. M. Hodges.*
205. Thorax of an adult; thirteen pairs of ribs. 1859.
206. The two upper ribs. Prolongation upward from the upper edge of the second, and meeting the first, but not co-ossified with it. 1847. *Dr. J. C. Warren.*
207. Rib, with its cartilage; and showing commencing bifurcation at its anterior extremity. 1859. *Dr. J. B. S. Jackson.*
208. Spine, ribs, and pelvis, in connection. Most of the bodies of the cervical vertebræ, and of the four upper dorsal, are more or less fused. The corresponding laminae are also fused, and imperfectly and irregularly developed. There are thirteen pairs of ribs, and upon the left side the three first are fused; these last being not much larger than one,

posteriorly, but forming, anteriorly, a broad and thin expansion. In the lumbar and upper part of the dorsal regions, the spine is somewhat curved; but otherwise there is nothing unusual. 1847. *Dr. J. C. Warren.*

209. Episternal bones, as described by Breschet. The whole sternum is preserved, and upon its upper edge, posteriorly, are situated two symmetrical bones, one upon each side of the median line, and about the size of large orange-seeds. The mode of connection with the sternum was not ascertained by Dr. H.; the bone having been found by him, in 1841, in a heap with others in the dissecting-room. This specimen and the next were formerly in the Cabinet of the Society for Medical Improvement.

210. A second specimen, essentially resembling the above, and that Dr. H. has since met with. 1847.

Dr. O. W. Holmes.

Dr. J. Wyman refers to formations, similar to the above, that he has met with about the knee in man, and particularly in rodents; and he questions whether they are to be regarded as anything more than sesamoid bones.

211. Sternum and clavicles of a rat, showing the true episternal bones between the two; and the same, from a younger individual, in which they are not yet developed; prepared by Dr. W., who refers to an article upon these bones, as they appear in Mammalia, and in Man, by C. Gegenbauer (Natural History Review, Vol. v. October, 1865). 1866.

Dr. J. Wyman.

212. An upper and lower extremity from the oldest of the above (No. 211); showing two sesamoid bones in the tendons of the gastrocnemii muscles, and one in a tendon at the head of the radius. 1866. *Dr. J. Wyman.*

These two last specimens are recorded here, though out of place, as they refer particularly to the two that preceded.

213. A small opening through the sternum, upon the median line, and just below the cartilages of the fourth rib. These last are partially ossified, and the ensiform is largely developed and ossified. 1847. *Dr. J. C. Warren.*

214. Thorax of a fœtus, showing a bifid condition of the sternum throughout, except, perhaps, at the very upper extremity; preserved in spirit. From a monstrosity. 1863. *Dr. J. B. S. Jackson.*

215-16. Ensiform cartilage of different forms. 1847. *Dr. J. C. Warren.*

217. An imperfectly developed clavicle, from a little girl, who died of acute disease at the age of eleven years. It is $1\frac{3}{4}$ in. in length, nearly $\frac{1}{2}$ in. in width, flattened and moderately curved. There was the usual attachment to the sternum, but Dr. C. observed none to the scapula. The other was similarly affected. The father of the child, who was exhibited to the Society for Medical Improvement, by Dr. C., has both clavicles in the same condition; but something like the outer half of these bones was indistinctly felt in connection with the scapula. He stated that two of his brothers had the same malformation; and he thinks that his father, from the slope of his shoulders, may have had the same. He has had seven boys and two girls; and all of the boys have had the malformation on one side or both. In regard to strength, and a free use of the upper extremities, he thinks that there is no deficiency in any of his family who are thus malformed. 1868.

Dr. Ephraim Cutter, of Woburn.

218. Scapulæ from an adult male. Acromion process fully developed, but quite distinct from the body of the bone; between which there was in the recent state a synovial cavity, but with little or no motion. The connecting membrane was cut through so as to expose the cavity. Bones otherwise fully developed. In one the acromion has been lost. 1854. *Dr. R. M. Hodges.*

219. Left scapula; adult. Union of acromion very imperfect. 1858. *Dr. R. M. Hodges.*

220. Scapula from some loose bones that had been collected by Dr. W. The acromion process is firmly united to the body of the bone; but the line of union is perfectly distinct, and the specimen might very readily be mistaken for one of old fracture. The epiphysis at the lower angle is not yet fully united to the body of the bone.

221. Scapula, evidently the mate of the last, and found amongst some of Dr. W.'s loose bones, though not with the last specimen. A large portion of the acromion has been broken off and lost; and from appearances, it may have been since the bone was prepared. Otherwise there is the same appearance of union between what remains of the acromion and the body of the bone that is seen in the last specimen. 1847. *Dr. J. C. Warren.*

There are also two other specimens in the museum; and the anomaly may be considered as sufficiently common.

222-9. A series of scapulæ, to show the development of the supra-scapular notch. 1849. *Dr. O. W. Holmes.*

230-1. Two clavicles, showing the difference of curvature that is occasionally seen in this bone. 1849.

Dr. O. W. Holmes.

232-3. Lower portion of the humerus, showing the supra-condyloid process. Two specimens, from different subjects; prepared by Dr. H., and reference given to a description of this anomaly by Mr. John Struthers, in the Brit. & For. Med. Review, for July, 1854. 1858.

Dr. R. M. Hodges.

234. A third specimen, by Dr. H. The ligament that passes from the process to the inner condyle of the humerus is shown. 1859. *Dr. R. M. Hodges.*

235. A humerus, showing an opening through the olecranon fossa. 1849. *Dr. O. W. Holmes.*
236. The two humeri of a Flat-head Indian, showing the same. 1860. *Museum Fund.*
237. One humerus, and parts of four others; and in four of these there is a similar and large opening. These bones are undoubtedly of Indian origin, having been dug up on Long Island, in Boston harbor, when a regiment was encamped there in 1861. Eight or ten individuals were found, and Dr. P. A. O'Connell, the surgeon of the regiment, and a former student of Dr. C., to whom the specimens were sent, stated that he examined the humeri, with especial reference to the existence of an opening through the fossa, and he believed that the humerus that is here shown was the only one in which it did not exist. Many years ago, Dr. Charles T. Jackson noticed this opening in the humerus of an Indian, from this neighborhood, and subsequently in another from the State of Maine. Dr. J. Wyman has also met with it in the N. American Indians; and, in the year 1853, at the Garden of Plants, in Paris, he saw the skeletons of seven negroes, with seven perforations in the fourteen humeri; three of them being perforated upon both sides, and one upon one side only. See *Med. Journal*, Vol. LXVI. p. 233. 1862. *Dr. Henry G. Clark.*
238. A portion of the left femur, showing a growth of bone from the linea aspera, and rather below the middle of the shaft, about two inches in length, three-fourths of an inch in height, thick at the base, and thinner towards the edge, and inclining toward the outer aspect of the bone. Dr. H. referred to a notice, by Mr. Humphry, in his work on the Skeleton, of this form of growth, under the name of "Supra condyloid process;" Mr. H. quoting two anatomists, who had described it, and regarding it as the analogue of what is found in the horse (No. 158) and the rhinoceros. 1859. *Dr. R. M. Hodges.*

239. A second specimen, very similar to the above. 1857.
240. The right fibula of an adult, showing the external surface deeply grooved to the extent of six or seven inches. Bone quite healthy. 1860. *Dr. R. M. Hodges.*

SERIES II.—SOFT PARTS CONNECTED
WITH THE BONES.

241. Calvaria of a young child, showing a minute injection of the pericranium and dura mater. 1847.
Dr. J. C. Warren.
242. Half of the thorax, probably from the same subject, and showing the vascularity of the periosteum over the ribs. 1847.
Dr. J. C. Warren.
243. Very marked blackish discoloration of the periosteum of the tibia of a fowl; and one of the tendons is shown, similarly affected; in spirit. Quite common in the Spanish breed of fowls, according to Dr. Cabot. See No. 629. 1863.
Dr. W. E. Coale.
244. Growth from a costal cartilage, about $\frac{3}{4}$ in. in length, and probably a malformation; in spirit. 1861.
Dr. J. B. S. Jackson.
245. Ligaments about the odontoid process. 1847.
Dr. J. C. Warren.
246. Ditto—sternum, a wet specimen. 1847.
Dr. J. C. Warren.

Ligaments of the pelvis. See Nos. 85-6.

- 247-9. Ligaments of articulation of lower jaw, hip, and knee;

- and prepared by the late Dr. S. Parkman. In spirit. 1847. *Dr. J. C. Warren.*
250. The tip of the spinous process of the axis, with three pairs of muscles that arise from it; dissected out and dried. Prepared by Dr. H., and named by him, "Stella musculosa nuchæ." 1868. *Dr. O. W. Holmes.*
251. An Italian wax preparation, showing upon one side of the head and neck, the muscles, lymphatics and ganglia, arteries and veins, and the parotid gland, with its duct. 1847. *Dr. J. C. Warren.*
252. A similar preparation of the upper extremity, showing the outer layer of muscles, superficial veins, and absorbents, and the ganglion near the inner condyle of the humerus. 1847. *Dr. J. C. Warren.*
253. Diaphragm, distended and dried. 1847. *Dr. J. C. Warren.*
254. Rectus sternalis muscle, in connection with the bone and cartilage; in spirit. For a figure of this case, with remarks by Dr. Holmes, see *Med. Jour.* Vol. LVII. p. 321. 1858. *Dr. R. M. Hodges.*
255. A second case (musculus sternalis). This was met with in the dissecting-room, by Dr. Hodges, and described as follows:—
- "Origin has no direct connection with the sternum until it reaches the cartilages of the fifth and sixth ribs, to which it is attached, giving off also a small strip to the sternum. The upper right slip is continuous with the clavicular portion of the pectoralis; the under one with the sternal part of same; the left slip is blended with the pectoralis of that side. At its lower insertion it passes wholly underneath the pectoralis; at its upper part, or origin, it is continuous with the sterno-mastoid. The part of the pectoralis arising from third, fourth, and fifth costal cartilages is nearly wanting."

The preparation consists of a very accurate and artistic drawing, in water colors, by Mr. B., from the dissection by Dr. Hodges. 1869.

Mr. William P. Bolles, med. student.

256. Muscular anomaly. An additional head arises just below the insertion of the coraco-brachialis, and is inserted into the biceps just below the union of its two heads. A dry specimen, and prepared by Mr. H. 1856.

Mr. Joseph S. Hildreth, med. student.

257. Another three-headed biceps; the additional head arising from the outer side of the humerus, just below the insertion of the deltoid. Prepared by Mr. P. 1863.

Mr. G. W. Pease, med. student.

258. Tendon injected; in spirit. 1847.

Dr. J. C. Warren.

259-60. Tendons of a bird ossified. Also the spur of a cock; and co-ossified with the metatarsal bone. 1857.

Dr. J. B. S. Jackson.

261. A delicate areolar tissue, from which the oil has exuded, and a coarse, fibrous, elastic tissue. From the head of a sperm whale. 1857.

Dr. L. Bartlett, of New Bedford.

SERIES III.—ORGANS OF CIRCULATION.

I. HEART.

262. Organ injected; an Italian preparation. 1847.

Dr. J. C. Warren.

263-4. Two other specimens. 1847.

Dr. J. C. Warren.

265. Model of the heart, etc.; cavities shown. By Auzoux, of Paris. 1851. *Museum Fund.*
266. Heart injected, etc.; from a child. Spine and part of thorax preserved. 1847. *Dr. J. C. Warren.*
267. The same, with the lungs in connection. 1847. *Dr. J. C. Warren.*
268. Right auricle and ventricle injected, but not the left. 1847. *Dr. J. C. Warren.*
269. Heart of a child, injected. 1847. *Dr. J. C. Warren.*
- 270-2. Mould in plaster of the cavity of the right auricle and ventricle, and of the left auricle; and in wax of the left ventricle. 1847. *Dr. J. C. Warren.*
273. Heart injected with alcohol; and, when stiffened, cut away to show the cavities and the valves; in spirit, and prepared by Dr. H. 1857. *Dr. R. M. Hodges.*
274. A second specimen, similarly prepared, by Dr. H., to show the relations of the valves. 1858. *Dr. R. M. Hodges.*
275. Heart and lungs of an adult; and the same of a child; in spirit. 1847. *Dr. J. C. Warren.*
276. An adult and healthy heart, upon which an experiment was performed in 1858, when M. Groux was here, and whose case (bifid condition of the sternum) excited so much interest in this country and in Europe. The object was to show what different parts of the organ corresponded to certain points in the anterior parietes of the chest.
- As the subject lay upon the back, long needles were thrust in perpendicularly, as follows: Immediately to the left of the sternum, between the second and third cartilages (1); between the third and fourth (2); and between the fourth and fifth (3). Immediately to the right of the sternum, between the third and fourth cartilages (4); and be-

tween the fourth and fifth (5). Middle of the sternum, between the third cartilages (6); and between the fourth (7). Just below the very anterior extremity of the fifth rib, upon the left side (8).

The thorax was then opened, and the heart removed without displacing the needles; and the result was as follows:—No. 1 passed through the left branch of the pulmonary artery; No. 2, through the pulmonary artery at the upper edge of the valves, and very near to the right side; and through the left auricle, very near to its appendix; No. 3, through right ventricle $\frac{1}{2}$ in. below the pulm. valves, through adherent margin of aortal valves, through upper edge of mitral valve, and through the other side of left auricle, $\frac{1}{3}$ in. above the valve; No. 4, through appendix of right auricle, near the base, junction of upper vena cava and auricle towards left side, and through left auricle very near to pulm. veins; No. 5, through right auricle, anteriorly, one inch above tricuspid valve; No. 6, through aorta, $\frac{3}{4}$ in. above valves, midway in regard to the circumference, and through right branch of pulm. artery; No. 7, through appendix of right auricle, aortal valves towards right side, and through the middle of the left auricle; No. 8, through the fat at the apex, and just beneath the pericardium, but without entering the cavities of the heart.

After the heart had been examined, strong threads were passed through in the course that the needles took, numbered 1–8, and tied. 1858. *Dr. J. B. S. Jackson.*

277. Heart of a cat, injected; with the vessels at the arch of the aorta. By Mr. H. 1860.

Mr. John Homans, Jr., med. student.

278. Heart of a woodchuck; with the vessels at the arch of the aorta. By Mr. E. 1860.

Mr. R. T. Edes, med. student.

279. Heart and blood-vessels of a “snapping turtle”; injected and prepared by Mr. E. With one lung. 1860.

Mr. R. T. Edes, med. student.

280. A portion of the heart of an ox, showing a large ossific mass just below the aortal valves, and that, according to Cuvier, is so generally found in herbivorous animals; dried. 1847. *Dr. J. C. Warren.*

In five fresh specimens, that I have examined recently, I found the bone in all; and it may be remarked that the structure is that of true bone.

281. Heart of a tortoise; in spirit. 1847. *Dr. J. C. Warren.*

282. Model, by Auzoux, of Paris, to show the circulation in the serpent. 1851. *Museum Fund.*

283. Heart and bloodvessels of a black snake; injected and prepared by Mr. E. One lung is also shown. 1860. *Mr. R. T. Edes.*

- 284-6. Hearts, with the blood-vessels and other organs of three large African serpents; one only dissected. The length of the animals was, respectively: 17 ft., 10 ft. 1 in., and 6 ft. 9 in. 1860. *Museum Fund.*

287. Heart of a shark, injected; with the branchial arteries; by Dr. J. Wyman. 1847. *Dr. J. C. Warren.*

- 288-9. Models, by Auzoux, showing the circulation in the carp, and in the mussel. 1851. *Museum Fund.*

II. BLOOD-VESSELS.

290. Mould of the interior of the pulmonary artery. 1847. *Dr. J. C. Warren.*

291. Fœtal circulation. 1847. *Dr. J. C. Warren.*

292. The same. Enlarged copy of the drawing in Mr. John Bell's Anatomy.

This shows well the fact that the ductus venosus opens into one of the hepatic veins, and not into the vena cava,

as is generally stated and figured in some of the text-books. 1861.

Mr. Charles M. Carleton, med. student.

293. The same, in a calf. By Messrs. H. & E.

Messrs. John Homans, Jr., and R. T. Edes, med. students.

294. A full-length preparation, by Dr. J. M. Warren. Heart and blood-vessels injected, and relations to the muscles shown. A negro, of immense size, who died at an early age, of phthisis, and measures now 6 ft. 2 in. in height. 1847.

Dr. J. C. Warren.

295. A similar preparation, of a young subject; one side of the cranium and of the jaw divided for a better display of the parts. 1847.

Dr. J. C. Warren.

296. The same; subject within a year old. This preparation shows a high division of the left brachial artery. 1847.

Dr. J. C. Warren.

297. Aorta and primary branches, in connection with the spine, etc. The phrenic art. arises from the cœliac axis. 1847.

Dr. J. C. Warren.

298. Vertebral arteries throughout; with spine and base of skull. 1847.

Dr. J. C. Warren.

299. Arteries from base of brain; displayed upon a board. 1849.

Dr. Edwin Leigh.

300. Arteries of head and neck. The transverse facial upon the left side quite large, and the facial small. The brain was removed through the nostrils. By Dr. H. 1850.

Dr. O. W. Holmes.

301. The same. Prepared for Dr. B. by Dr. R. M. Hodges. 1856.

Dr. Henry J. Bigelow.

302. Half of the cranium, showing an artificial representation

of the arteries and veins; with explanatory list and figures. From Paris. Alveoli cut away to show the vessels of the teeth. The septum opens, to show the nostrils and the sinuses. Outer table removed from one of the parietal bones, to show the diploe, and the veins ramifying in it; and the bone being raised, a wax representation is seen of the dura mater and its vessels. 1851. *Dr. J. C. Warren.*

303. Arteries of the neck, dissected out, and displayed upon a black-board; thyroids particularly shown. 1850.

Mr. H. B. C. Greene, med. student.

304. Distribution of the internal carotid and internal maxillary. By Dr. H. 1849. *Dr. O. W. Holmes.*

305. Internal and external carotids, with the vertebrals; the temporal bone being cut away. A branch from the arteria innominata replaces the left inferior thyroid. By Dr. H. 1858. *Dr. R. M. Hodges.*

306. A portion of the carotid arteries, from each side; injection to show the bulging that exists at the origin of the internal branch. By Dr. H. 1858. *Dr. R. M. Hodges.*

307. Branches of the carotid arteries, with the subclavian, and the axillary. Internal maxillary particularly shown. By Dr. H. 1856. *Dr. R. M. Hodges.*

308. Branches of the axillary artery. 1849. *Dr. O. W. Holmes.*

309. Left side of head, thorax, and shoulder; showing the carotids, subclavian, and axillary; falx, etc., and the Eustachian tube. By Dr. H. 1860. *Dr. R. M. Hodges.*

310. Head, with part of thorax, and upper extremities. Heart injected, with the arteries. 1847. *Dr. J. C. Warren.*

311. External carotid, with some branches of the subclavian. 1847. *Dr. J. C. Warren.*

312. Head, trunk, and portions of the extremities of a child; injected. 1847. *Dr. J. C. Warren.*
313. Branches of the abdominal aorta, and left inguinal artery. By Dr. S. Parkman. 1847. *Dr. J. C. Warren.*
314. An Italian wax preparation, showing the upper vena cava, subclavian and jugular veins, the v. azygos, and thoracic duct, throughout their entire course, the passage of the aorta through the diaphragm, the lumbar muscles, and the lymphatics and ganglia along the spine. 1847. *Dr. J. C. Warren.*
315. Upper and lower venæ cavæ, with branches; v. azygos, major and minor; and the veins of the right upper extremity. By Dr. C. 1862. *Dr. D. W. Cheever.*
316. First intercostal arteries; origin and distribution. By Dr. H. 1849. *Dr. O. W. Holmes.*
317. Posterior branch of intercostal artery. By Dr. H. 1849. *Dr. O. W. Holmes.*
318. Posterior branches of intercostal artery; and, particularly, the one that enters the spinal canal. By Dr. H. 1857. *Dr. O. W. Holmes.*
319. Inosculation between the epigastric and internal mammary arteries. By Dr. A. 1850. *Dr. Frederick S. Ainsworth.*
320. Arteries from the abdominal aorta; their origin, and to a considerable extent, their distribution. By Dr. H. 1856. *Dr. R. M. Hodges.*
321. Head and trunk, showing the organs of the thorax and abdomen, in situ, and injected. 1847. *Dr. J. C. Warren.*
322. Cæliac artery, and its branches; organs in connection. By Dr. H. 1854. *Dr. R. M. Hodges.*

323. Arteries of the stomach, etc. ; organ inflated. 1850.

A wax preparation, to show the hepatic artery, vena portæ, passage of vena cava behind the liver, and the obliterated umbilical vein. See No. 685.

324. A wax preparation of the spleen, with the artery, vein, and lymphatics. 1847. *Dr. J. C. Warren.*

325. Aorta, with the superior and inferior mesenteric arteries, and their branches. A portion of the intestine preserved. As an anomaly, the colica media arises from the cœliac axis. From a child. By Dr. C. 1862. *Dr. D. W. Cheever.*

326. Portion of intestine inflated and dried, and the mesenteric artery injected. 1847. *Dr. J. C. Warren.*

327. The same. By Dr. H. 1850. *Dr. R. M. Hodges.*

328. The same. By Dr. H. 1847. *Dr. O. W. Holmes.*

The same. From an elephant. No. 663.

329. The same. Ileo-colic artery. 1850.

330. Right upper extremity, head, thorax, and left shoulder. Arteries shown ; high division of right brachial. 1847. *Dr. J. C. Warren.*

331. Right upper extremity, with one-half of thorax and head ; axillary, subclavian, and carotid particularly shown. Thoracic duct injected ; and is seen entering the vein. 1847. *Dr. J. C. Warren.*

332. Section through head and thorax, showing the carotid, subclavian, and axillary arteries. By Dr. H. 1849. *Dr. O. W. Holmes.*

333. A preparation, to show the inosculation between the posterior scapular, and subscapular arteries. 1849. *Dr. O. W. Holmes.*

334. Arteries of the upper extremity. 1847.
Dr. J. C. Warren.
335. The same. 1850. *Dr. H. J. Bigelow.*
336. The same; with the nerves. By Mr. H. 1850.
Mr. Chas. H. Hildreth, med. student.
337. The same; a child. 1847. *Dr. J. C. Warren.*
338. Veins of the upper extremity, with the arteries. 1847.
Dr. J. C. Warren.
- Superficial veins; wax preparation. See No. 252.
339. Arterial inosculation about the elbow-joint; with the origin and distribution of the superior profunda. By Dr. H. 1850.
Dr. R. M. Hodges.
340. Inosculation about the elbow. By Mr. B. 1850.
Mr. Albert H. Blanchard, med. student.
341. Arteries and veins about the elbow; also the nerves about last. By Dr. R. M. Hodges. 1856. *Dr. H. J. Bigelow.*
342. Upper extremity of a cat, injected, to show the passage of the brachial artery through the supra-condyloid foramen. By Dr. H. 1859. *Dr. R. M. Hodges.*
343. Arteries of the forearm and hand. By Mr. H. 1849.
Mr. R. M. Hodges, med. student.
344. The same. 1849. *Mr. Luther Parks Jr., med. student.*
345. The same. The radial divides three or four inches above the wrist, and sends a large branch to the superficial palmar arch. By Dr. S. Parkman. 1847.
Dr. J. C. Warren.
346. Arteries of the hand. By Dr. H. 1862.
Dr. O. W. Holmes.

347. The same. By Dr. C. 1861. *Dr. D. W. Cheever.*
348. The same. By Dr. A. 1849. *Dr. F. S. Ainsworth.*
349. The same; a child. 1847. *Dr. J. C. Warren.*

These last preparations show much variation in the distribution and relative size of the branches.

350. Arteries of the pelvic region, and right thigh. By Dr. S. Parkman. 1847. *Dr. J. C. Warren.*
351. Iliac arteries and branches; the obturator arises about equally from the int. iliac and epigastric. By Mr. H. 1849. *Mr. R. M. Hodges, med. student.*
352. Internal iliac, iliac, profunda, and circumflex arteries. The obturator receives a small branch from the epigastric. By Dr. A. 1849. *Dr. F. S. Ainsworth.*
353. Iliac arteries and vein. The inguinal canal, external ring, and Gimbernat's ligament also shown. From a child. 1847. *Dr. J. C. Warren.*
354. Iliac artery and veins. By Dr. R. M. Hodges. 1856. *Dr. H. J. Bigelow.*
355. Internal iliac artery, etc. By Dr. H. 1856. *Dr. R. M. Hodges.*
356. Inguinal arteries. The obturator arises, by a common and short trunk, with the epigastric, from the inguinal. By Dr. H. 1850. *Dr. O. W. Holmes.*
357. Arteries of the left lower extremity. By Dr. S. Parkman. 1847. *Dr. J. C. Warren.*
358. Arteries of right lower extremity, with internal iliac. From a child. 1847. *Dr. J. C. Warren.*
359. Arteries of right lower extremity. By Dr. H. 1860. *Dr. R. M. Hodges*

360. Veins of lower extremity. 1847. *Dr. J. C. Warren.*
361. Popliteal artery. 1847. *Dr. J. C. Warren.*
362. Popliteal artery, with the inosculation about the knee-joint. By Dr. A. 1850. *Dr. F. S. Ainsworth.*
363. The same. By Dr. B. 1850. *Dr. J. Nelson Borland.*
364. Arteries of the foot. By Mr. H. 1849.
Mr. R. M. Hodges, med. student.

III. MALFORMATIONS.

365. Foramen ovale open ; size of a catheter ; valvular ; a dried specimen. From a woman, *æt.* 25. No cardiac symptoms ; and the heart was healthy.
This opening in the adult seems to be as common here as elsewhere. 1850. *Dr. J. B. S. Jackson.*
366. The same. Three specimens ; in spirit. 1850.
Dr. J. B. S. Jackson.
367. The same ; dried. The opening is large enough to admit the tip of the little finger, but valvular. From a woman who could not have been less than sixty-five years old, and in whom the heart was healthy, though a large aneurism arose from the asc. aorta. 1869.
Dr. J. B. S. Jackson.
368. Foramen ovale ; direct opening, 1 in. in diameter. From a lady, *æt.* forty-five years. No trouble until the age of nineteen, when dyspnœa came on, and this increased until death ; with lividity, but no palpitation ; pulse regular, and otherwise well. Thoroughly examined by Dr. B., five years before death ; physical signs as in "absolute health," and the case was regarded as functional. Seen again by him a few days before death, when there was extreme and permanent dyspnœa, but with a good pulse ; no murmur, and no physical sign of disease, except some slight indication by

percussion of enlargement of the heart. The lividity was extreme before death. On dissection, the right cavities were found much hypertrophied, but the left were healthy; as were also the valves. The whole heart is preserved. 1860.
Dr. Henry I. Bowditch.

369. A direct inter-auricular opening, more than $\frac{1}{2}$ in. in diameter, and just above the valves, which are somewhat imperfectly developed. Three or four small direct openings also, in fossa ovalis. Right ventricle rather thick, and the ductus arteriosus would have allowed the passage of the head of a pin. Organ otherwise well; and a part only is shown. From a child that died of pneumonia, at the age of five months. Stunted in its growth; paroxysms of dyspnœa from birth, and often livid; pulse rapid, small, and irregular. See Amer. Jour. of Med. Sc.; April, 1850. 1852.
Dr. M. S. Perry.

370. Interventricular opening, from a mulatto child, four years old. Dyspnœa, lividity, and paroxysms of distress, almost from birth. Action of heart regular, but with a loud bellows sound. The opening is, as usual, free, and at the upper part of the septum. Right ventricle much thickened, as usual, and the left rather thin. The pulm. artery was small, arose rather indirectly from the ventricle, and had two valves, which differed much in size, but were otherwise normal. Aorta enlarged, and the valves well. 1861.
Dr. J. B. S. Jackson.

371. Interventricular opening, from a delicate little girl, six years old. She always had hurried breathing, with rapid and violent action of heart, but was never livid. Œdema the last four months; with ascites, for which she was tapped several times. Dr. C. found the sternum prominent, and the heart evidently "distended"; the first sound "rushing," and the second clear. The opening was four lines in diameter, between the ventricles; these last being thickened, and the left perhaps a little the most so. Valves of the pulm. artery thickened, and two of them fused. Pericarditis. Liver echymosed; showing the tendency to

hemorrhage in these cases that has been several times observed here. 1855. *Dr. William E. Coale.*

372. Interventricular opening, from a little girl eleven years and eight months old. Tall, and very delicate, and at last died of phthisis. Lividity from birth, with palpitation and dyspnoea. Opening would have admitted the end of the little finger, and the aorta arose, of full size, directly above it. Pulm. artery rather small, and had two valves. Left ventricle thinner, and right much thicker than usual. Foramen ovale; small opening. 1858.

Dr. N. L. Folsom, of Dover, N. H.

373. Interventricular opening; and the pulmonary artery arises from the aorta. From a premature fœtus. 1850.

Dr. J. B. S. Jackson.

374. A portion of the interventricular septum, with the aorta. The upper portion of the septum, to the extent of half an inch, is thin and membranous, with a sort of pouch in the centre, three lines in diameter. From a man, æt. forty-five, who died of phthisis. 1855. *Dr. Calvin Ellis.*

Case of interventricular opening, in which there has been a question whether it was congenital, or the result of an accident. See No. 1706.

375. Interventricular opening; ductus arteriosus largely open, and the pulmonary artery entirely closed at its origin. The subject of this case had always been a puny little girl, of small stature, and died of phthisis at the age of four years and four months. From the age of six or eight months, she had always been livid, and particularly on exercise. She was subject, also, to a slight hacking cough, palpitation, and paroxysms of dyspnoea; the breathing being rapid, and almost panting when she was asleep. Extremities usually very warm, so that she was in the habit of kicking off the bedclothes, and hanging her feet out of the bed to cool them. The ends of the fingers and toes

were very markedly clubbed; and the nails were adunque, very large, and very livid.

Dr. T. saw her two weeks before her death, for the first time, and on the occasion of a hæmoptisis, the amount of blood lost being at least a pint. She had once or twice before raised a few bloody sputa; and the day before the hemorrhage she had played out of doors, and rather more actively than usual. Being very irritable, the chest was only examined upon the left side, when she was asleep. The respirations were 80, and strongly puerile; action of the heart tumultuous; the radial pulse being too feeble to be counted. The sounds seemed to be sufficiently well-marked, but accompanied with a hissing or blowing sound. 1868. *Dr. C. C. Tower, of S. Weymouth.*

376. Interventricular opening. The pulmonary artery also
 • arose from the aorta; but this, unfortunately, was not preserved. From a lad, æt. 18. There was blueness of the surface from birth; increasing for the first ten or twelve years, and greatly increased by mental excitement. Extreme dyspnœa on active exercise, with palpitation. Pulse very variable, irregular, and intermitting. Died from phthisis; having had frequent attacks of hæmoptisis for more than two years. The parietes of the organ, and size of the cavities are not remarkable. 1869.

Dr. H. I. Bowditch.

377. A foetal heart, showing one common auricle, and no open-
 • ing into the left ventricle. Right ventricle rather large, and the left rather small, with very free opening between the two. The aorta is quite small just before it joins the ductus arteriosus.

Several of these specimens are from malformed fœtuses. 1850. *Dr. J. B. S. Jackson.*

378. Malformed heart, from a child eight months old. Parox-
 • ysms of dyspnœa from birth, once or twice every twenty-four hours, and for an hour or two, with lividity, though at other times the color was natural. The two auricles are of the usual size; foramen ovale open. The left ventricle is

about as large as the two should be, but the right would not have contained half a drachm of fluid. Opening between the two ventricles about two lines in diameter, but none from the right auricle. Pulmonary artery arises from right ventricle, and is of full size; one valve imperfectly developed. 1852. *Dr. F. S. Ainsworth.*

379. Heart from a malformed fœtus (No. 866). There is an interventricular opening, and an occlusion of the pulmonary artery. This last is small, and the ductus arteriosus long and quite slender. 1859.

380. A sacculated pouch just below the Eustachian valve, quite defined, and readily admitting the end of the little finger; about as thick as the neighboring parts, and shows no sign whatever of disease. From a healthy, adult heart. By coincidence, a precisely similar specimen was met with during the same week. 1860.

Dr. J. B. S. Jackson.

381. Two-valved aorta, from a man æt. 35. 1859.

Dr. J. B. S. Jackson.

382. Two-valved pulmonary artery, from an adult. 1856.

Dr. J. B. S. Jackson.

383. A second specimen. 1861.

384-5. Two foetal hearts, showing an additional upper vena cava; opening in one into the left auricle, and in the other just below the Eustachian valve. 1850.

Dr. J. B. S. Jackson.

Fusion of two hearts. See monstrosities.

Origin of a thyroid artery, from the art. innominata. See No. 301.

386. Origin of the vertebral artery, from an injected aorta. 1861.

387. Right subclavian art. arises from the arch of the aorta, and passes behind the œsophagus; injected. By Dr. K. 1852. *Dr. Samuel Kneeland, Jr.*
388. Arch of the aorta, showing the two carotids arising by a short and common trunk, and the left subclavian quite near to them. The right subclavian arises three-fourths of an inch beyond this last, and considerably further back; and, as usual in such cases, passed behind the œsophagus. 1859. *Mr. J. Homans, Jr., med. student.*
389. Thyroid axis arises at some distance beyond the external border of the anterior scalenus muscle; and beyond it the internal mammary artery. By Mr. F. 1849. *Mr. Jabez Fisher, med. student.*
390. A large branch from the int. mammary runs downward upon the inside of the ribs. By Mr. H. 1858. *Mr John T. Heard, med. student.*
391. A second specimen; but a smaller branch. Prepared by Dr. H., who observed three cases of this anomaly, at the same time, in the dissecting-room, in the winter of 1857-8; and in all it existed upon each side. 1858. *Dr. R. M. Hodges.*
392. A preparation, by Dr. H., showing the bronchial arteries arising from the aorta, the intercostal, and right subclavian; the œsophageal arising from the bronchial, and the aorta; the right subclavian supplying the three upper intercostal spaces, and sending branches to the neck, which Dr. H. thought might be regarded as cervical intercostals. 1857. *Dr. R. M. Hodges.*
393. Arteries dissected out, and displayed upon a black-board. The right radial arises from the very upper part of the brachial, and the left from the axillary. And the middle thyroid arises from the art. innominata. From a child. By Dr. K. 1852. *Dr. S. Kneeland, Jr.*

- High division of the brachial art. No. 330.
394. A second specimen; and, further, the radial divides, about the middle of the fore arm, into two branches of nearly equal size. 1859.
395. Origin of the interosseous art., from about the middle of the brachial. By Dr. H. 1857. *Dr. R. M. Hodges.*
396. A second specimen. By Mr. P. 1856.
A writer in the Gazette des Hopitaux (Feb. 4, 1861), refers to this anomaly as occurring "assez souvent."
Mr. M. P. Page, med. student.
397. A large branch from the radial over the back of the wrist, to the first and second fingers. By Mr. C. 1858.
Mr. Chas. F. Crehore, med. student.
398. Arch of aorta, etc. A large bronchial art. arises from the right subclavian, and runs down along the trachea. Vertebral from the arch. By Dr. H. 1854.
Dr. R. M. Hodges.
- Colica media, from the cœliac axis. No. 325.
399. The two kidneys, showing four arteries arising from the aorta upon one side, and two upon the other. 1849.
400. Kidney, with two renal arteries. From the same subject as No. 393. 1852. *Dr. S. Kneeland, Jr.*
401. Kidney, with a portion of aorta; one renal art. arises from this last, and one from the common iliac, near its origin. By Dr. K. 1852. *Dr. S. Kneeland, Jr.*
- Obturator, from the inguinal, in common with the epigastric. No. 356.
- The same, about equally from the int. iliac and epigastric. No. 351.

402. Peroneal and posterior tibial arteries communicate $1\frac{1}{2}$ in. above ankle-joint, by a large, transverse branch; the peroneal above this being the largest of the two. By Dr. S. 1855. *Dr. A. D. Sinclair.*
-

SERIES IV.—LACTEALS AND LYMPHATICS.

I. LACTEALS.

403. Drawing, to show these vessels, in a pirate. Taken just after his execution in this city in 1812. 1847. *Dr. J. C. Warren.*
404. Thoracic duct injected. 1847. *Dr. J. C. Warren.*

The same. See Nos. 314 and 331.

II. LYMPHATICS.

Along spine. No. 314.

Head and neck. No. 251.

- 405-6. Outer surface of temporal bone; along the internal mammary artery; and the left subclavian region. Mercurial. 1847. *Dr. J. C. Warren.*

Upper extremity, and ganglion at elbow; superficial. No. 252.

- 407-8. Arm, and back of fore arm; mercurial. 1847. *Dr. J. C. Warren.*

- 409-15. Along the iliac vessels; inner and upper part of thigh; the whole lower extremity; groin, thigh, and upper part

- of leg; knee, leg and ankle; knee and ankle; popliteal region. Mercurial. 1847. *Dr. J. C. Warren.*
416. Surface of the lung; mercurial; in spirit. 1847.
Dr. J. C. Warren.
417. Surface of foetal liver; mercurial. 1847.
Dr. J. C. Warren.
- Surface of spleen. No. 324.
418. Gall bladder; mercurial. 1847. *Dr. J. C. Warren.*
419. Penis. Wet specimen; mercurial. 1847.
Dr. J. C. Warren.
- 420-1. Bladder and penis; mercurial. 1847.
Dr. J. C. Warren.
422. A wax preparation, showing the lymphatics of the penis, testicles, and cord. On the left side the lymphatics and ganglia of the groin; and on the right the same, as they may appear in venereal disease. 1847.
Dr. J. C. Warren.

SERIES V. — CEREBRO-SPINAL SYSTEM.

I. MEMBRANES.

423. Skull of a child, sawed to show the dura mater. The nasal septum is also shown, minutely injected. 1847.
Dr. J. C. Warren.
424. Adult cranium sawed transversely, for a different view of the same. 1847.
Dr. J. C. Warren.
425. French preparation, to show the same; very complete. 1852.
Museum Fund.

Injection of the dura mater. Nos. 241 and 302.

II. BRAIN.

426. Large model of the base, with the nerves at their origin. 1850. *Dr. Usher Parsons, of Providence, R. I.*
427. An enlarged model, in plaster, of the central portion of the brain. By Dr. H. 1862. *Dr. O. W. Holmes.*
- 428-35. Models, by Auzoux, of Paris, of the brain of man, the cat, rat, goose, calf, viper, tortoise, and shark. 1851. *Museum Fund.*
436. Brain of a dog-fish. 1850. *Dr. J. Wyman.*

III. MALFORMATIONS.

- 437-8. Photographs, and a colored lithograph, of the "Aztec children," male and female; idiot dwarfs, and probably from Mexico. 1862. *Museum Fund.*

On the 7th of January, 1867, the Aztecs were married, in London, and in great style. For an account of the ceremony, as given by the "London Herald," see the "Boston Transcript," for Jan. 25.

439. Photographs of the "Australian children," also male and female, and resembling each other enough to be brother and sister, as did the "Aztecs." They also resembled these last, but were older and larger than the "Aztecs" would have been; and it was ascertained, beyond any reasonable doubt, that they were not the same. The male was 5 ft. 3 in. in height, and the female, 4 ft. 3 in. The male could say a few words, as "No," "You lie;" but the female had never been known to utter a word. They looked very healthy, were very active and vivacious, as such subjects usually are, and very salacious. Breasts of the female well developed. Apparently Caucasians. 1866. *Museum Fund.*

440. A colored lithograph of a negro idiot; a young adult. His stunted condition ($3\frac{2}{12}$ ft.), healthy appearance, happy expression, and frequent protrusion of the tongue from his half-open mouth were perfectly characteristic. When he closed his mouth the incisor teeth did not meet, but left an elliptical opening, as in the Chimpanzee; the elbow and knee-joints could not be fully extended, and the calves are seen in the figure to be quite small. His head, which was formed as usual in such cases, and was one of the smallest, seemed to be kept shaved; and measured, antero-posty. $4\frac{7}{8}$ in., in circumference $14\frac{1}{2}$ in., between the orifices of the ears $3\frac{7}{8}$ in., and from the chin to the vertex $6\frac{7}{8}$ in. The attendant stated that he never made any articulate sounds; that he had to be attended to every two or three hours for his excretions; that he had hair upon the pubes, and an occasional erection, but he had never known him to have an emission, nor to show any tendency to masturbation. 1862. *Museum Fund.*

Casts of the heads of idiots, transferred from the Phrenological collection; all but the six last being originally from the collections of Dr. Spurzheim, and Mr. Holm, of London. 1847. *Dr. J. C. Warren.*

- 441-3. Pimault, with the skull and brain. The skull is in Esquirol's collection, at Salpêtrière.
444. "Sukey Hilling, sixty years of age; height 5 ft. 3 in.; weight 13 stone 11 pounds. Living at Beccles, Suffolk. Cast 12th of February, 1827. During her youth, she had the cerebellum active. Has sufficient locality to wander from home in the fields, and finds her way back; is fond of colors, and submitted to be cast on receiving a gaudy-colored shawl."
- 445-9. "Tom Franklin, John, Maria, Mary, Susan. The whole family, seven in number, are idiots. The father and mother keep the jail at Bungay, Suffolk, and are frequently intoxicated."
450. "Idiot inferior to ourang outang." Cast of skull.

451. Brain of an idiot; partial hydrocephalus.
452. Brain of an idiot; water let out.
453. Idiot girl, who died at Cork, æt. 17.
454. Idiot man, who died at Amsterdam, æt. 25.
455. Idiot of Suabia.
456. Idiot of St. Denis; æt. 21.
457. Head marked "Denys," and apparently an idiot.
458. Skull marked "Denys."

IV. SPINAL MARROW.

459. A portion of the organ, showing the origin of the nerves, ganglia, etc. Prepared by Dr. J. Wyman. 1847.
Dr. J. C. Warren.
460. The same. By Dr. A. 1849. *Dr. F. S. Ainsworth.*
461. Microscopic preparations, by Dr. E., of the spinal cord of an adult, and new-born child; also of an ox and sheep. 1868.
Dr. R. T. Edes.
462. Cauda equina. 1847. *Dr. J. C. Warren.*
463. Model, by Auzoux, of Paris, of the spinal marrow, with a portion of the brain, and showing the origin of the nerves. 1851. *Museum Fund.*
- 464-70. The same, of the nervous system of the butterfly, caterpillar, chrysalis, spider, star-fish, lobster, and aplysia. 1851. *Museum Fund.*

V. NERVES.

471. A wax preparation, very much injured by an accident, but still showing the fifth pair of nerves, and the distribution of its different branches, with their ganglia; also the par vagum, and sympathetic. Other parts will be elsewhere referred to. 1847. *Dr. J. C. Warren.*

472. One-half of the cranium. Artificial representation of the nerves, with explanatory list and figures, etc. By Guy of Paris. 1851. *Museum Fund.*
473. Maxillary bones, with the distribution of the fifth pair of nerves. 1847. *Dr. J. C. Warren.*
474. One-half of the head, showing the distribution of the portio dura, with some of the cervical nerves. 1847. *Dr. J. C. Warren.*
475. Preparation by Dr. H., showing the sympathetic, the two splanchnics, the par vagum, hypoglossal, the spinal nerves, and their connection with the sympathetic, and the semi-lunar ganglion. 1860. *Dr. R. M. Hodges.*
476. A model of the brachial plexus; its different filaments being separated in order to show the origin of each of its collateral and terminal branches. Prepared by Dr. H., after Sappy. 1858. *Dr. R. M. Hodges.*
477. Nerves of the upper extremity; also the fifth pair, the par vagum, and the communication between this last and the cervical nerves. 1859. *Messrs. John Dean, and Chas. F. Crehore, med. students.*
478. Nerves of the upper extremity. By Dr. H. 1856. *Dr. R. M. Hodges.*
479. The same. 1847. *Dr. J. C. Warren.*
480. Lower extremity and side of pelvis, showing the nerves. By Dr. H. 1859. *Dr. R. M. Hodges.*
481. Passage of a branch of one of the brachial nerves through a vein. This last is divided about equally, and the two branches reunite immediately after the nerve has passed through. 1855. *Mr. L. M. Sargent, med. student.*

SERIES VI.—SKIN AND APPENDAGES.

482. Skin of the face of a child, minutely injected, and dissected off, in the form of a mask. By Dr. Estes Howe. In spirit. 1847. *Dr. J. C. Warren.*
483. Skin injected, and the cuticle partly removed; in spirit. 1847. *Dr. J. C. Warren.*
484. The same; dried. With a power of fifty diameters the free inosculation of the vessels is finely shown. By Dr. D. 1860. *Dr. Silas Dunkee.*
485. The same; in turpentine. 1847. *Dr. J. C. Warren.*
486. Skin from the sole of the foot, with the cuticle partially removed; in spirit. 1847. *Dr. J. C. Warren.*
487. Skin of a negro; cuticle partially raised with the pigment; in spirit. 1847. *Dr. J. C. Warren.*
488. A piece of human skin, from the nates; tanned as hides usually are; in hemlock bark. 1856.
Dr. Ephraim Cutter, of Woburn.
- 489-92. Skin of an adult male, dissected off from the umbilicus to the knees; the whole being most elaborately tattooed to this extent, and not excepting the penis; cuticle removed. Secondly, a portion of subcutaneous cellular tissue colored. Third, several of the inguinal glands, quite darkly colored externally; but some of them having been cut open, are seen to be colorless within, in part. Fourth, carbon removed from some of these last, by Dr. John Bacon; portions of the lymphatic vessels containing coloring matter so as to render them visible.
- Virchow describes and figures this passage into the lymphatics of the carbonaceous matter, in the case of tattooing. 1857.
493. The same. Red and black; cuticle removed; in spirit. 1862. *Mr. W. B. Gibson, med. student.*
494. Section of the skin of a sperm whale; in spirit. About

1½ in. thick; and the cuticle being removed, the papillæ are well shown, covered by pigment. This and the two next specimens were sent in 1857, by

Dr. Lyman Bartlett, of New Bedford.

495. The same. Dried, and shows that it contains no oil.
496. The same. From the interior of the blow-hole; dried; quite thin, but color the same as the above.
497. Skin of a sturgeon, dissected off and dried. 1869.
Mr. Wm. Andrews, Janitor of the College.
498. A portion of the skin of the "ditch-toad," as it is called in Surinam (*Bufo aqua*); showing a very great development of the cutaneous glands. 1869. *Dr. J. Wyman.*
499. Cast-off shell of the horse-shoe; the investing membrane of the eye being detached with it, as usual. Dr. W. remarked that the earthy matter is absorbed before the separation takes place. 1852. *Dr. J. Wyman.*
500. A lock of hair from a lady who is a very perfect albino. She has a brother who is nearly as perfect a specimen as herself, and a sister whose complexion is quite dark. 1853. *Dr. Edwin Leigh.*
501. One-half of the upper lip of a seal, showing the great development of the whiskers, and of the nerve that goes to them. The large branch, with its filaments, have been dissected out, and also the sheaths from which the whiskers arise. By Dr. J. 1852. *Dr. J. B. S. Jackson.*
502. A hairy mole, from the forehead of an infant, of an oval form, and about two inches in length. 1859.
Dr. C. D. Homans.
503. A dark brown, congenital mark, with hair upon it; from a Flat-head Indian. 1860. *Museum Fund.*
- 503½. Photograph of a bearded woman, who was seen here on exhibition. Upon the chin and sides of the face there is as

full a beard as many men have ; but upon the upper lip no more hair than is seen in some women. 1868.

Museum Fund.

504. Cutaneous excrescence, from the side of the neck of a hog ; about $2\frac{3}{4}$ in. in length, $\frac{3}{4}$ in. in diam., and perfectly healthy in appearance. A similar one was upon the other side of the neck ; and it was stated that others were found in other hogs of the same lot. 1857. *Dr. A. A. Gould.*

SERIES VII.—EYE.

Minute injection of the vessels of the eye. The following ten preparations were made by Dr. Horace Senter, of Newport, R. I., a fellow-student of Dr. W., in London. Dr. S. was a most zealous anatomist ; and, having died young, the preparations were purchased after his death by Dr. W. 1847. *Dr. J. C. Warren.*

505. Choroid.
506. Choroid ; larger vessels.
507. Choroid ; larger vessels.
508. Choroid ; full injection.
509. Choroid ; iris in situ.
510. Ciliary processes ; well injected.
511. Iris injected.
512. Retina injected.
513. Venæ vorticosæ, injected.
514. Shows the iris in situ very well ; the ciliary processes, and the choroidal vessels.
515. Large model, by Auzoux, of Paris ; shows the different tunics, lachrymal gland, muscles, arteries, and nerves. 1847. *Dr. O. W. Holmes.*

- 516-17. Wax preparations, showing the internal structure. By Dr. Chiappi, an Italian artist, and formerly of this city. 1847. *Dr. J. C. Warren.*
518. The same. 1847. *Dr. J. C. Warren.*
519. Sclerotic coat distended, and cut open. Conjunctiva dissected off, and inverted. A dry preparation. 1847. *Dr. J. C. Warren.*
- Muscles of the eye, and lachrymal gland. No. 472.
520. Eyelids dissected off, and dried; and bristles passed through the puncta lach. 1847. *Dr. J. C. Warren.*
521. Two moulds, showing, first, the lachrymal canals and sac; and, second, a lachrymal canal, the sac and the passage into the nostril; the cavities having been injected with fusible metal, or something of the kind. The first specimen shows an indentation upon the surface of the sac, just after the canals have opened into it; and this Mr. P. supposes to mark the existence of an undescribed valve. 1864. *Mr. M. G. Parker, med. student.*
522. The eyeball, in situ, and dissected to show the capsule of Tenon, with the sup. rectus passing to it, and the insertion of the other recti muscles into the sclerotic coat. For a full anatomical description, by Dr. J., with a figure, see the publications of the Mass. Med. Soc'y, for 1868. 1869. *Dr. B. Joy Jeffries.*
- 523-4. Bony plates in the sclerotic of a bird. 1847. *Dr. J. C. Warren.*
- The same, in an owl. See No. 164.
525. Bony sclerotic, from the eye of a sword-fish. 1857. *Dr. J. Wyman.*
526. A blind-fish (*Amblyopsis spelæus*, Dekay), from the Mammoth Cave, Ky. About 2 in. in length. 1852. *Mr. Charles Kidder, med. student.*
- In the Amer. Jour. of Sc. and Arts, March, 1854, Dr. J. Wyman has given a full description of the anatomy of the

eye in this fish, with figures, founded upon the dissection of three specimens, and a partial examination of fourteen others. In one that measured four inches in length, the eyes were $\frac{1}{16}$ in. in their long diameter, of an oval form, and black; and a filament of nerve was distinctly traced from the globe to the cranial walls. Examined under the microscope, with a power of about twenty diameters, Dr. W. made out satisfactorily a sclerotic, a layer of pigment cells that might be regarded as a choroid, and of colorless cells to represent the retina; and in the front part of the globe, a lenticular body, about which he thought there was a question as to whether it should be regarded as the crystalline lens, or not.

527. A blind craw-fish, from the above locality; about 3 in. in length. 1852. *Mr. C. Kidder.*

SERIES VIII.—EAR.

528. A very large model of the organ, by Auzoux, of Paris; external and internal. 1847. *Dr. O. W. Holmes.*
529. Large model, in wood, of the external ear. 1847. *Dr. O. W. Holmes.*
530. Mould, in plaster, of the external meatus, and inequalities of the external ear; both sides. By Dr. H. 1859. *Dr. R. M. Hodges.*
Opening of Eustachian tube in the throat. See Nos. 109 and 309.
531. Dissection of the internal ear. From Paris. 1847. *Dr. J. C. Warren.*
532. The same. 1867. *Museum Fund.*
The same. See Nos. 79 and 472.
- 533-4. Temporal bone of a fetus, and of a child, cut away to show some of the internal parts. 1847. *Dr. J. C. Warren.*

535. Cavity of the tympanum; fœtal. 1847.
Dr. J. C. Warren.
536. Adult bone, cut away to show the membrane of tympanum.
By Mr. M. 1865. *Mr. Paul Munde, med. student.*
537. Ossicula from the adult. Several specimens, in which the
"orbiculare" is co-ossified with the incus. 1857.
Dr. J. B. S. Jackson.
538. Large wooden models of the ossicula. 1847.
Dr. O. W. Holmes.
539. Cartilage of Meckel shown in situ, in a fœtal pig upon
one side. And upon one side of the animal there has been
hung the cartilage from a human fœtus; from each side,
meeting upon the median line, and with the mallei attached.
By Dr. W., who refers to a full article upon the subject,
with figures, by MM. Magilot and Robin, in the *Annales*
des Sc. Nat. for 1862; Vol. XVIII. 4th series. 1865.
Dr. J. Wyman.
540. Preparation to show the mastoid cells. 1847.
Dr. J. C. Warren.
- 541-3. Two large models, in wood, and one in wax, of the in-
ternal ear. 1847. *Dr. J. C. Warren.*
544. Portion of the integument, showing the very small size of
the external ear, in the cetaceans. From a porpoise, about
5 ft. long. A bristle can just be passed through the carti-
laginous external meatus. 1852. *Dr. J. Wyman.*
545. Head of an owl, showing the absence of feathers about
the external meatus, and how this last opens, as Dr. Wyman
remarked, upward upon one side, and downward upon the
other. 1847. *Dr. J. C. Warren.*

SERIES IX.—ELECTRICAL ORGANS.

546. Transverse section of the body of an eel, showing the

great development of the electrical organ. By Dr. J. Wyman. 1847. *Dr. J. C. Warren.*

SERIES X.—MOUTH, NOSTRILS, ETC:

I. TEETH.

547-66. A series of preparations, to illustrate their natural history; the age of each subject being marked, approximately. From Paris. 1847.

Dr. William R. Lawrence.

567-70. Large wooden models of an incisor, canine, bicuspid, and molar tooth. 1851. *Dr. O. W. Holmes.*

Section through the cavity of a first incisor, and the crown of the permanent one. No. 607.

571-2. An adult molar tooth, from which the earthy matter has been removed by an acid; in spirit. And a bicuspid similarly treated, and dried. 1857.

Mr. Wm. A. Thompson, med. student.

Nerves supplying the teeth. No. 471.

573. Two upper incisors, that had appeared through the gum when the child was born, and were extracted, as they interfered with nursing. 1860. *Dr. A. A. Gould.*

573½. Upper molar; four fangs. 1862.

574. Skull of an adult, showing the two upper canine teeth, quite behind the incisors, and almost buried in the jaw. One of them has been accidentally lost. The lateral incisors, judging from their sockets, must have been very small, if they were ever shed. Lower teeth well. 1852.

575. A skull from Paris, showing the two canines high up in the upper maxillary bone; and the crowns being exposed, they are seen to point upward instead of down. The four incisors are in place. 1847. *Dr. J. C. Warren.*

576. A portion of the lower max. bone, showing a large tooth, and apparently a canine, imbedded in the bone; the point

being considerably below the edge of the alveolus. A section of the bone passes directly through the tooth. 1847. *Dr. J. C. Warren.*

577. A permanent incisor tooth, consisting of a well-developed crown and neck. Removed by Dr. H. from the antrum of a little boy, ten years old, and in whom it had caused dropsy of that cavity. A piece of bone having been removed from just above the alveoli, a large quantity of viscous, transparent fluid was discharged, and the tooth was seen lying flatwise on the posterior wall of the antrum, and firmly implanted there. Dr. H. refers to two similar cases, by A. Dubois and Blasius; and to these may be added one that is figured by Mr. Stanley, in his work on Dis. of the Bones. 1863. *Dr. R. M. Hodges.*

It is remarkable, in the above case, that it should have been an incisor tooth.

- 578-9. Two casts, in plaster, of the upper jaw, and showing an additional tooth between the incisors. Both adults. In one the tooth is of considerable size, and placed edgewise; and the woman said that she "had always had it." In the other it is nearly or quite as long as the incisors, but slender and conical; the man said that it appeared when he was fourteen years old. 1849. *Dr. E. Leigh.*

580. Bicuspid tooth cut away, to show the cavity filled with gold. 1857. *Mr. W. A. Thompson, med. student.*

581. Molar tooth of an East Indian elephant. 1860. *Boston Soc. of Nat. History.*

582. The same; horizontal section, and polished. 1860. *James C. Converse, Esq., a merchant of this city.*

583. Three teeth from a horse. 1860. *Dr. J. B. S. Jackson.*

584. Small tooth from a sperm whale. 1860.

585. Whalebone in its natural state, and showing the union of the laminae. 1847. *Dr. J. C. Warren.*

586-90. Jaws of a shark, to show the teeth; five specimens.
1847. *Dr. J. C. Warren.*

591. A sixth specimen. The individual was taken by Mr. M., off Nantucket, and is known there as the "Sand Shark." The length was about 8 ft. 1869.

Mr. Henry M. Martin, of Roxbury.

592. A transverse section of the lower jaw of the mackerel shark, showing the dental groove, and the teeth coming forward in succession. Some of these last are perfectly, and some quite imperfectly, developed; and the membrane has been removed from about the last, for their better display. By Dr. W. 1858. *Dr. J. Wyman.*

593. A pharyngeal bone, from one of the Labroid fishes, and showing the characteristic globose teeth. Some of these last have not yet descended, and are loose in the alveolar cavities, whilst others are ankylosed to the bone, as so often happens in fishes. From Florida. 1868.

594. Saw of a young saw-fish. 1862. *Museum Fund.*

595. Jaws of a fish (Lophius americanus), to show the teeth. 1847. *Dr. J. C. Warren.*

596. The same, of the Trichiurus, showing a very formidable set of teeth. Dr. Kneeland remarked that "the upper border of the mouth is formed wholly by the intermaxillaries; the maxillaries being above." 1861. *Museum Fund.*

II. GLANDS.

597. The head of a rattlesnake, showing the poison-gland, and the duct that connects it with the fang. The animal was five or six feet in length, and was shot by Dr. W., in Florida. Prepared by Dr. W. 1869. *Dr. J. Wyman.*
Parotid and submaxillary. Nos. 251 and 471.

598. Portion of mucous membrane, from the side of the tongue of a sperm whale, and showing a great development of glands below the surface. 1857.

Dr. L. Bartlett, of New Bedford.

III. TONGUE.

599. Minute and full injection. From a child. 1847.
Dr. J. C. Warren.
Nerves and muscles. No. 471.
600. Hyoid bone; pieces separated. 1847.
Dr. J. C. Warren.
601. The same; large wooden model. 1847.
Dr. O. W. Holmes.
602. The same. Prepared by Dr. C., in connection with the base of the skull. Styloid ligament extensively ossified upon each side. 1865.
Dr. D. W. Cheever.
603. Very long "styloid process," with a portion of the temporal bone; not co-ossified. 1847. *Dr. J. C. Warren.*
604. Hyoid bone of a sheep, in connection with the cranium. 1855.
Dr. O. W. Holmes.

IV. MOUTH.

605. One-half of the head of a young child; shows the mouth, throat, opening of the Eustachian tube, etc.; in spirit. 1847.
Dr. J. C. Warren.
606. Throat and tongue dissected, to show the muscles and nerves; in spirit. 1847. *Dr. J. C. Warren.*

V. NOSTRILS.

- Septum opens, and shows the cavity, with the blood-vessels and sinuses. No. 302. See also No. 472, for the nerves, and No. 423 for a minute injection of the septum.
607. Section through the nostrils of a child; showing the turbinated bones, and passing through the teeth. 1847.
Dr. J. C. Warren.

SERIES XI.—VOCAL AND RESPIRATORY
ORGANS.

I. LARYNX AND AIR-PASSAGES.

608. Large model of the larynx, by Auzoux, of Paris; showing the cavity, with the muscles and nerves. 1847.
Dr. O. W. Holmes.
- 609-10. Large wooden model of the cartilages of the larynx and trachea; and of the epiglottis. 1846.
Dr. O. W. Holmes.
611. Larynx and œsophagus; section and dried. 1847.
Dr. J. C. Warren.
612. The same, with trachea; dried. 1847.
Dr. J. C. Warren.
613. Larynx, trachea, and bronchi; dry. 1847. .
Dr. J. C. Warren.
614. Trachea and bronchi; in spirit. 1847.
Dr. J. C. Warren.
615. Casts, in plaster, of the interior of the larynx, ventricles, etc. 1851.
Dr. E. Leigh.
616. Absence of the left horn of the thyroid cartilage, and without any appearance of injury or disease, though there was, when recent, a considerable lateral distortion; dried. From an old man. 1862.
Mr. Eugene P. Robbins, med. student.
617. A second specimen; right horn wanting; in spirit. 1869.
618. A portion of the trachea and bronchi, showing the origin of a large additional bronchus from the primary bronchus upon the right side. 1867. *Dr. J. B. S. Jackson.*
619. Ossification of the cartilages of the larynx, in connection with the hyoid bone. 1847. *Dr. J. C. Warren.*

620. Thyroid and cricoid ossified. 1851.
Dr. J. B. S. Jackson.
621. Cartilages of larynx and trachea almost completely ossified. 1857.
Dr. J. B. S. Jackson.
622. Trachea ossified. 1851. *Dr. J. B. S. Jackson.*
623. Cricoid and part of trachea, ossified. 1847.
Dr. J. C. Warren.
624. Small portion of the trachea of a horse; in spirit. 1847.
Dr. J. C. Warren.
625. Trachea of a duck, showing the great development of the lower larynx; and
626. The same, from the peacock, showing, by contrast, the absence of this last. Both specimens show the ossification of the rings, which is normal in birds. 1862.
Dr. J. B. S. Jackson.
627. Humerus of a bird, prepared to show the internal cavity and the openings through which the air is admitted. 1866.
Dr. J. B. S. Jackson.
628. Respiratory system of an insect. (Neppa.) By Auzoux, of Paris. 1851.
Museum Fund.
629. Trachea, black; from a fowl. See No. 243. 1863.
Dr. W. E. Coale.

II. LUNGS, ETC.

630. Air-cells of the lung of a child; injected and dried. 1847.
Dr. J. C. Warren.
Lymphatics on surface of lung; injected with mercury.
See No. 416.
631. Lungs of a snapping-turtle (No. 179), inflated and dried. By Dr. H. 1855.
Dr. O. W. Holmes.
632. Lung of an iguana, with the arteries minutely injected, distended, dried, and preserved in turpentine. 1847.
Dr. J. C. Warren.

633. Lung of a frog, distended and dried. 1849.

A considerable portion of the lung of a black snake, in connection with the heart, etc. Inflated, dried, and cut open; showing the spongy appearance upon the internal surface. Externally, the left lung appears quite rudimentary; but internally there seems to be but one cavity. See No. 283.

The lungs of three African serpents; in spirit. Nos. 284-6.

That of 284 measured $5\frac{1}{2}$ ft. in length, but was torn in removal. That of 285 is cut open, and shows the cellular structure on the inner surface, anteriorly; the right ends bluntly at the gall bladder, seventeen inches from the liver, and the left has been cut away at the posterior extremity of the liver. That of 286 is preserved entire, for inflation, with the trachea.

SERIES XII.—ALIMENTARY CANAL.

I. OESOPHAGUS.

634. Minute injection. 1847. *Dr. J. C. Warren.*

From a large serpent; and enormous if distended. Nos. 284-6.

From a salmon. The large swimming-bladder can be inflated from it. No. 644 $\frac{1}{2}$.

II. STOMACH.

635. Adult; inflated and dried. 1868.

Dr. J. B. S. Jackson.

636. Fœtal; with the ileo-cœcal portion of intestine: 1851.

Dr. H. R. Storer.

637. Fœtal; minutely injected; distended in alcohol and cut open; in spirit. 1847.

Dr. J. C. Warren.

638. A second specimen; minutely injected by Dr. D. 1860.

Dr. S. Durkee.

639. Pyloric valve. The stomach and intestine having been

distended and dried, have been cut away to near the valve, which appears like a thin diaphragm, with a large central perforation. 1859. *Dr. J. B. S. Jackson.*

640. Stomachs of two foetal sheep; at an early period, and of different ages; distended and dried. By Dr. W. 1857. *Dr. J. Wyman.*

641. Model, by Auzoux, of Paris, of the stomach of a sheep; cavities shown. 1851. *Museum Fund.*

642. Stomach of a new-born calf; distended, dried, and cut open, to show the different cavities, and their connections. The relative size of the paunch, and the true digestive cavity, as compared with the adult, is well shown. 1860.

643. Gizzard of a bird, minutely injected, distended, cut open, and preserved in turpentine. The pro-ventriculus, with its glands, is also shown. 1847. *Dr. J. C. Warren.*

644. Stomach of an ostrich; in spirit. 1847. *Dr. J. C. Warren.*

Stomachs of three large serpents. See Nos. 284-6. 284 and 286 are entire, but 285 has been cut open, and shows a well-defined cardia and pylorus.

Stomach of the salmon; one entire, and one cut open. See No. 665.

645-6. Model, by Auzoux, of the stomach of a shark, and of a lobster. 1851. *Museum Fund.*

III. INTESTINE.

647. Portion of jejunum, distended and stiffened in alcohol; and then cut open to show the valvulae conniventes. 1859. *Dr. J. B. S. Jackson.*

648. Minute injection of small intestine. 1847. *Dr. J. C. Warren.*

649. The same; an adjoining portion being left in its natural condition. 1847. *Dr. J. C. Warren.*

650. The same ; dried and preserved in turpentine. 1847.
Dr. J. C. Warren.
651. The same ; fœtal. By Dr. D. 1860. *Dr. S. Durkee.*
652. Portion of small intestine, dried, and showing an unusual development of the follicles of Peyer's patches. From a case of malignant cholera.
One of the patches is elliptical, as usual, and very long. Two others are circular, and not more than three or four lines in diameter. In this last form they are occasionally found at the lower end of the ileum, and as often in any other part of the circumference of the intestine, as opposite to the mesentery. When these small patches exist, and are ulcerated in typhoid fever, the mistake might very readily be made of supposing that the ulcers were in the mucous membrane, and not in the patches, for want of a knowledge of the above fact. 1857. *Dr. E. Leigh.*
653. A portion of jejunum, inverted, and strongly inflated, so as to produce an artificial emphysema of the sub-mucous cellular membrane ; dry. 1859.
Dr. J. B. S. Jackson.
654. Portion of intestine, from an adult, and showing an unusual development of the meso-appendix ; inflated and dried. 1847.
Dr. J. C. Warren.
655. Preparation to show the ileo-cœcal valve. 1849.
Dr. J. B. S. Jackson.
656. Ileo-cœcal portion of intestine, distended and dried, and showing that the so-called appendix is in early life a mere continuation of the cœcum. Two specimens ; from a fœtus and a young child. 1849. *Dr. J. B. S. Jackson.*
657. Section, upon the median line, through the pelvis of a young child, and showing the relation of the organs ; in spirit, and not dissected. Rectum minutely injected. 1847.
Dr. J. C. Warren.
658. Ileo-cœcal portion of intestine of a domestic cat ; inflated and dried. 1860. *Dr. J. B. S. Jackson.*

659. The same ; from a leopard. 1862.
Boston Soc. of Natural History.
660. The same ; from a woodchuck (*Arctomys monax*), and showing the great development of the cæcum in the rodentia. By Mr. E. 1860.
Mr. R. T. Edes, med. student.
661. The same ; from an opossum. 1862.
662. The same ; from a calf. 1860.
Dr. J. B. S. Jackson.
663. Portion of the small intestine of an East Indian elephant ; distended and dried, with the mesenteric arteries injected. By Dr. Winslow Lewis. 1847. *Dr. J. C. Warren.*
664. Portion of the intestine of an ostrich from New Holland ; inflated and dried, by Mr. G. The immense cæcal appendages are shown, and the whole of the large intestine, which is very short. 1860.
Mr. Wm. B. Gibson, med. student.
- Intestine of three large serpents. See 284-6. Two are entire. No. 285 cut open, and shows a remarkably valvular-looking arrangement of the mucous membrane of both the small and large intestine. Cæcum $1\frac{1}{4}$ in. deep, and opening freely into the intestine, but so closely connected with it, that externally it would very readily be overlooked.
665. Intestine of the salmon. One entire, and can be partially inflated. The other cut open to show the openings of the appendices. Two specimens. 1860-1. *Museum Fund.*

IV. MALFORMATIONS.

- Stomach of a double calf. No. 898.
- 666-7. Diverticula. 1847. *Dr. J. C. Warren.*
668. The same ; $3\frac{1}{2}$ in. long, and about as large as the thumb ; 53 in. from cæcum, and at an angle of 45° with the ileum. From a man æt. thirty-four. 1858. *Dr. C. Ellis.*

669. The same; about 4 in. long; small at the origin, but enlarging towards the free extremity, and forming quite an acute angle with the ileum; 5 ft. above cæcum. Adult. 1858. *Mr. Asa P. Tenney, med. student.*
670. The same; about 2 in. long, rather small, of a conical form, and makes a very acute angle with the upper portion of the intestine; 5 ft. from cæcum. Female, æt. 20. 1858. *Dr. C. Ellis.*
671. The same; irregularly formed, and bulges towards the extremity; about 3 in. long, and 3 feet from cæcum. From a man, forty-seven years of age. 1859. *Dr. C. Ellis.*
672. Appendix cæci, $8\frac{1}{4}$ in. in length. 1856. *Mr. J. Henry Sanborn, med. student.*
673. Cæcum malformed; inflated, dried, and cut open. Externally, it appears quite small, and separated from the colon by a deep constriction. Internally, the communication between the two is seen to be not larger than the tip of the little finger, and close by the side of the ileo-cæcal opening. There is also a defined cavity, about the size of a marble, situated between the ileum and cæcum, and opening into this last, near the openings above referred to. Appendix normal. 1852.
674. A portion of the ileum, and about two inches of the large intestine, which last terminates in a cul de sac; well developed, so far as they exist, as well as the appendix. Connected with the cul-de-sac is a small portion of intestine, about $\frac{3}{4}$ in. in length, of the size of an adult appendix cæci, and closed at each extremity. And this constituted the whole of the large intestine.
From an infant that was operated upon by Dr. J. M. Warren, for imperforate anus. The stomach was found well, on dissection, and the small intestine 49 in. in length. 1847. *Dr. J. C. Warren.*
675. Congenital stricture at the anus. At birth a probe only could be passed, but it was afterward considerably dilated by mechanical means.

From a patient of Dr. S., that died at the age of eighteen months. A bristle marks the circumference of the orifice; and the intestine above is seen to be considerably dilated. 1858.

Dr. Joel Seaverns, of Jamaica Plain.

676. Imperforate anus. Case treated by Dr. Y. Operation with the trocar on the third day; canula left in for a week, and the opening then dilated with sponge. In six or eight weeks opening enlarged with the knife; and a tube, $\frac{3}{8}$ in. in diameter, having been introduced, was kept in for about a year. This was occasionally removed; and, once or twice, when it was obstructed, the fæces passed through the penis; this being first noticed when the child was about six months' old. Three or four months before its death, the parents removed the tube without Dr. Y.'s knowledge; the fæces soon beginning to pass through the penis, and continuing to do so ever afterward. For a time they passed also through the artificial anus, but for the last two months not at all. The child continued quite healthy, and died, at the age of eighteen months, from the effects of a fall a few days before.

On dissection, some liquid fæces were found in the rectum, and a quantity of foreign matter. The intestine itself was much enlarged, and moderately thickened; but, excepting a little excrescence a few inches above its termination, it was healthy. Opening between the rectum and the membranous portion of the urethra just in front of the verumontanum, direct, and about two lines in diameter. The bladder contained some liquid fæces, but was itself perfectly healthy. Through the opening made by Dr. Y., air could be forced before the parts were cut open, but the head of a very small pin would not pass. A piece of whalebone has been passed through the congenital opening, and the parts are fully displayed. Case quoted by Mr. Ashton, in his work on Dis. etc., of the Rectum, p. 64. 1850.

Dr. J. H. York.

For a statistical record of one hundred and four cases of "Anal and Intestinal Malformation," by Dr. Geo. H. Gay, see Boston Med. & Surg. Jour. Vol. LVII. p. 397.

In cases of imperforate anus, an opening into the "bladder" or "urethra" is occasionally reported; but, so far as I have seen, an opening into the membranous portion of the urethra is always found in an ordinary case of imperforate anus in the male subject. In extraordinary cases, or where there is great malformation of the internal organs, the opening may be into the fundus of the bladder, or there may be a great deficiency of the large intestine, and no opening at all. The opening is usually small, but easily enough demonstrated, if the rectum is inflated under water, after washing it out, and opening the bladder and urethra. The above general remark was made, and founded upon the observation of six cases, when the Catalogue of the Med. Society's Cabinet was published, in 1847; and several others have since been met with.

When the anus is imperforate in the female, the rectum opens into the vagina; and this opening seems to correspond to that in the male subject, — the membranous portion of the urethra being the genital portion of the urinary canal.

In an analysis, by Mr. Curling, of one hundred cases of "Congenital Imperfections of the Rectum," with reference to an operation (*Med. Chir. Trans.* Vol. XLIII. p. 276), he gives twenty-six, in which the intestine opened into the urethra, or neck of the bladder; and he remarks that there were "very probably more, as the opening is sometimes so minute as to prevent the free escape of meconium during life."

677. Imperforate anus in a pig, that appeared perfectly healthy, and was killed on the nineteenth day from birth. The rectum ends in a cul-de-sac; but between one and two inches from its extremity a short, dense, rounded cord connects it with the urethra at about the same distance from the bladder. The bladder and urethra having been cut open, this cord was found to be pervious, though air could not readily be forced through from the rectum. In spirit.

One of the other pigs, in the litter of eight or ten, had the anus imperforate, but the others were well formed. In a previous litter, the sow had borne a female, in which the

rectum and vagina had a common opening; this last being still alive when the above case was observed, and defecation being perfectly natural. 1850.

Dr. Waldo J. Burnett.

678. Imperforate rectum. The pelvic organs were dissected by Dr. R. M. Hodges, and have been preserved in spirit; showing the rectum, distended, and ending in a cul-de-sac, low in the pelvis, and below this a very small portion of intestine with the anus.

The child died on the sixth day, crying incessantly the last ten or twelve hours, and with the abdomen very tense and swollen; but there was no vomiting. The urine was very scanty; and two days before death it was slightly tinged by meconium, though nothing was found, on dissection, to explain this fact. Case in the practice of Dr. A., and no operation performed; a female child.

Three years previously the mother bore another male child that lived eight days, and in which the meconium passed freely through the penis; a perfect female having been born meanwhile. 1858. *Dr. James Ayer.*

679. Imperforate rectum; intestine distended and dried.

Case in Dr. M.'s practice; a female. Trocar passed in about two inches on the third day, but without opening the intestine, and it died on the fifth. Symptoms not urgent. The lower portion of the intestine was about an inch in extent, and the distance that separated the two portions was about the same. 1847. *Dr. E. B. Moore.*

680. A third specimen; in spirit. On the fourth day a trocar was thrust in, and meconium was freely discharged. The next morning a piece of gum-elastic catheter was passed up upon a probe; in the evening, as nothing had passed, the opening was enlarged with the knife, and a small quantity of meconium escaped. Death on the following day. On dissection, it was found that the probe and catheter had passed into the cellular tissue by the side of the intestine, and that there was an opening into the peritoneal cavity. 1869.

681. Rectum opening into the vagina. When the child was six weeks old, Dr. W. made an incision into the intestine, in the situation of the anus, drew it down, and stitched its margin to the integuments. The operation was perfectly successful; solid fæces passing through the artificial opening, and the liquid portion through the vagina. An operation for the closure of the opening into the vagina was deferred on account of the age of the child, and it died when about sixteen months old.

On dissection, a malposition of the large intestine was found; and a sharp flexure had produced an obstruction that sufficiently explained the death. The rectum having been cut open along the back, by Dr. W., there is seen an opening into the vagina that would admit the tip of the little finger; the intestine just above this being much contracted, and plaited upon the inner surface. The anal opening made by the operation seems to have been of good size. (Med. Jour. LXXI. 243.) *Dr. J. M. Warren.*

682. Rectum ends in a cul-de-sac; distended and dried. From a monstrosity (siren). 1869.

Dr. Hemenway, of Somerville.

683. Rectum and vagina opening by a common outlet; from a perfectly healthy lamb that was killed when five months old. Pelvic organs preserved in spirit, and fully displayed.

The rectum was considerably distended with fæces, and opened into the vagina between half an inch and an inch from the external orifice; the mucous membrane below, resembling that of the vagina rather than that of the rectum; and the clitoris being seen at the orifice, showing that the rectum opened into the vagina, and not v. v. 1850.

Mr. J. Nelson Borland, med. student.

684. Rectum of a calf, communicating with the lower part of the vagina by an opening that would have admitted a large catheter; both cavities, as well as the uterus, being in the recent state distended with meconium. The vulva was well developed, but separated from the vagina by a fleshy and moderately thick septum. The animal, which was

otherwise well formed, died on the third day, and was sent to Dr. B. 1860. *Dr. Henry J. Bigelow.*

SERIES XIII. — LIVER AND DUCTS.

685. A wax preparation of the organ, with the gall-bladder and ducts, lymphatics and blood-vessels. 1847.

Dr. J. C. Warren.

686. Liver of a mature fœtus, with diaphragm; dried. 1847.

Dr. J. C. Warren.

687. Entire absence of the liver, in a fœtus, $3\frac{1}{4}$ in. in length, and that was removed from the Fallopian tube; the woman dying, as usual in cases of tubular pregnancy, from copious hemorrhage into the peritoneal cavity. The umbilical vein entered the vena cava near the diaphragm; spleen very small; and otherwise the fœtus, which was entire when received with the uterus, was well formed. The contents of the small intestine, which, however, was not opened, had a very marked green color, to the extent of a line or more, but not in any other part; and the possibility of a vicarious secretion of bile was suggested. 1862.

Dr. E. P. Abbe, of New Bedford.

688. Organ very much fissured and lobulated; from Dr. ——— who died of phthisis. Undoubtedly congenital. 1855.

Dr. J. B. S. Jackson.

689. Cast, from a malformed fœtus (siren), showing a very irregular development of the left lobe. 1869.

Museum Fund.

690. A flattened portion of liver, about $\frac{3}{4}$ in. in diameter, and that was found in a fold of peritoneum, near the longitudinal fissure, and fairly separated from the main body of the organ. From an adult. 1860.

Dr. C. Ellis.

691. Spiral valve of the cystic duct; enough of which last has been cut away to show that it is not continuously spiral.

Dr. J. B. S. Jackson.

692. Bile ducts of a horse, with a small portion of duodenum. Injected by Dr. J. Wyman, to show the absence of a gall-bladder. 1847. *Dr. J. C. Warren.*

Organ from a large serpent. No. 284. Two and a half feet long, and the max. circumference $6\frac{1}{2}$ in. The gall-duct is thread-like; and the gall-bladder, which has been cut away, was thirty-five inches from the liver.

SERIES XIV. — URINARY ORGANS.

I. KIDNEYS.

693. Model of the healthy organ, by Thibert, of Paris. *Dr. John Ware.*

694. Fœtal organs, with renal capsules. 1847. *Dr. J. C. Warren.*

695. Section of a fœtal organ, minutely injected. 1847. *Dr. J. C. Warren.*

696. A left kidney, that was found lying on the iliac vessels; rather small, and of a somewhat flattened and circular form. A portion of the aorta is preserved with it, and shows the renal artery arising at its bifurcation into the iliacs. The vein was parallel to the artery. The right kidney was in its proper place. From an adult. 1858. *Dr. C. Ellis.*

697. A kidney, from a child that died of disease of the heart, and that is very remarkably and not very coarsely lobulated. 1854. *Dr. J. B. S. Jackson.*

Kidneys of three large serpents. Nos. 284-6. Those of the first are respectively $9\frac{3}{4}$ and $9\frac{1}{4}$ in. long; and $35\frac{1}{2}$ and 28 in. from the opening of the ureters into the cloaca.

II. BLADDER.

698. Pelvic organs of the male, distended and dried. 1847. *Dr. J. C. Warren.*

699. Bladder removed from the pelvis, distended and dried. From a male child. 1847. *Dr. J. C. Warren.*
Section through the pelvic organs of a female child; wet specimen. No. 657.
700. Bladder of a female domestic cat, distended and dried, to show the length of the urethra. 1860.
Dr. J. B. S. Jackson.
The same. From a leopard; in spirit. No. 755.
701. The same. From an East-Indian elephant; distended and dried, with the penis. Prepared by Dr. W. Lewis. 1847.
Dr. J. C. Warren.

III. MALFORMATIONS.

702. A kidney that was found lying along the edge of the left psoas muscle, and resting upon the promontory and hollow of the sacrum. The iliac arteries are shown; and the sacro median, with two small arteries, are seen entering the organ. The weight of the organ was $3\frac{3}{4}$ oz.; and that of the other, $8\frac{1}{4}$ oz. From a sailor, who died of phthisis; with a greatly enlarged liver, and an abscess in the organ that opened into the peritoneal cavity. 1868.
Dr. J. W. Graves, of Chelsea.
703. Absence of one kidney. The other organ is shown, with a portion of the bladder, and the opening into it of but one ureter. The two renal capsules are also shown. 1867.
Dr. J. B. S. Jackson.
704. Lower half of the two organs, intimately fused. Adult. 1848.
Dr. W. Lewis.
705. Two ureters, to the extent of about five inches from the kidney. Injected, in 1854, by Dr. R. M. Hodges, and dried. 1847.
Dr. J. C. Warren.
706. A portion of the bladder, that had been distended and dried, and showing two ureters upon each side. Upon one side they unite just before they enter the bladder, and upon the other they have separate openings. The division

began at the kidneys; and, having been cut away from these organs, the canals have been inflated. 1856.

Mr. J. H. Sanborn, med. student.

IV. PRODUCTS OF SECRETION.

707-10. Urea, artificially prepared. Uric acid and urate of ammonia; prepared from the urine of a serpent; and hippuric acid from that of a horse. By Prof. C. 1852.

Prof. Josiah P. Cooke.

711. Urine of a very large African serpent, solidified. Examined chemically, and by the microscope, by Dr. White, and found to consist of about 95 per cent. of uric acid, and 5 per cent. of urate of potassa. 1856. *Museum Fund.*

SERIES XV. — MALE GENITAL ORGANS.

712. Testicle, vas def. and cord. 1847. *Dr. J. C. Warren.*

713. Testicle, showing the tubuli sem. 1847.

Dr. J. C. Warren.

714. Epididymis, injected with mercury, by Dr. B. 1855.

Dr. Wm. D. Buck, of Manchester, N. H.

715. Vas deferens injected with mercury. 1847.

Dr. J. C. Warren.

716. Testicle of a rat; tubuli unravelled. 1847.

Dr. J. C. Warren.

Testes and vasa def. in the serpent. Nos. 285-6.

717-18. Spermatic vessel of a ram, and of a horse. 1847.

Dr. J. C. Warren.

719. Vesiculæ sem., with a portion of the bladder; dried. 1847.

Dr. J. C. Warren.

720. External organs, with the testicle. A wax preparation. 1847.

Dr. J. C. Warren.

721. Penis of a new-born infant, showing phimosis, and which

I believe to be a normal condition. — More than thirty years ago I attended an operation upon an infant, by a distinguished surgeon. The end of the prepuce was removed; and then, as it could not be retracted, a long and ineffectual attempt was made to dissect it from the glans. In relation to this case, I subsequently examined a great many subjects, and have never yet seen one in which the prepuce could be retracted, so as to expose the glans to the extent of more than one or two lines. Further, the prepuce has generally, if not always, been adherent to the glans, if the subject was a fresh one; the adhesion being much more than a mere gluing together of the surfaces, though it could be easily enough separated by a pointed probe. The above conditions remain for some time after birth, but at what period they cease, I have not ascertained. It is remarkable that paraphymosis sometimes exists, it is said, at birth. (Med. Jour. Vol. LXII. p. 325; and Vol. LXV. p. 121.) 1867. *Dr. J. B. S. Jackson.*

722. Penis; inflated, dried, and cut across to show the corpus cavernosum. The corpus spongiosum is also shown, and its continuation with the glans, which last has been cut away upon its upper surface. 1847. *Dr. J. C. Warren.*

723. A similar preparation, with a longitudinal incision, showing the spongy structure of the body of the organ, and the glans; with the septum between them. 1847.

Dr. J. C. Warren.

724. Penis; injected by Dr. H. From a middle-aged, tall, and athletic negro pugilist. Glans imperfectly filled; but, as it is, it measures from the posterior extremity of the corpus spongiosum, to the glans, $11\frac{1}{3}$ in.; in circumference, at the largest part, $4\frac{7}{8}$ in., and it displaces $\approx 10\frac{1}{2}$ of water. Before removal from the body, the organ appeared no larger than the average. 1859. *Dr. R. M. Hodges.*

725. A second specimen; injected by Dr. H. This was also from a negro, and it measures, in length, $10\frac{3}{4}$ in., and in circumference, $5\frac{1}{4}$ in.; displacing ≈ 8 of water. 1847.

Dr. O. W. Holmes.

- 726-8. Other specimens, of about the usual size, when injected :
 1st. $9\frac{1}{4}$ in. ; $4\frac{1}{4}$ in. ; $\frac{2}{3}$ $6\frac{1}{2}$. 2d. $9\frac{1}{8}$; $4\frac{1}{2}$; $\frac{2}{3}$ $5\frac{1}{2}$. 3d. $6\frac{5}{8}$;
 $3\frac{5}{8}$; $\frac{2}{3}$ $2\frac{1}{2}$. 1847. *Dr. J. C. Warren.*
729. Penis of a negro ; in spirit ; showing the frænum, which is
 sometimes wanting. (Catalogue of the Cabinet of the
 Soc. for Med. Improvement, No. 703.) 1861.
Dr. J. B. S. Jackson.
730. Bone from the penis of a dog. 1865.
Dr. J. B. S. Jackson.
731. The same ; from a raccoon. 1853.
Dr. O. W. Holmes.
732. Hypospadias, from an adult. The urethra opens just be-
 hind the glans. 1850. *Dr. F. S. Ainsworth.*
733. Cast, in plaster, of a second case, from a child two years
 old, and whose brother had fissure of the palate. There
 was an external appearance, as of fissure of the scrotum ;
 and at the upper part the glans penis, with its prepuce,
 was half concealed, and drawn downward, so that the
 urine trickled over the parts below ; the corpora cavernosa
 being very slightly developed. The testicles were in
 place. An operation for its relief was performed by Dr.
 Cabot, at the hospital (136, 12 ; and Med. Jour. April 2,
 1868), but the child died from the effects. On dissection,
 the parts were well formed, excepting the penis. 1868.
Museum Fund.
734. Organs of a malformed fœtus. The penis, as seen exter-
 nally, consists only of a glans with its prepuce ; but just
 below this the urethra opens freely. Of the scrotum there
 is not a trace ; nor of an anus. The bladder is seen to be
 fully developed ; and the rectum opens freely into the
 membranous portion of the urethra. In the preparation,
 the intestine is distended, and both openings are indicated
 by rods. 1810.
Dr. N. S. Chamberlain, of Marlboro'.
- 735-6. Casts, in plaster, of the developed breasts, and the un-

developed genital organs of a young Irishman, who had been in the U. S. naval service. The breasts resembled those of a virgin female, and the penis measured only $1\frac{1}{2}$ in. in length, and $\frac{5}{8}$ in. in diameter. An opportunity having been procured, by the kindness of Dr. Brinkerhoff, Surgeon, U. S. N., to examine this individual, the following observations were made: Skin delicate as an infant's; contour of limbs remarkably feminine; no trace of beard; some hair upon the pubes. Glans penis feels rather large, and can be about one-half uncovered by retraction of the prepuce, when this last is arrested as if by an adhesion to the organ; urethra quite normal, and he can pass a full stream of water; scrotum very imperfectly developed; one testicle very indistinctly felt, upon the left side, and toward the ring. The individual states that the penis is capable of erection, but that he has scarcely ever had any sexual feeling, and that he has never had connection with a female; that he had never polluted himself, nor ever had a seminal discharge. 1864. *Museum Fund.*

737. Photograph of the above individual; taken for Dr. Charles Martin, and sent to Dr. B. 1862.

Dr. H. J. Bigelow.

738. Cast, in plaster, showing a great deficiency in the external genital organs, from a man twenty years of age, and who entered the City Hospital, under the care of Dr. C., with an abdominal tumor, of four months' duration. He had very little beard, but his general appearance and voice were those of a man. Sexually, nothing remarkable.

The left half of the scrotum is entirely wanting; the right half containing a body about twice as large as the testicle, and partially divided so as to feel like a testis and epididymis. The penis was very short, with an imperfect prepuce, and resembled an enlarged clitoris; the meatus urin. being at the root of the organ. Hair upon the pubes sufficient. See next specimen.

Dr. Algernon Coolidge.

739. Cast of the front of the chest, from the above case, and showing a very marked but conical enlargement of the

breasts. Upon each side there was a marked though faint areola; with a few developed papillæ. 1866.

Dr. A. Coolidge.

740. Cast of a male breast, colored; 3 in. \times 2½ in., and about ½ in. thick in the centre. Showed microscopically, as examined by Dr. Bigelow, an abundance of fat and fibrous tissue, with some tendency to gland formation. There were two well-defined mammary glands, with a distinct nipple and areola. Testicles very small; and there was less hair than usual on the pubes. The man was twenty-one years of age, and died at the hospital. (259, 96.) 1864.

Museum Fund.

SERIES XVI. — FEMALE GENITAL ORGANS.

741. Ovary cut open, to show a spurious corpus luteum; a defined, rounded cyst, just below the surface of the organ, that was filled with coagulated blood. From a woman, who died of complicated organic disease, but of whose catamenial history nothing was known. 1860.

Dr. C. Ellis.

742. Organs, preserved in spirit. 1861.

Dr. O. W. Holmes.

743. Dry preparation of the pelvic organs, with the pelvis upon one side. 1847.

Dr. J. C. Warren.

Section of the pelvic organs of a child. No. 657.

744. Uterus of a child, minutely injected, and cut open; showing by the arbor vitæ, how, at an early age, it consists entirely of the cervix. The uniformly smooth surface of the ovaries at an early age is also shown. 1847.

Dr. J. C. Warren.

745. Three virgin uteri; all from young subjects, and who had probably been menstruating but a short time. 1855.

Dr. J. B. S. Jackson.

746. Uterus to contrast with the last; the ovaries being cicatrized by frequent menstruation. This also was probably from a virgin. The right ovarian ligament is short; and, in the recent state, there was a marked lateral obliquity of the uterus. 1861. *Dr. J. B. S. Jackson.*

747. External organs. Wax preparation. From Paris. 1847. *Dr. J. C. Warren.*

748. External organs; in spirit. 1849. *Dr. O. W. Holmes.*

749. Cast, in plaster, of the vulva, etc., of an adult. 1851. *Dr. E. Leigh.*

750. External organs, showing a well-marked hymen, from a girl æt. nineteen years; in spirit. 1861. *Dr. C. Ellis.*

751. Bifid uterus, and double vagina.

From a woman fifty-seven years of age, who had had three children; the labors being always severe. Catamenia ceased at the age of forty. Nothing known of the malformation until the woman's death, unless to herself; not even to her husband.

The uterus is hardly larger than the normal organ. The two cornua are symmetrical, about the size of the forefinger, and $1\frac{1}{2}$ in. in length; terminating in the Fallopian tubes, which, with the two ovaries, are normal. Cavity of the cervix single. The vagina is divided, throughout, by a longitudinal septum, into two cavities of about equal size; there being an opening, however, from the upper extremity upon the right side through into the os or the cervix upon the left side. A small os uteri is seen upon each side. 1865. *Dr. A. B. Hoyt, of N. H.*

752-4. Two oil-paintings, by Mr. P., showing the external and internal appearances of a uterus, the cavity of which was equally divided by a septum that extended from the fundus to the os. No appearance of division externally.

From a girl, about twenty-five years old. Pencil draw-

ings of the same, by Mr. P., and showing: 1st, the external appearances of the organ, and its appendages; 2dly, the double os, with a portion of the vagina, upon the inner surface of which last were some traces of a longitudinal septum; 3dly, the uterus cut open. 1862.

Mr. Edgar Porter, med. student.

Rectum opening into the vagina. No. 684.

755. Genital organs and bladder of a leopard. 1862.

Boston Soc. of Nat. History.

Ovaries and oviducts of a large serpent. No. 284.

756. Photograph of a child who was born in the State of Ohio, of German parents, July 27th, 1865. At the age of one year and eleven months menstruation commenced, and has continued regularly since; and about the same time the breasts and hips began to enlarge. During the last year she has been in this city, on a visit, and was seen by many of the medical profession; Dr. Gay having seen the menstrual fluid as it was being discharged. There is hair over the pubes, and in the axillæ. One of the breasts is shown in the photograph, and is seen to be quite large; and the hips, which measure $27\frac{1}{2}$ in. in circumference, are so large as to amount almost to a deformity. Her general health is perfect. The first set of teeth is complete, but none of them have begun to loosen. Her manners and tastes are those of a child of her age; and she has never, so far as her mother is aware, shown any sexual feeling. The photograph was taken when she was two years and eight months old. An account of her case, which, however, has not been seen here, was published by Dr. John King, in the Medical Journal at Cincinnati, in 1868. 1869.

Dr. Benj. E. Cotting.

SERIES XVII. — UTERO-GESTATION.

I. PARTS CONCERNING THE MOTHER:

757. Corpus luteum; eighth month. 1860. *Dr. C. Ellis.*

758. Corpora lutea. 1861. *Dr. J. B. S. Jackson.*

- 758½. The same, from the cow. 1861. *Dr. J. B. S. Jackson.*
759. Gravid uterus; about the third month. A wax preparation. External organs also shown. 1847.
Dr. J. C. Warren.
760. Uterus, with placenta attached; last month of pregnancy. 1861.
- 760½. The same, with the fœtus; about the seventh month. 1861.
761. The same; three to four months. Neck quite undeveloped. The fœtus was plump, and rather larger than the forefinger; and the uterus rose nearly to the brim of the pelvis. The decidua appeared, in the recent state, as if somewhat tubercular; the patient having had obstinate vomiting, from the time of conception, but finally dying from something intermediate between pneumonia and tubercular disease of the lungs. 1861.
Dr. J. B. S. Jackson.
- 761½. Uncontracted uterus, from a woman who died of hemorrhage, 1½ hours after labor, at the full period. 1855.
Dr. Ezra Palmer.
762. Decidua vera, remarkably entire, and inverted so as to show the comparatively smooth free surface. For the ovum, see No. 771. 1857. *Dr. John P. Reynolds.*
763. A second specimen, 3 in. in length, and still more complete. The shape is that of the fundus and body of an enlarged uterus. Outer surface rough, as usual, and the inner comparatively smooth. At the fundus, but rather on one side, is seen an ovum, that must have been about as large as an English walnut, and which has been opened by a crucial incision; parietes thin, as if blighted, and invested by the decidua reflexa; there being no appearance of the villousities of the chorion, embryo or cord. The mass came away with much hemorrhage, but without the woman's knowledge, and recovery was rapid. She considered herself as two or two and one-half months pregnant; and had already aborted once within a year. 1862.
Dr. John G. Blake.

764. Ovum to show the decidua reflexa, entire. Last menstruation ended March 11th; abortion, May 24th. 1861.

Dr. D. H. Storer.

765. Uterus of a sheep, about the middle period of pregnancy.
 • Both horns cut open, and there are cotyledons, with membranes in each; but there was only one fœtus, and this is shown. 1860.

Dr. D. H. Storer.

766. Portion of the uterus of a sheep, showing the cotyledons.
 • 1861.

Dr. J. Wyman.

766½. A portion of the uterus of a cow, near the full period of gestation, and showing a cotyledon. 1858.

Dr. J. Wyman.

767. Symphysis pubis relaxed during labor. It was cut through
 • in the recent state, and showed no other change than simple relaxation.

I have met with this several times; and not merely at the full period of pregnancy, but as early as at the sixth month. The degree of relaxation, however, has varied much, even at the same period. See Catalogue of the Med. Soc.'s Cabinet, No. 722. 1868.

Dr. J. B. S. Jackson.

768. Pelvis of a cat that was killed when in labor at the full period, and in which the symphysis pubis was not at all relaxed. Prepared by Mr. J. Homans. 1860.

Dr. J. B. S. Jackson.

II. PRODUCT OF CONCEPTION.

769. Ovum entire; about the third week, by estimate. 1862.

770. Several fœtuses; ages, six or eight weeks.

771. Ovum entire, and the chorion more or less villous over the whole surface. Embryo, so far as seen, about an inch in length. Last menstruation, middle of July; morning sickness began the second week in August, and abortion took place October 7th. For the decidua vera, see No. 762. 1857.

Dr. J. P. Reynolds.

772. Fœtus, with the membranes ; ten weeks. 1857.

Dr. D. H. Storer.

773. Fœtus, just eleven weeks from the last menstruation.
Length, $3\frac{3}{4}$ in., and spine, $1\frac{1}{2}$ in. Weight, 246 grs. 1860.

Dr. D. H. Storer.

774. Thirteen fœtuses, from about two and one-half to three
and one-half months old.

In the few observations that are given here of the size of fœtuses, in relation to their probable age, those subjects only were taken that seemed to have been in a healthy condition up to the period of abortion, and in which the catamenial function in the mother was generally healthy. Exceptions, when they occur, will appear. The length is taken from the vertex to the soles of the feet ; the lower extremities being straightened.

775. Fœtus, $4\frac{3}{4}$ in. long, and spine, $2\frac{1}{2}$ in. ; weight, $1\frac{1}{4}$ oz.

Last menstruation, Nov. 15th, and abortion on the 16th of the next February. 1861.

Dr. James Ayer.

776. Fœtus in the amnion, and without the placenta. About three months. 1859.

Dr. D. H. Storer.

777. Fœtus, $6\frac{3}{8}$ in. long, and spine, $3\frac{3}{4}$ in. ; weight, 3 oz. Menstruation ceased Sept. 13th ; recurred slightly Nov. 10th, and abortion took place Dec. 23d. 1860.

Dr. S. A. Carpenter, of N. Attleborough.

778. Fœtus, $8\frac{1}{2}$ in. long, and from vertex to umbilicus, $4\frac{1}{2}$ in. ; spine, $3\frac{3}{8}$ in. ; weight, $8\frac{3}{4}$ oz. Last menstruation ceased February 4th, and the fœtus was received quite fresh, June 7th. 1861.

Dr. Thaddeus Phelps, of N. Attleborough.

779. Twenty fœtuses ; ages from about $3\frac{1}{2}$ to $6\frac{1}{2}$ months.

780. Fœtus, $9\frac{1}{4}$ in. long ; spine, $4\frac{1}{2}$ in. ; weight, 10 oz. Last menstruation on the last of August ; slight show in the middle of September, and abortion December 23d, without much threatening. 1863.

Dr. Charles G. Putnam.

781. Fœtus, $7\frac{1}{2}$ in. long ; spine, $3\frac{3}{8}$ in. ; weight, 7 oz. Last

menstruation November 8th. Abortion in March, after a threatening of two weeks. Four days after the abortion a second fœtus was expelled, perfectly offensive. 1862.

Dr. H. J. Bigelow.

782. Fœtus; about four months, by estimate. Spine, $6\frac{3}{4}$ in., and from vertex to soles of feet, $13\frac{3}{4}$ in.; weight, 1 lb. $13\frac{1}{2}$ oz. 1855.

Dr. C. G. Putnam.

783. Fœtus, $7\frac{1}{4}$ in. long; spine, $3\frac{5}{8}$ in.; weight, $4\frac{1}{2}$ oz. Last menstruation began December 4th. Abortion, April 11th, 1863.

Dr. C. G. Putnam.

784. Fœtus, $8\frac{1}{2}$ in. long; spine, $4\frac{1}{3}$ in.; weight, 6 oz. An unmarried woman. Last menstruation from July 26th, to the 30th. August 10th, sexual connection. Abortion, Dec. 8th. 1863.

Dr. George S. Jones.

785. Fœtus, 8 in. long; spine, $4\frac{1}{4}$ in.; weight, $6\frac{1}{2}$ oz. Last menstruation, August 7th to 10th, and the woman supposed that she conceived immediately afterward. Abortion, January 1st; fœtal motions first felt seven days previously, and forty-two days previously she had a considerable discharge of blood. 1863.

Mr. Elisha H. Quimby, med. student.

786. Fœtus, $12\frac{1}{2}$ in.; spine, 6 in.; weight, 1 lb. 6 oz. Last menstruation January 17th to the 24th. Abortion, June 16th, with suspicion of its having been procured. Extroversion of the bladder, and the pubic bones widely separated. 1861.

Dr. T. Phelps, of N. Attleborough.

787. Fœtus, $12\frac{3}{4}$ in. long, and weighs 1 lb. $8\frac{1}{2}$ oz. From a lady, who was married Sept. 29th, just after menstruation had ceased; and she aborted, from over-exertion, in March. 1864.

Dr. S. L. Abbot.

788. A fœtus, 203 days old. It weighed 3 lbs. $5\frac{1}{2}$ oz.; measured $16\frac{3}{4}$ in. in length, and though not very plump, was fairly developed, and lived twenty-four hours. The mother was a respectable and perfectly reliable woman, and the statement was that her husband was at home just two

- hundred and three days before the child was born, and not for three months afterward, nor for about two months before that day. 1867. *Mr. Geo. S. Cowdrey, med. student.*
789. Fœtus; with the membranes partially cut open. About the fourth month. 1847. *Dr. J. C. Warren.*
790. Placenta, with a portion of the cord. Injected by Dr. H. 1857. *Dr. R. M. Hodges.*
791. Placenta, from a case of twins. In spirit.
- 792-3. The same. In spirit. 1858. *Dr. D. H. Storer.*
794. The same. Injected by Dr. Hodges. 1858. *Dr. D. H. Storer.*
795. The same. Case of triplets. Weight, 1 lb. 9 oz. 1862. *Dr. J. C. Dorr, of Medford.*
796. The same; in spirit. One of the masses is separate, but the two others are united. 1858. *Dr. D. H. Storer.*
797. A battle-door placenta, injected by Dr. Hodges. 1858. *Dr. D. H. Storer.*
798. A placenta, consisting of two entirely separate masses; more than an inch apart, and connected by large vessels; one is about one-third larger than the other. Labor natural. Injected by Dr. Hodges. 1859. *Dr. D. H. Storer.*
- 799-800. Placenta, in case of twins, and of triplets; colored casts. 1868. *Museum Fund.*
801. A blighted and diseased ovum, containing two fœtuses, about as large as at the tenth or eleventh week; there being but a single umbilical cord, which bifurcates as it approaches the fœtuses. Menstruation irregular, so that the period of pregnancy was undecided. 1856. *Dr. J. B. Alley.*
802. A portion of the umbilical cord, showing very marked lateral projections of the vessels, like diverticula; a thin

membrane only connecting them with the rest of the cord.
1862. *Dr. D. H. Storer.*

803. Fœtal kitten, with the zonular placenta. 1847.

Dr. J. C. Warren.

804-6. Fœtal sheep; early months. 1854. *Dr. J. Wyman.*

807. The same, enclosed in the amnion. 1856.

Dr. J. Wyman.

808. Membranes of a sheep; early months of gestation.
Cotyledons injected by Dr. W. 1854. *Dr. J. Wyman.*

809. Portion of the membrane of a calf, to show a cotyledon.
1858. *Dr. J. Wyman.*

810. Fœtal cotyledon, from a cow; a very fully and minutely
injected specimen. 1867. *Dr. J. C. Warren.*

811. A fœtal dog-fish, with the yolk-sac attached. 1849.

Dr. J. C. Warren.

812. A female Surinam Toad, showing the development of the
ova in the skin of the back.

See Dr. J. Wyman's paper upon the subject in the Amer. Jour. of Science, for May, 1854. "The eggs," he says, "are transferred by the male to the back of the female, to which they adhere, and where they are impregnated; their presence excites increased activity in the skin; its thickness is gradually built up around each egg, which it at length nearly encloses in a small defined pouch." In the preparation, a section has been made through into the cavity that exists beneath the skin of the back; thus exposing many of the egg-sacs, most of which have been emptied, though in some of them the remains of the embryo, or of the yolk, are still seen.

813. A second specimen, with the abdomen laid open, and showing the ovaries filled with eggs. But, as they have not been discharged, the skin of the back, which has been cut through, has not undergone any change. These two

specimens were amongst the eight upon which Dr. W. made his observations. 1854.

Dr. F. W. Cragin, U. S. Consul at Surinam.

814. A male and female obstetric toad, with some of the eggs. Common about Paris. Cuvier says: "The male assists the female in getting rid of her eggs, and attaches them on the two thighs, by means of some threads of a glutinous matter. He continues to carry them until the eyes of the tadpole become apparent," etc. 1862.

Dr. J. Wyman.

SERIES XVIII.—MONSTROSITIES, WITH MALFORMATIONS NOT ELSEWHERE INCLUDED.

I. BY DEFICIENCY.

Several varieties of Monstrosities by Deficiency are figured, as well as described from a large number of specimens, in the Catalogue of the Museum of the Boston Soc. for Med. Improvement.

- 815-16. Photograph of "Tom Thumb" and his wife; with their attendant, by way of comparison; and "Commodore Nutt." A second photograph of "Commodore Nutt" and Minnie Warren, the sister of "Tom Thumb's" wife. The exact age, height, and weight of these well-known dwarfs have not been ascertained. 1864. *Museum Fund.*

817. A malformed fœtus, entire, in spirit (acephalus of St. Hilaire, — Anomalies de l'Organization).

A twin, as usual in such cases; and born about the fifth month. Weight, $9\frac{1}{4}$ oz. Upper portion large, rounded, and œdematous. In each of the three specimens in the Med. Society's Cabinet, the œdema was very marked; and yet this character is not alluded to by St. H. The head is represented by a fleshy mass, about the size of an Eng. walnut, very flaccid, and covered by an exceedingly delicate integument; also, and not far from it, three or four firm,

fleshy masses, about the size of a pea. Extremities fully, but irregularly developed. Two fingers on left hand partially fused. Lower extremities in a cross-legged position, with varus upon each side, and a deficiency of toes. 1865.

Dr. Francis Minot.

818. Cast, in plaster, of the head and chest of a fœtus (Nosen-cephalus of St. H.) ; taken by an Italian, and colored by a German artist.

The case occurred in the practice of Dr. Walsh, who stated that the labor was rather premature, the quantity of liquor amnii large, and that the child lived about thirty-six hours ; having been born on Tuesday, at 11 P. M. The mother refused to nurse it ; but it sucked the finger, and took, during the first eighteen hours, about two ounces of milk and water, swallowing well. Pulse distinct ; warmth sufficient, and there was a discharge of urine and fœces. Convulsions began on Wednesday, at 6 P. M., and continued till death, which occurred on Thursday, at 10 P. M.

The weight of the fœtus was 7 lbs. The vault of the cranium and the integument being wanting, there rested upon the base a deep red, purplish tumor, of a flattened, spherical form, with lobulated edges, and measuring $2 \times 2\frac{1}{2}$ in. and 1 in. in thickness ; during life it was, of course, larger. The extension of the cuticle, as usual, for some distance over the mass, and beyond the limits of the cutis is finely shown on the cast. On dissection, it consisted of a coarse, fibro-cellular, and vascular tissue, but without a trace of brain, though some of the nerves were found. Otherwise, the fœtus was well-formed externally ; and internally, except that the renal capsules were very small, as usual in the "acephalous fœtus." See next specimen. 1859.

Museum Fund.

819. Cranium of the above fœtus. The parietal bones are entirely wanting, and leave in this region a large and rounded opening upward. Posterior portion of the occiput continued across from side to side, and in a single piece, but with some appearance of a division upon the median line. 1859.

Dr. Walter M. Walsh.

820. A second cranium, in which the posterior portion of the occiput extends from side to side, and is formed of two pieces that are closely connected inferiorly, but not superiorly; the upper edge being about on a level with the base of the skull. The frontal bones are very deficient, but send a prolongation backward, which, upon the left side reaches the occiput. Upon the right side there is between it and this last, a small, irregular bone, which is the only representative of a parietal. The spine was well-formed.

The case occurred in the practice of Dr. M., who reported that the mother was married in October, 1858; that she always menstruated regularly, twice after her marriage, and for the last time on the 9th of December; that motions were first felt, indistinctly, in May, and that the child was born on the 7th of November, or eleven months, less two days, from the last catamenial period. The ear presented.

The foetus weighed $7\frac{1}{4}$ lbs.; and, from its long limbs, and robust appearance, low forehead, and swollen eyes and face, it suggested strongly the idea of an English prize-fighter after a battle; and, again, the broad and flat ears, standing directly off from the head, as they would not if the malformation extended to the neck, suggested the idea, as seen from behind, of a Chimpanzee. Upon the base of the skull there was a considerable quantity of cellulovascular tissue, but no trace of brain. The pituitary body was found as usual. The spinal marrow bulged at the upper extremity, and about where the pons varolii would have commenced; and from this part, and below it, several nerves arose. 1865. *Dr. E. D. Miller, of Dorchester.*

St. Hilaire states (*Anom. de l'Organisation*, Vol. II. p. 339), that his father and M. Serres once found the pituitary gland in a pseudencephalus, which is one form of the "acephalous foetus;" but in his description of the anencephalus, which is another form of the same, he makes no allusion to it. On the other hand, I found it many years ago, as I presume that others have; and from the time that I saw St. H.'s remark, I have never failed to find it, and in numerous cases, when I have looked for it.

821. Fœtus, entire; in spirit. Spine open throughout, as well as the vault of the cranium; but upon the base of this last there appears to be a considerable portion of brain. Varus of both feet. 1847. *Dr. J. C. Warren.*

822. A second specimen, very similar to the last, but without the appearance of brain; the malformation, also, extends no further than the upper part of the neck. Sex, female. This form of monstrosity is fully described in the Catalogue of the Med. Society's Cabinet (p. 247). 1847.

Dr. J. C. Warren.

822½. A third specimen, similar to the last, and that, having been for a time preserved entire in spirit, was afterward removed and dried; and now strikingly resembles one that is figured by St. Hilaire (*Anom. de l'Org.*), and that was found in the Egyptian catacombs. 1868.

Dr. J. B. S. Jackson.

A very similar malformation is shown in a "Double-headed" Duck, No. 900.

823. A fourth specimen, preserved entire. The cranial and spinal cavities are open as far as the sacrum. Brain wanting; but, in the recent state, there were appearances of spinal marrow in the form of two flat and very thin bands, about two lines in width, and lying side by side, if they were not fused; toward the upper part these bands were thicker, and quite distinct. Spinal nerves not exposed. Upon the base of the skull there was a considerable quantity of cellulo-vascular tissue, but nothing that could be called a tumor. There was no neck; the ears were doubled down, with a narrow margin of hair about the base of the skull, as usual, and the eyes were prominent and turned upward, so as to give it the characteristic appearance of a large bull-frog. Labor was premature, judging from the size of the fœtus, which presented by the feet, and was still-born. Quantity of liquor amnii very profuse, as it usually is, more or less. The mother had previously had three well-formed children; and never felt the motions of this last. 1853.

Dr. Wm. E. Townsend.

824. A fifth specimen, preserved entire. Age about three and one-half months. The brain and spinal marrow are deficient; with hare-lip; an extroversion of the abdominal organs, and much lateral distortion of the trunk. 1847.

Dr. J. C. Warren.

825. Separated cranial bones, with the cervical vertebræ; from a fœtus similar to No. 822. For a description of the osteology in this form of monstrosity, see the Med. Soc.'s Catalogue, p. 248. The upper maxillaries are co-ossified; and the large wings of the sphenoid are united to the body of the bone.

In the dissection of this case, some small cellulo-vascular tumors were found about the base of the skull, but no brain. Pituitary body distinct. Spinal marrow terminated in the membranes. Otherwise well-formed externally; and so internally, excepting a very strongly marked fissure of the uvula, and the extremely small renal capsules.

The mother was a respectable woman, and had had other and well-formed children. Early in her pregnancy she was much frightened by a serpent, and often expressed an anxiety as to the effect upon her child; and, as soon as it was born, asked her physician if all was right. Motions had been very active. Labor occurred at seven or seven and one-half months; the back and shoulder presented, and the quantity of liquor amnii was prodigious. Sex, male. 1849.

Dr. J. B. S. Jackson.

826. Separated bones of the head of an acephalous fœtus. There are two parietals, which is very unusual in this variety of monstrosity, but they are very thin and delicate; the right is $1\frac{3}{4}$ in. in length, and $1\frac{1}{2}$ to 3 lines in diameter; the left is smaller. The two halves of the lower maxillary bone are fused; and this is exceedingly rare, so far as I have seen. There is fusion, also, of the two upper maxillaries; of the body and wings of the sphenoid bone upon the left side; and of all the parts of each temporal bone.

The posterior portion of the occiput is divided and formed as usual in these cases, excepting the narrow pro-

longation that bounds the base of the skull ; and this last is very short.

The subject was a male, $18\frac{1}{4}$ in. in length, and weighing 5 lbs. $4\frac{1}{2}$ oz. No trace of brain was found ; and the head was as usual in such cases. Penis rather deficient. Otherwise, well-formed externally ; and so internally, excepting the very small size of the renal capsules. Motions of the child very active and powerful during the last two months of pregnancy, the period of which was about nine months. Fœtus sent, April, 1868, by

Dr. Geo. Vining, of Pittsfield.

827. Cranium, prepared from a case in which the spine was open to the fifth cervical vertebra. Mother married eleven years, and never before pregnant. Labor at seven and one-half months. Liquor amnii profuse. Head presented. A female, and gasped after birth. 1861.

Dr. A. P. Richardson.

828. Cranium and spine from another case, in which the fissure extends to the sixth dorsal vertebra. The laminae of the cervical vertebræ are imperfectly developed, and co-ossified into two masses upon each side. The bodies of the same are very irregularly placed, and there are one or two more than usual ; one, that connects with the three last laminae, upon the right side, and with that of the first dorsal, being not above the body that connects with the two first dorsal laminae upon the left side, but to the right of it.

Labor at seven and one-half months, and the brow presented ; the prominent eyes feeling like two bullets. Female, and still-born. Dr. W. W. Morland, who reported the case, found the renal capsules small, but the other organs of the thorax and abdomen well-formed. 1860.

Dr. Stephen Ball.

829. Cranium and trunk of a fœtus, in which the first is deficient, as in the above cases, and the fissure of the spine extends to the middle of the lumbar region.

There is also an antero-posterior curvature of the cervical upon the dorsal vertebræ, with some fusion of the laminae of the first.

Age about seven months; and sex, female. No trace found of brain or spinal marrow; the nerves of this last last seeming to connect only with the membranes. Renal capsules very small, and united across the spine. Otherwise nothing unusual, excepting a fissure of the soft and hard palate. 1856. *Dr. Alfred Hitchcock, of Fitchburg.*

830. Cranium and trunk; the fissure extends to the sacrum, and there is a strong antero-posterior curvature of the cervical upon the upper part of the dorsal portion of the spine. The wings of the cervical vertebræ are extensively fused upon the left side, and the bodies of the vertebræ at the curvature are irregularly developed. Eleven ribs upon each side; extensively fused upon the left, and somewhat so upon the right side.

Labor at about seven and one-half months, and the quantity of liquor amnii large. Weight of the fœtus, 1 lb. 14½ oz., and length, 11½ in. 1864.

Dr. John O. Green, of Lowell.

831. Cranium and trunk; the fissure extending to the twelfth dorsal vertebra. Antero-posterior curvature such that the two halves of the posterior portion of the occiput rest directly upon the wings of the sixth dorsal vertebra. The bodies of the three last dorsal vertebræ are well-formed; that of the ninth is triangular, with its apex upward, whilst those of the other vertebræ are formed in about equal and lateral halves, quite regularly in the dorsal portion, but being more imperfectly developed in the cervical. These lateral halves are then separated, and an opening is the result, that is half an inch in diameter. The three or four last of these divided bodies of the dorsal vertebræ are fused upon each side. The laminae of the cervical vertebræ are also fused, and almost throughout, upon each side.

The mother had previously had four children, well-formed. Motions felt in the present case, as usual. Labor at seven and one-half months. Quantity of liquor amnii very great. Knee presented, with the cord hanging from the vagina. Child a male, and still-born.

During her pregnancy the mother was so much frightened

by a snake as to faint; felt at once that her child would be "marked"—tried to forget it, but could not, and "often" spoke of it to her friends.

Weight of the child, $2\frac{1}{2}$ lbs. In the thickened pia mater, and toward the frontal bone, was a small serous cyst, and near it a trace of brain. Pituitary body, as usual. In the posterior mediastinum were several organs; the stomach of an elongated form, receiving the bile-duct near one extremity, and the intestine arising from the other near the opening of the œsophagus; the small intestine, about 13 in. in length, and of which a portion passed through the opening in the spinal column, and appeared upon the back of the child as a mass about as large as the top of the thumb; a diverticulum arose from this last portion of intestine, 1 in. in length, and 4 inches from the stomach; the pancreas and spleen, with a small mass accessory to this last. The œsophagus was, of course, quite short. Before the dissection the protruded intestine was invested by a membrane about as thick as the spinal theca would have been, and to which it was somewhat adherent; there were also extensive adhesions to the mediastinum. The opening in the diaphragm, through which the organs passed, was near the spine, and small. Renal capsules exceedingly small. Large intestine 8 in. in length. Lungs small, and very imperfectly divided into lobes. Uvula slightly bifid. 1858.

Dr. Isaac F. Galloupe, of Lynn.

832. The head and upper part of the trunk of a fœtus, very similar to No. 822, but complicated with a double hare-lip; in spirit. The spine being so nearly entire, the neck was well-marked. Renal capsules small, but the other organs well-formed. Palate not fissured. Sex, male. 1856.

Dr. J. H. York.

833. Cast, by Dr. W., of the head of a fœtus, that differed in many respects from those above described. Case in the practice of Dr. P.; see 834. The mother had had four children, well-formed. Labor at eight months. Quantity of liquor amnii, thirteen quarts. Head presented. Child still-born.

Weight of the fœtus, $2\frac{2}{16}$ lbs. Upon the base of the

skull, and overlying the spine to a considerable extent, was a mass of brain, which had the capacity, by measurement, of nearly one ounce and a half; convolutions marked, with some appearances of a cavity, but having no appreciable connection with the spinal marrow. This last appeared in the form of two longitudinal, and moderately thick ribbons, each about one-third of an inch in width, and nearly or quite separated upon the median line; the nerves being given off from it anteriorly, and along its whole length. For the appearances of the face, see next specimen. Internal organs well formed, excepting the renal capsules, but these were not so small as usual in the "acephalous fœtus." Sex, female. The left lower extremity was much shortened and everted; the head of the femur being dislocated, and lying near the ant. inf. process of the ilium; upper margin of the acetabulum entirely wanting, but its cavity was of considerable depth, though nearly filled with fat, of which there was none upon the other side; round ligament considerably thickened. The left knee-joint was also partially dislocated; the condyles of the femur projecting strongly backward, and the leg making an angle forward upon the thigh. 1860.

Dr. J. Wyman.

834. Cranium of the above monstrosity; prepared by Dr. J. Wyman, who gave the following description of it, and of a median fissure that existed in the upper lip.

Dr. N. C. Parker, of Farmington, N. H.

"The appearances presented by the cranium are such as are often met with in anencephalous fœtuses, and in addition, the following appearances were noticed. The eyes were separated only by a very slight interval, so that the inner angles nearly touched. The lids having been arrested in an early stage of development, formed merely a narrow border, incapable of covering the globe. The nostrils were imperforate, though the nasal cavities were normally developed. The mouth was of a triangular shape, with a truncated apex; the upper lip consists of three portions, the right and left converging upwards, and a transverse portion above connecting them. In these particulars the

fissure is unlike a lateral one, where the two sides of it converge to a point. There was a deep notch in the region of the incisive teeth, but no fissure in the roof of the mouth.

“The inner orbital processes of the frontal bone had an unusual length; the nasal bones were wanting, and the ascending portions of the upper jaw met on the median line, thus closing the nasal cavities above. The alveolar border of the upper jaw contained on each side four cavities for teeth, namely, two for molars, one for a canine and one for a lateral incisor, in all eight. The middle incisors were wanting, and their places occupied by the median notch. Behind each of the incisive alveoli are traces of the intermaxillary suture, but that on the right was most distinct.

“A fissuré in the upper lip, on the middle line, is quite rare. Leuckart, Vrolik, and Von Ammon have each described one. The existence of it is admitted by Rokitan-sky, Meckel, and others. Leuckart and Vrolik believe it to be dependent upon, and always co-existing with, a defect of the intermaxillary bone, which opinion is supported by the specimen here described, where the bone in question is partly wanting. (*See Vrolik Tabulæ ad Illustrandum Embryogenum. Amst., 1849. Таб. xxxiii. Fig. 7.*)

“In the close approximation of the eyes, in the absence of nasal bones, and in the partial deficiency of the intermaxillary bone, this specimen shows a tendency to cyclopism. In cyclopien monsters, in addition to the fusion of eyes and closure of nostrils, there is always absence of the intermaxillary.

“The malformation here noticed is not, properly speaking, a fissure in the same sense that the lateral fissures are. There is naturally no fissure on the median line, in any stage of development, since the intermaxillary bud occupies the middle and is single, and never subdivided into two portions. If, however, the intermaxillary bud is not developed, the maxillary buds, as they push towards the middle, if they do not reach it, will leave an unoccupied space between them, which will account for the so-called fissure.”

- 835 A blighted, anencephalous fœtus. Preserved entire. Brain and spinal marrow wanting throughout. Head bent permanently toward the left shoulder, and directly continuous with it. Extremities malformed; the upper half of each arm being fused with the side of the body; each radius is flexed nearly to a right angle, and apparently dislocated at the upper extremity, and one of the ulnæ seemed to be wanting. The legs are permanently flexed upon the thighs, and the fingers and toes are deficient. The length of the specimen is $2\frac{3}{4}$ in., and the general appearance is characteristic of the "blighted fœtus." One child had been born, and Dr. B. was called to remove a diseased and adherent placenta. The mother considered herself as four or five months pregnant. 1862.

Dr. John G. Blake.

836. Cranium and trunk prepared. Differs somewhat from the common anencephalus; and resembles Nos. 783-8 in the Med. Soc.'s Cabinet. The frontal portion of the frontal bones is nearly as large as the thumb-nail, and bent down into contact with the body of the sphenoid bone. Behind the frontals are the parietals, of which the left is small, and the right not more than a line in width. The posterior portions of the occiput are also very small, and rest upon the extremities of the laminæ of the upper dorsal vertebræ. The cervical portion of the spine is very much curved upon the upper half of the dorsal, so that the face looks directly upward, but with a very marked lateral inclination toward the right side of the cervical vertebræ. The bodies are very irregularly developed, and much fused, as are also the laminæ on each side. The dorsal laminæ are also somewhat fused. But the most striking point in this skeleton is a union, upon the median line, of the seventh and eighth dorsal laminæ, whilst the rest of the spine is open throughout; those above and below, of course gradually approximating. The ribs upon each side are well-developed, but considerably fused; eleven on the left side, and ten on the right; one of these last being probably lost.

A seven months' fœtus. There were some appearances

of brain ; but, microscopically, Dr. Ellis found none of its characteristics. 1866.

Dr. Royal S. Warren, of Waltham.

837. Skeleton and trunk, prepared by insects. Cranium very imperfectly developed. The frontal and parietal bones, however, are large enough to extend over the whole base of the skull, but so depressed as to touch the left, and nearly touch the right clinoid process, and to leave the cavity posteriorly very small ; upper surfaces concave. The depth of the orbits, in consequence of the development of the frontal bones is quite marked, as compared with their shallowness in the more common form of "acephalous fœtus" (No. 821, etc.), in which last these bones are so very narrow. The posterior portion of the occiput is formed in a single piece, with a thick and rounded edge inferiorly, and arched upward so as to be only about one-fourth of an inch in width, on the median line. The lateral portions are well developed, as usual, but spread apart so as to make with the posterior portion an occipital foramen that measures 1 in. laterally, and $\frac{3}{4}$ in. in the opposite direction. The palate is fissured to just behind the alveoli. The spine is open throughout, and curved sharply backward at the junction of the cervical and dorsal vertebræ. Laminæ of the four last cervical vertebræ upon each side fused, and upon the left with those of the three upper dorsal ; an anomalous bone, and of some size, being also connected with the extremities of these last. Most of the ribs are more or less irregularly developed, and many of them are fused, posteriorly ; there being, besides the usual number, one upon each side, which is considerably developed, and must be regarded as cervical.

Age of fœtus about seven months. Motions quite strong until the last week or two. One foot presented, and the cord was wound around the other leg. Still-born. Quantity of liquor amnii large. There were several deformed persons in her neighborhood, by whom the mother was strongly impressed ; "made herself nearly sick, worrying, from a fear that her child would be deformed, and stated her fears many times to her husband."

The fœtus weighed 1 lb. 11¼ oz., and was 11 in. in length. Diaphragm wanting upon the left side, and the stomach, spleen, small intestine, and large intestine, as far as the left side, were in the left thoracic cavity. Left lung small, and undivided. Right lung of full size; one lobe, but with a fissure at base. Renal capsules very small. Fissure through whole of soft palate. 1866.

Dr. H. C. Bickford, of Charlestown.

838. Fœtus; in spirit. The cranial cavity is capacious; but, the spine being much bent, the whole head is thrown backward so that the occipital region is closely connected with the lower dorsal vertebræ. Over the lower part of the spine the cutis was to a considerable and definite extent nearly or quite wanting, though the cuticle seemed well developed. The amount of brain was large, but the spinal marrow was not distinctly seen. The deformity was great, from the shortness of the trunk, the protrusion of the chest, the entire absence of the neck, the throwing back of the head, and none the less from the fully developed extremities. Integuments of the lower part of the abdomen were quite œdematous. The skeleton, if prepared, would probably resemble one (No. 788) that is figured in the Catalogue of the Med. Society's Cabinet. The renal capsules, which were not so small as in the more common form of "acephalous fœtus," were fused (See No. 839), as the kidneys also were. The ventricles of the heart communicated, and the two branches of the pulmonary artery arose from the aorta. A few other malformations were noticed, but they were slight. 1856.

Dr. John E. Hathaway, of Worcester.

839. Fusion of the renal capsules; from the last case. 1856.

Dr. Hathaway.

St. Hilaire (*Hist. des Anom.* II. 543) quotes a case of fusion of the r. capsules, and remarks that there is no other on record; two, however, are reported in the catalogue above referred to (Nos. 762, 788), and another has been met with here (No. 829), besides those and the present case. — Feb. 1870, a fifth case.

840. Kidney, with the renal capsule, showing the small size of this last in the "acephalous fœtus." From No. 789, in the Med. Soc's Cabinet. 1847. *Dr. J. C. Warren.*

841. Cast, in plaster, by Dr. L., of a fissure of the uvula, from an "acephalous fœtus."

This fissure I have met with several times in this form of monstrosity, and am not aware that it has been before noticed. 1851. *Dr. E. Leigh.*

842. An acephalous and rhinencephalous fœtus. The upper lip has a contracted and somewhat cicatrized look; and about an inch above it are two eyes fused; the iris of each is distinct, and the inner canthus is upon the median line. The nose, or proboscis, is $\frac{1}{4}$ in. above the eyes; $\frac{2}{3}$ in. long, $\frac{1}{2}$ in. in diameter, and with an orifice at the extremity that opens into a cavity of considerable size. Ears bent permanently forward; and neck quite wanting. The brain about equals a hen's egg in bulk, and is covered by arachnoid. Spinal column open to about the lumbar vertebræ; and with traces, apparently, of spinal marrow. Otherwise well formed, externally. Sex, female. Weight, 1 lb. 8 $\frac{1}{2}$ oz.

Upon the left side the diaphragm was wanting, and the greater part of the alimentary canal, with the spleen, was in the left pleural cavity. Left lung small. Renal capsules rather larger than usual in the acephalous fœtus; and, otherwise, the organs seemed to be well formed. 1868.

843. The cranium of a premature fœtus, partially prepared, and showing a projection of the pituitary gland through the base. The cranium is greatly and very peculiarly malformed, and the extremities were also imperfectly developed. 1864.

844. Cranium, from a case of encephalocele. The patient was a male infant, that entered the Hospital (81,225) under the care of Dr. H. J. Bigelow. The tumor, that seemed to arise from the bridge of the nose by a sort of neck, and about which last the skin had its natural appearance, was about as large as a hen's egg, at birth, but had increased

much in size. A double ligature was applied by Dr. B. ; cerebral symptoms came on, and it died with the most intense meningitis on the fourteenth day.

The anterior horn of the right ventricle extended downward in the direction of the tumor, and was lost in the remains of the base of it. The cranium, having been prepared by insects, shows a regular and nearly circular opening, corresponding to the site of the tumor, and resulting from a deficiency in the frontal bones, and a depression of the bones below the tumor ; the nasals being broad and nearly horizontal in their position. The orbital cavities are large, and directed outward, and are quite distinct from the above opening ; the nasal processes of the maxillary bones nearly uniting with the frontals to form the lateral margin of the opening. Orbital portion of the frontal bones quite prominent within the cranial cavity. The sphenoidal fissures are quite large, and there are some irregularities of development dependent upon the formation of the opening in the skull ; but otherwise this last is well formed. 1859.

Dr. H. J. Bigelow.

For a summary of seventy-five cases of encephalocele, see *Med. Chir. Transactions*, Vol. xxxix. p. 307.

845. A fœtus, preserved entire, and at or near the full period. From the back of the head, which is of about the usual size, there hangs off a tumor that is larger than the head itself, feeling as if it might contain brain, and covered by integument, though this last is quite thin, posteriorly. 1855.
846. A cast, in plaster, of the back of the head of a fœtus, and in which the membranes of the brain protruded through an opening in the upper part of the occiput, and upon the median line ; forming a deep red, shining, and fleshy mass, of a rounded form, and quite as large as the last joint of the thumb. On dissection, nothing unusual was discovered in the brain, so far as exposed by a separation of the sagittal suture ; but the continuity of the membranes into the external mass was quite distinct. The abdomen was unusually enlarged, and owing to the great size of the kidneys. The other organs were well formed. Sex, female. Feet affected with varus. See No. 2455.

The fœtus was born at seven and one-half months, and lived but a short time. Sent to Dr. F. by his student, Mr. C. A. Shurtleff. The cast was colored by Mr. Clarence J. Blake. (Med. Jour. LXXVIII. p. 434.) See next specimen. 1862. *Museum Fund.*

847. Cranium from the above fœtus. It is sufficiently capacious, but rather flattened, and the bones are not fully developed. The opening in the occiput is about large enough to allow the thumb to pass. 1862.

Dr. T. E. Francis, of Brookline.

848. Cranium of a fœtus that most remarkably resembled the above, and that, by a singular coincidence, was also born in the practice of Dr. F. The tumor formed by the membranes, over the upper part of the occiput, was nearly as large as the top of the finger; and, having been lacerated, a probe passed readily into the cranial cavity; the brain not being involved. From the very low and retreating forehead, the cranium somewhat resembles that of the Caribs. Lower edge of the opening in the occiput thick and rounded; and the occipital foramen is also enlarged by a deficiency in the occiput upon the median line.

The kidneys, in this case, also, were so greatly enlarged as to be distinctly felt before the abdomen was opened; one weighed $5\frac{1}{4}$ oz., the other $5\frac{1}{4}$ oz., and the measurements were in proportion. Great numbers of cysts, throughout, and about the size of mustard-seed. Dr. Ellis found, microscopically, "healthy tubuli; tubuli of which the contents were granular, and dilated tubuli containing some granular matter. The walls of the cysts were fibrous, and the contents perhaps a little granular." The pelvis and infundibula were small, but perfectly well marked; and one of the ureters was easily inflated to near the bladder, where it was cut off. The bladder would not have held more than three or four drops of fluid.

The fœtus was quite plump, and measured $15\frac{1}{2}$ in.; imperfect varus. Sex, female. (Med. Jour. LXXII. 82.) 1865. *Dr. T. E. Francis.*

849. Cranium of a fœtus that must have been born between the

seventh and eighth months. It is flattened, somewhat like a Carib's, but there is no bone particularly malformed, excepting the posterior portion of the occiput, which, upon the median line, is very deeply and broadly fissured posteriorly or superiorly, and also, though less broadly, anteriorly or inferiorly. The parietal and frontal are somewhat deficient, as in hydrocephalus. 1869.

850. Portion of the spine, showing the condition of the bones in spina bifida; open from the tenth dorsal vertebra, downward. Laminae of the vertebræ fully developed, as usual. Specimen sent to Dr. B. Labour, at seven months. Breech presented. Child, a female, and still-born. Quantity of liquor amnii profuse. On dissection, a little serum was found beneath the membranes; and the nerves were spread out upon, and intimately connected with, the posterior parietes of the sac. 1852. *Dr. H. J. Bigelow.*

851. A second specimen; deficiency from the eighth or ninth dorsal vertebra to the sacrum. From a hydrocephalic fœtus, of which the cranium is preserved. See No. 1890. — The malformation is, as in the above case, where it is most usually found. 1848.

Dr. J. B. S. Jackson.

852. A large pendulous tumor, that was successfully removed, in a case of spina bifida.

“The child was born on the 4th of January, at the full period, well developed, and well formed externally, excepting the tumor and a slight varus of one foot. The tumor hung, like a pendulous polypus, from over the vertebral column, and about on a line with the crest of the ilia. It had a peduncle, which was about a foot in length, and about as large as the little finger, but enlarging somewhat just before it joined the body of the tumor. This last was nearly the size of two fists, of a rounded form, but tapering toward the peduncle, fleshy to the feel, and fluctuating, but not tense; the surface had the smooth, shining appearance, and there was the absence of cutis, that is seen in spina bifida. Upon the peduncle the cutis was well developed, and it terminated abruptly where the body of

the tumor began. Immediately after the birth of the child a ligature was applied to the peduncle, as near as possible to its origin, and it was then divided; but the ligature slipped, and there followed a hemorrhage which was very nearly fatal. It did well, however, and it has continued to thrive until the present time (May 20). The peduncle being found to have a large central cavity, a catheter was passed into it, but not into the body of the tumor, and a few teaspoonfuls of clear serum escaped, which, on being heated, coagulated to the degree of solidification; a ligature was then applied to prevent any further escape. At first there seemed to be a considerable deficiency of bone at the origin of the peduncle; and for the first two months the cicatrized surface bulged out quite perceptibly when the child cried. The opening, however, has gradually contracted, and an irregularity of surface is now only to be felt upon pressing down upon the vertebræ; the remains of the peduncle being about one-fourth of an inch in length."

The cavity of the tumor contained a little dirty fluid, and was lined by a serous membrane. Parietes from $\frac{1}{4}$ to $\frac{1}{2}$ in. in thickness, and many cysts were exposed upon the cut surface; the intervening tissue being lax but tough. The long peduncle had shrunk to $2\frac{1}{2}$ in. in length, and, having been cut open throughout, its inner surface presented no appearance of a lining membrane, but rather that of common integument. The cavity of the peduncle was about one-sixth to one-fourth of an inch in diameter, and with considerable difficulty a small probe was passed down into the cavity of the tumor. The opening into this last was about where the tumor began to taper toward the peduncle; and it was not direct, but just within the orifice of another adjoining canal, that was about three-fourths of an inch in length, and large enough to admit a probe about two lines in diameter. Upon the inner surface of the peduncle, and closely connected with it, by a lax cellular tissue, are two or three quite large nerves, and a large blood-vessel, which are gradually lost within the tapering portion of the tumor; the hemorrhage above referred to being thus explained.

1829.

Dr. Elisha Huntington, of Lowell.

Mr. T. Holmes, in his late work on the Surgical Treatment of the Dis. of Infancy and Childhood, refers to this unique case, as it seems to be, and questions whether it was really one of spina bifida; but there can be no reasonable doubt in regard to it; and Dr. Hodges, who reviewed the work of Mr. H. (Med. Jour. July 1, 1869), and has examined the specimen, coincides in this last opinion. Mr. H. thinks the cyst multilocular; but it was mainly one large cavity, and the cysts in the parietes were quite small. He also severely criticises the statement that the peduncle was "about a foot in length" at the time of birth; but I could sooner believe that it had shrunk to $2\frac{1}{2}$ in. after the depending weight was taken off, and it had lain for several months in spirit, than that so reliable a person as Dr. Huntington could have much overstated the fact. Unfortunately, Dr. H. is now not living, and I have been unable to get any further information in regard to the case.

853. Pelvis, with the integument, etc., from an unusual case of spina bifida; in spirit. From a fœtus, at the term; the arm presented, and it lived about half an hour.

Over the lower part of the sacrum was a tumor, about half as large as a nutmeg, of a flattened form, and covered by healthy skin. A rounded, fibrous cord ran from this to the spinal canal; and, this last being cut open, the spinal marrow was found to be continued nearly to the tumor, as it is to the sac in a common spina bifida, where this last is below the formation of the cauda equina. As usually happens in this variety of the malformation, the posterior laminae of the last sacral vertebrae were irregularly developed.

The penis was quite deficient, and the urethra terminated at some distance from the extremity. Stomach quite large, and the duodenum, terminating in a cul-de-sac just before it received the bile-duct, was distended to the size of a large nutmeg. Intestine well till it reached the bladder, when it opened into that organ, and then, standing off from it at a right angle, tapered off like an appendix, $\frac{3}{4}$ in. long. Over the front of the sacrum were two thin, firm, rounded, serous cysts, $\frac{1}{2}$ in. or more in diameter, and not

communicating with each other, nor with any of the organs. The right testis was in the scrotum, and the left in the abdomen; and a vas deferens joined that of the left, about midway, coming from what looked like, but was found microscopically not to be, a third testis. Kidneys about as large as usual, but the bladder was exceedingly small, and the urethra was scarcely pervious.

Dr. James W. Robbins, of Uxbridge.

The above case was published in the *Med. Jour.* (Vol. LIX. p. 355), with nine others, more or less similar to it, that have occurred here, and six others that I have seen in the museums of Europe; and to these may now be added the following case.

854. A second case. The sac was nearly, or quite as large as two fists, consisted of integument, lined by a serous membrane, and contained $\frac{3}{4}$ x or xii of serum; opening from spinal canal quite marked. The two elbows, and the organs of the abdomen presented; the child being most remarkably doubled up.

The abdominal parietes were entirely wanting. The bladder was formed in two cavities, that communicated freely near the neck; and one of them communicated almost throughout with the rectum; this last opening near the line of the integument. Right kidney in a state of hydronephrosis, and very large, as well as the ureter, which ended in a cul-de-sac, near the bladder. Left kidney, and renal capsules normal. Upon each side, and at some distance apart, was one-half of a uterus, with its tube, and one-half of a vagina, perfectly symmetrical; cut open upon one side, and shows the os tinæ. Ovaries not found; trace of external labia; pubic bones widely separated, as in extroversion of the bladder. Thoracic organs well. The preparation shows the sac, and the termination of the spinal marrow. 1854. *Dr. R. M. Hodges.*

855. Pelvic organs, from the above case. 1854.

Dr. R. M. Hodges.

856-7. Photographs of the patient, showing a back and side

view of a tumor over the sacrum, that "looked not unlike an immense hydrocele." She was a little girl; born August 5th, 1857; and the mother states that the tumor, when first discovered, was not larger than the tip of the little finger. When the photographs were taken, in May, 1867, it measured 12 in. around the base, $20\frac{1}{2}$ in. in its greatest circumference, and about 6 in. in height. July 2d, 1869, the base measured $14\frac{1}{2}$ in., and the greatest circumference $25\frac{1}{2}$ in. The skin, which is continuous over it, is generally so thick that the fluid is not seen through it; but in some places it is so thin and transparent that it looks as if it might burst at any time, and this thinness was more marked at the last date than at the first. When in bed, the tumor is less tense, "and if she turns upon it for a moment the brain suffers." She is a very largely developed child, weighing 90 lbs. in May, 1867, and 120 lbs. in July, 1869. Menstruated when she was a little over eleven years of age, and the breasts are "immense for a child." The above facts were sent by the attending physician, Dr. James Orne Whitney, of Pawtucket, R. I. 1869.

Dr. H. J. Bigelow.

858. A fourth case; cast in plaster of the lower part of the back, to show the tumor. The patient was a healthy-looking girl, twenty-three years of age, and had always been more or less under the care of Dr. J. L. Chandler, of St. Albans, Vt. The tumor consisted of a solid mass of flesh, centring over the sacrum, ill-defined, irregularly rounded, and about 8 in. in diameter, and 3 in. in elevation; the integument over it being perfectly healthy. At birth it was half as large as a goose-egg, and not, as it usually is, over the median line; integument at prominent part very thin, and toward the end of the first year it was punctured several times, and discharged a little fluid. It grew from that time with her growth, but for the past seven years had been stationary. There had always been partial loss of sensibility and muscular power, so that she was obliged to use crutches; and until the last seven years the excretions had been involuntary. The lower extremities were of course much wasted; the feet were affected

with varus, and there had also been disease of the bones of the feet from childhood, and sores upon the hip for eight years. Occasionally she had pain in the tumor, and at the same time in the head; and at any time in the head if she lay upon the tumor. About two years after this cast was taken, she fell from a horse, and received a severe blow upon the tumor, which enlarged to two or three times its previous size, and threatened to slough; and about four years after the fall she died. 1857. *Museum Fund.*

859. A fifth case; preparation of the sacrum and lumbar vertebræ, to show the wide separation of the sacral laminæ.

From a healthy little girl, seven years of age. Congenital tumor over the sacrum. Upon admission into the Hospital (115, 124) it was $16\frac{1}{2}$ in. in circumference, at the base; projected 5 in., and was of an ovoid form; tense, fluctuating, covered by integument, but in some parts seemed almost ready to burst. Punctured by Dr. C., and about a pint of clear fluid drawn off, of the spec. gravity of 1.006, containing a small quantity of albumen, and resembling that of hydrocephalus. The tumor was then tied at various points with strong ligatures; intense pain followed, and the child died on the fourth day. See next specimen. 1864. *Dr. H. G. Clark.*

860. Tumor from the above case. Cavity formed by a dilatation of the membranes. Spinal marrow removed, by cutting away the nerves; of full size, and gradually lost upon inside of sac, about two inches from orifice. Some appearance of nerves in cavity of sac. Quantity of fat between sac and skin considerable. 1864. *Dr. H. G. Clark.*

For a seventh case see No. 864.

In the Transactions of the Patholog. Soc. of London, Vol. VIII. p. 16, a case is related of extirpation of one of these tumors from over the sacrum; the membranes of the spinal marrow being exposed, though not wounded. The patient was an infant, ten months old. The tumor was supposed to have arisen from the spinal canal, but I have

seen nothing of the kind in the few cases that I have had an opportunity to dissect.

861. A sixth case, that differs somewhat from the above, in being situated over the junction of the lumbar and sacral vertebræ; covered with skin, and fluctuating.

The patient was a very healthy infant, three or four weeks old. A double ligature was passed through the tumor by Dr. B., and tied; and it died on the ninth day. The membranes were inflamed at the seat of the tumor, and the spinal marrow was continued down to it, as usual. The preparation of a part of the spine shows a separation of the laminae of the last lumbar vertebra, and the same was observed of the sacral; but these last were in part cut away in the removal of the specimen. 1856.

Dr. H. J. Bigelow.

862. Intermaxillary bones, from one of the worst cases of double hare-lip.

The patient was a robust infant; had very great difficulty in taking food, and was reduced from 12 to 8 lbs. in two weeks. Palate also broadly fissured. It died at the age of four months; and the parts, having been removed, were sent in spirit to Dr. B. Prepared since then as a dry specimen, and showing the four incisor teeth, and the union of the two bones, which last, according to St. Hilaire (*Anom. des Org.* Vol. i. p. 581), is usually observed in these cases. 1857.

Dr. H. J. Bigelow.

863. A second specimen. Bones united. Two incisors on right side, and one on the left; the fourth not being developed.

Removed at the Hospital (101, 234), from an infant four months old; and it died from pulmonary inflammation on the ninth day. 1862.

Dr. H. J. Bigelow.

864. Extroversion of the bladder, etc.; in spirit. From a patient of Dr. Charles D. Cleveland. Child small, and lived a week.

Labia separated to a considerable extent, and the pubic bones widely separated. Upon the surface of the bladder

there open separately the small intestine, which is larger than natural, but only 3 ft. long, the large intestine which is only $2\frac{1}{2}$ in. long, and three lines in diameter, and a well-developed and independent appendix cæci; the two last openings being traversed by bands. There is also a small and irregular offset from the large int. near its outlet. The uterus is in two widely separated portions; the right about as large as the whole organ should be, with its tube, ovary, os tinæ, and vagina ending in a cul-de-sac; the left was smaller and without a vagina, but otherwise the same. There is also the form of spina bifida above described (No. 853); the tumor over the sacrum being two or three inches in diameter, covered by integument and a very thin layer of fat, and discharging, when opened, a clear serum. 1860. *Dr. C. Ellis.*

865. A fœtus, preserved entire. The liver, with a large portion of the small and large intestine, protrude at the umbilicus, and were in the recent state, as now, entirely uncovered. The placenta adhered to the top of the head; and the cranial cavity, which was large, was mostly filled by serum, though there was also an undeveloped brain. The vault of the cranium was entirely wanting; the base being well developed. The left thumb is a mass of flesh, attached by a thread-like process, and this is the only other unusual external appearance. Labor occurred at the fifth month, and the breech presented. 1866. *Dr. J. S. Jones.*

866. Cast, in plaster, by an Italian, of a premature fœtus, and colored by a German artist. The mother was but seventeen years of age, and used means to procure abortion at the fourth month. Quantity of liquor amnii very large. Head presented. Cord about 4 in. in length, and child gasped a few times. Weight, 2 lbs. $2\frac{1}{2}$ oz.

The eyes are far apart, and have a remarkably staring look, from a want of development of the lower lids. The upper jaw, from its prominence, suggests the idea of the beak of a bird; the lower jaw retreating, and being exceedingly movable. The tragus alone represents the external ear.

Trunk well formed, but the extremities (No. 868) were very deficient. The scapulæ are narrow, and imperfectly developed. Each humerus is $2\frac{1}{4}$ in. in length, and connected by areolar tissue with the hands; the forearms being wanting. The right hand had three fingers; two fused, and one consisted only of a terminal phalanx. Upon the left was a thumb, a terminal phalanx connected with it, and one finger. The thigh bones are 3 in. long. The legs were strongly flexed upon the thighs, and quite short. Right tibia $\frac{7}{8}$ in. long, and, as well as the fibula, very broad, irregularly developed, and apparently quite cartilaginous. The foot had a truncated appearance, without toes, but with a well-formed heel; the skeleton consisting of a single, irregularly formed cartilage, and one small, second piece. Left tibia, $1\frac{1}{2}$ in. long, and well ossified, but quite broad and misshapen; lower third of fibula only formed, and consisted of a broad and thick cartilage. The foot was $1\frac{3}{8}$ in. long, with valgus, and a great toe, but no other. The tarsus consisted of a single cartilage, a well-developed toe, and by the side of it a second metatarsal bone, but nothing more. The internal organs were well-formed, excepting the heart. (No. 379.)

Museum Fund.

867. Cranium from the above. A bone over each auditory meatus may be the malar, misplaced, atrophied, and fused with the temporals; but, if not, there are no malars. Intermaxillaries very prominent. A trace only of the maxillaries exists, though the nasal processes are quite developed. Orbital cavities quite open inferiorly, and the vomer very conspicuous. Palatine bones seem wanting. Large wings of sphenoid bone, and the temporals irregularly developed and fused; and of the zygoma there is hardly a trace. Two large cartilages, in the recent state, in the place of the nasal bones, and resembling them in form, though very much larger. Each half of the lower jaw is formed in two pieces; the division being toward the front, and the malformation a very unusual one. 1859.

Dr. N. C. Parker, of Farmington, N. H.

868. Extremities from the above. 1859.

Dr. N. C. Parker, of Farmington, N. H.

869. Head of a malformed pig; in spirit, and very similar to the triocephalus of St. Hilaire. Two fully developed ears come very nearly together, leaving an opening between them, about $\frac{1}{4}$ in. in diameter, and through which air could be forced from the œsophagus or trachea. Rather more than an inch above this mouth, as it must be called, is a fleshy mass, also about $\frac{1}{4}$ in. in diameter, and that represents the nose; and these are the only features. Back of the head well formed; as was the animal otherwise, externally and internally. 1860.

For a rhinencephalus in an acephalous subject, see No. 842.

870-3. Casts, in plaster, of the hands and feet of a woman, in whom the thumbs and great toes were unusually short, and reached only to the first adjoining phalanges. The index finger is bent to a right angle, and this also was congenital. With this last exception, the above deformities existed in the father and sister of this woman. The second toe of each foot had become inflamed, and one of them was removed by Dr. C. All of the toes, also, are inclined to the inner side of the feet. 1866. *Dr. A. Coolidge.*

874-5. Casts, in plaster, by Dr. L., of the hands of a laborer, who was capable of doing as much work as any man. In the right hand one very broad metacarpal bone seemed to be common to the index and ring fingers, between which was a small nipple-like projection in place of a middle finger, and an open space toward which the fingers inclined. In the left there is the same open space, with two very imperfectly developed fingers, that were fused nearly to their extremities, and stiff, but having considerable motion upon a common metacarpal bone; one of them has a nail. The other fingers, have, each, their own metacarpal bone. Both hands are very broad across the knuckles; but, otherwise, they are well formed. 1849. *Dr. E. Leigh.*

876. Upper extremities of a five months' fœtus. One has been

prepared, to show the condition of the bones; humerus about $1\frac{1}{2}$ in. long; and ulna about 1 in.; radius wanting; the hand has only three fingers, but is otherwise well-developed. The other extremity, which is entire, resembles it in every respect, so far as appears. 1867.

Dr. G. J. Arnold, of Roxbury.

877. Malformation of the pelvis, and left lower extremity, in a five months' and healthy-looking fœtus; a ligamentary preparation by Dr. Hodges, and in spirit.

The pelvis is compressed laterally, and distorted; the sacrum is open posteriorly, as in spina bifida, and the coccyx turns backward. Upon the left side the body of the pubes is wanting, so that there is a deep notch from above instead of the thyroid foramen. The left acetabulum was situated very near to the spinous process of the ilium, and was so shallow that it could hardly be said to exist; the right was also very shallow, and allowed a very ready dislocation and reduction of the hip. The position of the right lower extremity was unnatural; but, as seen in the preparation, the skeleton is normal. The left femur is considerably shorter than the right. The fibula is one-fourth shorter than its fellow, broad and stout, and so curved that the sole of the foot, before dissection, lay close to the lower and inner part of the thigh. The tibia is represented by its lower cartilaginous epiphysis only; and this was connected, by a short fibrous band, with the inner condyle of the femur. Foot well formed. Patella wanting.

The right hand was flexed to an acute angle upon the forearm; and the left forearm to a right angle upon the arm. Kidneys wanting. Renal capsules rather largely developed, and in their normal position. Bladder exceedingly small, and the rectum opened freely into it; there being no anus. 1867.

Dr. J. B. S. Jackson.

878. The bones of the pelvis and lower extremity of a monstrosity (Siren); in spirit, with some of the organs.

The case was published in the *Med. Jour.* (Feb. 18th, 1869); and the following is a short abstract of the report. The lower extremities tapered as usual to a point; and the fœtus, which was generally well formed, weighed about 3

lbs. On dissection, the diaphragm was wanting upon the left side, and the stomach and spleen lay in the chest. The right lung was well, but the left consisted of but a single lobe. A left upper vena cava opened into the left auricle; and in the heart was an interventricular opening. The aorta sent off two very small iliacs, and a large vessel that ran straight along the median line to the umbilicus. The rectum ended in a cul-de-sac (No. 682), and the left lobe of the liver and spleen consisted, each, of several small lobes. Two renal capsules, and one small, encysted kidney. Uterus in two portions, and a cavity in each; with a Fall. tube, and ovary for each, and perhaps a rudimentary vagina. Bladder wanting. A little cutaneous excrescence was attached to the lower part of the spine, but had no connection with the spinal membranes. The ischia were fused throughout, as shown in the preparation, but leaving a pelvic cavity of considerable size; pubic bones much depressed and elongated, and the obturator foramina very closely approximated; sacrum very irregularly developed. The femur was $3\frac{1}{4}$ in. in length, and formed by a fusion of two; convex in front, and flat behind, with two distinct heads, two inner condyles and no intervening one, and two patellæ upon the back of the knee-joint. In most respects the preparation resembles one of Cruveilhier's (*Anal. Path.* liv. 40, pl. 6, fig. 6). Tibia $1\frac{1}{4}$ in. in length, tapered suddenly to a point, and terminated in three little phalangeal cartilages. The muscles about the thigh were well-developed, and most of them were distinctly made out, but some were wanting.

The case occurred in the practice of Dr. H., and the child, though so small, was carried to the full period; and during the fifteen or twenty minutes that it gasped after its birth, the heart was felt beating strongly in the right side of the chest. Quantity of liquor amnii exceedingly small. Cord short, and the placenta very small; and both had a diseased look. The heart, aorta, and umbilical artery, spleen and lungs, are shown upon a bent glass rod, and in the same jar with the pelvis, etc. The other organs are also preserved; and for a cast of the liver see No. 689. 1869. *Dr. H. P. Hemenway, of Somerville.*

879-80. Bones of the foot of an adult; articulated, and consisting of an os calcis, astragalus, a protuberance that may represent the scaphoid, and a metatarsal bone; all co-ossified into one mass, and somewhat irregularly though fully developed. Phalanges lost. Lower half of the leg in connection, and well formed.

Mate to the last, with the muscles; and very similarly formed. The scaphoid is sufficiently marked. Two phalanges co-ossified; but articulated with the metatarsal. 1847. *Dr. J. C. Warren.*

881. Photograph of a Hospital patient (119, 64). The right forearm and right leg end in a conical stump about midway; and the skin over them was perfectly free. A little warty excrescence near the end of the leg is not shown. A boy, æt. 13, and otherwise well formed. 1865.

Museum Fund.

882. Fusion throughout, of the second and third toes; nails very close, but separate. From an adult. The other foot was similarly affected; and the web between the second and third fingers of each hand extended nearly to the second phalanx. The other fingers and toes were normal; in spirit.

In the mother all of the toes were similarly affected; in a sister the same, besides a union of two fingers, and in her son, the same fusion of the toes. 1864.

Dr. Joseph W. Merriam, of Portsmouth, R. I.

883. Photograph of a native tailor in Manilla, who supports himself by working at his trade with his feet. There is an appearance of the scapulæ, but otherwise the upper extremities are entirely wanting. 1868. *Dr. B. Joy Jeffries.*

II. MONSTROSITY BY EXCESS.

884. Photograph of the well-known Siamese Twins, as they appeared when on exhibition, recently, in this city. Now fifty-five years of age. One is $5\frac{2}{12}$ ft. high, and the other 1 in. less. Each is separately married, and has a large number of children. In 1833 they had intermittent fever, and both had chills at the same time. 1866. *Museum Fund.*

885. Two fœtuses, united from the umbilicus to the upper third of the sternum; in spirit.

The mother was forty-three years of age, and had had seven or eight well-formed children. In the present case the heads presented, and the children lived about fifteen minutes after they were born. A month afterward the mother was doing sufficiently well. Weight of the fœtuses $5\frac{1}{8}$ lbs. Each (A and B) had its œsophagus and stomach equally developed. At about an inch from the pylorus the duodena united, and the canal was single for 37 in. It then again divided, but first dilated into a cavity of a somewhat triangular form, and nearly as large as the top of the thumb. Below this the small intestine of A was $23\frac{1}{2}$ in., and of B, 32 in.; large intestine of A, $16\frac{1}{2}$ in., and of B, 23 in. The intestine of A, $2\frac{3}{4}$ in. below the division, was obliterated by a thin septum; and below this was smaller than the other, and contained only mucus. Dilatations just at the division of the intestine in double monsters, are described and figured in the Catalogue of the Med. Soc.'s Cabinet. As usual in such cases, the diaphragm formed one large arch. The livers were fused, and had two distinct gall-bladders; and the following organs were found in each fœtus,—the spleen, kidneys, and renal capsules, bladder, testicles, vesiculæ seminales, lungs, etc.

The two hearts were fused, and very broad for their length. The auricles formed almost a common cavity. The upper vena cava of A ran down upon the left side, but opened into the right auricle; the course of the other v. cava being as usual. The pulmonary veins of each fœtus, respectively, formed a common trunk; that of B opening into the right auricle. From the right ventricle of A a pulmonary artery arose, but there was no ductus arteriosus. The left ventricle communicated pretty freely with the right, but not directly with the auricle. The aorta could be inflated, but a small probe could not be passed into it. Right umbilical artery wanting, and the iliac was, of course, very small; the left being very large. In B it was just the reverse. In B the pulmonary artery was normal. The left ventricle had no communication with the right, but was directly continuous with the right ventricle of A.

Aorta normal excepting the left carotid, which arose from the innominata at its origin.

The upper third of the sternum of each fœtus was distinct; but, below this, each sternum was formed by a fusion of the right half from one fœtus, and the left half from the other. 1859.

Dr. D. J. Perley, of Oldtown, Me.

886. A second specimen, similar to the above, and preserved in spirit. The feet presented; labor was not very difficult, and the woman did perfectly well. Weight of the fœtuses, $7\frac{3}{4}$ lbs. Sex, male. The muscles about the thorax vary somewhat, as the union of the fœtuses is not exactly face to face; and about the cord they are deficient to the extent of $1\frac{1}{2}$ in.

Alimentary canal double to the duodena, where they unite, at the distances from the pylorus, respectively, of $\frac{1}{4}$ in. and nearly 1 in. The intestine is then single for 44 in.; and then divides again into $17\frac{1}{2}$ in. of small, and 16 in. of large intestine for one fœtus, and 18 of small, and $18\frac{1}{2}$ of large for the other. Livers fused. Two gall-bladders; one hepatic duct opening into the cystic near the intestine, and the other having apparently a separate opening, though very near to the cystic. The other organs of the abdomen are in two sets, and well formed, excepting the pancreas, in which last the two organs are united by the head. Diaphragm as in the last case. The pleural cavities of one fœtus communicated; but, otherwise, the two sets of lungs, etc., were normal. Sternum as in the last case.

The two hearts were intimately fused. The auricular portion consisted mainly of a fusion of the two right auricles, and received the upper and two lower venæ cavæ. At each extremity of this common cavity was a left auricle, receiving the pulmonary veins respectively by a common trunk, and opening into the ventricles; the left auricle of A being quite small, and communicating largely with the general cavity, whilst that of B was more developed, and so far separated as to show a foramen.

The ventricular portion showed at the apex, externally, a tendency to fissure, and the two cavities communicated

freely toward the base. That of A was formed mainly by the ventricle that sent off the aorta; and the cavity from which the pulmonary artery arose was quite small, and communicated freely with it. That of B was much more equally divided into a right and left ventricle, which also communicated freely. Each ventricular portion had its separate aorta and pulmonary artery; and A had a long and slender ductus arteriosus, but B had none. 1847.

Dr. B. E. Cotting.

886½. A photograph of two black girls, eighteen years of age, who are united by the lower part of their backs, and who were recently exhibited in this city. They are said to have one anus and one vulva, but two urethræ; the call to urinate and defecate simultaneous, and the discharge being as in the case of a single individual; and the same with menstruation. When the lower extremity of one is touched, the other feels it, but cannot locate the sensation. Otherwise they are as two individuals. For a full account of these girls see the *Med. Jour.*, July 8th, 1869.

Museum Fund.

887. A kitten; entire. One head and eight extremities; fused to the umbilicus. 1865.

Boston Soc. for Med. Improvement.

888. A pig, similar to the above; with a fusion of two ears upon the back of the head. Sex, female. 1850.

Mr. A. H. Ogden, taxidermist.

889. A chicken, similar to the above. 1850.

Messrs. Davis & Dickinson, of Cambridge.

890. A chicken, with two supernumerary lower extremities, growing from the pelvis, and that are considerably, but imperfectly and unequally, developed. It lived about three weeks. 1867.

Mr. Josiah L. Hale, Jr., med. student.

891. Union of two fœtuses; two heads; two spines as low as the sacrum, and nearly approximated; a scapula, that

seems to be formed by a fusion of two, besides two perfect upper and lower extremities. Organs examined by Dr. C., and mostly removed; and the specimen was then dried; its height about 16 in.

The children were still-born, and the mother did quite well. Dr. C. was informed by the physician who attended the woman, and who had had a very extensive obstetrical practice, that, after one head was born, an evolution took place, and the breech came down, followed by the second head.

Dr. C. found two stomachs, with a union of the intestines about six inches below; a fusion of two livers; two gall-bladders; and one heart, which, with the blood-vessels has been partially injected, and is shown in situ, as well as the stomachs. 1850.

Dr. Charles A. Cheever, of Portsmouth, N. H.

892. Skeleton of a double fœtus, prepared and mounted by Dr. Jeffries Wyman. The subject of this case was presented by Dr. Fenn, who reported that labor occurred at the fifth or sixth month, lasted eight hours, and was not unusually difficult; the heads presenting.

The following anatomical description, by Dr. W., with his remarks upon the formation of double monsters, was published in the *Med. Jour.* Vol. LXXIV. p. 169. 1866.

Dr. Artemas I. Fenn.

“This fœtus was nine inches in length, had two well-formed heads, — the right of which will be called A and the left B, — facing each other somewhat obliquely; the two necks met on a level with the shoulders. Seen in front, the trunk and limbs had the usual form, except that the thorax was broad, and the limbs of the two sides were connected with different vertebral columns. There was neither genital nor anal opening, but a small spherical body existed in the place of a penis. From this a double raphé, in the shape of a V, extended backwards, each branch directed towards the coccyx of the same side.

“On the hinder face a third symmetrical arm was attached on a level with the normal ones. The hand was in the same plane with the other segments of the limb, namely,

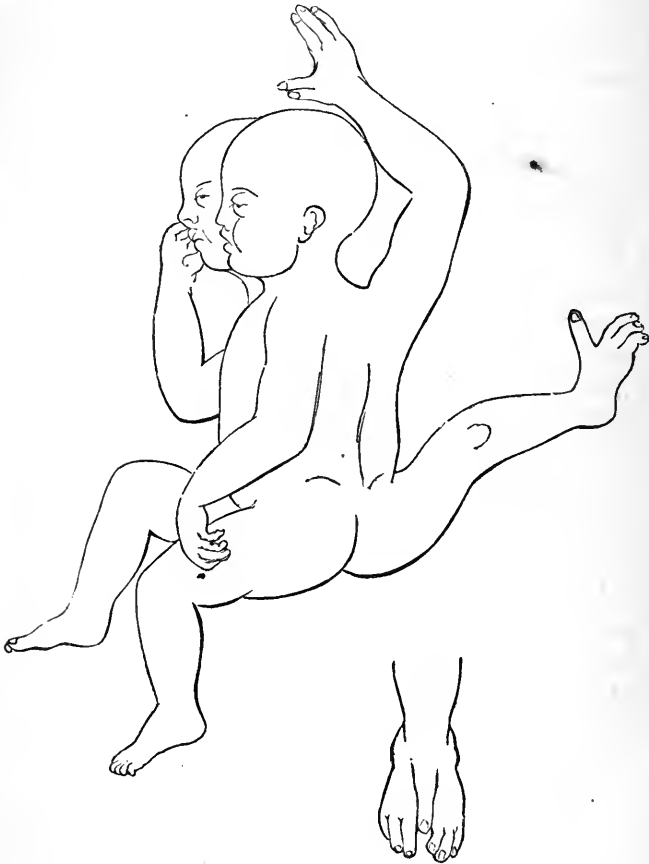from before backwards, the thumb pointing between the heads; it had no palm, but two backs, and each finger had nails on the two sides. The thumb and index finger were connate. The spinal grooves converged downwards, between which a third leg, symmetrical in structure, but somewhat distorted by pressure, arose on a level with the two normal legs, and was bent upwards, so that the toes pointed towards the back. The foot was compound, and provided with two groups of toes, of three each, one right and the other left, and a single large symmetrical toe arose from the middle of the back of the foot. This toe had a nail on each side. If this third leg is brought down to a level with the others, the heel is directed to the space between the other two feet, and thus the legs together form a true tripod.

“*Skeleton.*—A general conception of the plan of the skeleton may be formed by supposing two skeletons placed side by side, the arms nearest each other pointing backwards and palm to palm, and the corresponding legs with the toes turned backwards, and then each skeleton cut in a plane extending from the median line in front outwards to the right in one, and to the left in the other, through the clavicle, glenoid cavity, lengthwise of the arm and hand, so as to separate the inner and palmar surfaces from the dorsal; also in the same direction through the ribs and acetabulum, lengthwise of the legs, and through the second toe; this done, the portions of the skeletons nearest each other are to be thrown away, and the remaining ones brought together and fused. This, except with reference to a very few unimportant differences of detail, would give us a correct idea of the state of things in the skeleton here described.

“It will be unnecessary to describe any other parts than those connected with the third limbs, it being borne in mind that, seen in front, the two crania and vertebral columns, the thorax, pelvis, and limbs are formed as usual, except that the parts on the right side of the median line are connected with one head and vertebral column, and that on the left with the other. On the hinder side of the double thorax there is no sternum, except a small portion

described below; the ribs are short, bent strongly downwards, reaching nearly to the pelvis, and are united by their cartilages.

“The *arm* is connected with the rest of the skeleton by means of a piece of cartilage, which is attached to the top



of the sternum above described, and resembles a manubrium, but has no connection with the ribs; it is directed backwards between the two necks, and supports a symmetrical clavicle, which has the same direction. This has a deep fissure at either end, prolonged into a groove on the

body of the bone. It is formed, as it were, of two clavicles so turned that their upper surfaces are pressed against each other, and their greater concavities directed upwards. The *scapula* is composed of two bones, united at the glenoid cavity, having an acromion and spine on each side, but no coracoid processes. The bones of the arm, forearm, and hand are perfectly symmetrical; all the bones of the last two are arranged in a plane passing through the fœtus from before backwards, the radius in front and the ulna just behind it.

“The *pelvis*, as seen behind, has neither pubic nor ischiatic bones, but consists of two ilia, the left one of A and the right of B, united at the acetabulum, which last is on the median line. The *femur* is much compressed laterally, is slightly twisted, but otherwise symmetrical. The *tibia* and *fibula* are in the same plane with the arms, and each has a projecting point of bone, as if they had both been fractured. The tibia is the foremost of the two, and has a right and left tuberosity for the attachment of the right and left *patella*. The tarsal bones were not ossified, but the cartilage of a single os calcis was easily made out. The large and symmetrical toe had three phalanges, showing that it did not correspond with the great toe, contrary to what its great size would lead one to expect.

“*Muscles*.— Only such parts of the muscular system will require notice as are connected with the limbs described above, all the others being normal.

“The *left sterno-mastoid* of A and the right of B have the usual attachments to the head, but both are inserted into one and the same symmetrical clavicle and the single sternal piece above mentioned.

“The *left sterno-hyoid* and *sterno-thyroid* of A and the right ones of B arise from a common sternum, but are inserted into the usual parts belonging to the corresponding heads of the fœtus.

“The two *trapezii*, one arising from each head and vertebral column, are inserted into their respective portions of the compound scapula and clavicle.

“The *levator anguli scapulae* and the *rhomboidei* are double.

“Neither *pectoralis major* nor *minor* were found.

“A *serratus magnus*, on each side, arises from the ribs, and is inserted as usual into the base of the scapula on the same side with itself.

“A right and left *latissimus dorsi*, *supra* and *infra-spinatus*, *teres major* and *minor*, are all inserted into their respective portions of the humerus on each side. The *deltoid* arises equally from the two portions of scapula and the end of the compound clavicle; it is inserted symmetrically into the humerus. A *subscapularis* arises from each base of the scapula, but the two are inserted into each other by the union of the tendons, just behind the glenoid cavity.

“The *triceps* has two long heads, one arising from the edge of each half of the scapula, and two short heads arising from the side of the humerus, and is inserted as usual into the olecranon.

“In the place of the *biceps* and *brachialis* is a single muscle, arising from the humerus by a pointed head on each side of the deltoid, and in this respect resembling the *brachialis*; but, like the *biceps*, its tendon is inserted into the radius. There was no long head. Its action would be that of the biceps.

“The following muscles were repeated symmetrically on the two sides of this third arm:—

“*Supinator longus* and *S. brevis*.

“*Extensor carpi radialis longior* and *brevior*.

“*Extensor carpi ulnaris*.

“*Extensor carpi digitorum communis*.

“*Extensor longus pollicis*.

“*Abductor longus*.

“There were no *flexors* or *pronators*, nor any *extensor proprius* of the index or little fingers.

“Below the ribs and their cartilages on this side of the fœtus, some ill-defined muscles occupied the place of the broad muscles of the abdomen, but could not be identified as such.

“A *psaos* and *iliacus internus* existed on each side, but both were inserted into the single trochanter minor on the front of the femur.

“A *glutæus maximus* arose from each side of the com-

pound ilium, but both were inserted together into the back of the femur.

“ A single median *gracilis* arose from the symphysis of the ilia, and was inserted into the tibia in front between the two tuberosities.

“ The extensor muscles of the leg, namely, the *rectus* and *vasti*, were found in double series; the recti arising as usual from the pelvis, and the vasti from the lateral portions of the femur; each series was inserted into a corresponding patella, and by means of their respective ligaments into the right and left tuberosities of the tibia. Thus each set of extensors became a flexor with reference to the other. A *biceps* on each side was inserted into the top of the fibula. Besides this last-mentioned muscle, there were no other proper flexors of the leg.

“ On each side of the tibia was a *tibialis anticus*, but both were inserted into the top of the foot by a common tendon.

“ An *extensor communis* on each side of the tibia was inserted into the three corresponding toes, and a slip was given from each to the symmetrical toe.

“ A *peroneus brevis* was inserted to the outer sides of the foot.

“ A single *gastrocnemius* was present, but no *soleus*.

“ A *flexor communis longus* on each side was inserted into the toes in the same order as the extensors.

“ *Nerves of the Arm.*—A *brachial plexus*, consisting of five pairs of nerves, is given off from each neck, namely, from the left side of A and the right of B, and, with the exception of the internal cutaneous nerves, the branches of the two sides keep separate. In the axilla each plexus gives off a *circumflex* and an *external cutaneous* nerve, the latter perforating the supinator longus at the lower part of the arm. The two *external cutaneous* nerves unite and descend the back of the arm on the median line. The remaining branches of the brachial plexus pass on each side between the long head of the triceps and the humerus, descend on the sides of the arm, form the *musculo-spiral*, *radial*, and *ulnar* nerves, which last two are distributed to the backs of the hand. No median nerve was found.

“*Nerves of the leg.*—The *sciatic nerve* on each side as it passes from beneath the *glutæus* consists of three portions, two lateral and one median; each of the former, one to the right and the other to the left, passes along the edges of the external vasti and within the lower ends of the bicipites, then over the top of the fibula, forming the *peroneal nerve*, and finally to the back of the foot. The two inner branches, one from each side, unite on the median line, near the trochanter, into one, which descends as far as the popliteal space, where it divides into two branches, which descend behind the tibia, one on each side of the fibula and os calcis; the one going to the side of the foot belonging to B is the longest. The two form a right and left plantar nerve.

“The *phrenic nerves* on the front side were distributed separately to the diaphragm, descending on each side of the pericardium. The posterior pair united on the hinder face of the pericardium, but their distribution was not traced.

“The four *vagus nerves*, two from each head, were kept distinct throughout. The peculiar distribution of the *recurrent* branches will be mentioned further on.

“*Viscera.*—A rather small thymus gland occupied the upper part of the cavity of each half of the thorax, and rose a short distance in the usual place at the base of each neck. Two complete sets of lungs existed, and between them a single pericardium enclosing two distinct *hearts*. These were entirely distinct from each other, but symmetrically developed, or right and left. A single lower *vena cava* entered the pericardium from below, and then entered each venous auricle by separate branches; the same was true of the upper *vena cava*. The venous auricles of the heart were on adjoining sides, and the arterial auricles on the sides most distant from each other. The aorta of the heart of A descended on the right side of the vertebral column of A, and that of B on the left side of its vertebral column; in this case the right aorta, or that of A, was the one transposed, while that of B pursued the ordinary course. The innominate artery of A arose from the left side, and that of B from the right side of the arch. The recurrent branches of the *vagus* were in conformity with

this arrangement. The left recurrent of A and the right of B passed beneath the subclavian, while the right of A and the left of B passed beneath the arch of the aorta.

“A large opening was found in the diaphragm on the right side, and through this the right portion of the liver and some portions of the intestinal canal had passed.

“The *umbilical cord* had one vein and two arteries as usual, the former entering the liver on the median line of the body.

“The *liver* was not quite symmetrical in its shape, having been distorted apparently by the forced position of a part of it in the cavity of the thorax. It consists of three portions, a right and left lobe, each of which corresponds with the right lobe of a normal liver, but one of them is reversed. These unite on the middle line and form a third lobe, which corresponds with the left lobe of the two normal livers fused. Each lateral lobe has a bile duct, gall-bladder and common duct; also a portal vein, symmetrically arranged. A *vena cava inferior* passes up on each side in the notch formed by the union of the median and lateral lobes, but the two unite before entering the pericardium.

“There were two *stomachs*, with their pyloric portions turned towards each other; the great cul-de-sac of that belonging to A was in the right hypochondrium, and therefore reversed, while that of B had the usual position and was in the left. A *spleen* was connected with each. The right and left duodenums came together a short distance from the pylorus and formed a lateral communication, but afterwards separated, and though side by side continued distinct nearly to the cæcum, which, as well as the large intestine, was single. The length of the small intestine was 32 in.

“The urinary organs consisted of two compound kidneys and an urinary bladder with a double cavity. Each kidney had its hilus turned from the median line, was strongly bent on itself, and had a *renal capsule* at each end, so that there were in all four renal capsules. Each kidney also had two ureters, one of them much larger than the other, one set opening into the upper and the other into the

lower cavity of the bladder. This, excepting a constriction near its fundus, had the usual shape; but inwardly the mucous membrane formed a partial partition between the upper and lower portions. The two sets of ureters opened, one just above and the other just below this partition.

“There were two pairs of testes, — one resting on the kidneys or quite near them, and the other just at the entrance of the internal abdominal ring on the front of the fetus. Each testis had an epididymis and vas deferens, but in neither case was it traced to its connection with the bladder. There were, however, to be seen just below the septum of the bladder, mentioned above, three openings, which probably belonged to the vasa deferentia, one pair entering the bladder separately, while the other united and entered through a single opening.

“The descriptions of double monsters by many different observers all show that the tendency is to symmetrical development, so that when an organ ordinarily single becomes double the two organs are always right and left. This is well seen in the specimen just described, in the existence of a right and left heart, right and left stomach, spleen, etc. In the cases where organs, commonly double, are increased in number, we may have either a third organ, or two entire ones. In the first case the law of symmetry is manifest in a most striking manner. For all such third organs, if not compound in structure, are divisible into right and left halves, and half from a different fetus, and repeating each other oppositely. If, however, they are made up of many parts, as a limb, then the individual parts repeat each other in a similar way. In the arm already described, the muscles repeat and balance each other exactly throughout, and the same is mostly true of the legs.

“The force, whatever it be, which regulates the distribution of matter in a normal or abnormal embryo, always acts symmetrically, and if we look for anything among known forces, analogous to it, it is to be found, if anywhere, in those known as polar forces. The essential features of polarity, as in symmetry, are antagonism, either

of qualities or forms. Studying the subject in the most general manner, there are striking resemblances between the distribution of matter capable of assuming a polar condition, and free to move around a magnet, and the distribution of matter around the nervous axis of an embryo.

“In every complete series of magnetic curves there are two neutral lines, one extending lengthwise of the magnet, so that the curves formed are divided into right and left; secondly, a transverse one, the particles on each side of which are known as forming the north and south curves. In the right and left series, those which are on one side of the magnet are symmetrical with those on the other, but not in themselves; and in the north and south series those on either side of the transverse neutral line are symmetrical with each other, but not in themselves. Thus we have in the first case something analogous to right and left or bilateral symmetry, and in the second to fore and hind symmetry.

“If two magnets are placed parallel to each other and at a distance, then two complete sets of curves are formed in the usual way; but if they are brought so as to be within each other's influence, the magnetic figure now becomes a compound one, the central portion of which consists of the united curves from the two adjoining sides of the magnet, and the particles from either series of the curves do not pass beyond the line where the forces of the two magnets are in equilibrium.

“If the magnets are now inclined towards each other so as to touch at one end, having a V-shape, then we shall have the particles arranged so as to produce a figure double in front but single behind. The ends which are separated will arrange the particles so as to form a double series of curves, independent of each other; but as the magnets come nearer together, the curves begin to press against each other, and an intermediate symmetrical figure is formed.

“The distribution of matter in animals having bilateral symmetry, both in normal and abnormal development, is analogous to the series of distributions just described.

In normal development such distribution comprises, first, all that we designate as right and left; second, all that we designate fore and hind, with reference to the ends of the long axis of the body, or to what has been called fore and hind symmetry. In the fully developed animal this last is less easily recognized than the first, but in the embryo it can be traced without much difficulty.

“1st, in the nervous canal, enlarged at either end, the foremost enlargement for the brain, permanent; the hindmost, transitory, except in birds, where it forms the enlargement enclosing the rhomboidal sinus.

“2d, the plates of the vertebral column first appear midway, and are then developed in opposite directions, extending it backwards and forwards.

“3d, in the intestinal canal, with its allantoidian sac, which is respiratory, antagonizing the pulmonary sac, also respiratory.

“4th, in the limbs, which throughout all their earlier stages assume positions strictly antagonistic.

“If on one and the same yolk two nervous axes are formed on opposite sides of the yolk, each will distribute the matter under its influence without coming in collision with that of the other, except near the umbilicus, so that two nearly perfect embryos will be formed.

“If the two nervous axes are formed near to each other, so that the particles under their influence come in contact, then at the line of contact a series of intermediate organs or limbs, as the case may be, under the influence of the two axes, will be formed, as in the specimen described in this paper.

“Furthermore, if the axes are inclined so as to form a V-shaped figure, the two separated ends will have a head more or less complete; but as the two converge, the organs become more or less fused, and at length the hindmost are reduced to the normal type, the intermediate ones having become obsolete.”

893. Double fœtus; in spirit.

- Two heads and spinal columns; one pair, each, of upper and lower extremities, and a third imperfectly developed,

lower extremity arising from the right buttock. Sex, female. Dr. L. reported the weight as about 14 lbs., and the labor premature by about two weeks; one heart, and two sets of lungs; "one stomach, with two œsophagi and two pyloric orifices opening into each contiguous duodenum; two sets of intestines throughout, terminating in an anus for each set; two livers fused, and two sets of pelvic organs." (Med. Jour. Vol. LIV. p. 426.) 1856.

Dr. J. H. Lucas, of Martha's Vineyard.

894. A kitten; entire, and in spirit. Two faces, with one common central eye in addition. Otherwise well formed, externally. Female. 1853.

895. A double kitten; preserved entire in spirit. Integument deficient upon the top of the head, and probably also the brain. Three eyes upon the left side, more or less fused, and none upon the right. 1869.

Boston Soc. for Med. Improvement.

896. Colored drawing, by an artist, of a calf with two heads, two necks, two spines to the sacrum, four extremities; no tail. Otherwise well formed externally; about the usual size of a new-born calf. Sex, female.

Labor exceedingly difficult; four men, with a rope about the calf, and the help of a lever, being at last required to extract it; and even this great force was continued for an hour or more. In four weeks the cow was able to rise without help; and five years afterward, though still lame, she had had three calves at the full period, and got through well, and was then again pregnant. The notes that were taken of the dissection having been lost, it can only be stated that between the scapulæ there was an attempt to form another, as was shown by a small cartilage. For the skeleton, heart, and stomach, see Nos. 897-9. 1853.

Museum Fund.

897. Skeleton of the above subject. Crania not quite symmetrical, but otherwise well. Spines separate and well-developed throughout the dorsal region, except the two last bodies of A (A being the subject on the right, as seen from

behind); spinous processes, also, of the upper half of this region extensively fused. The sacrum, and four last lumbar vertebræ are normal. The next, anteriorly, is one of which the adjoining transverse processes are irregularly developed; in B it joins the last dorsal; but in A, in which the two last dorsal are very imperfectly developed, it joins an additional lumbar. Upon the right of A's spine, and the left of B's, there are fourteen ribs; and between the opposing transverse processes of each dorsal vertebra is a small and irregular bone, which is formed, of course, by the fusion of two ribs. Extremities not preserved. 1853.

Museum Fund.

898. Stomach from the above case. Two œsophagi opening about two inches apart. One paunch, large enough to be formed by the fusion of two. A second cavity of full size, and another quite undeveloped. One third cavity only; and one fourth. 1853.

Museum Fund.

899. The heart, and some of the large vessels from the above case; injected and dried. The heart is single, and appeared externally well formed. The aorta gives off not far above its origin a large and common trunk, that soon divides into the two carotids, and a common trunk for the two subclavians of A. About an inch beyond, it sends off another large branch, about three inches in length, and that divides into the two carotids for B. It then receives the ductus arteriosus, and, two inches beyond, it gives off a branch larger than the last, and more than three inches in length; sending off, then, the left subclavian of B, and soon afterwards two branches to the lung of B. These last must be considered as branches of the pulmonary artery, as this vessel is seen to give off branches that went to the lung of A, but none in the opposite direction. One of the pulmonary veins is seen, and the lower cava; but as to the upper cava there is a question; there must have been two, and one of them may have had an unusual termination. All of the above vessels were dissected in situ, and marked where there could have been any question about them.

Museum Fund.

900. A fœtal duck, entire; in spirit. Two heads almost entirely distinct. Crania and cervical portion of vertebrae deficient as in the acephalous fœtus. 1854.
901. A small "striped snake," with two heads; entire and in spirit. From New Hampshire. 1851.

Dr. William Pitt.

A fœtal kitten, showing a deficiency of the integument upon the top of the head; and of the brain; with three eyes, more or less fused, upon the left side, and none upon the right. 1869. See No. 895.

Boston Soc. for Med. Improvement.

903. A collection of double trout, newly hatched, and having the umbilical vesicle external to the abdomen. From a trout-breeding establishment at West Barnstable. Several of them are united only by the tail, others by the posterior half of the body, and in one there was a central eye that seemed to be composed of a fusion of two; but this last has been accidentally lost. In one a head and portion of a body projected from the side. In one the tail is irregularly malformed; and in several, not preserved, there was a marked curvature of the whole body, so that they swam round in a circle. All of these little fishes were quite lively when first received; and it is stated at the establishment from which they were sent that they generally live until the umbilical vesicle has entered the abdomen, and they begin to take food. Dr. C. observed in more than one case that the action of the hearts in the double fishes was not synchronous. A large number of these double trout have been the progeny of a very prolific individual that is kept in a tank by itself, and has to be fed, as it is perfectly blind, and apparently from cataracts. Double salmon are also met with in the same establishment, and one or two are here shown. 1869.

Dr. Algernon Coolidge.

904. Model of Aké, the Chinese.

The following description of this well-known individual is a summary of one that was published, with a figure, in the third volume of the Philadelphia Jour. of the Med. &

Physical Sciences (1821), by Prof. John K. Mitchell, of Philadelphia, who, when a young man, happened to see Aké, and sent to the Journal, from Canton, a very full report of what he had observed. The description that is recorded in the Catalogue of the Hunterian Museum, and referred to more or less fully by Geoff. St. Hilaire, and others, was by Mr. Livingstone, Surgeon of the British Factory at Canton; but Mr. L. himself never saw Aké, and the artist who was employed to make the model that was sent to England, only made it after he had seen the individual, and, as he said, had carefully examined him. Mr. L.'s description was sent by Prof. M. to the above Journal not long before he sent his own, and was published in the second volume, p. 148.

Aké was sixteen years old, 4 ft. 7 in. in height (Mr. Livingstone says 4 ft. 10 in.), and rather delicate in appearance, though he reported himself healthy. His mother had a tedious labor at the time of his birth, but did well. (Mr. L. says that she survived only two days.) His uncle, who, with him, stated that he was a vigorous infant, and that the parasite, as it has been called (and that may be designated as P.), was nearly as large as himself at birth. It consisted of a neck, trunk, and four extremities; the attachment on the part of P. extending to within 2 inches of the pubes, and on the part of A, from about $1\frac{1}{2}$ in. below the top of the sternum, to about 1 in. above the navel. Length of P. from neck to heel, 31 in.; neck, 2 in.; from base of scapula to top of sacrum, $6\frac{3}{4}$ in.; body and neck, 12 in.; lower limbs, 19 in.; left foot, 5 in.; upper extremities, with hands, $18\frac{1}{2}$ in.; penis, when flaccid, 3 in.; circumference of penis, $2\frac{1}{2}$ in.; pelvis, 18 in.; body above pelvis, 10 in.; upper part of thigh, 11 in.; of arm, 7 in.; elbow, 6 in.; and middle of fore-arm, 3 in. Perpendicular height of adherent surface, $7\frac{1}{2}$ in., and circumference of same, $17\frac{1}{2}$ in. (In a foot-note to Mr. L.'s description in the Hunterian Catalogue, it is stated that Lieut.-Gen. Wood, on careful measurement, found the trunk and neck to be about 11 in., and the longest limb, 13 in.) Its general appearance was meagre, and the hands and feet were cold in the warmest weather (the usual temperature of

both being natural, according to Mr. L.) The limbs, though round and plump at first, became much attenuated toward their extremities. Union face to face; but A could readily turn P. so as to bring its nates (Mr. L. says either side) into contact with his abdomen. These opposing surfaces were excoriated, and required the constant intervention of a roll of cloth to prevent ulceration. There was but one scapula (Mr. L. says two), and that extended across the back to the left shoulder. The spines of three vertebræ were discoverable in the neck, and they were then lost beneath the scapula. Between this last and the pelvis, the back, which was quite soft, sank deeply in, and no vertebræ could be felt. There were the usual number of fingers, but they were very feebly developed. Right foot clubbed (according to Mr. L. they both were), and the left had but three toes. Scapula and humeri so loosely connected with the neighboring parts that they could be moved from the pelvis nearly to the top of its neck. All the joints of the upper extremities admitted of a limited motion (Mr. L. says free). The lower extremities, however, were stiff, and the hips probably anchylosed. A. and his uncle said that when he was four or five years old he could move these; and he could also move the upper extremities. His mother, however, passed a string about them, and over the neck, to protect them from injury; and, the heels being brought nearly into contact with the nates, excoriation ensued, followed by adhesion of the calf of the leg to the back of the thigh, and loss of motion at the knee-joints. About two years before Prof. M. saw him, P.'s left humerus was broken, by a fall from a buffalo, but it had united firmly.

The penis, 3 in. in length, as above stated, enlarged during erection, and the scrotum "might have contained the testes of a vigorous adult." No testes, however, were found in it; though there seemed to be one at the left abdominal ring, as shown by a tumor there, and the peculiar pain that was caused by pressure upon it. (Mr. L. says that there was no vestige of the testes, and very little scrotum.) There was a congenital phymosis, but the glans was in a natural condition, and a mucous secretion was

emitted *guttatim*. There was never, however, as the lad said, a discharge of semen or of urine. (Mr. L. says, however, that the kidneys of P. seem to perform their function perfectly; and states that Gen. Wood examined the pair with great attention at his own house, and saw them urinate simultaneously. This last very important statement is recorded in a foot-note to Mr. L.'s description, as published in the Philadelphia Journal above referred to; but in the note to the description in the Hunterian Catalogue, and in which Lieut.-Gen. Wood's measurements of Aké are given, nothing is said of the urine.) Erection of the penis took place when excited by imagination or irritation; but, when from this last, the penis of A did not become erect.

The pelvis was large and well formed, the nates plump and prominent, and in the place of the anus there was a deep dimple. The nipples of P. were not more than $1\frac{3}{4}$ in. from the "anter. super. spine of the ileum;" and those of A were on a line with the shoulders of P. This last had no vestige of a navel; in the case of A. there was an appearance of its having been double, but that was owing, it was said, to the excoriation above referred to.

The abdomen and thorax of P. seemed to form one large muscular sac, two-thirds of which were united on the sides to ridges, probably of bone, that arose from the front of A. "Within the area bounded by this ridge, there appears to be a vacuity in the bony structure of the chest of Aké, and it seems probable that if the two chests do not form one cavity, they are only separated from each other by soft parts;" and "when the lad coughs or breathes the sac of the parasite is puffed up like a bladder."

There was no sign of a heart in P., and pulsation was only obscurely felt in one place; that was in the femoral artery, and it was synchronous with the radial pulse of A.; 90 in the morning, and increasing gradually to 115 towards night. (Mr. L. says that pulsation had been distinctly felt in the carotids; but Prof. M. made a most careful search, and could find nothing of it.)

Prof. M. says that the body, and especially the neck of P. is acutely sensible, but he strongly denies, on the au-

thority of A., the statement of his keepers, that when any part of P.'s body is pinched, the corresponding part of his own feels a sensation. This seems altogether improbable, and yet Mr. L. says that the experiment was tried, and "the statement most satisfactorily confirmed by an ingenious medical gentleman." 1847. *Dr. J. C. Warren.*

905. Cast, in plaster, of a child, from the right hypochondrium of which there arise one upper and two lower extremities, that are largely, and apparently well developed, excepting a deficiency of the fingers. The lower part of the trunk of the dependant seems also to have been considerably developed. The child itself is 22 in. long, and otherwise well formed externally. So far as it can be ascertained, it came from Canada, was exhibited in New York in 1858, and died of pneumonia at the age of $4\frac{3}{4}$ months. It was bright and vigorous, and the adventitious limbs had the power of motion. It was said that there was an anus, and a penis, with excretions, but this statement was contradicted. Case never published, so far as known. 1861.

Museum Fund.

906. Photograph of a child, seven months old, that had a large congenital tumor attached to the cheek, and in which were found the organs of a second child.

Prof. Joseph Pancoast, of Philadelphia, who removed the tumor, and sent the photograph to Dr. W., stated to him in a letter, dated Dec. 7th, 1859, as follows:—

"I find a rudimentary bony pelvis and limbs, a large stomach and large intestine, the latter having striped muscular fibres at its lower end, and terminating in a cul-de-sac. The stomach and intestinal canal communicated by three orifices with the external air; and a tubular process of the buccinator muscle of the perfect child (which is now well and hearty) seems to have been employed to pump the air through these orifices into the hollow viscera. The absorbent glands were numerous and large. It had an independent growth of its own, and was growing, at the time I removed it, at a faster rate than the perfect child."

This case has never been published, though Prof. P.'s clinique upon the subject was reported in the Philadelphia Med. & Surg. Reporter, March, 1859; and from this last the following extracts are made: Tumor nearly a foot in length, and divides upon the surface into several globular masses, with fingers and a rudimentary forearm. Intestines covered by skin, but at birth by a membrane like the peritoneum. Parasite separated from the child by a peculiar, caul-like membrane. Pulsation distinct, from 40 to 100 per minute, and not synchronous with that of the child's heart. Removed by the *écraseur*. Weight nearly $2\frac{1}{2}$ lbs. In structure, it looked like a fatty tumor, with the parts of a *foetus* superadded. A body, regarded as a heart, contained imperfectly formed auricles and ventricles. Mesenteric arteries and veins large. About 18 in. of intestine, and ending in a *cul-de-sac*. Meconium mixed with a large amount of adipose matter. There was also a liver, a large nerve running through the mass, appearances of a bladder and urachus, a penis or clitoris, and externally an umbilicus. 1860. *Dr. J. Mason Warren.*

907-8. Thibert's model, showing the external appearances, in Velpeau's case, of a congenital scrotal tumor, that contained foetal bones, hair, etc. (See V.'s *Clinique Chirurg.* Vol. III. pp. 198-217.) A model of a cyst, containing hair, is also shown; from the same. 1847.

Dr. G. Hayward.

909. Photograph of a man with three lower extremities, and in whom the penis is double. See Dr. Geo. G. Fisher's *Essay on Compound Human Monsters* (Albany, N. Y., 1866), London *Lancet*, July 29, 1855, and *Med. Chir. Trans.* Vol. XXIX. p. 103. 1860. *Dr. Geo. A. Bethune.*

910. A newly-hatched chicken, entire, and in spirit. Two additional lower extremities grow from the pelvis; thighs united, but separate below. 1865.

Boston. Soc. for Med. Improvement.

911. A supernumerary thumb, about half as large as the thumb itself, and that arose from over the metacarpo-phal. articu-

lation. It stood off at nearly a right angle, and consisted of two phalanges, between which there was scarcely any motion, though there was more at the base. The last phalanx forms an acute angle with the first. Removed by cutting through the bone near the base. The patient was twenty years of age (Hosp. 141, 13). There is a cast of the hand, taken before the operation, in the museum of the hospital. 1869. *Dr. H. J. Bigelow.*

912. The hands and feet from a monstrosity. Each has six digits, and they are all fully developed, and symmetrically placed; excepting the additional finger upon the right hand, and that arises from over the outside of the metacarpal bone. 1863. *Dr. J. Wyman.*

913. The right upper and lower extremity of a mature fœtus, showing additional toes as in the above right hand and foot. 1867.

914. A fœtus, of about three and one-half months; six digits on each hand and foot. 1857. *Dr. H. J. Bigelow.*

915. Casts, in plaster, by Dr. P., of the two feet of an infant, nine months old, showing an additional well-developed, but rather unsymmetrical great toe. Also of the two little fingers, over the outer edge of the middle joint of which a little bud shows the attempt to form an additional finger. 1866. *Dr. Calvin Pratt.*

916. A "double pig's foot;" left side; fore leg; dried; "dew-claws" formed as usual. Upon the inner side are two additional toes, apparently upon one metacarpal bone, and very much smaller than the two others. 1865. *Mr. Charles Atwood.*

917. Cast, in plaster, of the hand, and part of the forearm of an adult, showing seven well-developed and well-formed fingers, but no thumb.

Of the carpal bones, the trapezium and naviculare were wanting; and in the forearm there were two ulnæ, but no radius. One of the ulnæ was $8\frac{1}{2}$ in. long, and well formed: but the other, at the upper extremity, was quite irregularly

developed. Humerus, 10 in. long, and the scapula irregularly developed. The central, or index finger, which was of the usual size, received two extensor muscles; the malformation being regarded as a fusion, by the radial edge, of two extremities.

The subject of this case was a machinist, and otherwise well formed. Dr. F. S. Ainsworth made a preparation of the extremity, showing the muscles and arteries as well as the bones (No. 156 in the Med. Soc.'s Cabinet), and described the same very fully in the *American Jour. of Med. Science*, for January, 1853. The cast was made by Mr. S. *Mr. Albert F. Sawyer, med. student.*

918. Legs of a chicken, showing an additional thumb. Several specimens. 1851. *Dr. J. B. S. Jackson.*
919. The large claw of a lobster, of which the small or terminal phalanx shows a strong attempt at duplication. 1865. *Dr. Wm. E. Townsend.*
920. A portion of the cranium, with the four horns, of a four-horned goat. From Switzerland. 1866. *Dr. H. J. Bigelow.*
921. Cast, in plaster, showing a congenital and great enlargement of the middle finger of the right hand; with a slight enlargement and lateral divergence of the index and ring fingers. The finger was amputated by Dr. B., and the head of the metacarpal bone removed; the adjoining fingers becoming afterward quite closely approximated. 1856. *Dr. H. J. Bigelow.*
922. Cast of the left hand, which is of the usual size. 1856. *Dr. H. J. Bigelow.*
923. The finger itself above referred to. From a Hospital patient, a girl, æt. 17 (45, 150). 1856. *Dr. H. J. Bigelow.*
924. Cast, in plaster, of the hand and forearm, from a second case similar to the above. The middle finger was $5\frac{3}{4}$ in. long, $4\frac{5}{8}$ in. in circumference midway, and its extremity

curved round over the ring finger. Index finger, also, somewhat enlarged; and there is a congenital and very marked, though nowhere abrupt, enlargement of the forearm; the circumference being 4 in. greater than that of the opposite side. Finger amputated by Dr. B., with the head of the metacarpal bone. 1862.

Museum Fund.

925. Finger last referred to. From a young man, æt. 19; Hospital (105, 128). 1862. *Dr. H. J. Bigelow.*

Mr. Annandale remarks (Malformations of the Fingers and Toes), that the above malformation generally attacks one or more of the fingers, and that it "may be associated with a similar condition of the whole upper extremity." In two other cases that have been observed here, the middle finger only was affected. See Mr. Curling's illustrated paper in the *Med. Chir. Trans.* Vol. xxviii. p. 337.

926. Two "double peaches;" in one they are of equal size, but in the other specimen one of them is quite small. 1855.

Dr. J. B. S. Jackson.

927. A double tomato. 1856.

John Feenan, ward-tender at the Hospital.

928. A double grape. 1862.

Mr. F. H. Jackson.

929-30. A double peanut and filbert. 1866.

Mr. J. Whipple, med. student.

SERIES XIX. — MISCELLANEOUS SPECIMENS.

Renal capsules, in the fœtus. See No. 694.

Ditto, in the acephalous fœtus. See No. 840.

Ditto, in the absence of one kidney. See No. 703.

Fusion of the renal capsules. No. 829.

Spleen ; wax preparation. See No. 324.

931. Supplementary spleen, about the size of a small marble.
1867. *Dr. J. B. S. Jackson.*

932. Spleen, deeply fissured, from an adult. 1867.
Dr. H. A. Martin.

933. Three spleens ; from an "acephalous foetus," sent by Dr. A. One is of medium size, and the two others smaller, but much larger than the "supplementary spleens" usually are. 1863. *Dr. I. Allen, of Roxbury.*

934-7. The following French preparations were presented by Mr. C., Professor of Chemistry, in 1852 :—

1st, Margarine.

2d, Margaric acid.

3d, Stearine.

4th, Stearic acid.

Prof. Josiah P. Cooke.

SECOND DIVISION.

MORBID ANATOMY.

SERIES XX.—BONES.

I. FRACTURES.

938-9. Longitudinal section of six dorsal vertebræ, showing a fracture of the body of the fourth or fifth. The upper edge is broken off, and perhaps all around, and lies now rather in front of the body, as in No. 140 in the Med. Soc.'s Museum; thus allowing a backward displacement of the body. The thickness of this last is very much diminished, but, as it would appear, rather by an absorption than by a crushing down of the cancelli; and the same change seems to be going on in the body of the vertebra below. Antero-posterior curvature moderate. A dry specimen.

The other half of the same, in spirit; to show the spinal marrow and membranes, which, so far as appeared externally, were quite uninjured.

From a woman, æt. twenty-five years, who fell 15 ft., and seventeen days afterwards entered the Hospital (114, 82). Lower extremities paralyzed, and sensibility diminished. Pain passing up leg on pinching left instep; with the feeling as of an electrical shock when ice was applied to right foot and leg. Dej. involuntary, and catheter regularly required. Sank, with bed-sores and diarrhœa, and died rather less than nine weeks after the accident. 1864.

Dr. R. M. Hodges.

940. Fracture of the spine.

The patient was a sailor, twenty-four years of age, who fell 50 ft. on board of a vessel, and lived nearly seven weeks after the accident, under the care of Dr. G., at the Marine Hospital.

There was throughout a complete loss of the power of motion, and of sensation, excepting some indistinct sense of feeling toward the last. Urine retained for the first day or two, but ever afterward discharged involuntarily, as were the fæces. Urine also strongly ammoniacal, and mixed with pus. The man only complained of pain in his back when he was moved, and then not urgently. Bed-sores soon began to form, and became large and numerous before death; and the emaciation was very extreme. Four dorsal and one lumbar vertebræ having been removed, and prepared in connection, by Mr. Charles S. Wood, a student of Dr. G., it is seen that the body of the eleventh dorsal is very extensively fractured, and the curvature is such that the body of the tenth must be within one-third of an inch, or less, of the first lumbar. There is much new bone about the bodies of the three last dorsal vertebræ anteriorly, but scarcely any posteriorly. Laminae of the eleventh broken away from transverse processes. Spinous processes in line, but that of the tenth is broken and comminuted. Eleventh rib broken upon each side, near the spine, but partially united. 1869.

Dr. J. W. Graves, of Chelsea.

941. Several vertebræ, separated by maceration, and showing an extensive fracture of the first lumbar.

From a girl, æt. 19, who jumped 20 ft. from a building, when on fire, and struck upon the nates. Immediate paralysis of the lower extremities and sphincters followed, with insensibility. Three weeks afterward, when she entered the Hospital (39, 132), there was sensibility, with some power over the sphincters, but a very marked projection of the vertebræ. Also much pain in legs from the time of the accident. Lived about nine months, and died of phthisis.

The whole upper edge of the first lumbar vertebra was broken off, and, from the curvature that ensued, it has come nearly into contact with the body of the second. The body is almost split through vertically, from back to front; the anterior face is forced backward by the body of the last dorsal that lies upon it, and the back part of the body en-

croaches very greatly upon the spinal canal. The body of the last dorsal is also broken about two-thirds through from behind forward; but without any diminution of its thickness. The different parts of the first lumbar are consolidated; but there is nowhere any new growth nor appearance of inflammation. Prepared by Dr. Hodges. 1857. *Dr. H. J. Bigelow.*

942-3. Two casts, in plaster, of the back, from a case of fracture of the spine, with final recovery.

The patient, a sailor, æt. eighteen years, fell 60 ft. from the mast-head of a vessel, and struck upon his back. The accident happened Sept. 19th, 1866, and he was carried to the Hospital at once (127, 146). Back bowed as though the bodies of the vertebræ were broken anteriorly.

He was in great pain, but could move his legs, and had sensibility in them. On the 20th the record was: "Both extremities natural as far as motion and sensation are concerned." Bladder not very full, but the catheter was used. 21st: "Motion and sensibility of legs still good." Urine normal. 22d: Same record of extremities. 2 dej. after enema, and one involuntary in night. 23d: Urine drawn much oftener, and as cloudy. 24th: Frequent desire to micturate, but is unable to do so. Catheter; and left in. 25th: "No apparent loss of power or sensation in lower extremities." Tender between last dorsal and first lumbar vertebræ.

Oct. 4th: "Can move himself about in bed." Scalding pain in urethra during micturition. 8th: Sits up with help. Distinct curvature from 3 in. below scapulæ to upper edge of pelvis, but without any distinct local depression or prominence. No marked local pain on pressure. Urine ammoniacal.

Nov. 10th: Walks about without difficulty, and general condition is good. On the 25th the casts were taken by one of the hospital pupils. Right thigh below the buttock less sensitive to temperature than the left. Upon the back of the right thigh the minimum distance at which the points of a pair of compasses appear as two distinct points is 3

in., and upon the left it is half an inch. On the 26th he was discharged, well.

The case thus far was published in the *Med. Jour.* (Vol. LXXVI. p. 390), by Dr. Geo. H. Gay, who had charge of the patient until the 1st of Nov.

From the Mass. Gen. Hospital he went directly to the Marine Hospital at Chelsea, where he was under the care of Dr. Graves. On admission he walked with crutches, but on the 10th of January he could walk very well without even a cane, and he continued to improve until he left the hospital, on the 23d of March. 1867.

Dr. H. J. Bigelow.

944-5. Two casts of the back, from the above case, taken after the man had been for some time at the Marine Hospital, and showing a great diminution of the curvature of the spine.

As in the case of the two first casts, one was taken whilst the patient was sitting up, and the other as he was lying down; the curvature being most marked in the first. 1867.

Dr. John W. Graves.

946. The fifth lumbar vertebra, from a Flat-Head Indian, showing an entire separation of each lamina from the body of the bone between the two articulating processes, and also of the laminae from each other, upon the posterior median line. The first is regarded by Dr. J. Wyman as the result of an old and undescribed form of fracture; and in the *Med. Jour.* (Aug. 12th, 1869), he has reported eleven cases of the same, that he has seen; to which might be added that of Dr. John C. Warren, the founder of the Museum.

Dr. W. says that this fracture is "often noticed in the preparation of skeletons," that it has only been observed in the fourth or fifth lumbar vertebra, and that in one subject he found it in both of these bones. He thinks that it cannot be a malformation, and the result of an arrest of development, as the separation of the fragments is not where it should be in that case; and yet there is an uniformity in the appearance of the bones, and an absence of

anything like comminution, that at once suggests the idea of malformation. In the present case we must suppose, if the laminae were broken upon the sides, that they were broken also, and most symmetrically, upon the posterior median line. 1862. *Museum Fund.*

947. A deep incised wound in the body of the first dorsal vertebra.

From a young man who was stabbed in the middle of the right side of the neck, with a broad and sharp knife. The hemorrhage, which was very copious, was arrested; the common carotid being tied, though it was subsequently found uninjured. After this he rallied well; but on the second day phlegmonous inflammation came on about the wound, and he died seventy-eight hours after the injury. (Med. Jour. Vol. LXIX. p. 98.) Vertebrae prepared by Dr. H., and dried. 1863. *Dr. R. M. Hodges.*

948. The fifth and sixth cervical vertebrae, entirely separated, but not dislocated, and with only a trace of fracture.

From a man who was struck upon his breast, and thrown upon his back, when attempting to get upon the front platform of a horse-railroad car. Lived rather more than three days. Hospital, 97, 62. 1861.

Dr. George H. Gay.

949. Cranium of a man who lived twelve and one-half years after the passage of a large iron bar through his head.

The subject of this case was twenty-five years of age, of a strong constitution, and in vigorous health, and was engaged in blasting rocks, when the charge exploded. The bar, with which he was ramming or tamping it down, having been driven through his head, was thrown high into the air, fell at a distance of some rods, and was picked up smeared with blood and brain. The accident happened in the State of Vermont, Sept. 13th, 1848, and an account of the case was first published by Dr. Harlow, in the Boston Med. & Surg. Jour. in Dec. (Vol. xxxix. p. 389).

In a few minutes he recovered his consciousness, was put into an ox-cart, and having been carried three-fourths of a

mile to his hotel, he got out with some assistance, and entered the house. Two hours afterward, when he was seen by Dr. Harlow, he was quite conscious and collected in his mind, but exhausted by a profuse hemorrhage from the top of the head; the scalp being everted, the bones very extensively fractured and upraised, and the brain protruding. In front of the angle of the lower jaw, upon the left side, was a linear wound through which the bar had entered, by the pointed end. There was a protrusion of the left eye, equal to nearly one-half of its diameter; and the left side of the face was more prominent than the right. With a view to the presence, possibly, of any foreign bodies, Dr. H. passed one index finger down its whole length into the wound from above, and the other freely upward from below. Frequent vomiting of blood from the stomach. The pulse at this time was 60.

On the 15th the hemorrhage had ceased; vision of the left eye was indistinct, and there was delirium. On the 16th a fetid discharge, with particles of brain, from the head; with a discharge also from the mouth. 23d: More rational, stronger, and asked for food. Vision in left eye quite gone. Pulse 60-84 since the accident. On the 24th erysipelas appeared below the wound; and for the next three days he was more comatose, with a large fungous growth from the upper wound, and a fungus from the inner canthus of the eye, that first appeared on the 19th. 27th: Discharge from the upper wound small, and exhalations from the mouth horribly fetid. The large fungous growth was excised, and $\frac{3}{4}$ viii of pus were discharged by incision over the lower part of the frontal bone. Eye very prominent. The discharge after this was profuse and fetid. Oct. 6th he was better locally and generally, and sat up for a few minutes, but appeared demented. Nov. 8th he was in every way doing well, and went abroad. On the 14th he walked half a mile, exposed to dampness and cold, and there followed a febrile attack, with lancinating pain in the left side of the head and face. For this he was bled and purged; and on the 18th he was about the house again. On the twenty-fifth, about seven weeks and a half after the

accident, he returned home, a distance of about thirty miles.

January 1st, 1849, the wound was quite closed. In April the left malar bone continued to be more prominent than the right. The eye, however, was less prominent than it had been; but the motions of the globe were limited, and there was ptosis of the lid, with a partial paralysis of the left side of the face. Upon the top of the head was a quadrangular prominence, and behind this a deep depression. No pain, but a queer feeling in the head. In regard to the state of his mind, he was very fitful and vacillating, though still very obstinate, as he always had been; and he was very profane, though never so before the accident.

After his recovery he travelled about with his bar, and exhibited himself in several of the large cities in this country; and in 1851 he got a situation, as a hostler, in a stable. In August, 1852, he went to S. America, and drove a six-horse stage-coach in Chili. In 1859 and '60 his health began to fail, and early in 1860 he had a long sickness, but no particulars could be learned in regard to it. In June, 1860, he went to San Francisco, where his friends were residing; and as his health improved, he went to work upon a farm. In February, 1861, he had a fit, and soon two or three others. He had been ploughing on the day that he was attacked, and had had no premonitory symptoms. In a few days he was better, and did at different times various kinds of work. On the 20th of May he was attacked with severe convulsions, which recurred frequently; and on the following day he died.

In July, 1866, Dr. Harlow ascertained that his patient's mother was residing at San Francisco; and after a correspondence with her, and other members of the family who were with her, he not merely obtained the final history of the case, but in the most commendable spirit, and with a full appreciation of the scientific interest of the case, permission was given to have the cranium removed, and sent here for examination and preservation. In effecting this very desirable object, he was aided by D. D. Shattuck,

Esq., a brother-in-law of his patient, Dr. Coon, Mayor of the city, and Dr. J. D. B. Stillman, all of San F.

The cranium arrived in this city, with the bar, in 1868, and have been most generously presented, by Dr. Harlow, to the Mediçal College.

On examination of the cranium, it is generally, though not always, possible to distinguish between the bones that are gone, as the result of the injury, and those that have crumbled away and been lost since the man's death; the smoothness of the edges determining this point for the most part. The whole of the small wing of the sphenoid bone upon the left side is gone, with a large portion of the large wing, and a large portion of the orbital process of the frontal bone; leaving an opening in the base of the skull, 2 in. in length, 1 in. in width, posteriorly, and tapering gradually and irregularly to a point anteriorly. This opening extends from the sphenoidal fissure to the situation of the frontal sinus; and its centre is an inch from the median line. The optic foramen, and the foramen rotundum are intact. Below the base of the skull the whole posterior portion of the upper maxillary bone is gone. The malar bone is uninjured; but it has been very perceptibly forced outward, and the external surface inclines somewhat outward, from above downward. The lower jaw is also uninjured. The opening in the base above described is continuous with a line of old and united fracture that extends through the supra-orbitary ridge, in the situation of the foramen, inclines toward, and then from the median line, and terminates in an extensive fracture that was caused by the bar as it came out through the top of the head. This fracture is situated in the left half of the frontal bone, but, inferiorly, it extends somewhat over the median line. In form it is about quadrilateral; and it measures $2\frac{1}{2} \times 1\frac{3}{4}$ in. Two large pieces of bone are seen to have been detached and upraised; the upper one having been separated at the coronal suture from the parietal bone, and being so closely united that the fracture does not show upon the outer surface. The lower piece shows the line of fracture all around. Owing to the loss of bone, two openings are left in the skull; one, that separates the

two fragments, has nearly a triangular form, extends rather across the median line, and is 4 in. in circumference; the other, situated between the lower fragment, and the left half of the frontal bone, is long and irregularly narrow, and is $2\frac{3}{8}$ in. in circumference. The edges of the fractured bones are smooth, and there is nowhere any new deposit. 1868. *Dr. John M. Harlow, of Woburn.*

For the bar above referred to see No. 3106.

950. A cast of the head of the above individual. Soon after Dr. H. published the case, Dr. Bigelow wrote to him, and made arrangements, at a very considerable expense to himself, to have the man sent down to this city, and kept here for a full examination. After he had satisfied himself that the bar had actually passed through the man's head, and that he had essentially recovered from the accident, he was exhibited to the profession, the cast was taken, and a full account of the case, with illustrations, was published by Dr. B., in the *American Jour. of Med. Sciences*, July, 1850. 1856. *Dr. H. J. Bigelow.*

The very small amount of attention that has been given to the above wonderful case, by the profession in this country, as well as in Europe, can only be explained by the fact that it far transcends any case of recovery from injury of the head that can be found in the records of surgery. It was too monstrous for belief, and yet Dr. Harlow has at last furnished evidence that leaves no question in regard to it.

951. A skull that was prepared by Dr. B., to show the course that the bar was supposed to have taken. 1856. *Dr. H. J. Bigelow.*

952. Cast of the head of a man who was transfixated through the head by an iron gas-pipe, and who, to a very considerable extent, recovered from the accident.

The accident happened in the State of Ohio, May 14th, 1867, and the following is an abstract of the case, which was reported to Dr. Bigelow by the attending physicians, Drs. M. Jewett and F. W. Inman. The patient, a healthy and intelligent man, about twenty-seven years of age, was

blasting coal, when the charge exploded unexpectedly, and the pipe was driven through his head, entering at the junction of the middle and outer thirds of the right supra-orbital ridge, and emerging near the junction of the left parietal, occipital, and temporal bones. One of his fellow-miners saw him upon his hands and knees, and struggling as if to rise; and, going to his assistance, he placed his knee upon his chest, supported his head with one hand, and with the other withdrew the pipe. This last projected about equally from the front and back of the head; and much force was required for its withdrawal. On being raised from the bottom of the shaft, which was about 100 ft. deep, he shivered as if he was very cold, groaned heavily, put both hands to his forehead, shook his head deprecatingly when spoken to, but moved his lips.

Three hours after the accident Dr. I was called, and found him comatose, and in a state of collapse; pulse 35, and weak; respirations nine per minute, and every breath seemed as if it would be the last. The right eye protruded half an inch, and blood, mixed with portions of brain, was oozing from the anterior wound, which was smooth, and about large enough to admit the index finger; the hemorrhage, however, being inconsiderable, though free at first. Posteriorly the opening was much larger, and the bones protruded; the extent of the fracture being about 3 in. The gas-pipe (No. 3107.) was shown, and about one-half of it was smeared with blood and brain; 4 ft. 2 in. in length, and $\frac{5}{8}$ in. in diameter. Some spiculæ of bone were removed from the back of the head; the free use of stimuli was ordered, with cold to the head, and warmth to the extremities. On the 16th his breathing was stertorous, with a pulse of 40; and calomel with podophyllin was given, with beef-tea. On the 17th there was some reaction; and as the medicine had had no effect, it was repeated, and, after an enema, free catharsis followed, with a tænia, 17 ft. long. On the 19th he was more restless, and, as it was difficult to keep him in bed, tart. antimony, with opium, was given.

In a very few days he began to swallow what was put into his mouth; about the twelfth day he began to take

food freely, and in about three weeks from the time of the accident he ate voraciously. A pint of whiskey was given daily for the first five days, and on the 19th reaction commenced, with a pulse of 80. If he did not want food or whiskey, he would roll over and turn away. For six weeks the discharges from the bowels and bladder were involuntary. In seven weeks he sat up, and in one more he walked about a little. The right hand he used somewhat, but less well than the left. For about ten months after the accident his memory for some things was nearly lost, but during the next two months there was a considerable improvement.

When he was first seen, a probe, 4 in. in length, was passed into each of the wounds as far as it would reach, and without obstruction; and the chief point in the treatment consisted in the frequent passage of the probe, with a view to keeping the openings perfectly free. During the first ten days the probe was passed its whole length, and daily. If the orifices, and especially the posterior one, were at any time obstructed by a plug of brain, the coma would very much increase; and by shaving it off repeatedly, and passing the probe, the relief would often be very great. The discharge from the back wound was very considerable; and, as it became quite offensive, injections of chlorate of potash were frequently used. On the sixth day there was a slight ptyalism, and this Drs. J. and I. thought may have tended to prevent secondary inflammation.

Dr. Jewett visited Boston with the patient, at the invitation of Dr. Bigelow, and kindly presented to him the gas-pipe, and transferred to him the case, with liberty to make such use of it as he should see fit. Dr. B. exhibited the patient, with the gas-pipe, to the Mass. Medical Society, at their annual meeting in June, 1868, and then added the pipe to his collection in this museum; the cast being taken subsequently. The man appeared to be in a good state of general health; and, though his mental powers were considerably impaired, there was nothing unusual in his expression, nor would there be noticed, in a few minutes' conversation with him, any marked deficiency of intellect.

He had done no work, however, since the time of the accident, and he had not fully recovered the use of his eye, nor of his right hand. Above the eye there was a small cicatrix, and a slight irregularity to the feel of the surface of the bone. Posteriorly there was a depression, quite defined, and nearly large enough to admit the top of the index finger, but without any elevation, or irregularity of the surrounding bone.

Drs. Jewett and Inman delivered to Dr. Bigelow, with their report, the statements of different physicians who saw the man with them, and no one of whom had the slightest doubt of the main fact in the case. Statements also were given by different non-professional persons. After Dr. J. returned to Ohio he sent to Dr. B. the hat that his patient wore at the time of the accident, and in it are holes corresponding to the openings in the skull. 1868. See No. 3107. *Dr. H. J. Bigelow.*

953. A skull, fractured so as to separate the whole anterior half from the posterior; the bones being also separated to some extent at the coronal suture. 1847.

Dr. J. C. Warren.

954. A second specimen, in which the whole of the left side is beaten in. The patient fell from the top of a house. 1847.

Dr. J. C. Warren.

955. Top of the skull, showing a fissure through the parietal bones; and upon one side it may have extended to the base. Bones separated at the coronal suture, as in No. 953. Trephined. 1847.

Dr. J. C. Warren.

956. Top of the skull, showing an extensive and comminuted fracture.

From a laborer, who was struck with the point of a pickaxe, in a fight, and lived about four days. Very drowsy. Quite conscious when first seen, without palsy, and with a pulse of 44; pupils acted. Several pieces of bone removed at the hospital (125, 164) by Dr. C.; and these, having been with the other fragments dried

in place by Mr. John Green, one of the house-pupils, have been colored so as to be designated. On dissection, lymph and pus were found beneath the dura mater, but no laceration nor inflammation of the brain itself. 1866.

Dr. H. G. Clark.

957. A portion of the frontal bone, showing a very extensive fracture.

The patient, a boy, æt. 13, fell from the roof of a house; and, when brought to the hospital (138, 88) there was great depression of, and just above, the nasal bones — “the nose seeming to have been driven into the face.” He was very nearly senseless, and otherwise severely injured. The depressed bone was raised by Dr. Hodges, and the patient lived until the tenth day; consciousness remaining, more or less, until the last thirty hours. The nasal, and small portions of the adjoining bones were found completely detached, but still connected together, as shown in the preparation. The body of the sphenoid is also seen to have been broken. The fracture extended through the base of the skull, to the occiput, and there was some separation of the lambdoidal suture, with a separate fracture upon one side of the head. Pus was found beneath the dura mater, along the longitudinal sinus; and extensive softening of the cerebellum. 1868.

Dr. G. H. Gay.

958. Top of the skull, showing a very extensive and comminuted fracture, with fissure, and looking as if it may have been caused by blows with a hammer. Injury of the inner table very extensive.

A hospital case (117, 234), and carried there at once. The man was perfectly conscious on admission; and described a murderous attack that had been made upon him. Scalp much bruised and lacerated. Brain oozing out above right ear. Pupils natural. Very cold and almost pulseless. On the third day about the same; mass of brain discharged as large as the top of the thumb. Became unconscious that night, and remained so until he died, on the sixth day. Left side palsied, and pus issuing

from above the ear. On dissection, a large fragment of bone was found driven into the brain near the right ear; this being replaced in the preparation. Some coagulated blood about the membranes; and pus over the arachnoid. 1865.

Dr. H. J. Bigelow.

959. Fracture, with wound of the lateral sinus.

The patient, a boy, fifteen years of age, had been struck by a heavy plank, and was carried at once (July 18th) to the hospital (132, 126). Scalp wound to the extent of 2 in. behind the right ear, with much hemorrhage; but he had his consciousness. Wound enlarged; and, a depression being found upon each side of the occipital suture, one large triangular piece of bone was removed, and several smaller ones. The opening in the sinus was about $\frac{1}{4}$ in. in length, and the hemorrhage from it profuse. On the 29th there was a hemorrhage to the amount of ℥xij. ; and another of ℥viiij. ; on the 30th one of ℥iij. or iv. ; on the 31st one of ℥vj. ; and on the 1st of Aug. he died without cerebral symptoms.

The opening in the skull was of an irregularly triangular form, about 2 in. x $1\frac{1}{2}$ in. The sinus traversed it horizontally; and the opening in it, enlarged by inflammation and sloughing, was $1\frac{1}{4}$ in. in length, contained no clot, and was smooth and perfectly healthy in appearance upon its inner surface. The dura mater, so far as exposed by the fracture, was covered with pus and inflammatory deposits, but upon the inner surface it was healthy, though discolored. Some effused blood, however, was found upon the opposite side of the head, between the dura mater and the bone; an abscess in the muscles, at the lower part of the wound, and a fissure in the skull, an inch in length, extending from the seat of the fracture nearly to the foramen magnum.

In the preparation, the fractured bone with the dura mater, and the wounded sinus have been dried. 1867.

Dr. R. M. Hodges.

960. Portion of the skull, fractured by a slung-shot.

From a healthy man, æt. twenty-one, who received the in-

jury on the 4th of May, and entered the hospital on the 7th (125, 236). On admission his pulse was 60. Pupils contracted; and there was deafness, stupidity, inability to protrude the tongue, and a miscalling of words. On the 11th and 12th there was a convulsion, and he was then trephined. The fracture was beneath the temporal muscle, which was much lacerated. Bone depressed in a perfectly regular concavity, outside of which there was no radiation of the lines of fracture, and within which there was much comminution. Inner table more extensively broken than the outer, and dura mater ruptured to the extent of $\frac{3}{4}$ in.; a meningeal artery requiring ligature. The pulse rose during the operation from 48 to 135; and the pupils, that had been sluggish, acted promptly as soon as the compression was removed. On the 21st of June the man left the hospital; and on the 18th of July he resumed his work. 1866.

Dr. R. M. Hodges.

961. A skull, showing an extensive fracture of the left parietal bone, and extending through the temporal and sphenoid bones into the basilar portion of the occiput.

The parietal foramina are quite large in this specimen. 1847.

Dr. J. C. Warren.

962. Fracture of the base, from side to side, and across the sella Turcica. 1859.

Dr. C. Ellis.

963. Frontal bone, showing upon the outer surface a defined, circular depression, about $\frac{3}{4}$ in. in diameter. The result of some old injury; perhaps from the thrust of some blunt-pointed instrument, or from a spent ball. Corresponding internal surface thrust inward. 1847.

Dr. J. C. Warren.

964. Top of the skull, showing an oval depression of the right parietal bone, larger than a silver dollar, and with two superficial fissures running off from it. Entirely co-ossified. Inner table projected into cranial cavity, with well-marked ridges. From a man over fifty years of age. 1859.

Dr. R. M. Hodges.

965. Portion of a skull, showing a very defined fracture, just upon the limits of the right mastoid process, very nearly an inch long, about half an inch wide, comminuted, and somewhat depressed. Inner table also comminuted, and the fragments somewhat driven in. A fissure also extends to the foramen magnum.

The patient, æt. forty-one, was accidentally shot, and entered the hospital at once (41, 170). Mind rather confused. External wound filled with blood, and pulsating; with hemorrhage from the ear. An incision was made, and a flattened slug extracted; considerable hemorrhage from cranial cavity, and lateral sinns was supposed to be wounded. Died on the fifteenth day; having had delirium, with stupor most of time, and unhealthy inflammation about the wound.

On dissection, the membranes at the seat of injury were gangrenous and inflamed, with some redness and softening of the cerebellum; purulent infiltration of the muscles upon the right side of the thorax, and pus in the right pleural cavity. Nothing reported of the sinus. 1856.

Dr. H. J. Bigelow.

966. A portion of the occiput, in which is a defined, circular opening, $\frac{1}{4}$ in. in diameter in the external table, and without the slightest fissure about it; the internal being broken up as usual in gun-shot fractures. With the bone is a conical pistol-ball, very much flattened, and that was found in the brain. From a man who was supposed to have been murdered. 1864.

Dr. George S. Jones.

967. A skull that had been shot through the occipital region; the surrounding bone being considerably fractured. Sent on by Dr. F., who served professionally during the whole of the Civil War. 1863.

Dr. J. W. Foye.

968. Portion of frontal bone, removed by the trephine; perforation through it of considerable size, and upon the inner surface some new bone. A man, æt. twenty-six, fractured his skull one and a half or two years previously; followed by epilepsy, periodic insanity, etc. Hospital case (19, 119). He remained nearly three months after the opera-

tion ; and, when he left the hospital, his head was decidedly better, though he still became dizzy on quick motion.

This, and the following cases, may be introduced here, though not cases of fracture. 1849.

Dr. George Hayward.

969. A second specimen ; bi-concave in form, and with a small perforation in the centre. A delicate projection of bone adhered to the dura mater, and was accidentally broken off after the operation.

The patient was a clergyman, æt. forty-one, who had had epilepsy for nearly twelve years. The fits came on immediately after the healing of an ulcer on the head, and from which a piece of bone had been discharged. At first they were very frequent, and he always had a heavy and distressing sense of pressure, that was referred to the cicatrix as a centre. This last was just behind the coronal suture, upon the left side, and quite depressed. On the 17th of March, 1838, he entered the hospital, and on the 24th, Dr. H. removed the bone with the trephine ; the relief from the feeling of pressure being immediate, and the recovery from the operation rapid, so that he left the hospital on the 9th of April.

The above account is from a full history of the case, by Dr. H., in the *Med. Jour.* (Vol. xviii. p. 325). In 1866, the patient died of an abdominal disease, from which he had suffered for several years, and on inquiry of his family the following facts were ascertained : that he began to preach about two months after leaving the hospital, continued to for ten years, and was subsequently occupied in various literary pursuits ; had seven or eight fits during the first ten years, and four or five subsequently, — the first in November, 1838, and the last about four years before his death ; complained comparatively little of his head after the operation. 1849.

Dr. Geo. Hayward.

970. A large portion of the parietal bone, with a portion of it that was removed by the trephine. This last is about two-thirds of an inch in thickness, and the parietal upon one side of the opening is seen to be much thickened.

A hospital case (25, 64). The patient, a man *æt.* twenty-six, fractured his skull nineteen years previously. Followed by palsy of right side for nine years; and for some years past by epilepsy. Idiotic look, and gait shuffling. In the operation the pin could not be used, and this explains the bevelled form of the cut. Patient died at the end of a week, and the dura mater was found sloughy, with pus in the membranes, and an abscess, about an inch in diameter, in the brain, beneath the seat of the operation. 1849. *Dr. G. Hayward.*

971. Portion of parietal bone, from the superior anterior angle. Removed by the trephine. A hospital case (88, 57). A man *æt.* twenty-five. Skull fractured by an axe when five years old. Epilepsy for fifteen years. Bone depressed about one-fourth of an inch. Died on the sixth day. There is no irregularity upon the inner surface of the bone as from fracture. 1861. *Dr. S. D. Townsend.*

972. Top of the skull, showing an old fracture of the frontal bone, and its removal by the trephine.

A hospital case (93, 154). The patient, a man *æt.* thirty-seven, met with the accident eighteen years previously. Epilepsy for the last six years. Semi-idiotic. A depression at seat of injury would admit the first joint of the finger. Three pieces of bone were removed by the trephine; one just above the eye, the frontal sinus being largely opened. The three openings were then connected by straight cuts; and the intervening piece of bone, the seat of the old fracture, was removed. On the eighth day cerebral symptoms came on, and he died about five and one-half weeks after the operation.

A cavity was found in the substance of the brain, beneath the seat of the operation, $1\frac{1}{2}$ or 2 in. in diameter, and probably recent; with some meningitis. The opening in the bone, resulting from the fracture, is about $3\frac{2}{3}$ in. in circumference, with sharp edges, and a smooth, inner surface. The opening, resulting from the operation, is equal to 3 in. square. In the preparation, the pieces are shown in their original position. 1861. *Dr. H. J. Bigelow.*

973. A cranium, showing the effects of an old fracture. There is a deficiency of bone, in the right parietal, about $5\frac{1}{2}$ in. long, an inch at the widest part, irregular in form, and horizontal in its direction; anteriorly there extends from the opening to beyond the median line, something that looks like the cicatrix of a narrow fracture; the internal surface is much more irregular, and there is a peculiar eroded look to some distance beyond the external cicatrix. Posteriorly a cicatrized line extends from the opening, downward into the occiput, and is much more marked internally than upon the outer surface, with erosion and much roughness. There is no deposit of new bone; the edges of the large opening having a smooth, cicatrized look, and the structure of the whole bone being quite healthy.

From a female, dissecting-room subject, about thirty-five years of age. Corresponding to the large opening was a large and deep cicatrix externally; and anteriorly, there seemed to be a smaller one. There is a question whether this may not have been a case of burn, or of disease; but it, on the whole, appeared more like a fracture. 1859.

Dr. R. M. Hodges.

974. Lower half of the skull, showing an irregularity of the under surface of the occiput, and an appearance as of a nearly closed fissure upon the median line, perhaps the result of an old fracture; occipital foramen considerably enlarged posteriorly. Upon the inner surface is some very earthy-looking deposit of new bone. From a middle-aged man, who had been regarded as a simpleton. 1856.

Mr. Jas. Coldham, med. student.

975. Old and strongly united fracture of the body of the lower jaw, with considerable absorption of bone between the angle and the seat of fracture. Some appearance, also, of a second fracture near the articular process. From an old person. 1860.

Dr. R. M. Hodges.

Removal or depression of the upper maxillary bone. See nasal polypi.

Removal of a portion of lower jaw, for neuralgia. Series xxii.

976. Transverse and recent fracture of the sternum, just below the cartilages of the third rib. 1853.

Dr. J. B. S. Jackson.

977. A second specimen; at the junction of the middle and lower thirds. From a case of laceration of the heart. 1863.

Dr. C. Ellis.

978. The two upper bones of the sternum, completely separated, except so far as they are held together by the fibrous expansion posteriorly; and without fracture. 1861.

Dr. H. G. Clark.

979. Ten lower ribs, from the right side, showing very numerous fractures. Prepared in connection.

From a sailor (hospital, 83, 195), who fell from the third story of a house, and lived about seven hours. Extensive laceration of the lung, and emphysema. 1859.

Dr. C. Ellis.

980. Old fracture of a rib near the angle. 1847.

Dr. J. C. Warren.

981. The same; toward anterior extremity. Union quite regular. 1847.

Dr. J. C. Warren.

982. The same. Union quite regular. Probably from a dog. 1847.

Dr. J. C. Warren.

983. Recent and complete fracture of the coracoid process of the scapula. 1847.

Dr. J. C. Warren.

984. A scapula, showing a defined circular perforation through the body of the bone, as by a rifle-ball. 1863.

Dr. J. W. Foye.

985. Comminuted, and somewhat recent fracture of the clavicle; not yet united. Preserved on account of the exuberant growth of new bone at the seat of injury. 1866.

986. The same. Somewhat comminuted, but union not exceedingly irregular. Apparently not a very old case. 1860.
Dr. R. M. Hodges.
987. Old and strongly united fracture of right clavicle, midway. 1856.
Dr. H. J. Bigelow.
988. The same; towards outer extremity. Quite broad and flattened at seat of injury. Shortened about $\frac{3}{8}$ in. The mate preserved. Prepared by Dr. H. 1857.
Dr. R. M. Hodges.
989. The same. Fragments overlap about an inch. 1860.
Dr. R. M. Hodges.
990. The same; outer half, and quite oblique; union very regular. From a case of dislocated shoulder. 1866.
Dr. D. W. Cheever
- 990 $\frac{1}{2}$. Old fracture of the furculum of a fowl. Union irregular. 1855.
Dr. C. Ellis.
991. Comminuted fracture of the surgical neck of the right humerus. Lower portion much displaced. Head of the bone in place, but quite detached from shaft, though some of the fragments have united. Bones prepared in connection, by a student of Dr. C. 1859.
Dr. H. G. Clark.
992. The same; perfectly consolidated. Thibert's model.
Dr. Geo. Hayward.
993. Upper half of the humerus, extensively fractured; the fissures running in a longitudinal direction.
From a man who was run over upon a railroad; compound fracture of arm and scapula. Amputation at shoulder-joint on the following day; and death on the ninth. (Hospital, 54, 133.) 1852. *Dr. S. D. Townsend.*
994. Gun-shot fracture of the humerus; very much comminuted.
Two inches and a half of the bone were excised by Dr. T., but extensive suppuration followed, with much prostration, and the arm was subsequently amputated. The man

did well. Specimen prepared by Dr. T. Three smooth fragments, removed before the excision, and thus showing the effects of inflammation. Two pieces of a conical ball are also shown, that were removed at the time of the excision. 1864.

Dr. J. B. Treadwell, Surgeon U. S. Vols.

The following casts were presented to Dr. G. H. Lyman, by Dr. J. H. Armsby, Surgeon of the Military Hospital at Albany, N. Y., and by Dr. L. to the Museum; the external appearances after recovery being shown.

995. Case in which the upper part of the humerus was excised June 11th, 1864, and three days after the wound. 1869.
996. Amputation of shoulder-joint, June 12th, 1864; nine days after the injury. 1869.
997. The same; June 18th, 1864; the day after the injury. 1869.
998. The same; for a rail-road injury. 1869.
999. A transverse T shaped fracture of the humerus, as it has been sometimes called, and $2\frac{1}{4}$ in. above its lower extremity; the lower fragment being split straight down into the joint, and into two almost equal portions.
- The patient, æt. forty-five years, fell 20 ft. from a ladder, struck his elbow, and received a compound fracture. A few hours afterward the limb was amputated by Dr. H., $5\frac{1}{2}$ in. above the joint, and the man did well. 1869.

Dr. John Homans.

1000. A second specimen. The bone is rather irregularly and obliquely fractured, about 2 in. above the joint; and the lower fragment is broken into the joint, in about two equal pieces. There is also a partial fracture of the ulna, just below the coronoid process, from before backwards, and a small piece is broken from the inner edge of the coronoid. The radius is uninjured.

From a man, æt. thirty-five, who entered the hospital (140, 213) July 22d, with a compound fracture of the el-

bow, and almost pulseless. The limb was amputated on the 23d, and he died of pyemia, Aug. 27th. 1869.

Dr. R. M. Hodges.

1001. Comminuted fracture above the elbow; produced after death; from the ulnar edge of the humerus into the joint, between the condyles. Olecranon also fractured. 1847.

Dr. J. C. Warren.

1002. Bones of the upper extremity, prepared by Dr. C., and showing a fracture of the humerus just above the condyles, and midway through them into the joint; the outer condyle is also broken off. The radius and ulna, also, are broken just above the lower articulation; the latter comminuted.

From a man, æt. forty-eight years, who fell downstairs whilst intoxicated, Dec. 24th, 1865, and entered the City Hospital on the 26th. Ecchymosis extensive, and especially around the elbow. Amputation at 4 P.M., on the 27th. Delirium tremens, with low muttering, and death on the 29th. 1866.

Dr. Algernon Coolidge.

1003. Humerus, in two portions; probably the result of an ununited fracture. The upper fragment is light in structure, reticulated, and hollowed out, with some deficiency of the walls; very much as in some cases of cancer. The lower fragment is sound, but with some new bone about the supposed fracture. 1847.

Dr. J. C. Warren.

1004. Lower half of the humerus; very probably from a case of ununited fracture. Surface porous, with some new deposit about upper extremity. 1847.

Dr. J. C. Warren.

1005. Portions of humerus removed for an ununited fracture; one is an inch in length, and the other about three-fourths of an inch.

A hospital case (113, 220). The bone was fractured by a conical ball, in the summer of 1863, and "considerably splintered." About an inch was sawed off from each fragment, but union never took place. April 16th, 1864, Dr.

B. removed the pieces here shown ; first dissecting up and reflecting the periosteum, then drawing the fragments together by a wire, and then replacing the periosteum. June 24th the man was doing well, and left the hospital. Sept. 17th he returned to have the wire removed ; and the union then was quite firm. "Dec. 16th, 1865 : The arm is perfectly firm, and for some time the man has done a great deal of heavy lifting, such as wheeling coal, without favoring the injured arm in the least." The wire is shown with the bones. 1865. *Dr. H. J. Bigelow.*

The above was the first of eleven cases, in which Dr. Bigelow has done an operation for ununited fracture, which was original with himself, and in all of which the result was successful, excepting one (No. 1010) in which the bone was diseased. The principal points of the operation consist in a dissecting-up, and preservation, with the least possible injury, of the periosteum, in consideration of its "osteoplastic function ;" the drawing together of the bones, and securing them by wires, after the ends have been sawed off ; and the removal of burrowing pus. These cases, all of which occurred at the Mass. Gen. Hospital, have been published by Dr. B., with remarks upon the history of the operation, and also a clinical lecture upon the subject, in the *Med. Jour.* Vol. LXXVI. pp. 297 and 325.

1006. A second case. The patient, a laborer, æt. twenty-six, entered the hospital (121, 150) June 12th, 1865, and the accident happened a year before ; the fracture being compound, and caused by the passage of the wheel of a hand-car over his arm. At the end of six weeks it was again fractured ; and it never again united.

On the 21st, Dr. B. made an incision upon the outside of the arm, turned aside the musculo-spiral nerve, stripped back the periosteum from each fragment of the bone, and sawed off $\frac{1}{2}$ in. from the lower, and $\frac{3}{4}$ in. from the upper. The ends of the bone were then drilled on the outer side, and a silver wire passed through ; and, the bones having been placed in apposition, the wire was twisted by four half-turns. The arm was then placed in an inside and outside angular splint, and the wound closed by sutures.

July 28th an outside angular splint was applied. Aug. 7th there was slight stiffening at the seat of fracture; and on the 22d only a slight motion could be detected. Nov. 4th, all soreness and discharge having ceased, and the humerus being perfectly stiff, the wire was cut away; and on the 29th of December he left the hospital well. The wire is shown with the bones. (Med. Jour. Vol. LXXVI. p. 330.) 1868.

Dr. H. J. Bigelow.

1007. A third case. The patient, a carpenter, æt. twenty-eight, entered the hospital (119, 124) Jan. 2d, 1865. There had been a simple fracture of the humerus a little below the middle of the bone, twelve weeks before, and that had been treated in the usual way by splints; but there had never been any attempt at bony union, though the bones were found in apposition. On the 7th each fragment was drilled in three places, and an inside and outside angular splint applied; but on the 26th there was no union.

Feb. 25th an incision was made along the outside of the arm, and after dissecting the ends of the bones from the periosteum, $\frac{1}{2}$ in. was removed from the upper fragment, and an inch from the lower. Holes were then drilled, and a silver-plated copper wire was passed and twisted. The musculo-spiral nerve had been divided accidentally; and the ends, having been brought together, were secured by a suture through the neurilemma. Several arteries were tied; and, after closing the wound, the arm was placed in an inside angular splint, firmly bandaged, and then upon a flat angular splint, reaching from the shoulder to the hand.

On the 26th there was great numbness over the dorsal surface of the thumb and index finger, and a general paralysis of the extensors of the wrist and fingers. March 8th the wound was open throughout, with considerable inflammation; and the suture came away from the neurilemma. On the 31st there was considerable stiffness; and on the 6th of May the arm was quite stiff. June 24th the wire was removed, and is shown with the bones; sensibility had returned to the thumb and finger, but the extensors of the wrist and fingers were still powerless. On the 17th of March, 1866, he reported at the hospital that he had worked

at his trade since August, and without inconvenience. The arm was perfectly firm, and free from pain; and the extensors of the wrist and fingers had recovered the power of motion perfectly.

The union of the musculo-spinal nerve, Dr. B. regarded as a point of great interest. (Med. Jour. Vol. LXXVI. p. 329.) 1868. *Dr. H. J. Bigelow.*

1008. A fourth case. Portions of bone removed at two different times.

The patient, a soldier, received a gun-shot wound about the middle of April, 1862. The humerus having been shattered about midway, the fragments were at once removed, and the ends of the bones sawed off and approximated. At the end of six months no union had taken place; and the ends of the bones having been again sawn off, were wired together. In two weeks the wire was removed. There never was any union, and when he entered the hospital (125, 22) Nov. 3d, 1865, there were several fistulæ, the bone could be felt, and a few small pieces had been discharged. The arm swung freely in all directions, but there was no pain; and the general health was excellent.

Nov. 4th an incision was made over the lower fragment, upon the outside of the arm, and the sinuses were found to extend down into the interior of the bone. The cavity in this last was then exposed throughout by the removal, by the trephine, of three pieces of bone, and the interior was thoroughly scraped with a gouge. The periosteum was scraped back, and a portion of the lower fragment was removed. This last was $2\frac{1}{2}$ in. in length, $1\frac{1}{2}$ in. in diameter, and changed in structure, as well as enlarged, by chronic inflammation; irregularly pointed toward the extremity, and shows the course of the sinuses as they extended down into the interior of the bone. The periosteum was then scraped back from the upper fragment, which was healthy, though not more than one-half its natural size, and quite pointed. A few points were nipped off; the end fitted into the cavity in the lower fragment, and the two wired together. Splints were applied so as to keep

the parts perfectly at rest, and the case seemed to be going well ; but on the 20th of February the upper fragment was found to be dead, and was removed.

March 31st, 1866, there was no union, and a second operation was performed. The cavity in the lower fragment was found to be filled up, and the wire was still firm ; but the upper fragment was free. The periosteum having been scraped back from both, a piece was sawn from the lower, $1\frac{3}{4}$ in. in length, and the same in diameter ; rough toward the end, and pointed upon one side. The portion sawn from the upper fragment was $1\frac{1}{4}$ in. in length, $\frac{7}{8}$ in. in diameter, and quite pointed at the extremity. Holes were then drilled, and the fragments were wired together, but not tightly.

On the 28th of April there seemed to be some stiffening ; but on the 10th of June he fell upon his elbow, and broke his arm again ; and on the 15th of July he left the hospital.

Jan. 12th, 1867, he was readmitted ; there being no union, and on the same day a third operation was performed. The ends of the bones were much roughened ; and there was great difficulty in everting the fragments, and detaching the periosteum, on account of their shortened condition. One inch and three-fourths, however, were removed from the lower fragment, and it was 2 in. in diameter where cut across. The upper fragment was of normal size, but with fatty degeneration of the interior, and from this one inch was cut off. The bones were then drilled and wired, and a towel was placed in the axilla to keep out the upper fragment. On the 13th there was almost complete paralysis of the extensors of the fingers, though no nerve was known to have been divided.

The parts being kept in good position, there was slight stiffening on the 6th of February ; and on the 16th of April, the humerus being quite firm, the forearm could be flexed, and the arm raised freely from the side. The next week he left the hospital. July 3d he returned to have the wire removed, and the union was firm ; but the paralysis continued.

Dr. B. remarked that at the time of the first operation,

the lower fragment was reddish, dense, brittle, and amorphous, as it is sometimes in the denuded walls of the cavity of sequestra; and that, at the end of about a year, and when dead bone could no longer be felt, the tissue was comparatively healthy, and the interior cancellated. The arm was seven inches shorter than its fellow. (Med. Jour. Vol. LXXVI. p. 332.)

The bones that were removed at the two first operations are shown; with one of the wires. 1868.

Dr. H. J. Bigelow.

1009. A fifth case. The patient, æt. thirty-three, was wounded with a conical ball, at the battle of Gettysburg, July 3d 1863, and the result was a compound and comminuted fracture of the humerus. July 5th about 3 in. of the bone were removed, but the bones were not kept in apposition, and no union followed. In five months the wound healed, and never troubled him afterward; and, having resumed duty, he served out his full time with his regiment.

On admission into the hospital, Jan. 26th, 1866 (125, 116), the extremities of the bone were felt, pointed and considerably absorbed; and the arm hung atrophied and useless. On the 27th the operation was performed for Dr. B. by Dr. Hodges, 1 in. being removed from one of the fragments, and $1\frac{1}{2}$ in. from the other; the bones, as seen in the preparation, being much atrophied. The ends were then drilled, and a silver wire was passed and twisted, allowing room for slight movement. The periosteum was returned to its place; the wound closed and dressed; and an internal angular splint applied. Abscesses formed after the operation; but on the 31st of March the union was firm, and he left the hospital. May 23d he returned to have the wire removed; and on the 30th of April, 1867, he wrote to say that his arm was strong, and that for months he had used it daily. (Med. Jour. Vol. LXXVI. p. 331.) 1868.

Dr. H. J. Bigelow.

1010. A sixth case. The lower $2\frac{1}{2}$ in. of the humerus, from a case of ununited fracture; the upper extremity of the

specimen being rounded and smooth, excepting a very small cavity.

The patient, a corpulent, flabby woman, æt. forty-five, entered the hospital (117, 240) Nov. 10th, 1864; having had a compound fracture eighteen months before. Seven months after the accident a seton was passed, and left in for a month; and other means were used; but the bone never united. The ends of the bone were drawn widely apart by the weight of the forearm, unless held in place by an apparatus that she had worn during the last seven months. On the 19th Dr. B. made an incision upon the outer back part of the arm; the ends of the bone were turned out, the periosteum dissected back from the lower fragment to the extent of about $1\frac{1}{2}$ in., and from the upper to that of 2 in., and the ends removed. The bones were so degenerated as to be easily cut with a knife, and the wire was therefore not twisted tightly. The arm being very unwieldy, it was placed upon a flat right-angled splint.

Jan. 7th there was no stiffening, and the wire had apparently cut through.

On the 1st of April the wire was removed; on the 26th the arm was amputated, at the request of the patient; and on the 17th of June she left the hospital. (Med. Jour. Vol. LXXVI. p. 328.) 1868. *Dr. H. J. Bigelow.*

1011. Humerus much shortened, and the head depressed. This specimen illustrates the difficulty of diagnosis that sometimes occurs between old fracture and disease. 1847.

Dr. J. C. Warren.

1012. Old fracture of the humerus in a bird. Union strong, though the fragments are more than half an inch apart.

1013. A 2d. Union very irregular, and perforated by a hole of some size; with a pointed projection upward of the lower fragment.

1014. A 3d. Union irregular, and less consolidated than the others. This and the last are accompanied by their mates.

1015. A 4th. Union strong, though the fragments completely overlap; and a longitudinal section having been made (1860), it is seen that the cavity of the bone, to the extent altogether of about 2 in., is filled with cancellated structure. The bone is $5\frac{3}{4}$ in. in length, and the earthy matter had been removed by an acid. — The above were given by Dr. W. 1847. *Dr. J. C. Warren.*

1016. A 5th. Union very strong, though the fragments overlap $1\frac{1}{2}$ in., and are considerably separated. 1856. *Dr. H. J. Bigelow.*

The same, in an eagle. No. 162.

1017. Elbow-joint, showing a recent fracture of the outer condyle of the humerus and head of the radius; by a charge of small shot, at short range. Soft parts extensively injured. Amputation the same day by Dr. H., and the man did well. A hospital case (106, 200). Bones prepared by Dr. H. 1863. *Dr. R. M. Hodges.*

1018. Photograph of a soldier, after recovery from excision of the elbow-joint. In June, 1862, a ball passed through the joint, which became enormously swollen, with very profuse discharge, and the man was greatly reduced. In September he was well enough for the operation, and about 3 in. of the bone were removed by Dr. P. Very great pain and swelling followed; but his recovery was afterward rapid, and on the 1st of December he could write his name with ease. Sent to Dr. H. by Dr. John H. Packard, of Philadelphia. 1864. *Dr. R. M. Hodges.*

1019. Bones of the forearm, and lower part of the humerus, showing an old and ununited fracture of the olecranon, nearly $1\frac{1}{2}$ inches from its extremity, and into the joint.

From a dissecting room subject, æt. thirty years. The separation was considerable, and the intervening space filled with dense, fibrous tissue. The cartilages, ligaments, tendon of the extensor muscles, and the whole joint were perfectly healthy. Prepared by Dr. H., as a dry specimen. 1857. *Dr. R. M. Hodges.*

1020. Comminuted fracture of the olecranon. From a man, æt. fifty-five, who received other injuries, and died in forty-eight hours. (Hospital, 131, 50.) Prepared by Mr. R. H. Derby, one of the house-pupils. 1867.

Dr. H. J. Bigelow.

1021. Old, double, transverse fracture of the olecranon; with close fibrous union. The lines of fracture are, respectively, $\frac{1}{2}$ in. and $1\frac{1}{3}$ in. from the extremity of the bone; and at this last the union was so close that it only appeared when the pieces were separated by maceration. The fossa in the humerus is very large. The lower extremity of the fibula was also broken. 1866.

Dr. D. W. Cheever.

1022. Thibert's model. A consolidated fracture of the olecranon process; the separation of the parts being inconsiderable. The arm, during treatment, was kept in a state of demi-flexion.

Dr. Geo. Hayward.

1023. A piece of bone, broken from the olecranon, and fifteen years afterwards removed from the elbow-joint; in spirit.

From a man, æt. twenty-three. (Hospital, 87, 50.) When eight years old he injured the elbow severely; and four or five years afterward noticed something movable in the joint, and which, in a certain position, prevented flexion. The elbow was quite natural in appearance, but there was something apparently bony, and about the shape of the inner condyle, between this last and the olecranon; the condyle being much smaller than the outer one. The loose body was somewhat movable.

The following record was made by Dr. B.: "An incision, made on the side of the olecranon, between that and the internal condyle, exposed the uneven surface of the loose body, which was removed without difficulty. It was about the size of a civet bean, and in parts quite as thick; very rough, and almost spiculated on one side, and only unequal on the other, like the side of the olecranon itself, which it doubtless is, inasmuch as the substance is bony, and the surface here and there covered with what is, under the microscope, true cartilage. Elsewhere is found some amor-

phous and granular lymph." The wound healed in a week, and the patient was soon discharged, well. 1859.

Dr. H. J. Bigelow.

1024. External condyle of the humerus, and about one-third of the head of the radius, gouged off in a machine-shop.

From a man, æt. twenty-four years, who entered the hospital immediately after the accident (126, 146). Muscles extensively lacerated. The patient being quite healthy, Dr. H. preferred excision of the joint to amputation. Some inflammation followed, but the man was discharged well in seven and one-half weeks. 1866.

Dr. R. M. Hodges.

1025. Fracture of the inner condyle, from a fall; the forearm having been at the same time dislocated backward and outward.

From a young girl, æt. sixteen. The accident happened Dec. 6th; sloughing ensued, and the limb was amputated Jan. 21st. Discharged, well, Feb. 15th. A hospital case (87, 100). The condyle is seen to have undergone considerable change; as have also the other bones, more or less. 1860.

Dr. H. J. Bigelow.

1026. One-third of the head of the radius broken off, with a comminuted fracture of the upper extremity of the ulna. The fragments of this last have been cemented together by Dr. H.

From a man who fell from the roof of a house, and died within about twenty-four hours; the elbow-joint having meanwhile been excised. 1868. *Dr. R. M. Hodges.*

1027. Gun-shot fracture of the radius, midway, and of the ulna near the upper extremity; both comminuted. Union not strong; the new bone being still tender. In the ulna there is embedded a piece of a gun-barrel, more than 2 in. long, and $\frac{1}{2}$ in. or more in width.

From a soldier, who was wounded at Gettysburg, July 3d, 1863; the ulna by a shrapnel charge, and the radius by some other missile; little bits of lead being found between the fragments of this last. Soft parts extensively lacer-

ated. He entered a military hospital July 13th, and a few days afterward the iron was removed. Extensive suppuration followed; and on the 12th of September the arm was amputated at the junction of the middle and upper thirds; a piece of the man's dress being found in the flesh. Did well until Oct. 4th, when symptoms of pyemia came on, and he died on the 10th. About $\frac{3}{4}$ of ill-conditioned pus was found in the shoulder-joint; but the internal organs were healthy.

Bones of the forearm prepared and wired together by Mr. C., and the iron replaced. 1863.

Mr. Stephen Cushing, Jr., med. student

1028. Bones of the elbow-joint, removed by excision; about 2 in. of the humerus, which was very much comminuted; ulna uninjured, and the head of the radius only chipped.

A railroad accident (hospital, 132, 132). The man recovered with a very useful arm, though soon after he left the hospital he got tipsy, and tore the bones completely apart. 1867.

Dr. R. M. Hodges.

1029-30. Casts, in plaster, of the forearms and hands, showing the deformity that takes place in partial fracture of the bones in young persons.

Case of a boy, *æt.* about fourteen years, who entered the hospital about five years ago. Six weeks previously he fell backward from a wagon, and received the blow upon his hands. On admission the swelling had subsided, and it was evident that both bones of both forearms were broken, about 2 in. above the joints. 1856.

Dr. H. J. Bigelow.

1031. Longitudinal fracture of the head of the radius, with fracture of the ulna from the coronoid process downward.

From a man who died at the hospital six hours after this and other injuries.

The specimen shows a clear and regular split, involving very nearly one-half the head of the radius, and cleaving outwards so as to extend no further than the neck of the bone. The fracture of the shaft of the ulna is very oblique, commencing at the depression of the articular sur-

face, marking the separation of the coronoid process and the olecranon, extending almost longitudinally $3\frac{1}{4}$ in. downwards, and detaching from the shaft that portion of the bone to which the olecranon was attached.

Dr. H. remarked that there are very few recorded cases of longitudinal fracture of the head of the radius; and, of those that he had found, three were associated with the rare accident of fracture of the coronoid process of the ulna; and the present specimen shows that this also might have been a fracture of the coronoid process, had the split which passed down the shaft of the ulna terminated anteriorly (towards which aspect it inclined, and came nearest) instead of posteriorly. 1766. *Dr. R. M. Hodges.*

1032. Old fracture of the lower half of the radius and ulna. Lower fragments inclined outward.

From a female dissecting-room subject, fifty years of age, or more. The femur was also fractured. No. 1082. 1865.

Dr. Wm. C. B. Fifield, of Dorchester.

1033. Oblique fracture of the radius, at the junction of the middle and upper third. The muscles of the whole arm were atrophied, and rotation of the forearm considerably impaired. Fracture very firmly united, though so irregularly as to prevent rotation of the bone. Upper fragment so twisted upon the lower, that the surfaces of the two are not in the same plane, and the bicipital tuberosity is consequently displaced outwards. There is also upon the upper surface of the head of the bone a small fracture, of the size of a three-cent piece, superficial, united with remarkable evenness, without any sign of inflammation, and marked by a defined outline. 1856.

Dr. R. M. Hodges.

1034. Old fracture of the ulna, just below the middle of the bone; union regular. 1847.

Dr. J. C. Warren.

1035. The lower extremity of the radius, showing a stellate crack of the articular surface, and extending upwards for more than an inch.

From a hospital patient, who died from other injuries.

At first there was only a complaint of lameness, as from a sprain, but after some days there were swelling and tenderness, which, from their persistence, led Dr. B. to diagnose a stellate crack of the bone, as a probable result of the fall, and of which he had met with a similar case two years previously. Dr. B. remarked that the bones of the wrist would act as a wedge upon the concave, articular surface of the radius; and that this case would explain the persistence of some cases of sprained wrist.

Case published in the *Med. Jour.*, with a figure (Vol. LVIII. p. 99); and copied, with the figure, in Dr. F. H. Hamilton's work on Fractures. 1848.

Dr. H. J. Bigelow.

1036. Bones of the forearm, with the lower portion of the humerus. There are appearances of old fracture of the ulna, just below, and involving the elbow-joint. It may, however, have been altogether, as it certainly was in part, a chronic arthritic affection. The articular surfaces are irregular, and new bone is thrown out about their edges. Outer portion of the head of the radius absorbed, and the rest worn away and eburnated, as is the corresponding portion of the humerus. Lower extremity of the radius enlarged; and the articular surface is irregular and fissured, as from old fracture into the joint. The elbow must have been flexed at a right angle. See next specimen. 1856.

1037. Lower extremity of the radius; the mate of the last specimen, and showing the same appearances. 1856.

Dr. R. M. Hodges.

1038. Comminuted fracture of the lower end of the radius, just above, and into the joint, and a second fracture, $2\frac{1}{2}$ in. above the joint.

From a man who received a very violent blow from a piece of machinery, Dec. 24th. On the 26th he entered the hospital (127, 248), with gangrene of the limb, in consequence of the exceeding tightness of the bandage that

had been applied; and on the 29th he died. Prepared by Mr. R. H. Derby, one of the house-pupils. 1867.

Dr. H. J. Bigelow.

1039. Three and five-eighths inches of the radius, and $2\frac{1}{2}$ in. of the ulna, necrosed after a fracture, about $\frac{3}{4}$ in. above the joint; and removed three months after the accident. The whole of the radius is involved to a considerable extent, but much less of the ulna. The result, probably, of tight bandaging.

From a little boy, six years old. When he entered the hospital (136, 129) the bones protruded above the wrist anteriorly; and, being loose, were removed at once, so that in a few days he was discharged. The external surfaces are not extensively involved, and the formation of new bone was well advanced. The epiphyses remained in place. 1869.

Dr. R. M. Hodges.

1040. Old, oblique, and impacted fracture of the lower extremity of the radius just above the articular surface. Bone sawed open. Dissecting-room. 1856. *Dr. R. M. Hodges.*

1041. Cast, in plaster, showing the external appearances in a case of comminuted fracture of the radius, about an inch above the wrist-joint, fracture of the styloid process of the ulna, and lateral displacement inward of the lower part of the forearm; but without any anterior or posterior displacement.

The patient was a very heavy woman, æt. forty-four years, who fell down-stairs, and struck upon her arm. She also had a very bad compound dislocation of the elbow. Amputation at once by Dr. Cabot, and the case did well. (Hospital 102, 238.)

1042. Bones from the above case; prepared in connection. 1863.

Dr. Samuel Cabot.

1043. Small portions of the radius and ulna, removed in case of ununited fracture.

From a man who was wounded at Gettysburg, July 3d, 1863. About 4 in. of the bones were removed, and there

never had been any union. Oct. 6th, 1865, he entered the hospital (125, 4), and on the 13th the operation was performed. The upper fragment of the ulna was turned out, the periosteum scraped back, and about $\frac{1}{2}$ in. sawn off. About an inch only of the lower fragment remained, but the periosteum was raised, and a very small piece of bone was removed. The ends of the radius were then sawed off ($\frac{3}{4}$ in. and $1\frac{1}{4}$ in.), and the bones were drilled and wired. Dec. 3d the wire in the ulna broke through, and was removed. March 14th there was no union in either bone; and the wire was removed from the radius, with four small pieces of dead bone; the patient having left the hospital on the 1st of February. 1868. *Dr. Geo. H. Gay.*

1044. Cast, to show the appearances on recovery, after a large portion of the hand had been cut away, for a gun-shot injury. The index finger and thumb remain, and are very useful; flexion and extension being perfect. Taken by Dr. G. K. Smith, of Brooklyn, N. Y., at the Armory Square Hospital, in Washington; and a copy placed in the Army Med. Museum in that city. 1866. *Dr. C. B. Porter.*

1045. Photograph of the above patient. 1866.
Dr. G. H. Lyman.

1046. Recent fracture of a metacarpal bone, near its anterior extremity. 1847. *Dr. J. C. Warren.*

1047. First phalanx of the thumb, showing a separation by violence of the posterior epiphysis. From a boy, æt. fourteen. Hand badly crushed; amputated, and did well. (Hospital 118, 162.) Specimen prepared by Mr. F. B. Greenough, one of the house-pupils. 1865.
Dr. R. M. Hodges.

1048. Excision of the metacarpo-phalangeal articulation of the thumb. From a boy who had a pistol burst in his hand. The articulation was laid open; and there was dislocation, with a transverse fracture of the very anterior extremity of the metacarpal bone. The wound healed by the first

intention; and the thumb hardly differed from its fellow in appearance, though somewhat impaired in mobility.

Dr. H remarked, that "in view of the bad results ordinarily attending compound dislocations of the fingers, this case, so far as it goes, seems to justify the assertion of many authorities, that in similar instances excision is a safer course to pursue, than simple reduction." 1867.

Dr. R. M. Hodges.

1049. Fracture in a bird; of the radius near the upper, and of the ulna near the lower extremity. Union irregular. Prepared by Dr. J. H. Blake. 1860.

Dr. H. J. Bigelow.

1050. The two pubic bones entirely separated from the ischia, through the foramen ovale on each side; but the symphysis is not disturbed. The left is also partially, and to a considerable extent, broken quite through in front, and only bent upon the posterior surface.

From a man, who was jammed between two railroad cars, and died the same day. A hospital case (121, 26). Great swelling and ecchymosis about pelvis. Right thigh strongly and permanently everted. A free incision was made in the perineum, as the urine had escaped from the bladder; the pubic bones being found pushed backward, on dissection, and the prostate lacerated throughout. The left sacro-iliac synchondrosis was also separated. 1866.

Dr. H. G. Clark.

1051. Comminuted fracture of the os innominatum, and mostly confined to the pubes. Some new bone thrown out, but little or no union.

From a man, forty years of age, who lived a few weeks, and appeared for a time as if he might recover. Urethra lacerated; and the infiltration of urine was followed by extensive sloughing. Case reported and figured in Dr. F. H. Hamilton's work on Fractures and Dislocations. 1859.

Dr. H. G. Clark.

1052. Gunshot wound of the pelvis, and upper extremity of the tibia.

From a man who was assaulted in the street. One ball is seen to have passed through the tibia just below the joint, which last is extensively fissured; and for this injury the thigh was amputated on the eighteenth day. Secondly, a portion of the pelvis shows that another ball passed through, and shattered the tuberosity of the right ischium. It then traversed the pelvis, produced a deep but incomplete fracture of the left pubes, close to the symphysis, fell back into the cavity of the pelvis, and was afterwards extracted from near the groin. The man lived twenty-two days from the time of the injury, and was found to have an extensive purulent infiltration of the cellular tissue of the pelvis, but without any injury to the peritoneum, bladder, or any of the large vessels or nerves. (Hospital, 126, 242.) 1866
Dr. R. M. Hodges.

1053. A portion of the pelvis, showing a comminuted fracture through the acetabulum, from the great sacro-ischiatic notch to the obturator foramen, and an extension of the fracture along the upper portion of the acetabulum, that nearly separated the ilium. The whole posterior portion of the acetabulum is broken off in one piece. The head of the femur, a portion of which last is shown, is deeply indented upon its anterior surface, as the head of the humerus sometimes is in dislocation; the outline being quite defined, as if it had struck against some sharp edge of bone. At the time of the dissection a portion of the pelvis was displaced backward, and the head of the femur followed it.

From a man, æt. thirty-six years, who fell from the roof of the barracks, at the Charlestown navy-yard, struck upon his right side, and died in forty-eight hours. A hospital case (88, 72). The limb was shortened, the foot inverted, the toes resting upon the instep of the other foot, the knee semiflexed, and he was unable to move the limb on account of pain. Six of the ribs were also fractured, and there were several superficial lacerations of the liver. 1860.

Dr. S. D. Townsend.

1054. A portion of the femur, and of the pelvis, from a boy

twelve years of age, who was accidentally shot. The ball entered the left hip, shattered the trochanter, emerged at the fissure between the nates, and passed through the other buttock. Not much pain; and hemorrhage slight. Loose bone was removed from the trochanter, and he died on the fourth day. A hospital case (106, 86).

In the preparation the trochanter is quite gone, and the shaft of the bone is somewhat injured. The ischium is also broken, and a portion of the tuberosity has been carried away. 1864. *Dr. R. M. Hodges.*

1055. A partial fracture or fissure in the neck of the femur, in a man forty-two years of age; the upper half of the bone is shown. There was also a transverse fracture of the same bone, midway, and a fracture of the spine.

The patient, a laborer, fell through two stories of a building, upon a hard floor; entered the hospital (67, 212), and died on the eighteenth day from the accident.

The fissure involves about three-fourths of the circumference of the neck, the inner anterior portion only being spared; and to a considerable extent it runs along very near to the head of the bone. It is quite closed, but there is considerable motion between the head and neck, when the head and shaft are grasped, and moved upon each other; and the fissure would undoubtedly result in a perfect fracture if much force were used. From the fracture of the shaft, midway, a fissure extends upward and toward the neck; but it does not meet the one above described.

This case has been reported, and the specimen figured in a paper upon Fractures of the Femur, by Prof. R. D. Mussey, in the Amer. Jour. of Med. Sc. for April, 1857. 1856. *Dr. H. J. Bigelow.*

Dr. Hamilton also refers to it (p. 84) in his work on Fractures.

1056. Oblique and recent fracture through the neck of the femur, terminating inferiorly in a sharp point, and just involving the head of the bone, which last only is shown. 1847. *Dr. J. C. Warren.*

1057. A recent fracture of the neck, almost close to the margin of the head posteriorly, and half an inch or less below it anteriorly. The shell of the neck was driven into the head half an inch posteriorly, and the head is bent upon the neck so as to open the line of fracture in front nearly one-fourth of an inch. The central portion of the head of the bone was also driven three-fourths of an inch into the less compact, cancellated structure of the neck; and altogether the impaction was such that considerable force was required to separate the fragments; these last being now permanently fixed in the position in which they were before the separation, and with some eversion.

From a woman, æt. seventy-six, who fell upon the right trochanter, and two days afterwards entered the hospital (107, 84) under the care of Dr. G. There was eversion of the limb, with shortening of half an inch; and the patient, who regarded the injury as nothing more than a severe bruise, died in two weeks of pneumonia.

Dr. Bigelow thinks it fair to suppose that bony union would have occurred if the woman had lived. See No. 1115. 1869. *Dr. Geo. H. Gay.*

1058-61. Effects of conical balls, as shown upon the dead body; upon the neck of the femur, upon the condyles, and upon the ankle; and, by contrast, the effect of a common round ball above the condyles. In spirit. See *Med. Jour.* Vol. LXIX. p. 357. 1861. *Dr. H. J. Bigelow.*

1062. Fracture, confined to the neck of the right femur. Bones macerated, and show very little change.

From a feeble, old woman, seventy-six years of age, who fell as she was walking across her room, and struck the right hip. Lived ten weeks. Eversion and slight shortening of limb; much pain when thigh was flexed on pelvis; no crepitus before nor after death. 1860.

Dr. Francis Minot.

For Dr. Bigelow's anatomical description of the upper extremity of the femur, in relation to fractures, see No. 111.

1063. Recent and irregularly transverse fracture of neck of femur near the head of the capsule. Dried, without maceration. 1861.

1064. Fracture of the neck, within the capsule, and nearly transverse. The upper portion of the bone is shown, with a portion of the os innominatum, and a longitudinal section through the two. The capsular ligament was intact at the time of the examination.

The patient was a female, æt. eighty-four years, and the accident happened from a slight cause. There was strong eversion, shortening apparently to the extent of 2 in., and such severe pain that etherization was necessary before she could be removed to her bed; crepitus then was distinct. A weight was attached to the limb, and she became quiet; but pain, more or less severe, continued until she became unconscious, a day or two before death, which occurred on the twentieth day; large bed-sores forming from the irritation of the urine with which she was constantly kept wet. 1869.

Dr. B. E. Cotting.

1065. Irregularly transverse fracture of the neck, and about at the junction with the head of the bone. The capsular ligament is mostly torn through, but to a considerable extent it remains, and shows that the head, in such cases, would not have to depend entirely upon the round ligament for its supply of blood. A small piece is broken from the tip of the great trochanter. From the appearances the patient may have lived some little time after the accident. 1855.

The following five Thibert's models were given in 1847.

Dr. Geo. Hayward.

1066. Fracture of the neck within the capsule, from a fall upon the trochanter. There was inflammation of the bone; and a large abscess communicated with the interior.

1067-8. Fracture of the neck, within the capsule; with section of the bone, showing inflammation of the medullary membrane.

The other half of the same.

1070. Lower portion of the same femur, showing an extension of the inflammation, and an opening for the discharge of the pus.

1071. The other half of the lower portion of the same, showing suppuration of the medullary membrane.

1072. Fracture of the neck of the femur, close to the head, and with almost no change.

From a negress, æt. ninety-nine years and nine months. Too feeble for a long time to go out; and fell as she was walking across her room. There was at the time, shortening, eversion, mobility, and crepitus; scarcely any pain except when the limb was moved, and then not at all severe. No treatment. Sat up about half of the time after the first few days; and she seemed to fail from being confined to her bed more than usual. Died five months after the accident. 1865.

Dr. George Faulkner, of Jamaica Plain.

1073. Recent fracture. The neck of the femur, the small trochanter, and the great trochanter in two pieces are, each, broken from the shaft. From a middle-aged man. In the preparation the pieces have been connected. 1859.

Dr. R. M. Hodges.

1074. The upper portion of the femur, showing a recent and very oblique fracture at some distance below the trochanters; and from it a longitudinal split upwards, and through the great trochanter. Also a fracture of the neck, just above the trochanters. 1847.

Dr. J. C. Warren.

1075. Fracture between the neck and shaft; the great trochanter being also broken off.

The neck forms a right angle with the shaft; and the union is so imperfect that the fragments separated in maceration. 1847.

Dr. J. C. Warren.

1076. Head and trochanters only preserved, showing a fracture

of the neck, and a separation of the great trochanter into two pieces. 1847. *Dr. J. C. Warren.*

1077. A strongly marked case of impacted fracture of the neck at its union with the shaft, and ununited, though some new bone is thrown out. Trochanter scarcely, if at all, implicated. Sawed longitudinally.

Sent to Dr. Winslow Lewis by Dr. Chase, of Thomaston, Me., and by Dr. L. to Dr. B. "The patient was seventy years old, and the fall was slight that caused the fracture; but for many years he was lame, and unable to walk without pain, which was always referred to the articulation." 1854. *Dr. H. J. Bigelow.*

1078. Section of the upper part of the femur, showing a fracture of the neck from the shaft, with deep impaction.

From a man, æt. eighty-four years, who had been hemiplegic for several years, and fell suddenly upon his hip. Dr. C. found him in bed, with slight eversion, shortening to the extent of $\frac{1}{2}$ in.— $\frac{3}{4}$ in. and immobility, but no crepitus. The patient kept his bed for four weeks, without any bad symptoms, but gradually sank, and died in the middle of the seventh week. Case published by Dr. C., with a figure and remarks, in the *Med. Jour.* Vol. LV. p. 364. 1856. *Dr. H. G. Clark.*

1079. The upper portion of the femur, from which the great trochanter has been broken, and to which it is imperfectly united. The neck, which is not preserved, must have been broken from the shaft and impacted, as shown by the hollow in this last. 1847. *Dr. J. C. Warren.*

1080. Fracture of the neck, from the shaft.

The patient was ninety-three years old, very feeble, and lived a month from the time of the accident, which was probably caused by her slipping from a rocking-chair. There was no crepitus, never any shortening, and but little pain; but there was some swelling of the limb, and posteriorly extensive ecchymosis. The fracture is very nearly at the union of the neck with the shaft; a large portion of the great trochanter is also broken off; and the trochanter

minor is so comminuted as not to be recognizable. Some new bone is thrown out in various places, but without union. The articular surface is somewhat eburnated; and upon the neck is some caries, that was probably connected with a large effusion of pus and offensive matter, that was found amongst the muscles about the upper half of the thigh, and in the cavity of the bone. 1860.

Dr. B. Lincoln Ray, of Providence, R. I.

1081. Old fracture of the neck, at its junction with the shaft, from which it stands off at a right angle; the inner portion seeming to be forced inward upon the cancelli, as usual, as the shaft is everted. No osseous union apparent, though the parts are pretty firmly fixed. The large and small trochanters are broken from the shaft and united; and there is some comminution of the adjacent parts.

From a man, fifty years of age (Hospital, 251, 158), who reported that his right leg had been shorter than the left, "from an unreduced dislocation" two years previously. 1863.

Dr. Calvin Ellis.

1082. Old and strongly united fracture. The neck, with a small portion of the great trochanter, anteriorly, is broken from the shaft, and stands off at a right angle from it; and the largest portion of the trochanter is broken from the shaft, posteriorly. There is also a detached piece of bone, of considerable size, that was felt, and was quite movable before dissection, and may, perhaps, have been the small trochanter.

From a female, fifty years of age, or more. No. 1032 was from the same subject. 1865.

Dr. Wm. C. B. Fifield, of Dorchester.

1083. Old and strongly united fracture of the neck at its junction with the shaft, and from which last it stands off at a right angle; the head being much depressed. Both trochanters are also broken off in one piece. 1847.

Dr. J. C. Warren.

1084. Cast, in plaster, of the whole femur, showing a fracture of the neck from the shaft, from which it stands off as in

the last case; the head being here, also, much depressed. Great trochanter broken. Rotation outward below the fracture, to the extent of about one-fourth of a circle. 1847. *Dr. J. C. Warren.*

1085. Cast, in plaster, of the upper portion of the femur, showing a fracture of the neck of the bone, and in which there was osseous union; a case in which there has been much difference of opinion as to the seat of the fracture.

This case was fully reported by the late Prof. R. D. Mussey, in the *American Jour. of Med. Sc.* for April, 1857, with three figures; and copied, with the same, by Dr. Hamilton, in his work on *Fractures, etc.* The patient, a man seventy years of age, fell upon his left hip from a wagon, and Dr. J. C. Dalton, of Lowell, who saw him, reported eversion, crepitus, and shortening by more than an inch. Four or five days afterward he was carried home more than a hundred miles; and eighteen days after the accident Prof. M. saw him. He found considerable eversion, very little pain, and no shortening. The man could support the limb upon the floor for a minute or two, as he stood erect, and Prof. M. thought that there was no fracture. In four months he could walk with a cane; and three years and eight months afterward (Dr. D.'s statement) he died of internal disease.

The neck is much shortened, and the head more than half an inch below the top of the trochanter; shaft rotated outward; head $\frac{1}{3}$ in. from intertrochanteric line posteriorly, and $1\frac{3}{8}$ in. anteriorly. A section showed perfect consolidation by bone. The specimen has been examined by various surgeons in Europe, as well as in this country, and their various opinions are given by Prof. M.

When this case was entered in the manuscript catalogue of the museum, in the year 1850, Dr. Dalton furnished a history of it, in which he described a shortening of at least $2\frac{1}{2}$ in., a ready reduction, but an immediate return of the limb to its former position, and an entire loss of power below the hip; crepitus was not alluded to. 1847.

Dr. J. C. Warren.

1086. A fracture that, in the recent state, must have very closely resembled No. 1057, and strongly united by bone.

From a woman, æt. seventy, who fell upon her side, and was thought unequivocally by Dr. C. to have fractured the neck of the bone, when he saw her soon after the accident. He did not wish to distress the patient by making a critical examination of the limb, but founded his diagnosis simply on the total loss of power that she had over it. For two and a half or three months she was kept upon her back, with the knee flexed, and two pillows beneath it; and then she began to sit up, with the limb extended. Crutches were afterwards used; then a crutch and a cane; and for the last two and a half years she used neither, though she was able to go about the house, and somewhat out of doors, limping a very little, but without any pain. There was, however, a great deal of pain during the first few weeks after the fracture. Her general health had been quite good; and she died, of internal disease, four years and seven months from the time of the accident. After her death there was a shortening of the limb to the extent of about three-fourths of an inch, but no eversion was noticed.

The head of the bone is depressed, and bent obliquely downwards and backwards towards the lesser trochanter, with rotation outwards of the shaft. Anteriorly the neck projects somewhat beyond the margin of the head, whilst posteriorly it is impacted beneath it, and into the head; leaving a fissure, or separation of the fragments at the seat of fracture, as usual.

A longitudinal section having been made through the middle of the head and great trochanter, and in front of the small trochanter, the cut surface shows throughout a most complete bony union. Upon the posterior half the cortex or outer shell of the neck extends quite across this surface. Upon the other half it extends nearly one-half across, from below, and beyond this the cancellated structure is as continuous with that of the neck as if the bone had never been broken.

This case, and No. 1057, have been reported by Dr. H. J. Bigelow, in his work on Dislocation and Fracture of the

Hip, and the specimens have been figured as they appear externally.

The section was very much nearer to the posterior than to the anterior face, and, since the above was in print, a second has been made through the anterior half of the bone; but the result is about the same. 1869.

Dr. Benjamin Cushing.

1087-8. Fracture of the neck, within the capsule; section.

The anterior half has been dried, and includes the whole circumference of the neck at the seat of fracture; the posterior parietes of the neck extending across the section as a compact line of bone. Along the external surface of this line the cancellated structure of the neck is united, firmly and throughout, though only to a limited extent; the head being thus immovably fixed upon the shaft. The neck is almost entirely absorbed. Upon the outer surface of this anterior half there is a deep fissure between the fragments, from which a dense fibro-cellular tissue was removed, in the preparation of the specimen, and that would seem to have been the result of eversion. The separation amounted, at the maximum point, to about half an inch, and the opposing surfaces are rough. The other half of the bone is in spirit, and shows the dense tissue that closely unites the fragments, but there is no bony union, and the head considerably overlaps the neck of the bone.

The following is an abstract of a history of this case, which, with remarks, and a drawing of the specimen, was published by Dr. W. in the Mass. Med. Society's edition of Sir A. Cooper's work on Dislocations and Fractures of the Joints.

The patient was a gentleman, seventy years of age, who fell and struck upon the left trochanter as he was ascending the steps of the State House. He was able, however, to walk up to the Senate Chamber, where he remained an hour and a half, and took part in the debates, but was then obliged to go home in a carriage, and Dr. W. saw him. There was no change in the appearance of the limb, no crepitus, and only a moderate pain on strong outward rotation or strong flexion of the thigh upon the pelvis. Dr.

W. regarded it as a fracture within the capsule, but never thought it necessary to apply any apparatus. For some days the patient persisted in getting out of bed, as he could not believe that there was a fracture; and he would also frequently, in the course of treatment, move the limb by moving his whole body for the sake of experiment, and in spite of remonstrances. There was no eversion nor shortening; and as, at the end of eight or nine months, the pain on motion, and the tenderness had diminished, he was advised to move from the bed to the sofa; but it was about two months before he would make the trial. From this time he improved so that he was afterward frequently able to drive out, though he had to be carried down-stairs; and he could swing the limb freely, when supported, though he could not bear his weight upon it, nor use crutches. Death finally occurred two years and a half after the accident; and after an illness of three days. On dissection, the capsular ligament was thickened, and a slight rising of the bone, just at the edge of the articular surface, indicated the line of the fracture. 1847.

Dr. J. C. Warren.

1089. Upper portion of the femur, from a case of old fracture. The neck is so far absorbed, that the head approaches the small trochanter very nearly, and at that part there is bony union to a considerable extent. Otherwise the upper fractured surface, close to the head, in its present macerated and dried condition, is rough; whereas the lower or opposite surface is smooth, and the cancelli are covered over by a thin layer of bone. The two surfaces are but little separated from each other. The whole bone is very light in structure, and shows that there had been outward rotation.

The following history of the case was received from Dr. Charles L. Knowlton, of Ashfield, after the death of his father, who sent the specimen to Dr. B. The patient was eighty-three years old, and fell at her door; and, when seen by Dr. K., Sen., shortly afterward, the fracture was recognized. There was very marked shortening, eversion of the foot, and much pain when the limb was moved, for about a year after the accident. Her health then improved, and

there was little or no pain. Died in 1846, after a short sickness, seventeen months after the accident. 1856.

Dr. H. J. Bigelow.

1090. Old and ununited fracture of the neck of the femur; a portion of the pelvis being preserved with the bone. Prepared by Dr. Cheever. In spirit, and described by Dr. Bigelow:—

“This specimen shows in a remarkable manner the ilio-femoral or Y ligament, and the obturator internus muscle, in their relations to the displaced bone, in a case of old and unimpacted fracture of the neck of the femur. The neck is wholly absorbed, leaving within the socket, to represent the head of the bone, a movable hemisphere, with a smooth, flat, external surface. In direct contact with this is the shaft of the femur, which, by attrition, has become excavated. The whole neck having been absorbed, the femur slides upon the flattened head to the extent of an inch or two; the contiguous fibro-cartilaginous surfaces being quite smooth.

“A point of great interest in this specimen is the mechanism by which this motion is limited. The patient standing in an upright position, the weight of the body was of course suspended by the ligamentous fibres. Upon careful dissection, these are found to consist, in part, of the capsule of the joint, and in part of the obturator internus muscle; each of which may be here separately described. The capsule of the joint, while thin upon its lower aspect, and contributing little to the support of the body, is quite thick at its upper part; the Y ligament being developed in a remarkable manner. Although the lower branch of the Y, usually described as the ilio-femoral ligament, and commonly the stronger of the two, is here comparatively atrophied, the outer and upper branch is hypertrophied to a remarkable degree, and has obviously been the principal agent in suspending the weight of the body. A curious confirmation is thus afforded of the existence of this outer band, which I have elsewhere described as playing so important a part in dislocations of the hip. The outer and upper part of the capsule is also somewhat developed.

“A second point of interest is the development of the obturator internus muscle, which is enlarged and elongated so as to form a posterior suspensory ligament. The body was obviously slung in this case between the external Y ligament in front, and the obturator internus muscle behind. And the tendinous material of the latter is so developed as to justify its description as a tendon inserted at its small extremity into the trochanteric fossa, while it is expanded at its large extremity into a firm fascia overlaid with muscle, and which covers the foramen ovale and adjacent bone. The important part performed by this muscle, in this specimen, corroborates the view I have elsewhere taken of its function in dislocation of the hip.

“Having described the agencies by which the body is suspended, it only remains to add that the inner and atrophied branch of the Y ligament may have served in this case, and in default of other ligamentary fibres, to limit abduction, and especially extension of the femur.” 1865.

Dr. H. J. Bigelow.

1091. A second specimen. Upper part of the femur; in spirit.

- The neck, which is almost entirely absorbed, seems to have been broken within the capsule; and, the capsular ligament being thickened, and firmly adherent about the seat of injury, a close and firm fibro-cellular union must have taken place; the motion being now inconsiderable. There is strong eversion, and the centre of the head is about $1\frac{1}{4}$ in. below the top of the great trochanter, which last is also partially broken.

From a woman, æt. seventy-four years, who was run over in the street, and lived nearly 7 months after the accident; dying suddenly from cardiac disease. Not confined to her bed, but had great pain, with much eversion, and shortening to the amount of an inch. 1856.

Dr. S. D. Townsend.

1092. A third specimen; macerated. Slight concavity where the neck should be. Most of the head remains as a detached piece; and the opposing surfaces, as well as the original articular surface are smooth, though somewhat

irregular ; there being a considerable osseous deposit about the edges as from chronic arthritis. In the recent state the head was connected with the acetabulum, and also with the shaft by light and long bands of fibro-cellular tissue. 1858. *Dr. R. M. Hodges.*

1093. A fourth specimen. The patient, when eighty years of age, fell from a low chair upon the floor, and never walked afterward, except by pushing a chair before her ; being unable to use crutches. Limb shortened 3 or 4 in. Little or no pain for two or three years ; but, for two years before her death, which occurred five years and a half after the accident, the pain was extreme, and of a neuralgic character.

The bones having been macerated, there is seen to be a complete absorption of the neck, as usual in such cases ; the new articular surfaces being very uneven, and with some eburnation, especially upon the shaft. Upon the original articular surface of the head is a considerable deposit of new bone, as from chronic arthritis. 1860.

Dr. H. E. Clap, of Wrentham.

1094. A fifth specimen ; upper third of the bone shown, with the head macerated. In the place of the neck is a slightly concave and rough surface. Remains of the head of the bone about two-thirds of its original size ; fractured surface slightly rough, with some new deposit upon the articular surface. 1860. *Dr. R. M. Hodges.*

1095. A sixth specimen ; macerated. The head is mainly preserved ; the articular surface being generally quite smooth, but with considerable deposits of new bone upon it. The opposing surfaces of the two fragments are cicatrized, and the neck is mostly absorbed, but a portion of it remains with each fragment. Bones atrophied. 1860.

Dr. R. M. Hodges.

1096. A seventh specimen ; in spirit. Fracture at the junction of the head and neck ; with some fibrous union, but a considerable separation between the fragments. Neck wholly absorbed. 1847. *Dr. J. C. Warren.*

1097. An eighth specimen. Upper part of the femur; in spirit. Old fracture, with complete absorption of the neck. Head somewhat reduced in size; cartilage extensively absorbed, with appearances as of old cellular adhesions; fractured surface covered by a thin membranous pellicle, and connected with the shaft by strong fibrous bands, that are long enough to allow of very free motion.

From a woman, æt. eighty-two years, who fell whilst walking, in February, 1852, and died in the summer of 1857. The limb shortened immediately; and Dr. W. thinks, to the amount of about 2 in.; remaining in whatever position it was placed. Very little pain; and three months after the accident she was able to move about on crutches. 1858. *Dr. Jonathan Ware, of Milton.*

1098. A ninth specimen. There is a close and firm ligamentary union; and the specimen has been ingeniously prepared, and handsomely mounted by Dr. Beach, so as to leave the fragments in connection, and yet show the motion that there is between them. The capsular ligament has been turned back; and in it are two or three pieces of bone, of considerable size, that may have been the result of arthritis. Nothing is known of the history of the case; but with such a limb the patient may have got about tolerably well. 1869. *Dr. R. M. Hodges.*

1099. A tenth specimen. Fragments separated by maceration. The neck of the bone has been entirely absorbed, and the head rested and probably moved freely upon the shaft as far down as the small trochanter; there having been no attempt at union. The articular surface was somewhat eburnated, but mainly covered with a tissue that looked not very unlike cartilage, though the microscope showed it to be only a condensed fibrous substance. At the time of the dissection, a hollow was observed among the muscles above the femur, and into which this bone would crowd when the patient walked.

From a man, over sixty years of age, and who, eleven years before his death, was crushed down by a very large and heavy weight, that fell directly upon him. There was

not much motion between the fragments, but enough to show considerable comminution. A closely fitting swathe was applied, with such extension as was practicable to keep the limb quiet, and after some weeks he was able to get up, and gradually move about on crutches. After a time he could get along with two canes, and this he did until his last sickness, — walking sometimes several miles at a time. He finally died with some affection of the heart and kidneys. 1869. *Dr. B. E. Cotting.*

1100. The upper portion of the femur, misshapen, broad, flattened antero-posteriorly, rough over most of the surface, with irregular, sharp, projecting laminae of bone between the trochanters posteriorly; the head and neck rising almost erect, and in a line with the shaft. Structure heavy and dense. Perhaps the result of fracture. 1847.

Dr. J. C. Warren.

1101. A fracture of the neck from the shaft; extending obliquely downward to about 2 in. below the great trochanter. A large piece of bone, $3\frac{3}{4}$ in. in length, is also split off from the front of the shaft.

The patient, Dr. S. L. D., æt. seventy-three years, was walking, with both arms closely wrapped in a shawl, when he slipped upon the ice and fell heavily upon a brick pavement. The limb was found shortened $1\frac{1}{2}$ in., with much swelling and ecchymosis, distinct crepitus, and much eversion of the foot. Put upon an inclined plane. Chills and fever ensued, with jaundice; and he died on the forty-seventh day. Large and extensive effusion of dark and disorganized blood found in the thigh on dissection. 1868.

Dr. John O. Green, of Lowell.

1102. A recent fracture of the femur, midway. From a child, five years old, that was run over by a truck. The soft parts were most extensively injured, and amputation was done at once (June, 1858) at the hip-joint, — the child living nearly a fortnight.

This was the first time that the operation was performed in this city. (Hospital, 78, 63; and Med. Jour. Vol. LIX. p. 284.) 1858. *Dr. J. M. Warren.*

1103. A strongly marked specimen of recent, oblique fracture of the upper half of the femur; neck scarcely involved. From a man who was thrown down in the street, and kicked. Shortening, $1\frac{3}{4}$ in. (Hospital, 97, 220.) 1862.

Dr. G. H. Gay.

1104. Portion of a femur, showing a recent and transverse fracture of the shaft midway. From a man who was run over by a heavily loaded wagon. (Hospital, 97, 222.) 1861.

Mr. John Homans, med. student.

1105. Fracture of shaft of femur, midway. Union strong, but quite irregular. The fragments form an angle outward, are not in apposition, and the upper fragment, as so generally happens, is in front of the lower. 1847.

Dr. J. C. Warren.

1106. The femur of a large male, dissecting-room subject. Upon the anterior and outer part of the bone, midway, is an appearance as if it may have been cut by an axe; the bone being raised, as it often is in old sabre cuts of the skull, and to the extent of more than 4 in. The surface is perfectly healthy about it; but upon the head and neck there is some osseous deposit. 1860.

Dr. R. M. Hodges.

1107. Femur curved somewhat abruptly at upper third outward and forward; outline regular. The result of an old fracture. Sawed lengthwise; bone atrophied, and the cavity interrupted at curvature. 1847.

Dr. J. C. Warren.

1108. A second specimen, in which the curvature is very much greater. Sawed open, and the canal is seen to be interrupted. 1847.

Dr. J. C. Warren.

1109. A third specimen; similar to the last. New osseous growths about condyles, as from chronic arthritis; and some about the seat of injury. 1847.

Dr. J. C. Warren.

1110. Portions of the shaft of the femur, removed for ununited fracture midway; one is $1\frac{3}{4}$ in., and the other $2\frac{1}{4}$ in. in

length. Extremities rounded, with some new bony deposit.

From a man who entered the hospital (107, 86) March 10th, 1863, just after the accident. Limb shortened $2\frac{1}{2}$ in. Dec. 5th a seton was passed between the fragments. June 4th, 1864, the bones were drilled, and again July 20th. Nov. 12th Dr. B. did the operation that has already (p. 164) been referred to, and with perfect success. April 26th, 1865, the wire was removed. On the 1st of June the man walked about on crutches; and on the 12th of July, when he left the hospital, the femur was perfectly firm. On the 10th of Nov., when he again showed himself at the hospital, he walked without the aid of a cane, and not the least motion could be detected in the femur. (Med. Jour. Vol. LXXVI. p. 325.)

The wire is shown with the bones. 1865.

Dr. H. J. Bigelow.

1111. Upper half of the femur, with an abundant earthy periosteal deposit, toward the lower extremity. Structure generally light. From a young subject. Probably from a case of ununited and rather recent fracture. 1847.

Dr. J. C. Warren.

1112. Fracture just below the middle of the shaft, and strongly united, but with considerable shortening. The central cavity of the fragments, as they overlap, being separated by a coarse cancellated structure, into which the hard walls have become changed.

From a male, dissecting-room subject. The limb was very much bowed outward; and the bone, at the seat of fracture, seemed to be just beneath the skin. Sawed longitudinally, and prepared by Dr. H. 1857.

Dr. R. M. Hodges.

1113. Fracture of the femur, at the junction of the middle and lower thirds. Union strong, though the bones have overshoot $2\frac{3}{4}$ in.; the upper being inside, and rather in front. 1847.

Dr. J. C. Warren.

1114. Lower half of the femur, sawed longitudinally, and one-

half preserved; showing the effect of an old fracture. The fragments are bent to a right angle, and firmly united. Both are diseased; and about the upper is an old periosteal deposit. At the seat of injury there is a large cavity in the interior, that seems as if it may have communicated with another external to the bone. From a young subject. 1847.

Dr. J. C. Warren.

1115. Old fracture of the left femur, $4\frac{1}{2}$ in. from the lower extremity; lower portion of bone shown, and sawed longitudinally. Union strong, but very irregular, though not overlapping; lower fragment drawn backward. Structure of the connecting bone seems to show that the accident could not have been an old one. In this connecting bone is a large cavity, smooth upon the inner surface, and looking as if it may have contained a piece of bone, or some foreign body; a small fragment of lead being seen near the opening from it. 1864.

1116. A portion of the femur, showing a comminuted fracture of the lower third; the especial point of interest, being a contusion or breaking down of the cancelli of the outer condyle. Some appearance of absorption, and of an attempt at exfoliation. The fragments are united in their natural position. From a man who fell from the staging of a house, and lived six weeks. (Hospital, 79, 70.) 1859.

Dr. H. G. Clark.

1117. Comminuted fracture, just above the condyles of the femur. Union imperfect, and exceedingly irregular. Bones most remarkably atrophied; the knee-joint being included in the preparation.

From a woman, between eighty and ninety years of age, and in whom many of the other bones were found broken. 1847.

Dr. J. C. Warren.

1118. An oblique fracture, just above the condyles; and a second, between these two, into the knee-joint. The upper fragment is drawn downward in front of, and 2 in. below, the knee-joint; its pointed extremity being far advanced in the process of separation, and showing finely the contrast

between the living and the dead bone. A considerable quantity of new and soft bone connects this upper fragment with the shaft above the inner condyle.

From an intemperate man, æt. thirty-seven years, who slipped and fell with the whole weight of his body upon this limb. On entrance into the hospital (28, 331) Dec. 20th, 1844, there was a shortening of 2 or 3 in., considerable swelling and emphysema about the knee, and a protrusion of the upper fragment nearly an inch, with great pain, and considerable bleeding. The fracture was reduced, but the bones could hardly be kept in place; and on the third day, the extension being discontinued, on account of the pain and swelling, the limb was simply laid in a fracture box. Suppuration and sloughing followed. Feb. 5th the limb was much shortened, and the upper fragment seemed to have penetrated the knee-joint beneath the patella. On the 11th of March it protruded below this bone, and on the 11th of April the man died. 1847.

Dr. J. C. Warren.

1119. A portion of the femur, 2 in. in length, and evidently separated from one of the fragments in a case of compound fracture; being a completion of the process that was going on in the last case. 1847. *Dr. J. C. Warren.*

1120. A portion of femur, more than an inch in length, and probably sawed off in a case of compound fracture; there being no appearance of necrosis, nor of its having been previously amputated. The canal is closed by a deposit of new bone. 1847. *Dr. J. C. Warren.*

1121. Recent oblique fracture of the lower third of the shaft. Lower fragment much comminuted, and looks as if the individual may have been run over by a loaded wagon. 1856. *Dr. H. J. Bigelow.*

1122. The lower portion of the femur, showing an extensive breaking down of its surface, in and near the popliteal region, with flattened shot sticking in the bone.

From a young man, æt. eighteen, who accidentally received a charge of shot from a fowling-piece. Dr. B. found

ten or twelve shot-holes, but with little swelling, and no hemorrhage. On laying the parts open, however, the finger could be passed freely about in the popliteal space; and the injury being evidently very extensive, the limb was amputated six or eight hours after the accident, and the patient did well. 1856. *Dr. H. J. Bigelow.*

1123. Comminuted fracture of the inner condyle, with a conical ball in the middle and back part of the knee-joint.

The patient, an army officer, entered the hospital (106, 92) fourteen days after a wound, just above, and upon the inside of the knee. Two days after admission a large amount of pus was discharged through an opening upon the outside of the knee, and the inner condyle, which was found loose, was removed. Nine days after admission the limb was amputated by Dr. H.; and three or four days afterward severe chills came on, followed by dyspnoea, yellowness of the skin, and delirium. Six days after the operation he died.

The ball was found lying in the joint; the patella was fractured; and there was an extensive infiltration of pus into the soft parts. (*Med. Jour. Vol. LXXIX. p. 357.*) 1863.

Dr. R. M. Hodges.

Fracture of the femur of a civette; very regular union. See atrophied bones.

1124. Fracture of the femur of a fowl. Union strong, though the fragments are much separated. The bone having been cut away upon one side, the cancellated structure that connects the two fragments is shown, and the continuation of the cavity of these last to the seat of fracture. 1853.

1125. A second specimen. Union not very irregular; and, on section, the relation of the two fragments is shown. 1867.

Dr. J. B. S. Jackson.

1126. Knee-joint, preserved in spirit, and showing a complete separation of the condyles of the femur from the shaft. 1847. *Dr. J. C. Warren.*

1127. Lower portion of femur, dried, and showing the same. From a little girl, about five years old, who was run over

- by a truck. Amputation by Dr. Y., and the child did well.
1856. *Dr. J. H. York.*
1128. Old and transverse fracture of the patella, with ligamentary union; the fragments being about 2 in. apart.
1847. *Dr. J. C. Warren.*
1129. A second specimen; separation about half an inch. No enlargement of the fragments. The other patella had previously been broken. 1862. *Dr. H. J. Bigelow.*
1130. Recent fracture of the patella, and somewhat comminuted.
1857. *Dr. H. J. Bigelow.*
1131. Fragments from a case of old, and irregularly transverse fracture of the patella; a small piece having been broken off from one of them. The separation amounted to about half an inch.
From a middle-aged male subject. 1867.
Dr. D. W. Cheever.
1132. A small piece broken from the edge of the patella; not separated as in transverse fracture, but not united. 1847.
Dr. J. C. Warren.
1133. Very irregularly oblique, and comminuted fracture of the upper half of the tibia, into the joint. Produced after death. 1847.
Dr. J. C. Warren.
1134. Recent, oblique fracture of the lower half of the tibia.
1847. *Dr. J. C. Warren.*
1135. A portion of the tibia, and probably of an ox, showing the same. 1847. *Dr. J. C. Warren.*
1136. Old fracture of the tibia of a deer, united quite as regularly as in the average of cases in the human subject.
1860. *Dr. S. Kneeland, Jr.*
1137. An old, oblique fracture of the tibia. Union regular.
1847. *Dr. J. C. Warren.*
1138. Cast of a leg, with 4 in. of the tibia, that were removed

from it on the day of an injury. Presented to Dr. L. by Dr. J. H. Armsby, Surgeon of the Military Hospital at Albany, N. Y. 1869. *Dr. G. H. Lyman.*

1139. Old fracture of the tibia, just below the ligament of the patella, and of the fibula opposite to it. Union not very irregular. 1860. *Dr. R. M. Hodges.*

1140. Oblique fracture of the tibia, just below the middle of the bone. Union very regular along inner surface. Inclines toward fibula; and toward this last, anteriorly, is an opening, about half an inch in length, that leads into the interior of the bone at the seat of the fracture, but without any appearance of disease about it. 1857. *Dr. R. M. Hodges.*

1141. Portion of the tibia sawed open, in case of an old, oblique fracture. 1858.

Mr. Chas. F. Crehore, med. student.

1142. Old and compound fracture of the tibia and fibula. Union regular, but with a considerable growth of new bone about the seat of injury. From a man, ninety years of age. (Hospital, 119, 84.) There was not much irregularity over the fracture; but the limb was shortened $2\frac{1}{2}$ in. Prepared by Mr. G. W. Tarbell, house-pupil. 1865.

Dr. H. J. Bigelow.

1143. Fracture of both bones, 3 or 4 in. above the ankle; that of the tibia being very oblique. Union sufficiently strong; but with some shortening, and with chronic inflammation of the tibia.

The patient, an elderly woman, had a compound and comminuted fracture; and eighteen months afterward Dr. G. amputated the limb for an extensive and intractable ulcer, that followed the accident. The patient did well. 1855. *Dr. Thomas H. Gage, of Worcester.*

1144. Old fracture of both bones, just above the ankle. 1847.

Dr. J. C. Warren.

1145. Bones of the leg, ankylosed toward the lower extremity,

- with probable fracture, and some appearances of ostitis.
Tibia sawed. 1860. *Dr. R. M. Hodges.*
1146. Old, oblique fracture of tibia, just above the ankle; and of the internal malleolus. Union strong, but with a considerable inward curvature. 1847.
Dr. J. C. Warren.
1147. Oblique fracture of tibia, near the ankle-joint. Union strong and regular, with ankylosis to fibula. 1858.
Dr. R. M. Hodges.
1148. Fracture of both bones, at lower third, and somewhat comminuted. Union strong, though some openings remain at the seat of injury. There is also ankylosis between the bones. 1847.
Dr. J. C. Warren.
1149. Upper extremity of the tibia, broken from the shaft, and through into the joint. One fragment is united by bone to the outer condyle of the femur, and stands off from it at an angle of about 45°. From the back of the other fragment a small piece has been broken off, and imperfectly united; and from its lower extremity a considerable piece of dead bone is being separated. Some new deposit is seen upon both fragments. 1847. *Dr. J. C. Warren.*
1150. Old fracture of the fibula through its lower articular surface. 1847.
Dr. J. C. Warren.
1151. A second specimen. Now dried, but showing, when recent, a free articular surface between the fragments. From the same case as No. 1021. 1866.
Dr. D. W. Cheever.
1152. A third specimen. 1847. *Dr. J. C. Warren.*
1153. A very marked, defined, and regular enlargement of the tibia, in its lower third, about 2 in. in extent, involving equally the whole circumference, and that may be called fusiform. Having been sawed longitudinally by Dr. Hodges, the walls of the bone, at the affected part, are dense as well as thickened; and the cavity, though not

perfectly obliterated, is filled with a denser cancellated structure than elsewhere. The bone is otherwise quite healthy; and, though the idea of a syphilitic node has been suggested, there can be no reasonable doubt that the bone had been fractured. 1847. *Dr. J. C. Warren.*

1154. Abrupt and very marked curvature of the shaft of the fibula; and possibly the result of fracture. 1847.

Dr. J. C. Warren.

1155. Old fracture of the tibia, just below the middle of the bone, and followed by periostitis. Surface rough; and the lower half much enlarged and porous. On section, the cavity is seen to be obliterated, and the walls of the lower fragment are quite thin. The irregularity at the seat of fracture is slight, and externally hardly perceptible, in consequence of the extensive and very thick periosteal deposit, so that the existence of a former fracture would be very questionable, if the fact were not known.

The patient was a healthy man, about forty-five years of age, and had his limb amputated in 1861. Twelve years previously he had a compound fracture of both bones, with extensive laceration of the soft parts, and never worked from that time. An ulcer formed, which never healed, and the whole limb became swollen, œdematous, and livid. Health quite good since the operation. 1864.

Mr. J. H. Chandler, med. student.

1156. Compound fracture of both bones of the leg, near the ankle. The end of the tibia is separating, and above the dead line new bone has been thrown out; the lower fragment is quite detached, and is broken through into the joint, but with some appearances of union. The lower fragment of the fibula is quite comminuted, but with some union. From a man, æt. sixty. (Hospital, 77, 166.) Amputation at the end of two months, and the patient did well. 1858.

Dr. H. J. Bigelow.

1157. Portion of the tibia, that must have been removed from a case of compound fracture. A large piece of bone at the fractured extremity is dead, and in the process of separa-

tion ; the distinction between the dead and living bone being strongly marked. A very interesting appearance in this specimen is the action of the absorbents upon the bone that is dead, showing that originally the separation was to have taken place lower down than where it was going on at the time of amputation or death. 1847.

Dr. J. C. Warren.

1158. Fracture of the tibia and fibula ; not old. A considerable quantity of new bone is seen upon the surface of the fragments ; and the fibula is united, but the tibia is not ; a separation of dead bone is going on from both fragments of the tibia. 1858.

Dr. J. M. Warren.

1159. Both bones fractured at about the lower third ; from a young subject. Union irregular, and rather imperfect. 1847.

Dr. J. C. Warren.

1160. A preparation, by Dr. H., showing the result of a neglected fracture. The foot is strongly flexed upon the leg ; the tibia is bent to a right, and the fibula to an acute, angle ; and the union, though very close, is not osseous.

The patient, a healthy lad, sixteen years of age, was observed, when two or three days old, to have some trouble with his leg, and soon afterward the fibula was found to be broken. No treatment. At the age of two years the leg began to yield, and in six months it was bent to a right angle. When he was eight years old, the bones were removed at the angle, the tendo-achillis was cut, and for a time it was kept in proper position. The mother, however, entirely neglected the child, and the leg was soon nearly as bad as ever. Last year Dr. H. amputated the limb, and the lad has since done well with a Palmer's leg. 1857.

Dr. J. E. Hathaway, of Worcester.

1161. Cast, in plaster, of a foot and leg, that must have most remarkably resembled the last case.

The patient, a little girl, eleven years of age (Hospital, 57, 102), broke her leg when six years old ; and, her mother being a drunkard, nothing was done for her. The tibia seemed to have been broken about $2\frac{1}{2}$ in., and the

fibula about $1\frac{1}{2}$ in. above the joint; and the union was firm. The lower fragments were bent strongly forward upon the dorsum of the foot, and the upper fragments were united to them at a right angle. The bones were forcibly broken down, the tendo-achillis was cut, and the parts kept in proper position, but the result was only partially satisfactory. 1856.

Dr. H. G. Clark.

1162. A third case, in which the fragments are bent upon each other, and the lower one upon the foot, precisely as in the two above cases. A ligamentary preparation.

The patient was a delicate girl, twenty-two years of age, and one of the lowest prostitutes. The bones were broken when she was five or six years old, and her case was entirely neglected. In the spring of 1862, Dr. Carney, who was then the physician of the Bridgewater State Almshouse, cut out about 1 in. each of the tibia and fibula; the tibia being very sharply flexed, and closely united, though not by bone. (See next specimen.) The limb, which was straightened, was $1\frac{1}{2}$ in. longer than before, and union was progressing well. Six weeks after the operation, Dr. C. resigned his situation; and his successor, finding the union incomplete, rubbed the ends of the bones together, with a view to complete it, and continued this treatment for three weeks. From the time that she left B. she walked without crutches, and flat upon the sole of the foot; limb bowed outward, and very much shortened, but much less than before the operation; considerable stiffness at seat of fracture. The union is seen to be very close, but it is not osseous. In January, 1866, the patient died at another almshouse. 1866.

Dr. D. W. Cheever.

1163. Fragments of bone, from the last case. 1867.

Dr. Sidney H. Carney.

1164. Portion of a tibia, enlarged and quite rough about and toward one of its extremities, as from inflammation; and, otherwise quite healthy. Perhaps from a case of ununited fracture. 1847.

Dr. J. C. Warren.

Old fracture of the tibia of a deer; union quite as regular as in the average of cases in the human subject. 1860. See No. 1136. *Dr. S. Kneeland, Jr.*

1166. Old fracture of the metatarsal bone of a bird, and probably an eagle. Union very irregular, and with some shortening. Nate also shown. 1859.

1167. Fracture of the under surface of the astragalus; and perhaps one or two of the adjoining tarsal bones are involved. Cartilage entirely gone from the upper surface, and the surface generally is quite smooth. Articular surface of tibia covered with a soft, cellular tissue. In spirit. 1847. *Dr. J. C. Warren.*

For very numerous and probably partial fractures in a rickety skeleton, see next series.

II. DISLOCATIONS.

1168. The cervical vertebræ, showing a complete rupture of the intervertebral substance between the sixth and seventh bodies, and a dislocation forward of the sixth upon the seventh, upon the right side; a very small piece of bone only being broken from the body of the seventh.

From a laborer, twenty-one years of age, who entered the hospital (13, 90) three hours after a bank of earth fell upon him. When first seen he groaned constantly, and complained of universal pain. Sensibility sufficiently well. Some power of motion of upper extremities, but none of the parts below. Could not raise his head from the pillow; and any attempt by another to raise it, or the upper extremities, caused pain. Skin very hot; and pulse 80. He lived thirty days; and, meanwhile, the symptoms were about the same. Respiration entirely diaphragmatic. Urine retained at first, but afterward involuntary. Dejections mostly, if not wholly, involuntary; and toward the last costive. Abdomen tense and tympanitic. Very restless, and groaned much; but could not localize his pain. On the fifteenth day two large sloughs were reported over the sacrum, and from that time he gradually sank. 1847.

Dr. J. C. Warren.

1169. Very extensive dislocation between the two first cervical vertebræ; probably the result of chronic disease. A cast in plaster; the original having been purchased in Paris by Prof. R. D. Mussey. When the atlas is horizontal, the body of the axis is thrown backward at an angle of about 45° ; the spinous processes being separated to the extent of half an inch, and the odontoid, which is very much altered in form and position, approaching to within about one-fourth to one-twelfth of an inch of the arch of the atlas. Anteriorly, the body of the axis was considerably separated from that of the atlas, but the two were connected by delicate bony fibres. The articulating processes were ankylosed. 1854. *Museum Fund.*

1170. Cast, in plaster, of the front of the chest. From a case of old dislocation of the left shoulder-joint. The head of the bone projects forwards from the upper part of the axilla; and the acromion is prominent. From a male subject. (See next specimen.) 1866. *Museum Fund.*

1171. Scapula, and upper part of the humerus, from the above case. A large amount of new bone has been thrown out upon the inner surface of the first, and just below the coracoid process; and the articular surface thus formed is concave, irregular and porous, but solid in structure. The surface of the glenoid cavity is quite irregular, but not reduced in size. The coracoid process is large; and the under surface, which is irregular, and with a trace of eburnation, had formed a part of the new articular surface. The upper part of the scapula shows a recent fracture, and the body of the bone seems to be atrophied. The great tuberosity of the humerus is entirely effaced; the head is large and misshapen, and the whole surface is irregular, with only a trace of eburnation. A small portion only of the head had been in contact with the new articular surface; and upon the back part a groove is formed by the throwing out of new bone, and corresponding to the edge of the glenoid cavity. In the recent state the head of the bone lay quite free in the new cavity; covered for the most part with a soft, red, fleshy tissue, and without cartilage. Some

small fragments of loose bone, that were found after maceration, may perhaps have been formed in the capsular ligament. There was also an old fracture of the clavicle. (No. 990.) 1866. *Dr. D. W. Cheever.*

1172. Old dislocation of the head of the humerus. The bones that form the shoulder, with a portion of the parietes of the chest, are prepared in connection; and show the head lying in a large and free cavity, beneath and nearly in contact with the clavicle, midway, and between the coracoid process and the ribs. No distinct appearance of a new socket. A large piece of compact bone is seen in the capsular ligament. 1847. *Dr. J. C. Warren.*

1173. Left scapula, and upper third of humerus, from a case of dislocation of ten months' duration.

The patient was less than fifty years of age, and under the care of Dr. J. Brown, Physician to the State Alms-house at Tewksbury; the dislocation could be reduced, but the bone could not be kept in place.

The false joint upon the inner surface of the scapula is strongly marked, and about on a level with the glenoid cavity, which last is about one-half destroyed; mostly rough, but in part eburnated. The coracoid process, which is broad, and upon the upper surface rough, is upon the under surface continuous with the false joint, and eburnated almost throughout. The head of the humerus is large and misshapen, and without any appearance of the great tuberosity or neck; surface partly eburnated, but elsewhere quite irregular. The capsular ligament, which has been preserved, shows several deposits of new bone. Prepared by Dr. H. 1858. *Dr. R. M. Hodges.*

1174. Left scapula, and part of the humerus, from a case of dislocation. From a man, *æt.* fifty years or more.

The new joint, which is very marked, appears upon the inner surface of the scapula, in the form of a high ridge of bone, and rather below the level of the glenoid cavity; there being a space of considerably more than an inch in extent between the ridge and the glenoid, upon which last there is scarcely any deposit of new bone. Surface of the

false joint rough and not large nor eburnated. Glenoid cavity well ; and coracoid process not at all involved. The head of the humerus is round, smooth, and quite healthy in appearance ; but posteriorly, and just behind the great tuberosity, is a deep groove that must have corresponded to the edge of the glenoid. Some growth of new bone from the summit of the tuberosity. 1858.

Dr. R. M. Hodges.

These two last specimens, and No. 1171, well illustrate the remark of Dr. Hodges, that in what is called dislocation into the axilla, the head of the bone is generally situated beneath the coracoid process.

1175. Humerus, from a case of dislocation, and showing a large and deeply indented cavity between the head and the great tuberosity. 1847. *Dr. J. C. Warren.*

1176. Lower portion of the humerus, from a case, probably, of old dislocation of the elbow. A large, irregular, somewhat excavated and defined surface exists upon the back of the external condyle ; and, upon the back of the inner, a considerable growth of bone, as if for the formation of a new socket. A large portion of the original art. surface remains, with some appearance of recent caries. Whole bone quite compact. 1847. *Dr. J. C. Warren.*

1177. Bones of the upper extremity, from a case, probably, of old dislocation inward of the elbow. The outer portion of the humerus, with the condyle, is entirely destroyed, and in their place is a rough and irregular surface. The inner condyle seems to have been absorbed ; and the olecranon cavity is being obliterated. The coronoid and olecranon processes are very much thickened, and the whole articular surface of the ulna much reduced in size, — the inner portion being quite beyond the limits of the humerus. The head of the radius is enlarged, the margin broad and projecting over the neck, and the whole is inclined outward. About the centre of the lower surface of the humerus is a shallow cavity for the head of the radius ; and a portion of the art. surface remains for a portion of that of the ulna.

The position of the forearm seems to have been one of partial flexion and eversion. 1847.

Dr. J. C. Warren.

1178. Scaphoid bone torn from the wrist; a small piece only having been broken off.

From a young girl who had her hand crushed between the cog-wheels in a mill, Oct. 17th, 1863. It was entirely separated from the radius; the radial artery and nerve, and the extensor tendons of the three first fingers being severed. On the 1st of February it had quite healed, with ankylosis upon the radial side; and the patient finally got a very fair use of the hand, though it never could be fully extended. 1865. *Dr. George J. Arnold, of Roxbury.*

1179. A dislocated semi-lunar bone.

From a man, who fell eight or ten feet, put out his hand to save himself, and struck his wrist upon some loose stones. A wound upon the palmar aspect, about 2 in. in length, was the result, and the bone, which lay in the wound, was retained only by a few shreds of tissue. The cuneiform bone was loosened, but easily replaced, and two small fragments of it are seen attached to the semi-lunar. The other bones were uninjured, and none of the tendons were ruptured, but there was an unnatural mobility of the wrist-joint, and the void left by the dislocated bone was easily detected, especially upon the back of the wrist; there being neither swelling nor deformity.

The case occurred in the practice of Dr. C., and the bone was removed by Dr. Hodges about four hours after the accident. On the sixth day swelling and inflammation commenced; suppuration of the cellular tissue as high as the shoulder was the result, and the man died on the tenth day.

Dr. H. remarked on the rarity of compound dislocation of a single carpal bone, except as the result of gun-shot or machinery wounds; the accident being caused in the few cases that he quoted, and with one exception, by a fall upon the palm of the extended hand; and the semi-lunar

bone being generally the one that was dislocated. (Med. Jour. Vol. LXXIII. p. 261.) 1865.

Dr. E. Cutter, of Woburn.

A case of dislocation of the semi-lunar bone, with some other injuries to the wrist, was reported to Dr. Hodges by Dr. David Mack, Jr., of Belmont. The bone was replaced, but amputation was subsequently required.

1180. Dislocation of the femur upward upon the dorsum of the ilium. The head is nearly or quite absorbed; but the extremity of the neck, which is but little if at all shortened, flares out so as to form a substitute for it. The new socket upon the ilium is sufficiently well developed, and the acetabulum nearly obliterated. Ilium pushed inward anteriorly, and above the brim of the pelvis. The lower extremities in the preparation (from Paris) are articulated with the pelvis, and the affected limb is turned inward and shortened about $2\frac{3}{4}$ in. 1852. *Museum Fund.*

1181. Cast, in plaster, of a case of dislocation into the obturator foramen; the head of the femur being quite prominent upon the inside of the pelvis. From the neck, anteriorly, there seems to have been a growth of new bone that connected it with the pelvis. Acetabulum deep, but small. Purchased at the London Hospital, 1852.

Museum Fund.

1182. Photograph of a little girl, six years old, who had a dislocation of the femur into the obturator foramen, of four years' duration. The thigh was strongly flexed upon the body, and the leg upon the thigh; and the whole limb was everted, separated from its fellow, wasted, and worse than useless.

The child entered the hospital (139, 253) June 18th, and on the 23d an attempt was made by Dr. B. to reduce the dislocation, but without success. The rectus femoris, and the fascia about it were divided; and the forcible twisting of the limb caused a partial fracture of the femur midway. This last united well, and by the use of extension and other mechanical means, the limb was so far improved, that when the child left the hospital, on the 12th of August,

she could bring the sole of the foot to the ground, though there was some shortening. 1869.

Dr. H. J. Bigelow.

1183-6. Four photographs of a soldier, who could voluntarily dislocate the hip; a front and side view, in natural position; and a back and side view, when dislocated. While skirmishing up a hill he sprang back suddenly, got his foot entangled, and his weight dislocated the hip. This being at once reduced, he marched seven miles, and from that time continued on duty for fifteen days, when he entered a hospital. From Dr. L.'s report: "He is able, at any time to luxate the hip-joint, and does it by pressing the foot on the floor, to fix it firmly. He then contracts the adductors, throwing out the pelvis, when the head leaves the socket, and goes on the dorsum." 1865.

Dr. George H. Lyman.

1187. Knee-joint dislocated; a wet specimen. The crucial ligament is torn from the femur; and the periosteum and outer lateral ligament are stripped up to the extent of $2\frac{1}{2}$ in. A very small piece is broken from the fibula, and this is the only fracture. 1847.

Dr. J. C. Warren.

1188-9. Permanent dislocation of the patella outward. Two casts; one shows the knee-joint flexed, and the other extended; the deformity being much greater in the first than in the last.

The patient was a lad, æt. 14-15 years; and the accident was caused three years before by a fall upon the knee, while skating. Half an hour after the fall he was able to continue skating, and for two or three days he perceived nothing unusual. Swelling and pain in the joint then came on, and for five months from that time he kept his bed. On getting up, Dr. C. found the outer edge of the patella apparently resting upon the outer condyle of the femur, and tilting the inner edge forward; the groove between the condyles being easily felt. The ligamentum patella was stretched upward and outward so as to keep the bone fixed; and it was narrower than the one upon the other side, as if it had been partially ruptured. The only

muscle that seemed to contract with energy in walking was the vastus externus. An indistinct transverse groove was felt above the patella; but it was impossible to say how far the connection between the muscles and the patella had suffered. The motions of the joint were quite free, and the patient only complained of a slight limp in walking.

Dr. C. remarked that Malgaigne had collected twenty-five cases of outward dislocation of the patella, and had seen two; Dupuytren had seen three; Boyer one; Sir A. Cooper one, and Liston none. 1866.

Dr. Algernon Coolidge.

1190. Cast of the foot, from a case of dislocation of the astragalus.

The patient was a man seventy-eight years of age, and the injury was occasioned by a fall when he was eight years old. He had always had pain, with lameness, and an enlargement of the ankle. After his death Dr. F., with permission of the family, went to Portland, Maine, and removed the foot. The cast was then taken, and the foot prepared by Dr. F.; (No. 1191.) 1869.

Dr. Wm. C. B. Fifield, of Dorchester.

1191. The tarsal bones, with a portion of the bones of the leg preserved in connection from the last case, and showing the following appearances: The astragalus is entirely separated from the os calcis, except to a small extent, as seen posteriorly; retains its proper relations to the tibia, but is turned inward to an angle of about 45° , so that its anterior rounded head is not one-half covered by the scaphoid bone, though there is a very considerable projection inward of this last, as if for the purpose of retaining the articulation. The os calcis, just behind its articulation with the cuboid bone, shows a large and very marked articular surface, and there is a corresponding one upon the very lower extremity of the fibula. There is a little twist of the tibia, induced by the inward revolution of the astragalus. Lower extremity of the fibula much enlarged, and directly in front of its articulation with the os calcis is a growth of new bone as large as the last joint of the finger. This last is discon-

nected ; but there is a considerable amount of new growth from the bones, the result of chronic arthritis. The cuneiform and cuboid bones are in proper relation to the os calcis. No appearance of fracture. 1869.

Dr. Wm. C. B. Field, of Dorchester.

1192. Upper half of the tibia, enlarged and misshapen. The upper articular surface inclines backward, and of the fæcettes that connected it with the femur, the inner one is upon the very back part ; the original articular surface in front being effaced by old disease. 1847.

Dr. J. C. Warren.

1193. Bones of the knee-joint, from a man about thirty years of age. Dislocation of the leg backward was very marked, as are also the changes upon the articular surfaces of the bones. 1855.

Dr. R. M. Hodges.

1194. The ends of the metatarsal bones are shown, with a considerable growth of new bone upon the inside.

From a man, æt. twenty-eight years. (Hospital, 101, 8.) Each of the toes turned outward, so as to make almost a right angle with the line of the foot ; the joints being much enlarged, with a clean ulcer, which would heal if he kept quiet, and having been sore every winter for eight years. The right great toe was amputated, with the head of the metatarsal bone. Upon the left side the joint was excised, but the opposing surfaces did not come in apposition. At the end of a month he was doing well ; the left foot being much more nearly healed than the right. 1862.

Dr. H. J. Bigelow.

III. DISEASES OF BONES.

1195. Thibert's model. Acute and superficial inflammation of the parietal bone and periosteum ; the result of a fall.

From a child. A crucial incision shows a slight erosion of the bone. 1847.

Dr. Geo. Hayward.

1196. Chronic inflammation of the lower jaw. The patient was a healthy girl, æt. fourteen, who entered the hospital June 15th, 1850 (44, 152). Eighteen months before, a bicuspid

tooth was extracted for toothache of a few days' duration, but without relief. Enlargement of the jaw soon commenced, increased from that time, and, on admission, extended from the right coronoid process to much beyond the median line upon the left side; but with no pain after the first three or four months. The bone was removed at once by Dr. B. from the articulation upon the right side to the first molar tooth upon the left, and in about five weeks the patient was discharged well. This year (1867) she has been heard from, and there has been no return of disease. The bone is regularly enlarged, excepting the coronoid process and the articular portion; structure compact, but rather coarse; surface rather rough, but nowhere carious. A wedge of bone was sawed out at the time of the operation, in order to ascertain the character of the disease. 1867. *Dr. H. J. Bigelow.*

1197. Daguerreotype of the above patient before the operation. 1867. *Dr. H. J. Bigelow.*

1198. The left humerus and the greater part of the right femur, showing a separation of the epiphyses, etc.; the result of acute inflammation of five weeks' duration.

The patient was a delicate lad, eleven years of age, and on the 15th of August, 1834, the disease commenced. On the 18th, there were active constitutional symptoms, with pain in the right thigh and some in the joints. On the 20th, he was seen by Dr. James Jackson, and of his detailed report of the case the present history is an abstract. There were then the indications of periostitis about the femur; swelling with some hardness, heat, and extreme tenderness. On the 31st, Dr. J. found him greatly reduced; thigh about the same, and a similar affection of the right arm, with some extension to the forearm. On the 5th of Sept., the arm was better and the thigh less swollen, but with signs of deep-seated suppuration below the trochanter. On the 8th, suppuration about left shoulder-joint, with a projection as from dislocation forward of the bone; swelling of thigh greatly diminished, as from an absorption of the pus; pain urgent; greatly reduced; punctured left shoulder, and discharged two ounces of healthy pus; the

swelling of right elbow having returned, this also was punctured and discharged the same amount of pus. Death on the 19th.

On dissection, the shaft of the left humerus was found separated and thrown forward. No disease in the joint, though there was a cavity between the head and the shaft that contained thick pus. The condyles were also separated, and between them also and the shaft was a cavity containing pus. Periosteum separated from some parts of the humerus. Forearm dislocated toward the inside, and the olecranon somewhat denuded. Upon the right side, pus was found between the acromion and the humerus; also about an inch below the joint, and there the periosteum was removed. The elbow was very much as it was upon the other side. The trochanter major was separated from the shaft, and between the two was a cavity that contained pus, and that extended to where the fluctuation was felt on the 5th of Sept. Hip-joint healthy, excepting some discoloration. Periosteum extensively separated from the shaft. Upon the left side the great trochanter was also separated, though less perfectly than upon the right, and there was a smaller quantity of pus between it and the shaft. The lungs contained numerous small purulent deposits, with some acute pleurisy upon the left side.

The two bones above referred to have been dried and show the trochanter separated, but the head of the femur still attached; neck carious and surface generally rough as from inflammation. The surface of the humerus is less diseased. 1847.

Dr. J. C. Warren.

1199. Extensive bony deposits about the greater part of the humerus, with destruction by caries of the head of the bone; structure light.

From a lad *æt.* seventeen, who entered the hospital Dec. 2d, 1867 (134, 107). Disease of eight months' duration, and previously healthy. Large abscesses had formed, with much swelling and much pain; bone felt through fistula. General health much reduced. On the 14th his condition had improved, and the limb was removed at the shoulder-joint; the remains of the head of the bone being removed

separately. On the 18th he began to have chills, and on the 26th he died with symptoms of pyemia; there having been, toward the last, great pain in the region of the liver (Series xxxii.), and a general abdominal tenderness. (See No. 2371.)

The bone, which is a very handsome specimen, was prepared by Mr. H. H. A. Beach, one of the house-pupils. 1868. *Dr. H. J. Bigelow.*

1200. Upper portion of the right femur, showing the effect of acute inflammation. From a middle-aged man (Hospital, 218, 89). Disease of thirteen weeks' duration. Began with "fever," and two weeks afterward severe pain in knees and feet, extending to right hip; the thigh becoming very much swollen and the pain intensely severe.

On dissection, a bloody fluid was found in the hip-joint, and the cartilage mostly gone, though in some parts it was quite healthy, and lay like a loose flap upon the subjacent bone. Head of femur to some extent destroyed. Both knee-joints were similarly affected; the bone being of a deep-red color just below the surface, the deeper parts infiltrated with a yellowish serum. A large collection of pus was also found between the muscles and periosteum above each knee. The upper third of the head of the femur seems to have been destroyed by caries, with some extension of disease to the neck. Cancelli exposed, and without a trace of new deposit. 1859. *Dr. C. Ellis.*

Inflammation of femur, the result of fracture; see Nos. 1066-70.

1201. Femur of an infant nine months old, and showing the effects of inflammation. At the age of two months it fell from the arms of its attendant. At the end of a week the thigh was swollen midway, and in a month from the time of the accident an abscess was opened and discharged freely. Three or four openings were afterward made, and one remained till death. Emaciation moderate. Death at last sudden.

On section, the original outline of the bone is seen, and the cavity is more or less filled with cancellated structure. A large deposit of new bone has formed externally; generally

smooth upon the surface, involving a large part of its circumference, and having within it a large cavity upon the surface of the bone, and in which was at first a very small sequestrum. The whole is exceedingly light and atrophied. 1868. *Dr. W. C. Blaisdell.*

1202. Both humeri, with one bone from each forearm; enlarged, and rough upon the surface, as from chronic ostitis. One of the bones having been sawed, the cavity is seen to be nearly obliterated, but without any appearance of periosteal deposit. From a female, dissecting-room subject, and prepared by Dr. H. 1856. *Dr. R. M. Hodges.*

1203. Humerus and fibula, from a young adult. The greater part of the two bones is enlarged, but generally sufficiently smooth. Humerus compact in structure; central cavity of full size, and without any appearance of caries, though it opens by a cloaca upon the surface of the bone; and upon the corresponding surface of the integument there were some appearances of old disease. 1858.

Dr. R. M. Hodges.

1204. The remains of extensive chronic inflammation of the tibia, with ankylosis of the knee and ankle-joints; the knee being bent to a right angle.

From a young man, æt. nineteen years, who entered the hospital in May, '63 (104, 251). Four years previously he had erysipelas of the right leg, followed by a sore, and stiffness of the knee; at the same time there was severe pain in the left hip-joint and thigh; and when he left his bed the hip was found to be dislocated; this last being marked on admission, with remains of old ulcers along the right tibia. The limb was amputated; and, after some sloughing of the stump, the patient was discharged well in two months. 1864.

Dr. J. M. Warren.

1205. Bones of the leg, with a portion of the femur, showing bony ankylosis between the femur and tibia, femur and patella, tibia and head of fibula; with a hole in the place of the centre of the joint, as usual. The lower fourth of the tibia is healthy; but the rest of the bone is enlarged,

irregular upon the surface, porous, and with a cavity of considerable size upon the inside of the head.

From a man, æt. thirty-eight years. (Hospital, 111, 144.) At the age of fifteen years an abscess formed about the knee, and during the following year several pieces of bone were discharged. After this he was well for eleven years; and the pain then returned. Fourteen months before entrance it increased, and fistulæ formed; the discharge from that time being continuous. Amputated, and did well. Bones prepared by Mr. O. F. Wadsworth, one of the house-pupils. 1863.

Dr. H. J. Bigelow.

1206. A portion of the calvaria, much thickened, and in some parts measuring nearly half an inch; tables quite thin.

From an idiotic boy, fourteen years of age, and always epileptic. The rest of the calvaria was more or less thickened; and some of the sutures were very nearly obliterated. Universal, old, and firm adhesions of the membranes of the brain were found. (See No. 37.) 1856.

Dr. R. M. Hodges.

1207. A second specimen; max. about one-third of an inch. Bone otherwise quite healthy. 1856.

Dr. H. J. Bigelow.

1208. A third specimen. The frontal bone is nearly three-fourths of an inch thick, where sawed through; and the structure is solid. Inner surface irregular, and upon this side the new growth seems to have taken place; the outer being smooth and healthy. From a case of acute abscess of the lung (Series xxviii.). There had been no symptoms referable to the head; and nothing else was found than the above. 1856.

Dr. C. Ellis.

The three following specimens are casts, and transferred from the Phrenological Collection. (Series xliii.) 1847.

Dr. J. C. Warren.

1209. "Top and base of a remarkably thick skull of a woman, who, at the age of fifty, enjoyed the use of all her faculties. From this period her skull thickened gradually by disease, and her faculties became impaired in the same ratio, until she died at the age of sixty. The average thick-

ness of her skull is about 1 in." ; and the extremes, $\frac{3}{8}$ in.— $1\frac{1}{2}$ in.

The original was in the collection of the late Dr. Spurzheim ; and the casts are well known in the museums.

1210. Section, from a very thick skull ; max. $1\frac{3}{8}$ in.
1211. Skull, showing apparently a very great thickening of the bones of the cranium, and of the face.
1212. A portion of the calvaria, from $\frac{1}{4}$ to $\frac{3}{4}$ in. thick, and resembling in structure the original of No. 1209. No appearance of tables or cut surface, and structure rather light. Vascular grooves on inner surface strongly marked. From the collection of the late Dr. Sewall, of Washington. 1857. *Mr. Webster Lindsley, med. student.*
1213. A calvaria, thick, heavy, and porous from increased vascularity. From a girl, twenty-five years of age, who had formerly had syphilis. About eight months before death, there came on, after an especial exposure, obscure cerebral symptoms, with appearances of hysteria ; and from these she suffered most of the time until her death. See Amer. Jour. of Med. Sc. April, 1852, p. 362. 1859. *Dr. D. H. Storer.*
1214. Two femora ; moderately enlarged, and not very rough on the surface, but very heavy as in sclerosis ; mates. 1847. *Dr. J. C. Warren.*
1215. Femur, very similar to the last. 1847. *Dr. J. C. Warren.*
1216. Lower half of shaft of femur, considerably enlarged, except along outer surface ; rough where most diseased ; structure rather light. 1847. *Dr. J. C. Warren.*
1217. Portion of a femur, showing a pretty defined enlargement. Externally it seems to be a periosteal deposit, and such was very probably its origin ; though, on section, it appears to be a compact, solid enlargement of the bone itself. The disease was evidently of long standing. 1847. *Dr. J. C. Warren.*
1218. Lower portion of a very large and otherwise healthy femur, enlarged posteriorly, and rough ; structure solid. 1847. *Dr. J. C. Warren.*

1219. Tibia, moderately enlarged, cylindrical, and rough externally; very dense and heavy. Long. and transverse sections show no periosteal deposit; and the cavity to a considerable extent is quite obliterated. 1847.

Dr. J. C. Warren.

1220. Shaft of the tibia, enlarged to a considerable extent; and the linear appearance upon the surface, so often seen in chronic osteitis, is strongly marked. On a transverse section there is no appearance of periosteal disease; cavity very small. 1856.

Dr. R. M. Hodges.

1221. Tibia enlarged, dense, and heavy; surface somewhat rough. Articular surfaces healthy. On section, no periosteal change; and of the cavity there is hardly a trace. 1847.

Dr. J. C. Warren.

1222. A fibula, enlarged, and covered with spines and ridges. No appearance of periosteal deposit on transverse section. 1847.

Dr. J. C. Warren.

1223. Upper third of the tibia, irregularly enlarged, and particularly toward the back part. No periosteal deposit. Cavity nearly or quite obliterated. 1847.

Dr. J. C. Warren.

1224. Bones from a subject supposed to have died of syphilis; five cervical vertebræ, the clavicles, humerus and ulna, and the long bones of the lower extremities, with a patella. Generally more or less enlarged, misshapen, and rough upon the surface, with a marked growth of new bone from the edges of the bodies of two of the vertebræ. One of the tibiæ having been sawn across, the enlargement is seen to be of the bone; a small portion of which only is compact toward the surface. No appearance of periosteal deposit. Cavity occupied by coarse, cancellated structure. 1848.

Museum Fund.

1225. Lower third of femur enlarged, etc., by chronic inflammation; not very heavy, but surface rough; cavity obliterated, and no appearance of periosteal deposit. Upon the cut surface is a small cavity that contains a loose sequestrum, and that was cut across in the amputation. The synovial surface is rough from caries, as was also that of the tibia and fibula.

From a woman, thirty years of age. (Hospital, 77, 104.) Disease of nine years' duration. Pain, with discharge of pus, but never of bone. Three years before entrance she sprained her knee; followed by great pain, and swelling. Health much reduced. Amputation; and sequestrum removed from cut surface; soft parts infiltrated with lymph; much bleeding and prostration. Several ounces of pus in knee-joint. Discharged, well, about three and one-half months after the operation. 1858.

Dr. H. J. Bigelow.

1226. Femur, of which the upper half is enlarged, etc., as from chronic inflammation. Head and neck remarkably unaffected. 1847.

Dr. J. C. Warren.

1227. Upper two-thirds of femur, flattened, misshapen, and rough upon the posterior surface. 1847.

Dr. J. C. Warren.

1228. Long. section of the femur, showing the effects of chronic inflammation; enlargement, roughness upon the surface, and obliteration of the cavity, so far as the disease extends. 1857.

Dr. R. M. Hodges.

1229. A tibia, over which there may have been an old ulcer. Upon the inner surface, and toward the lower part, is an abrupt and very defined elevation of the surface, that becomes broader above, and is gradually lost in a disease that involves more or less the whole circumference of the bone. The surface of this last is quite rough, with well-marked caries at the upper back part. The extremities of the bone are quite healthy. 1847.

Dr. J. C. Warren.

1230. Tibia, sawed lengthwise, and showing the changes that have taken place in the bone, in connection with an old ulcer upon the inside, and just below the middle of the leg. The ulcer was 3 in. or more in length, quite raised above the surrounding surface, and the bones were almost exposed. From a dissecting-room subject.

The whole bone is enlarged to the extent of 5 or 6 in.; and upon the inner surface, corresponding to the ulcer, it is much raised, and has the coralloid appearance so often seen in diseased bones. Upon the cut surface the affected

part is quite compact, but still shows some traces of its formation externally to the original bone. The fibula is more or less enlarged throughout, and irregular upon the surface, as the bones so often are in cases of old ulcer of the leg. 1853. *Dr. R. M. Hodges.*

1231. Tibia, very much enlarged and misshapen, from chronic inflammation, with an appearance as if there may have been an old ulcer of the soft parts upon the inside of the leg, and toward the upper part; the bone being carious to the extent of 2 or 3 in., though not deeply so. On transverse section, the wall of the bone all around is compact; and there are no remains of the cavity. 1858.

1232. Tibia of a little boy, æt. seven years, who entered the hospital Nov. 29th, 1865 (122, 116). Run over by a horse-car a year before, and was said to have had a compound fracture of the leg. On admission he limped about on crutches, with a large, uncovered surface upon the front of the leg, and distortion of the foot. Amputated Feb. 21st, and discharged well March 20th.

The lower portion of the bone, to the extent of 4 in. or more, is diseased, except the posterior walls, which are healthy. There is a very marked enlargement, roughness, and irregularity of the surface; and, having been sawed longitudinally, the parietes are seen to be cancellated. There appears to be an expansion of the bone, a periosteal deposit, and a blending of the two; with some longitudinal curvature, as if the anterior portion had been hypertrophied by inflammation. No appearance of fracture. 1867.

Dr. R. M. Hodges.

1233. A portion of the shaft of the humerus, 9 in. in length, and resembling a piece of old, decayed wood. Surface covered with a new growth of bone, soft and nodulated. Extensive caries, with some necrosis. 1847.

Dr. J. C. Warren.

1234. Femur and tibia, greatly diseased; the result of scrofulous inflammation. From a lad fourteen years of age, who was in the hospital (81, 171), under the care of Dr. B. Swelling, pain, ulcers, and sinuses for eighteen months.

The whole limb was found much swollen; and, to the feel, the bones were much enlarged. The boy, previously, had become much reduced and died a month after admission.

On dissection, the organs were found pale, and the liver large, light-yellow, and very fat. Tissues about the bones condensed, with numerous abscesses. The bones, having been prepared by Dr. Ellis, the whole femur, excepting the articular portions, is seen to be much enlarged and misshapen; surface rough and irregular, with large foramina for the nutrient vessels; several cloacæ, at the bottom of which small portions of dead bone are generally seen, but of which one only is loose; structure generally rather light. It appears as if a large periosteal deposit may have taken place; and just above the condyles, anteriorly, this is detached from the surface beneath. The tibia is much less diseased than the femur; healthy toward upper extremity, and lower half most diseased. Posteriorly there seems to be caries to the extent of several inches, but nowhere to any great width. The fibula, which is not preserved, was slightly enlarged toward the lower extremity. 1859.

Dr. H. J. Bigelow.

1235. Right femur, very greatly diseased. Lower half much enlarged; and nearly the whole surface is rough from the irregularly flattened or pointed growths of new bone that have formed. In some parts the periosteal deposit is in the form of a very delicate cancellated structure, covered by a thin pellicle of smooth bone. No appearance of necrosis. Structure, as judged by the weight, extremely light. At about the junction of the upper and middle thirds the line of the bone is irregular, as if there may have formerly been a fracture. 1869. *Dr. Charles B. Porter.*

1236. A portion of femur, eleven inches in length; much enlarged throughout, and uniformly of a light and reticular structure. No appearance of periosteal deposit, and hardly any remains of the cavity. 1847. *Dr. J. C. Warren.*

1237. Tibia very greatly enlarged, flattened laterally, and misshapen. Surface generally smooth. A transverse section shows no periosteal deposit. Walls generally sufficiently

distinct, but in some parts cancellated quite to the surface. No trace of a cavity. Epiphyses not co-ossified. 1847.

Dr. J. C. Warren.

1238. Chronic inflammation of the tibia. From a man *æt.* twenty-seven, who injured his leg nineteen years before entrance into the hospital (126, 274). Inflammation followed, and for the first six years there was an occasional discharge of bone. Had done no work for the last six months. On admission, the knee was bent to a right angle; bone enlarged and bowed inward; skin tense, discolored and cicatrized; discharge profuse, and through the openings dead bone was felt. Dr. H. amputated above the knee, and in seven weeks the man was discharged, but with some inflammation of the stump, and dead bone; his general health having never been good.

The bone is enlarged throughout. Upper half mostly diseased, and especially toward the back; being very rough from caries, and with small pieces of dead but not loose bone. 1867.

Dr. R. M. Hodges.

1239. Old disease of the tibia, from a man *æt.* fifty-eight, who entered the hospital Feb. 14th, 1868 (134, 184). When about twelve years old he injured his leg, and there was swelling from that time. Twelve years before entrance he had compound fracture of both bones of the leg, and at the seat of injury, which was about the junction of the middle and lower thirds. In four years the limb was sound, but three years afterwards a small sore formed, and kept open from that time. Five weeks before admission the leg became much swollen, painful, red, and *œdematous*; and three days afterward the sore increased and the discharge became abundant; the leg, on admission, being twice the size of the other, and with a foul ulcer upon it, of which the diseased tibia formed the base.

On the 15th, Dr. B. removed the diseased bone, some of which was excessively hard; and on the 12th of March the man left the hospital.

Sept. 22d, he was readmitted with a deep and defined excavation at the seat of disease, 3 in. in length and 1 in. in width. The wound had never quite healed, and the sur-

rounding surface was dark and glazed. Amputation was performed on the same day below the knee, and though he did not do well after the operation, he was again discharged Dec. 31st.

The cavity in the bone is $3\frac{3}{4}$ in. long, 1 in. wide, and nearly $\frac{3}{4}$ in. deep; the inner surface rough, and showing openings into the cavity in the interior of the bone. The whole bone is enlarged, deformed, and somewhat irregular at the seat of the former fracture. 1869. *Dr. H. J. Bigelow.*

1240. Tibia, very greatly diseased, and throughout; the result of chronic inflammation. From a man thirty years of age, (Hospital, 83, 175.) Nineteen years before entrance he had sinuses over the tibia, with discharge of bone. Recovered in two years, but subject to inflammation from that time, though he never again had any openings until a year before, when they appeared in various parts of the leg, with discharge of bone. When seen, the bone was very much enlarged, and the openings very numerous. Dr. C. commenced an operation for necrosis, but finally amputated at the knee-joint. Condyles of the femur diseased, and were removed with the patella. Discharged well in six weeks and a half; but soon returned with ulceration of the stump, and four months after the operation died with typhoid fever.

The bone is very much enlarged and misshapen; very rough and porous upon the surface, and partly from caries; some dead bone in two or three places, with cloacæ; structure light; articular surfaces diseased. On transverse section, the bone consists throughout of a coarse, cancellated structure; being nowhere compact. No appearance of periosteal deposit nor of a central cavity. 1859.

Dr. H. G. Clark.

1241. A tibia, broken off just above the middle of the bone, shows a light, earthy structure, but no periosteal deposit; external surface not compact, and not very rough; cavity nearly obliterated. Much enlarged, but gradually reduced to its natural size toward the lower extremity. 1847.

Dr. J. C. Warren.

1242. Tibia, much enlarged; and, on section, consists throughout of a very light, cancellated structure, without any trace of wall or cavity. Surface generally not very rough, but more so toward the upper back part. 1847.

Dr. J. C. Warren.

1243. Os calcis; free surface, rough and porous, and upper articular surface superficially carious; structure light. 1847.

Dr. J. C. Warren.

1244. Last 5 in. of the tibia, enlarged, and rough upon the surface, from periosteal deposit, with some caries. From a woman, æt. forty-five (Hospital, 123, 76). Disease of two and a half years' duration. Amputated, and did well. In the recent state the cartilage was destroyed, and the fibula diseased. Prepared by Mr. C. Pratt, one of the house-pupils. 1866.

Dr. H. J. Bigelow.

1245. A humerus, of which the lower two-thirds are enlarged, and apparently by a periosteal deposit. The surface is very rough and reticulated, with some appearance of caries; On section, a small portion of the circumference of the wall is quite dense and healthy; the rest, consisting of a coarsely reticulated structure, but with scarcely a trace of the periosteal deposit, that seemed to be so marked externally. The cavity of the bone is of full size. 1847.

Dr. J. C. Warren.

1246. Ulna, enlarged; rough and porous on the surface. On a transverse section the enlargement is seen to be altogether due to an old periosteal deposit; the bone being scarcely affected; structure quite light. 1847.

Dr. J. C. Warren.

1247. Lower portion of the femur, much enlarged by an old, thick, periosteal deposit, and which has the pinkish tinge that is sometimes seen. The bone itself is not enlarged, but the walls are beginning to be cancellated and fused with the external deposit; as seen on a transverse section. 1847.

Dr. J. C. Warren.

1248. A small portion of the shaft of the femur, showing an old periosteal deposit along one side, and which, to a con-

siderable depth below the surface is as solid as the bone itself. The two at last become fused, as a thick, solid mass, so that upon a partial examination a periosteal deposit might not have been thought of. Upon the other side of the bone are some appearances of a similar deposit, and in which there is a complete fusion.

As usual, even in the oldest of such deposits, the cavity of the bone remains; whereas in osteitis it is often obliterated. 1847. *Dr. J. C. Warren.*

1249. Longitudinal section of lower third of femur; enlarged from old periosteal disease, and upon the surface rough and irregular; structure light and reticular. 1847.

Dr. J. C. Warren.

1250. The shaft of the femur, enlarged by an old periosteal deposit. On section, the original walls of the bone are more or less cancellated, and to a considerable extent they are no longer traceable. Cavity obliterated. 1847.

Dr. J. C. Warren.

1251. Two femora; mates. Old periosteal deposit along shafts, and surface quite porous. 1847. *Dr. J. C. Warren.*

1252. Femur, very similar to the last. 1847.

Dr. J. C. Warren.

1253. Femur, of which the shaft is enlarged by a periosteal deposit. 1847.

Dr. J. C. Warren.

1254. A tibia, wanting the two extremities, but more or less diseased so far as shown; a periosteal deposit, generally thin, and, in its pinkish color, bearing a striking resemblance to some of the urinary calculi that consist of the urate of soda. The deposit is rather earthy and crumbling, and so intimately fused with the bone, as seen on section, that its existence might almost have been questioned; a second section, however, defines the outline of the two very perfectly. The cavity of the bone is becoming cancellated. External surface not porous nor foliated, as it so often is in periosteal deposit. 1847. *Dr. J. C. Warren.*

1255. Tibia, enlarged anteriorly, and midway, as in case of a node. Section shows a periosteal deposit, of which the

outline is distinct for more than one-half the extent, though elsewhere, and anteriorly, it is scarcely traceable; compact upon the external surface, but crumbling beneath, and of a pinkish color, as in the last specimen. Wall of the bone healthy toward the back part, but less compact in front, where it is blended with the thick periosteal deposit. Cavity not affected. 1847. *Dr. J. C. Warren.*

1256. Tibia, enlarged throughout, by an old periosteal deposit, as seen upon the surface, and transverse section. It varies much in thickness, and in some parts is brittle, and disposed to flake off, leaving the surface of the bone beneath rough. Walls otherwise not affected; and the cavity is of full size. 1847. *Dr. J. C. Warren.*

1257. A rather defined, and very thick periosteal deposit, upon the front of the tibia, mainly just below the middle of the shaft, and to the extent of about 4 in. Externally it has the usual appearance, except in front, where it is exceedingly rough. On longitudinal section, it seems to consist, at the thickest part, of coarse and rather indefinite fibres, that stand perpendicularly to the bone; and beneath these the bone itself seems to have become thickened, cancellated, and intimately united with the new deposit. Elsewhere the deposit has the usual appearance. The walls of the bone are otherwise healthy, and the cavity is of full size. Probably connected with an old ulcer of the leg. 1847. *Dr. J. C. Warren.*

1258. Tibia, diseased throughout, excepting the articular surfaces. Enlarged, dense, and heavy. Externally porous or foliated, and showing very plainly the periosteal character of the disease. On transverse section, this character is unequivocal; but, though the original bone is to some extent sufficiently distinct in outline and structure, it forms generally with the new deposit an almost homogeneous, solid mass, excepting one portion, which is becoming cancellated. The cavity of the bone, in this case, is small. 1847. *Dr. J. C. Warren.*

1259. Tibia and fibula, showing an abundant, but nowhere thick

periosteal deposit. On section, the walls are thin and cancellated, the cavity large, and the whole is very light. 1847. *Dr. J. C. Warren.*

1260. Metacarpal bone of an animal (Bos), from New Orleans; long. section. Very greatly enlarged by periosteal deposit, of which the max. thickness, at the lower extremity, is $1\frac{1}{2}$ in.; outer portion to some extent compact, but structure otherwise very coarsely cancellated. Surface generally rough and reticulated, with deep grooves for the tendons, but comparatively regular in front. Anchylosed to the first phalanx of each toe; and behind these is a very large and most irregular growth of new bone; very little more than the articular surfaces of the phalanges being seen. Structure very solid; that is, nowhere light and crumbling. 1866. *Dr. H. R. Storer.*

1261. Caries of the temporal bone, from a case of phthisis; and explaining the chronic otorrhœa that is occasionally observed in this disease. From a hospital patient, twenty-nine years of age (206, 71); and who had had a discharge from the ear from childhood. The bone was felt denuded through the meatus; the tympanum was destroyed, and there opened into it an abscess of the size of a pea. There was serum in the cells of the bone, but no distinct tubercular deposit. Sections have been made, and the bone dried. 1859. *Dr. J. B. S. Jackson.*

1262. An upper molar tooth, with a portion of carious alveolus between the fangs. From a middle-aged man, who looked healthy, but complained of weakness. For about a fortnight his teeth had been loose, and of several that he had picked out, all had more or less of the alveolus attached to them. The gums were spongy, tender, but not painful, and bled on the slightest pressure. No cause known for disease. Under the use of the chlorate of potash, he was very soon relieved. 1863. *Dr. G. W. Pease.*

1263. Enlargement of the lower portion of the radius, with extensive caries just above the articular surface. Structure rather light and porous. 1847. *Dr. J. C. Warren.*

1264. Os innominatum, showing a carious cavity upon the inner surface, about as large as the top of the thumb, and nearly extending through into the acetabulum; the surrounding bone being perfectly smooth and healthy. 1847.

Dr. J. C. Warren.

1265. A portion of the femur, with the acetabulum; showing deep and very defined caries of the neck of the bone, and extending to the shaft. From a child, two years old. Pain, tenderness, and fever for four months, with dislocation. Death from "dropsy of the brain." Pus was found in the cavity of the hip-joint, but without any external opening. 1847.

Dr. J. C. Warren.

1266. Thibert's model. Caries of the great trochanter, with extensive abscess about the bone. 1847.

Dr. Geo. Hayward.

1267. Lower two-thirds of femur, showing a large and defined carious cavity just above the condyles, posteriorly. The surface of the bone about the cavity shows the effects of inflammation. 1847.

Dr. J. C. Warren.

1268. Upper half of femur; surface of shaft deeply carious, and in some parts grooved almost as by an instrument. Bone not enlarged; and without any new deposit on surface. 1847.

Dr. J. C. Warren.

1269. Lower portion of the femur, showing caries of the condyles, and a deep cavity between the two. In this last is a large piece of loose dead bone, that would most effectually have prevented a natural cure of the disease. Bone somewhat enlarged and inflamed just above the condyles. 1847.

Dr. J. C. Warren.

1270. Caries of the knee-joint general, and in one or two places quite deep. Lower part of the femur somewhat enlarged.

From a laborer, *æt.* thirty-four years. Disease of two years' duration, and for three months he had done no work, though he was able to walk with the help of two canes. General health sufficiently good, but failed after his entrance into the hospital (33, 1). Abscesses formed, and at the end of about two months the limb was amputated, but he continued to sink, and died on the sixth day.

On dissection, the sinuses were found to open freely into the cavity of the joint, and there was pus amongst the muscles of the thigh; but no other disease, excepting a granulated liver. 1847. *Dr. G. Hayward.*

1271. Knee-joint, with the surrounding soft parts; in spirit; and showing a cavity nearly 5 in. in length, between the head of the tibia and the fibula, the inner surface of which is partly smooth, and partly rough, as from coagulated blood. Tibia extensively carious. 1847.

Dr. J. C. Warren.

1272. Head of the tibia, showing several deep and defined carious cavities beneath the articular surface; the intervening portions of this last being nearly smooth. 1847.

Dr. J. C. Warren.

1273. Caries of the tibia, and very much as in the last case, except that it is less deep and extensive. Some periosteal deposit. 1847.

Dr. J. C. Warren.

1274. Superficial caries of the shaft of the tibia, to the extent of $3\frac{3}{4}$ in. Some appearances of exfoliation, and the bone is very much in the condition in which it would have been if there had been an extensive and thin exfoliation, such as is seen to be going on in No. 1295. 1847.

Dr. J. C. Warren.

1275. A portion of the leg, preserved entire in spirit, and showing an ulcer $6\frac{1}{2}$ in. in length, covered with large granulations, and extending to such a depth that the tibia must be in part mostly, if not entirely, destroyed. The fibula seems to be ankylosed to the tibia below the disease. 1847.

Dr. J. C. Warren.

1276. Lower half of the fibula, much and very irregularly enlarged, with two large and deep cavities. Structure rather solid than otherwise. 1847.

Dr. J. C. Warren.

1277. Caries of the body of the astragalus, with necrosis. Upper and lower articular surfaces also carious, but not the anterior. Os calcis preserved, and is considerably diseased. Structure very light.

From a man, æt. forty-seven (Hospital, 78, 141). Dis-

ease of two years' duration; and came on in the course of a severe and general "rheumatism." Ankle very painful; gradually swelled, and in about six months sinuses formed, and remained open, though no bone came away. Amputated, and did well. 1859. *Dr. S. D. Townsend.*

1278. Extensive caries of the tarsal bones, and particularly of the astragalus and os calcis. There is a large cavity in this last, and the smoothness of the inner surface shows the attempt at separation. The caries of the articular surfaces is not in proportion to that of the substance of the bones. No new deposit. The whole have been very handsomely wired and mounted, by Mr. Burt G. Wilder, student of med., with the adjoining portion of the bones of the leg, and of the metatarsal bones.

From a man, æt. forty-five, who had had disease about the heel, from the age of twelve or fourteen years; many attacks of inflammation over the outer surface of os calcis, with discharge of bone; and always with more or less hard swelling. When the limb was amputated in October, there was a large and recent abscess in the sole of the foot, a large, old cicatrix about the heel, and sinuses about both ankles, with a brawny condition of the integuments. Subsequently he had inflammation of the stump, with failure of the health, and in the spring a discharge of bone; but, when last heard from in July, he was doing sufficiently well. 1862. *Dr. R. M. Hodges.*

1279. A small perforation through the very upper portion of the occiput, and that communicated with a chronic abscess in the substance of the brain. (No. 1874.) 1847. *Dr. J. C. Warren.*

1280-1. A portion of the femur, showing the effects of osteomyelitis after amputation. (See No. 1441.) The bone having been sawed, one-half is in spirit, and the other dried. 1866. *Dr. Geo. H. Gay.*

1282. Upper two-thirds of the femur, sawed longitudinally. Cavity in the substance of the bone, just below the neck, 2 in. in length, of an oval form, perfectly defined, and roughened upon the inner surface, but with no appearance of

acute caries. Upon the front of the bone is a small, defined outlet from it; and toward the back a smaller one. The structure of the bone around the cavity is compact to a considerable extent; and the central cavity commences lower than usual. Externally, and corresponding to the cavity, the bone is rough from a new deposit; head flattened, and the neck shortened and much more in a line with the shaft than usual. The bone was dry when sawed, and the cavity empty. 1860. *Dr. R. M. Hodges.*

1283. Lower third of the femur, enlarged, and rough upon the surface. Where it has been cut across, the cavity is obliterated, but upon the surface is seen the defined, round opening of a fistulous canal, that extends downward through the substance of the bone, and opens upon the posterior surface just above the condyles. It may have originated in such a cavity as is shown in the last specimen. 1847. *Dr. J. C. Warren.*

1284. Chronic inflammation of the tibia.

From a man, æt. twenty-four years (Hospital, 106, 64). Thirteen years before entrance he struck his ankle, and within a few days had pain, swelling and abscess. Several months afterward pieces of bone began to come away from about the ankle, and along the spine of the tibia, and so on for two or three years, but not since. The ulcers, however, remained open, and the leg had been worse. When seen, his general health was impaired; leg and ankle much enlarged, and the surface diseased. Amputation 3 in. below the knee; followed after a time by chills, hemorrhage, and an appearance of sloughing; and at the end of three weeks by death.

The tibia is uneven, and deformed as from chronic unhealthy inflammation. Anchylosed to astragalus, and lower end of fibula. On long. section, a cavity is seen in the very lower extremity of the tibia, rough upon the inner surface, and capable of holding $\frac{3}{4}$ i or ij; and a smaller one is seen in the astragalus. Upon the outer surface of the fibula, and near its lower extremity, is a very marked growth of new bone, about 1 by $1\frac{1}{2}$ in. in extent, $\frac{1}{8}$ in. in thick-

ness, and with a smooth and defined neck; the surface is rough, and overlaps the base. 1864.

Dr. J. M. Warren.

1285. Lower portion of the tibia, enlarged and somewhat irregular; and, having been sawed lengthwise, there is seen in the interior, and just above the articular surface, a pretty well defined cavity, more than an inch in diameter, and filled, in the recent state, with a white, opaque, curdy matter. Cavity of the bone obliterated to some extent. The astragalus is closely anchylosed with both bones of the leg; and the fibula is somewhat enlarged. From the dissecting-room. The limb looked as if it may have been the seat, formerly, of a chronic ulcer. 1857.

Dr. R. M. Hodges.

1286. A portion of the lower jaw, showing the effects of chronic otitis; including in extent the right canine, and the first molar tooth upon the left side, and probably removed during life. The disease is situated almost entirely upon the outer surface of the bone, and consists of an enlargement of its substance, and a change of structure; forming a tumor equal to $1\frac{1}{4}$ in. in diameter. Upon the inner, and along the under surface, the bone generally looks compact and healthy, though there is some enlargement toward the mouth. On transverse section, the compact wall has for the most part disappeared, and the mass is seen to consist of a pretty hard bone, mixed with the dried remains of a dense, fleshy substance; this last being intimately connected with the surrounding soft parts. Rather in front of the left canine, and which, with the adjoining incisor, has been removed, is a cavity of some size in the substance of the bone; the opening from this having a fistulous appearance before the specimen was dried. 1847.

Dr. J. C. Warren.

1287. Lower portion of the femur, with the surrounding soft parts; in spirit. The bone is enlarged, and to some extent consists of little more than a mere shell; being occupied by a cavity that, about in the situation of the condyles, communicates freely with another in the soft parts, and which last extends about 7 in. along the front of the bone.

The bone appears healthy where sawed across. Knee-joint probably bent to an acute angle during life, as the articular surfaces, to some extent, look directly backward. These last are generally sufficiently healthy, though partly connected by cellular adhesions. 1847.

Dr. J. C. Warren.

1288. Chronic inflammation of the femur. From a man, forty-two years of age. Disease of fifteen or sixteen years' duration. Lower portion of thigh enlarged, with an offensive, sanious discharge. General appearance of necrosis, though no bone had been discharged.

The enlargement begins just above the middle of the bone, and extends to the condyles; the surface being quite rough posteriorly. About 3 in. above the condyles, anteriorly, is a defined opening, about three lines in diameter, and leading upward into a cavity within the bone; the structure of the bone being generally healthy. 1855.

Dr. W. N. Lane, of Charlestown.

1289. Extensive necrosis of the femur. From a man twenty-seven years of age. (Hospital, 110, 130, and Med. Jour. vol. LXXII. 129.) At the age of fifteen he jumped from a wall, and the shock was followed by severe inflammation, abscesses and discharge of bone during the first year. During the same year the femur broke in its lower third but united again with a shortening of 3 or 4 inches. Confined by attacks of inflammation during one-half of the time since disease began; and for some years the knee-joint had been involved. Amputated Feb. 27th; convalescence slow, but in Oct. he was seen by Dr. W. in fine health and spirits.

In the lower back part of the femur is a large and perfectly loose sequestrum, 5 inches in length, with a cloaca leading from the cavity that contains it, and opening upon the front of the femur. The cavity of the bone, where sawed, is obliterated. Appearances of former fracture nearly effaced. Knee-joint disorganized.

Dr. W. remarked, in connection with this case, upon the very few cases of extensive necrosis of the femur that had been relieved by operation, so far as he had seen; and also

upon the very abundant hemorrhage from the smaller vessels where there had been much previous inflammation in the amputated limb. 1865. *Dr. J. M. Warren.*

1290. Necrosis of the femur, with disease of the knee-joint.

From a man æt. thirty-five, who entered the hospital Sept. 9th, 1869 (141, 197). Eighteen years previously he broke the lower third of the femur, and for a year small pieces of bone were occasionally discharged. A stiff knee was the result. Eleven months before entrance he fell through a barrel, struck the knee, and sharp pain followed. Three months afterwards an opening formed upon the inside of the knee, and subsequently behind the joint, with free discharge. On the 15th Dr. G. amputated the limb, and there was much hemorrhage, with great exhaustion for a day or two. On the 27th there was a sudden and copious hemorrhage that made it necessary to open the wound and tie the bleeding vessel. After this the man did well, and on the 25th of October he left the hospital.

The portion of femur removed is rather more than 4 inches in length, much enlarged, closely cancellated throughout upon the amputated surface, and without any appearance of central cavity. Surface irregular, and with spiculæ. In the back part of the bone is a cavity, more than an inch in diameter, that opened largely into the knee-joint, and that is just seen upon the amputated surface; not very rough within, and contains a sequestrum, $2\frac{1}{2}$ in. in length that is smooth upon the outer surface, and involves a large portion of the circumference of the original bone. The knee-joint contained pus, and the cartilage was to a great extent destroyed; the patella resting upon the outer condyle. 1869. *Dr. G. H. Gay.*

1291. Extensive necrosis of the tibia. A sequestrum, $9\frac{1}{4}$ in. in length, rough upon the surface, quite thick and perfectly loose, lies along the front of the bone, and so perfectly exposed that it might be removed at once, if it were not for its connection with a second that lies deep in the substance of the bone, and toward its posterior face. The whole shaft of the bone is enlarged, misshapen, curved, and rough or granulated upon the surface anteriorly. Through

the large cloacæ upon the posterior surface the smaller sequestrum is seen $3\frac{3}{4}$ in. in length; the two being connected by a small neck like a sleeve-button. The extremities of the bone are healthy. 1847.

Dr. J. C. Warren.

1292. Tibia, very greatly diseased. A cavity, that extends throughout its entire length, contains a sequestrum $7\frac{1}{2}$ in. long, and to a large extent smooth upon the surface. The shell of bone that remains is thin for the most part, with very large deficiencies, light in structure, and everywhere irregularly nodulated and granulated upon the external surface. The upper and lower articular surfaces seem to have been healthy.

From a young subject. The specimen belonged to Dr. P.'s father, and its history is unknown. 1869.

Dr. C. B. Porter.

1293. A radius from which a large portion of the shaft would probably have in time been discharged as a sequestrum. Having been cut across at the time of the dissection, it is seen that the bone itself is not enlarged, though to some extent rough upon the surface. It is surrounded, however, by a very thick and recent periosteal deposit. In this last, toward the carpus, is an opening into a cavity from which a portion of the old bone may have been discharged; and toward the upper extremity are three smaller openings through which a sequestrum is seen. The extremities of the bone are healthy. See No. 1408. 1856.

Dr. H. J. Bigelow.

1294. A femur, upon which an operation for necrosis had been performed. From a man thirty years of age (Hospital, 34, 167). Wrenched his knee twenty years before; followed by pain, suppuration, and discharge of bone for the first five years, but none since. Health not affected. Lower part of thigh considerably affected, with four openings about it. The outer part of the thigh was cut down upon, toward the front, and a large portion of bone was removed, but no sequestrum was found. The operation lasted more than an hour, and was followed by violent inflammation and death in forty-eight hours.

The greater part of the shaft is enlarged. Posteriorly quite rough; and toward the lower part is a small sequestrum, $2\frac{1}{4}$ in. long, and situated in a broad, superficial, and rather smooth cavity. The excavation, the result of the operation, is $2\frac{1}{4}$ in. long, $\frac{7}{8}$ in. wide, and generally about an inch deep. The bone is very heavy, and the central cavity filled up, as in cases of chronic inflammation; but a sinus is seen extending from it to the cavity that holds the sequestrum. 1856. *Dr. H. J. Bigelow.*

1295. Very extensive caries of the shaft of the tibia; mostly superficial, but in some parts quite deep. Also a thin, smooth, and superficial plate of bone, 5 in. in length and 1 in. at the widest part, is seen in the process of exfoliation. In two or three other places there are small exfoliations; and toward the lower third nearly the whole thickness of the bone seems to be more or less necrosed to a small extent. (See No. 1274.) 1847. *Dr. J. C. Warren.*
1296. A portion of the shaft of the femur, showing a superficial exfoliation in progress 2 by $1\frac{1}{2}$ in. in extent. Bone very solid. 1847. *Dr. J. C. Warren.*
1297. A superficial sequestrum from the tibia, $7\frac{3}{4}$ in. in length, and involving a large part of the circumference of the bone.
 From a healthy boy, ten years of age. Duration of disease eight months, and no assignable cause. Redness, swelling, and severe pain the first few weeks; then relieved by the formation of an abscess, and not much complaint afterward. On admission into the hospital (139, 55), there were four sinuses; and the bone being loose, was removed. Did well. 1868. *Dr. H. J. Bigelow.*
1298. Necrosis of nearly the whole shaft of the tibia; from a child. The surface of the bone is very extensively denuded, and to some extent its entire thickness is involved. There is some thickened and not very old periosteal deposit external to it; and at the upper extremity some of the old bone that is alive, and from which the dead bone had not yet separated. 1847. *Dr. J. C. Warren.*

1299. Extensive necrosis of cancellated structure of the upper part of the tibia. From a man twenty-four years of age. (Hospital, 89, 208.) For the last fourteen years he had been subject every three or four years to attacks of pain, swelling, abscess, and discharge of bone. Ten days before admission one of these attacks came on, and the pain was intense, with delirium; dead bone felt; discharge free and offensive. A piece of bone $2\frac{1}{2}$ by $\frac{3}{4}$ in. was removed, and he died five days afterward.

The upper half of the tibia becomes, gradually, much enlarged near the head; the surface is destroyed to a considerable depth, and exposes a large portion of the cancellated structure that is nearly separated as dead bone. This last and the surrounding bone is very light and delicate. The outer surface of the tibia is slightly rough and porous, but without any appearance of periosteal deposit. 1861.

Dr. Geo. H. Gay.

1300. Lower portion of the femur, not including the condyles, and showing an extensive and advanced necrosis; the surface and the deeper seated parts of the bone being involved. There is also an abundant, soft, granular, and apparently recent periosteal deposit. 1847. *Dr. J. C. Warren.*

1301. Lower portion of the radius, removed by M. Velpeau, of Paris, and presented to Dr. W., who happened to be present at the operation. The styloid process seems to be dying, with caries about it, and periosteal deposit upon the surface above it. An acute disease. 1847. *Dr. J. C. Warren.*

1302. Removal of the entire ulna, from a young man *æt.* seventeen. He had been in the cavalry service, and his disease was attributed to the hard duty that he performed. During the last week of May, 1866, severe pain came on, followed by swelling; treated as phlegmonous erysipelas, by incisions; pus evacuated with relief, but the sinuses remained.

Dead bone was felt on his admission into the hospital, July 8th (126, 138); and an opening near the elbow having been enlarged, the whole articulating extremity of the ulna was found loose and was removed. A long incision was then made, and the entire shaft of the bone, with the

lower articulating extremity, were drawn out without force ; the new bone being cut with the knife. The shaft is quite compact, and smooth externally ; but the extremities are in several delicate pieces, showing that the greater portion of them had been destroyed by caries. Aug. 26th, the wound had nearly healed, and there was an extensive development of new bone. Neither articulation showed any disposition to inflame, and the motions were already very good. Sept. 17th, the limb was doing as well as possible, and he was discharged. 1866. *Dr. R. M. Hodges.*

1303. The bones of a finger that was amputated for felon. The first phalanx is dead and a large part of it absorbed. The second is inflamed upon the palmar face ; with a cavity, and in it a small sequestrum ; the surrounding bone being enlarged, and of a delicate structure. The third phalanx is sufficiently well. 1866. *Dr. R. M. Hodges.*

1304. Thibert's model. Necrosis of the tibia, from a gunshot wound. 1847. *Dr. Geo. Hayward.*

1305. Necrosis of the os calcis. In the posterior portion of the bone, the whole of which is very much enlarged, rough, and misshapen, there is seen an irregular cavity, and within it a large piece of cancellated bone in the process of separation. 1846. *Dr. J. C. Warren.*

1306. A portion of dead bone from the top of the skull ; about 2 inches in diameter, including the whole thickness of the bone, and compact in structure, but shows that it had been inflamed before it died.

From a healthy woman, thirty years of age. The disease was of two years' standing, and she denied a syphilitic origin. Looked at first like the scab of favus. Bone loose, and removed at once. Pulsations of brain very marked after removal. 1859. *Dr. H. J. Bigelow.*

1307. Eleven portions of bone removed, from the top of the skull, and equal altogether, in extent, to about 4 inches in diameter.

From a respectable married woman, forty-three years of age. In 1861 she applied to Dr. G., with chronic laryn-

gitis, perforation of the palate, inflammation of the scalp, and greatly reduced health; the cranial affection getting worse as the throat was relieved. Case published in full by Dr. G. in the *Med. Jour.* Vol. LXXI. p. 495; but there have been further discharges of bone since then. "Patient positively denied that she ever had syphilis in any form, and neither her husband, to her knowledge; children perfectly healthy." 1865.

Dr. Johnson Gardner, of Providence, R. I.

1308. A sequestrum about $1\frac{1}{2}$ in. in length, that was retained for several months after it was detached, and then coughed up.

From a young man twenty years of age, who had had ulceration about the palate, with exposure of the bones, eighteen months before the report of the case by Dr. B. The bone being at last suddenly detached, was supposed, by the attending physician, to have slipped into the larynx. This was followed by cough, which lasted until about six weeks before the report was made, when the bone was thrown off, enveloped in pus, and of a very offensive odor. Meanwhile the patient had not thought of the bone being in the air-passages, though he had a harassing and peculiarly loud and loose cough, with mucous râles over one lung, and at one time a severe attack of pneumonia upon the other side. After the discharge of the bone, the cough wholly left him; and six weeks afterward, when the report was made, he was in perfect health.

It was questioned whether the bone had lodged in the fauces, or had passed down the larynx. 1860.

Dr. H. J. Bowditch.

1309. Thin exfoliations of bone from the forehead, following a rhinoplastic operation.

The patient, a girl, æt. twenty-two, had lost her nose from a scrofulous form of lupus. Dec. 15th, 1866, Dr. B. brought a piece of skin down from the forehead, and with it the periosteum, with the hope that this last might form a substitute for the nasal bones that had been destroyed by the disease. No such result, however, followed. On the

2d of March the exfoliation took place, and on the 30th of April the forehead had healed. (Hospital, 129, 126.) 1868.

Dr. H. J. Bigelow.

1310. A sequestrum that involved the whole anterior portion of the lower jaw. From a healthy man. Disease of two years' duration, and attributed to mercurial salivation. Bone quite loose and removed at once. Jaw otherwise sound. 1863.

Dr. H. J. Bigelow.

1311. A second, that involved almost the entire front of the lower jaw. From a healthy infant, about two years old. This patient, and the last, were both brought to the hospital as out-patients on the same day. Duration of disease in this case for several months. Cause unknown. Bone loose, and removed at once. 1863.

Dr. H. J. Bigelow.

1312. The lower and upper maxillary bones, very extensively necrosed; from a man who had been engaged in making friction matches, and was thus exposed to the fumes of phosphorus, which at last caused the disease. When first seen by Dr. B., in March, his lower jaw was immensely swollen, and his tongue and gums highly inflamed. The following January he died of acute meningitis. Some of the bones of the nostrils, and the sella turcica were also necrosed. 1856.

Dr. H. J. Bigelow.

1313. Sequestrum, from the side of the lower jaw, $2\frac{1}{4}$ in. in length, and about 1 in. in diameter. Infiltrated with a deposit from the saliva, and consequently very compact and heavy.

From a hospital patient, æt. forty-nine (36, 228). Disease of nearly one and a half years' duration; and came on as an acute inflammation, after exposure to cold; side of face much swollen, and presented the appearances so often seen in necrosis. The sequestrum had been loose for two months, and was removed from the inside of the mouth. 1856.

Dr. H. J. Bigelow.

1314. A sequestrum from the humerus, $6\frac{1}{2}$ in. long, and from the articular surface upward it comprises a very consider-

able part of the bone, so far as it extends; the surface being partly smooth, though mostly rough.

From a healthy boy, fifteen years of age. (Hospital, 41, 198.) One year previously the arm was badly broken, and he had compound dislocation of the elbow. The fracture did well; but four months after the accident two small pieces of dead bone came from the wound at the elbow, that had never healed, and afterward the lower extremity of the humerus began to push out. Fistulous openings formed along the shaft, and for the last two months the upper extremity of the sequestrum had protruded. The arm was found shortened, much enlarged, and very hard; and the elbow immovably flexed. The lower end of the sequestrum had become black, and the boy had "amused himself from time to time, by whittling off the end with his jackknife." The bone having been removed, he was discharged in a few days; and, when heard from four or five years afterward, he had a good arm, and sufficient motion at the elbow. 1856. *Dr. H. J. Bigelow.*

1315. Necrosis of the clavicle. The separated portion is more than $2\frac{1}{2}$ in. in length; and, to some extent, the whole thickness of the bone is involved. 1847.

Dr. J. C. Warren.

1316. Sequestrum, $1\frac{3}{4}$ in. long, from the interior of the humerus, and involving to some extent more than one-half of the circumference of the bone; also a smaller one, $1\frac{2}{3}$ in. long, with some of the pieces of new bone that were removed with the sequestra.

From a young man, nineteen years of age. (Hospital, 111, 119.) Two years previously he had had "rheumatic fever;" followed by an abscess about the middle of the arm, that opened some weeks afterward, and had continued to discharge. Pain sometimes severe, though generally slight. Bone removed at once, and the patient did well. 1863.

Dr. H. J. Bigelow.

1317. Portion of bone removed from the tibia, in case of necrosis. One, which must have been loose, is nearly 6 in. long, and includes the central cavity almost throughout, though with only a comparatively small part of the whole

thickness of the bone. Of four others, from $2\frac{1}{2}$ to $3\frac{1}{4}$ in. in length, two are partly dead, and two consist of new bone that had confined the sequestra. The marks of a trephine and cutting instrument are seen.

From a soldier, æt. twenty-one years. About a year previously a rifle-ball struck the leg at about the junction of the upper and middle thirds, and glanced down the bone. The wound remained open; and in the space of about 6 in. there were seven sinuses, with a fetid discharge. Did well after the operation. (Hospital, 111, 136.) 1863. *Dr. H. J. Bigelow.*

1318. Sequestrum, about 2 in. long, and apparently from the femur. 1847. *Dr. J. C. Warren.*

1319. Sequestrum, $3\frac{3}{4}$ in. long, and slender; from the interior of some long. bone. 1847. *Dr. J. C. Warren.*

1320. Necrosis of the head of the first metatarsal bone; progress of disease very rapid. From a healthy lad, seventeen years of age, who inflamed his foot by wearing a pair of new brogans, from the 6th to the 10th of November. Dec. 14th Dr. B. found swelling, and extensive suppuration, with several fistulæ, and easily removed the dead bone. 1857.

Dr. H. J. Bigelow.

1321. A portion of the pelvis, showing a large and deep cavity along the articular portion of the pubes, and that contained a sequestrum. It is smooth, though very irregular upon the inner surface; and there is very little disease of the bone about it. — The surface, externally, was red, with fistulæ; and the disease appeared to be superficial. 1856.

Dr. H. J. Bigelow.

1322. A femur, that had been the seat of necrosis for about forty years. — From a man, fifty years of age. (Hospital, 69, 103.) Suppuration almost from the first, with occasional discharge of bone. Eight openings about lower part of thigh. Health feeble. Amputated, and did well. In the interior of the bone is a cavity, about 6 in. long, with large openings from it upon each side, but no dead bone; several small pieces having been removed before the operation, and a large one before his entrance into the hospital. The bone shows the effects of chronic inflamma-

tion, so far as the disease extends; but above and below this it is quite healthy. 1856. *Dr. H. J. Bigelow.*

1323. Lower half of the femur, showing the effects of former inflammation and necrosis.

From a man, æt. twenty-seven years. (Hospital, 125, 106.) About twenty years before, he had typhoid fever, followed by "fever sores" about the lower part of the thigh, that kept open for about seven years, with occasional discharge of bone. He then got well, and remained so until 1861, when he went into the army, and after much exposure there came on disease of the knee-joint; for this last amputation was performed Feb. 10th, 1866, and on the 29th of March he died of pyemia.

The shaft of the femur, which has been sawed longitudinally, is moderately enlarged, rough and porous upon the surface; and just above the condyles, anteriorly, shows a defined cavity in, and almost extending through, the substance of the bone, large enough to admit the end of the forefinger, smooth and cicatrized for the most part upon the inner surface. The central cavity of the bone is mostly obliterated. 1866. *Dr. R. M. Hodges.*

1324. Great disease of the femur; the result of chronic inflammation and necrosis. The lower $5\frac{1}{2}$ in. of the bone is hollowed out into a large cavity, and surrounded incompletely by a thin shell of diseased bone. Amputation having been performed immediately above, the bone is seen to be misshapen, and the site of the central cavity is occupied by a solid, bony formation, for the closure of the cavity below; the structure of the bone around this solid portion being cancellous. Knee-joint flexed; ankylosis, partly bony. The tibia is healthy; but, from a change in the articular surface, the bone is inclined outward.

The patient was nineteen years of age; and the disease, which was of eleven years' duration, came on as an acute and very severe inflammation. In ten weeks dead bone was felt, and the knee was very strongly flexed. A year afterward the bone was removed, the limb was straightened, and for three years small pieces of bone only came away. His general health was good after the first few

months; but, in the spring of 1866 it failed, and in Jan., 1867, when he entered the hospital (129, 144), it was very much impaired. The knee was ankylosed, and slightly flexed, with several openings, and a discharge of foetid pus. The limb was removed by Dr. B., and in three weeks he was discharged well. 1868. *Dr. H. J. Bigelow.*

1325. Cast, showing the external appearances in the above case before amputation. 1868.

1326. A portion of fibula, 6 in. in length, light and earthy, with fusiform enlargement. A great part of the calibre has been destroyed, and there remains in its place a cavity from which a sequestrum had undoubtedly been discharged; a small piece of dead bone being still adherent, though the inner surface is generally smooth. 1847.

Dr. J. C. Warren.

1327. Lower half of the femur, of which the cavity is hollowed out, and the inner surface smoothed as if it must have contained a sequestrum; with a large opening upon the anterior surface. The upper portion of the specimen is enlarged, very rough as from a new deposit, and terminates in a short and very irregular edge, but without any appearance of fracture. In structure it is extremely light. 1847.

Dr. J. C. Warren.

1328. A portion of the shaft of a long bone, and probably the femur. Somewhat curved, much flattened, and altogether small and atrophied. The parietes are very thin, and leave a free cavity within, that terminates in a marked cul-de-sac, and is bounded in part by the internal, light, reticulated tissue of the bone. The cavity looks like one that had contained a sequestrum, though there is no appearance of inflammation of the bone. 1847.

Dr. J. C. Warren.

1329. Almost the entire length of the femur, from below upward. The canal opens midway, and above this the bone gradually becomes narrower, and at last tapers almost to a point; the edges being smooth. Very little enlargement, or roughness of the surface. Structure light; and the central canal is smooth, and hollowed out, as if it had contained a sequestrum. 1847. *Dr. J. C. Warren.*

1330. Transverse section of a femur, removed by Dr. W., in an operation for necrosis. Bone very much enlarged; structure light, and in a cavity in its substance a small sequestrum is seen. 1847. *Dr. J. C. Warren.*
1331. A portion of the femur, apparently; 6 in. in length, and about $1\frac{2}{3}$ in. in diameter. Where it has been sawed across there is no trace of a cavity, but a uniform and rather light bony structure; the very surface only being compact. No periosteal deposit. The other extremity terminates in two long and strong bony projections, or prongs they may be called; with a considerable amount of caries upon the inner surface, though the longest one has for the most part a smooth and cicatrized appearance. Perhaps from a case of necrosis; and not certainly human. 1847. *Dr. J. C. Warren.*
1332. The seven cervical vertebræ of an adult. Bodies and articulating processes extensively fused, with considerable deposit of new bone, and a strong inclination of the atlas toward the left side. Bones quite solid. 1863. *Dr. O. W. Holmes.*
1333. Eight dorsal vertebræ; bodies anchylosed along the front, and toward the right side, by the growth of new bone from the edges of the bodies. 1847. *Dr. J. C. Warren.*
1334. Five dorsal, and two lumbar vertebræ; exostoses from the edges of the bodies, with partial anchylosis. From a laborer, about sixty years old. When eighteen years of age he fell down the hold of a vessel, and ever afterward had trouble in his back, with general rheumatism; dying at last of cardiac disease. 1866. *Dr. J. S. Jones.*
1335. Three lumbar vertebræ; a thick mass of new bone unites two of the bodies upon the front, and toward one side. 1847. *Dr. J. C. Warren.*
1336. Specimen very similar to the last. 1847. *Dr. J. C. Warren.*
1337. Two lumbar vertebræ; bodies anchylosed as in the above, but interesting on account of the extensive fusion of the articulating processes upon one side. 1847. *Dr. J. C. Warren.*

1338. Two lumbar vertebræ; articulating processes broadly expanded, thickened and rough. 1847.

Dr. J. C. Warren.

1339. Two lumbar vertebræ; partial ankylosis, etc., of bodies. 1847.

Dr. J. C. Warren.

1340. Last dorsal, and three upper lumbar vertebræ. The bodies are diminished in thickness, and in the case of one of them very greatly so; with exostoses from the edges. 1847.

Dr. J. C. Warren.

1341. Longitudinal section of six dorsal vertebræ, in which the edges of the bodies, the laminæ, and the heads of the ribs are co-ossified; with a considerable ant. post. curvature. 1847.

Dr. J. C. Warren.

1342. Three lumbar vertebræ of a horse, and of which the bodies of two are co-ossified. 1851.

1343. Sacrum, and last lumbar vertebra; united upon one side by a thick bony mass. The sacrum is unusually straight. 1847.

Dr. J. C. Warren.

1344. A scapula, that shows the effects of chronic arthritis; and prepared by Mr. G. W. Pease. The acromion process is considerably lengthened by the addition of three pieces of new bone, that are as yet quite separate; and upon the under surface of these, and of the process, is a very marked and eburnated articular cavity. The coracoid process is enlarged; and eburnated at the extremity; and the glenoid cavity is enlarged, though scarcely eburnated.

The articular surface of the head of the humerus (No. 257) is enlarged anteriorly and definitely, so as to involve the true neck of the bone, and the two tuberosities; and this was the only part, Mr. P. thinks, that came in contact with the articular surface of the scapula.

From a male dissecting-room subject; the fingers seeming to be deformed as by rheumatism. 1863.

Dr. D. W. Cheever.

1345. Bones of the elbow-joint, showing the effect of chronic arthritis, — a growth of new bone about the articular surface of the humerus, and almost a filling up of the olecra-

non fossa. The lower extremity of the other humerus is also shown, and is in very much the same condition.

From the dissecting room. See next specimen. 1860.

Dr. R. M. Hodges.

1346. A portion of newly formed bone, nearly or quite half an inch in diameter, and that was said, by the student who dissected the subject, to have been lying free in the cavity of the joint in the last case; though more probably it was in the capsule. The articular surface of the humerus, toward the outer condyle, is somewhat irregular, though not at all grooved, but there is no corresponding appearance upon the head of the radius. 1860.

Dr. R. M. Hodges.

1347. A second case. Bones of the elbow-joint, prepared in connection, by Dr. H., with their ligaments. A very considerable amount of new bone is thrown out about the articular surfaces; and there are also several pieces of new bone in the capsular ligament, the largest of which almost equals in bulk the tip of the little finger. The articular surface of the humerus looked well, excepting a somewhat grooved appearance. 1860.

Dr. R. M. Hodges.

1348. A third specimen. New bone about the articular surfaces, with eburation of the outer portion of the humerus. Upon the articular surface of the head of the radius, anteriorly, is an appearance as if a considerable piece of the bone may have been broken away, and, though strongly united, may have caused subsequent inflammation. This surface of the radius, and the corresponding one of the humerus, are somewhat eburnated. Bones otherwise healthy, as were the wrist and shoulder-joints. From an old subject. 1859.

Dr. R. M. Hodges.

1349. An entire pelvis, with ankylosis of each sacro-iliac synchondrosis. Otherwise quite well. 1847.

Dr. J. C. Warren.

1350. A second pelvis, rough upon the surface, and light in structure. The right ilium and sacrum are fused. 1847.

Dr. J. C. Warren.

1351. Very remarkable change in the head and neck of the femur; none of the first remaining, and a small portion only

of the last. The articular surface is altogether below the trochanter, and inclined at an angle of about 45° with the shaft of the bone; it is broad, somewhat convex, and somewhat porous, but not rough; edges everted, and irregular. The whole femur having been preserved in the present case, it is seen to be as solid and as healthy in structure, as in any adult. From Paris, and introduced here, though marked "*fausse articulation.*" 1847. *Dr. J. C. Warren.*

1352. Upper portion of the femur, showing the interstitial atrophy, and the very great change of form in the head of the bone, that sometimes occurs in chronic arthritis. From the same patient as No. 1117. 1847. *Dr. J. C. Warren.*

1353. Os innominatum, and upper part of the femur, showing the effects of "chronic rheumatic arthritis." The head of the bone is much enlarged and misshapen, and moderately depressed. A large part of the smooth surface is worn away superficially, leaving it rough and porous. Corona much enlarged by the growth of new bone, and shelving over the neck. This last is not much if at all shortened, but shows the new deposit. Acetabulum not much if at all deeper than natural, though there is a considerable addition of new bone to the edge; the bottom of the cavity being very much thickened, the pit at the bottom obliterated, and the edge continuous so as to form an opening in the place of the notch; inner surface coarsely porous, and nowhere eburnated. Traces of new deposit upon os innom. in various parts. 1860. *Dr. R. M. Hodges.*

Photographs from the Albany College Museum. 1869.

Dr. G. H. Lyman.

1354-5. These show a growth of bone from around the margin of the head of the femur, and deeply overhanging the neck. Before and after section.

1356. Head of the femur, locked into the acetabulum, by a growth of new bone around it.

1357. Upper portion of both femora. In each the neck is shortened, and the head depressed. Upper surface of the head elongated and egg-shaped, but the lower not so; some new bone about insertion of round ligament, and some shelving of edge over neck. 1860.

Dr. R. M. Hodges.

1358. Cast, taken by Dr. B., of the hand and forearm, to show the external appearances that resulted from chronic arthritis, and that might be mistaken for fracture of the forearm. 1859. *Dr. H. J. Bigelow.*

1359. Bones of the finger, in connection, and showing a strong lateral inclination of the terminal phalanx upon the second, but without any appearance of disease. 1859. *Dr. R. M. Hodges.*

1360-1. Thibert's models. Cavity of the acetabulum, enlarged, with thickening of the bone, and flattening of the head of the femur, from the same; the neck being nearly absorbed.

According to the catalogue, the result of external violence, though the appearances are those of chronic arthritis. 1847. *Dr. Geo. Hayward.*

1362. Portion of the pelvis and femur, from each side; showing a great thickening of the bottom of the first, and some new deposit about second. 1863. *Dr. D. W. Cheever.*

1363. Growth of new bone about the margin of the head of the femur. Bone dense. 1847. *Dr. J. C. Warren.*

1364. Knee-joint showing an abundant osseous deposit about the edges of the articular surfaces; these last being irregular and to a small extent eburnated. 1847. *Dr. J. C. Warren.*

1365. Eburnation of the condyles of the femur.

"There was no apparent external deformity, nor any deficiency in the motions of the joint. Eburnation existed on the whole of the anterior portion of the articulating surface of the external condyle. The patella, also eburnated and worn thin by attrition, was displaced outward, so as to be disconnected with the internal condyle. The two surfaces were marked with furrows in the direction of the movements of flexion and extension, accurately fitting together, and sliding upon each other like pieces of polished ivory. They were entirely free from cartilage, which elsewhere existed in a normal condition. The joint was surrounded with deposits of irregularly shaped new bone (*stalactites ossenses*), and a single point, pediculated, but

firmly attached, of the size and shape of a lentil, existed on the cartilaginous surface of the internal condyle." 1856.

Dr. R. M. Hodges.

1366. Astragalus and os calcis strongly but very partially ankylosed, and with growths of new bone about the edges of the articular surfaces. 1847. *Dr. J. C. Warren.*
1367. Tarsal bones of a horse, showing the disease that exists in spavin; ankylosis, with exostoses upon the surface; and the inside of the joint is as usual most affected.
1368. Two phalanges of a horse ankylosed throughout, so far as appears upon long section; with exostoses about the former seat of the articulation. The disease is known as "ringbone."
1369. The two last phalanges of a horse, strongly ankylosed, with a branching and most exuberant growth of new bone over the surface.

This and the two last specimens were presented in 1860.

Messrs. Robert T. Edes and John Homans, Jr., med. students.

1370. All of the cervical, with the first dorsal vertebræ. This last is reduced by caries to a thin plate, ankylosed to the first rib and to the seventh cervical vertebra. Spinous processes of the first dorsal and last cervical widely separated. The body of this last projects into the spinal canal, and is carious. Bodies generally in front quite rough, with growths of new bone from the edges.

From a man who died from erysipelas. More than two years before, he had abscesses, resulting apparently in dislocation of the cervical vertebræ, and followed for a year by entire loss of power of motion in the limbs; but this last was gradually restored. There was, also, perforation of the œsophagus, through which his drinks often escaped. 1849.

Dr. F. S. Ainsworth.

1371. Skeleton of a young adult subject affected with Pott's disease. The sixth, seventh, eighth, and ninth dorsal vertebræ are involved in a very strong ant. post. curvature; the bodies and laminae being fused into one mass and very extensively absorbed. Bodies of all of the dorsal vertebræ superfi-

cially carious. Ribs distorted, and the bones generally are quite delicate.

From Paris; articulated, but not in proper position.
1847. *Dr. J. C. Warren.*

1372. A second adult skeleton, similarly affected. Body of the eighth dorsal almost entirely destroyed by caries; and those of the four last curved somewhat forward and ankylosed. Articulating processes and laminae partially ankylosed. Bodies of the upper dorsal and two upper lumbar vertebrae somewhat carious. Bones generally quite healthy.

From Paris, and formerly articulated like the last specimen. Thorax and spine taken apart by Dr. N. B. Shurtleff, and properly rearticulated. 1847.

Dr. J. C. Warren.

1373. Ten dorsal and one lumbar vertebrae preserved in connection and sawed lengthwise. The bodies of the seventh, eighth, ninth, and tenth dorsal are more or less absorbed, and two of them almost entirely so; the curvature amounting nearly to a right angle. Bodies fused, but not continuously. Laminae ankylosed, and also the heads of the ribs. Between the last dorsal and first lumbar there is more recent disease; the intervertebral substance being entirely destroyed, and the adjoining bodies considerably necrosed, with caries about the dead bone. In the intervertebral substance, also, between the tenth and eleventh, and between the eleventh and twelfth vertebrae, was a small cavity that contained a little curdy matter, and was formed independently of the bone.

From a male subject, who was greatly deformed. Extensive tubercular disease of the lungs; with pus between the ribs upon each side, but none along the psoas muscle.
1860.

Dr. R. M. Hodges.

1374. Six dorsal vertebrae, showing an extensive destruction by caries of the bodies of the ninth and tenth, with slight curvature.

From a man æt. fifty, who died at the hospital (218, 245). Disease of four months' duration; failure of health, loss of muscular power with involuntary twitchings, etc., of lower extremities, paralysis of bladder, with tenderness,

and much pain in spine, during a considerable part of the time. The lung adhered strongly to the carious vertebræ; and, on tearing it away, there was an escape of pus. Some tubercles in one lung, and with pus in the kidneys. Specimen prepared by Dr. E. 1859. *Dr. C. Ellis.*

1375. Destruction by caries of the whole body of the seventh dorsal vertebra, almost the whole of the eighth, and about one-third of the sixth. Curvature marked, but not great; there being quite a large open space in front, and ankylosis between the spinous processes of the sixth and seventh vertebræ for the support of the column. The theca is exposed to a large extent, and the general appearance is that of an old and arrested disease. The bodies of the two upper lumbar vertebræ are also extensively carious; more than one-half of the body of the second being destroyed, and the whole of the first, excepting the very upper portion. This last disease appears recent and progressive, as compared with the above; and the curvature is sufficient to have brought the diseased surfaces nearly into contact. Between these two portions of the spine the bodies are somewhat diseased superficially, and the intervertebral substance between two of the lower dorsal vertebræ is destroyed; but otherwise the spine, the whole of which is preserved and has been prepared by Dr. J., is healthy.

The patient was a German woman, æt. twenty-six years, and accustomed, as her countrywomen are, to carrying heavy weights upon her head. In Nov., 1847, having always before this time had robust health, she was in a steam-car, that was thrown off the track and demolished, about a mile and a half from this city. Several persons were killed, and she was half buried by the ruins of the car that she was in. On her arrival in this city she was able to walk, with assistance, to a carriage, and from the carriage into a house. An hour or two afterwards she was seen by Dr. J., who did not think her dangerously injured. On removing her corsets she complained of considerable dyspnœa, and of much pain about the middle of the dorsal vertebræ; saying that she felt as if she had been "twisted off." There was also tumefaction of the integument at the same part, with projection of the spinous processes, and in a few

days extensive ecchymosis. The pain and tenderness in the loins was more complained of afterward. In about three months she was able to move about the room with the aid of a chair; but in less than a week she was obliged to go to bed again on account of pain; and subsequently a lumbar abscess formed. About this time she was found to be pregnant; and just nine months after the accident labor threatened, but she was not confined until three weeks afterward. The child was unhealthy, and lived eighteen months. The mother lived one year and nine days from the time of the accident, and from first to last there never was any loss of sensibility or muscular power, nor any affection of the sphincters, though there was a drawing up of the lower extremities with very great pain. The abscess discharged freely so long as she lived; and, on dissection, was found to extend from one diseased portion of the spine to the other.

Dr. J., who attended the patient throughout, and who has given the above history of the case, supposes that the spine was broken in two places at the time of the accident, and that caries supervened; but there is certainly nothing now in the dorsal portion to show that it had ever been fractured. The lumbar portion looks more as if there may have been such an injury, but there is no appearance there of any attempt at reparation, though there is an anchylosis of the transverse processes upon one side. 1866.

Dr. J. S. Jones.

1376. Section through the spine and pelvis of an adult; bones of one-half preserved in connection, with the ribs. Curvature so acute that the body of the eighth dorsal nearly touches the fourth lumbar; and the lower rib comes in contact with the crest of the ilium; those of the three last dorsal vertebræ and the first lumbar mostly absorbed, and fused into an irregular mass. Laminæ also extensively fused. The spinal canal is sufficiently large. 1847.

Dr. J. C. Warren.

1377. Eight vertebræ, mostly dorsal; in spirit. One of the bodies is very nearly destroyed; and, the laminæ being cut away, there is seen to be extensive caries upon the back

part of two or three of the bodies. The membrane in front is thickened, and beneath it there had been an extensive abscess; the surface of the bone, however, not being much affected. 1847. *Dr. J. C. Warren.*

1378. A section through two lumbar vertebræ. One-half is in spirit, and shows in the back part of each body a cavity about as large as the top of the little finger; one of these being filled with an opaque, curdy matter, and the other, from which it has been removed, showing a distinct lining membrane. Intervertebral substance destroyed, with some caries of the opposing surfaces. The other half was prepared as a dry specimen, for the Cabinet of the Soc. for Med. Improvement (No. 1009), and shows the smooth interior of one of the cavities, and a hypertrophy of the cancellated structure, into which there had been a tubercular deposit.

From a man, æt. twenty-seven, and a hospital patient (36, 50). Disease of more than two years' duration; but he gave up only about three months before death. A large abscess was found upon the right side of the spine, and extended far down into the thigh; and one upon the left side opens in the lumbar region. 1852.

Dr. H. J. Bigelow.

1379. Extensive and deep caries of the bodies of the tenth and eleventh dorsal vertebræ, with a more superficial disease of three of the lumbar.

From a man, twenty-five years of age, who entered the hospital Dec. 14th, 1867 (134, 126). There had been pain in the back for six months, and over the sacrum for three; his previous health having always been quite good. An abscess was opened; after which he became feverish and delirious, and died on the 8th of January.

Much caseous matter, with large and extensive collections of pus, was found about the vertebræ; a miliary deposit throughout both lungs, tubercular meningitis, and the same disease in both testicles. 1868. *Dr. H. J. Bigelow.*

1380. Cast, in plaster, of a portion of the back of a little girl, six years old, and showing a very marked angular curvature of the lumbar vertebræ. Disease of rather more than

two years' duration; began with slight pain, and a small projection was then noticed. Went to school during the summer. Pain became quite severe, with great tenderness. Entered the hospital in January (81, 193), and was much improved by treatment. 1860.

1381. Thibert's model. Chronic abscess, connected with caries of the vertebræ, and opening at the groin. 1847.

Dr. Geo. Hayward.

1382. The same; connected with caries of the first lumbar vertebra. A small opening upon each side of the spine; with extensive cicatrices, from former counter-irritation. 1847.

Dr. Geo. Hayward.

1383. Two lumbar vertebræ. The body of one is extensively destroyed by caries; and in its centre is a piece of dead bone far advanced in the process of separation. Some chronic arthritic growth, also, from the edges of the bodies. 1847.

Dr. J. C. Warren.

1384. A lumbar vertebra, showing a large piece of bone in the process of separation from the under surface; caries not at all extensive. 1847.

Dr. J. C. Warren.

1385. Three lumbar vertebræ, showing deep caries of the bodies, but without loss of thickness. Edges of two of the bodies ankylosed by chronic arthritis. Laminæ and processes not affected. 1847.

Dr. J. C. Warren.

1386. One lumbar vertebra, similar to the last; the body being almost destroyed by caries, but without loss of thickness. 1847.

Dr. J. C. Warren.

1387. Five lumbar vertebræ, and one dorsal; preserved in connection, and showing a caries upon one side. Quite a cavity in the fifth lumbar; though the disease is generally superficial. No curvature. Bones atrophied.

From a man, æt. twenty-eight years, who died in the hospital (50, 160). Disease of nearly one year's duration, and began with severe pain in the abdomen. A large abscess formed in the groin, early in the disease, through which, toward the last, the urine passed; and a second, near the back part of the crest of the ilium. On dissection, this last was found denuded; and there was a large abscess

in the back, but none in the abdomen. The patient has been very dissolute for several years; and was in a state of marasmus when first seen. 1852.

Dr. J. C. Warren.

1388. Extensive and deep caries of the three last lumbar vertebræ, but without curvature.

From a man, æt. twenty-one, who died at the hospital (207, 156) with symptoms of tubercular meningitis. Old tubercular disease of the lungs, and bronchial glands was found, but an examination of the brain was not allowed. The upper portion of the sacrum was also carious; the cavities being filled with a soft caseous substance, and the same being found in the psoas muscles. Those portions of the bones that were not carious were infiltrated with a thick red fluid. 1857.

Dr. C. Ellis.

1389. Caries of the front of the bodies of the sacrum, and of the two last lumbar vertebræ; the body of the last lumbar being almost entirely destroyed. From a female patient, æt. twenty. (Hospital, 75, 116.) Hip disease about seven years before death; and disease of the spine for rather more than two years. A well-marked projection was found at the upper part of the sacrum, though nothing of the kind appears in the specimen. There was much pain; a large abscess opened at the groin, and a considerable amount of pus was found about the seat of the disease. 1858.

Dr. H. J. Bigelow.

1390. Sacrum, with the three last lumbar vertebræ, ankylosed into one mass; the result of former, but arrested inflammation. Strong osseous bands upon each side unite the bodies of two of the lumbar vertebræ with the sacrum, superficially, but unlike what are seen in chronic arthritis. All of the laminae and articulating processes are fused. Bones generally sound, and without curvature. 1848.

Dr. O. W. Holmes.

1391. Last lumbar vertebra, with portions of the last two dorsal. The thickness of the body of the lumbar is sufficient externally, but the upper and under surfaces are deeply concave, so that in the centre it is quite thin. Of the body of the last dorsal a portion remains; but of the one above

it is quite gone. Laminæ and art. processes fused. Possibly the result of a crushing down of the bodies by external violence. 1847. *Dr. J. C. Warren.*

1392. Fusion of the bodies and laminæ of the second and third cervical vertebræ; probably the result of inflammation, that was soon arrested. From a middle-aged woman. 1854. *Dr. L. M. Sargent.*

1393. Four cervical vertebræ, of which the bodies and articular processes, and upon the left side the laminæ are ankylosed. No curvature. 1847. *Dr. J. C. Warren.*

1394. Three dorsal, and three lumbar vertebræ; articulated. From a case of aneurism of the aorta; and within the cavity of which the bones were in part denuded. Bodies carious to a small extent; the cancelli being exposed. 1858. *Dr. R. M. Hodges.*

1395. Absorption, by aneurism, of a large part of the bodies of two lumbar vertebræ. 1867. *Dr. C. Ellis.*

1396. Upper half of the humerus, showing the results of old disease, and probably inflammation of the joint. The head and neck are entirely destroyed; and the articular surface, if it may be so called, is rough, though nowhere carious. The bone generally is curved and misshapen, but sound in structure.

From a man, thirty-six years of age, who died of internal disease (Hospital, 210, 3); and "for three years has had occasional pain in each shoulder, with some in the other joints." The appearances are not at all those of "chronic rheumatic arthritis." 1857. *Dr. C. Ellis.*

1397. Bones of the elbow-joint, showing superficial caries of the articular surfaces. From a young subject. The joint was swollen, with limited motion, and an external fistula leading to it. The bones are light and porous. 1859. *Dr. R. M. Hodges.*

1398. Disorganization of the left elbow-joint; the result, probably, of some old disease. The portion of the humerus that usually articulates with the ulna is almost destroyed; and of the inner condyle not a trace remains. The remaining portion, which is partly rough and partly ebur-

nated, is situated altogether upon the front of the humerus, and connects with the head of the radius, which is considerably enlarged, and somewhat eburnated. In the head of the ulna the most striking appearance is the great development of the ridge that is usually seen upon the art. surface; and this ridge fits into a deep fissure between what may be called the inner and outer articular portions of the humerus. No appearance of recent disease, nor of old fracture, excepting a small piece of bone that is connected with the coronoid process by fibrous substance, and that is quite as probably a new formation. Bones quite compact, but slender from atrophy.

From a middle-aged subject. The elbow was very much and almost permanently bent. 1857.

Dr. R. M. Hodges.

1399. Bones of the elbow-joint removed by excision; 3 in. of the humerus, and 2 of the ulna, with the head of the radius. The articular surfaces are superficially carious; and externally to the joint the bones are rough from the exuberance of the new deposit.

The patient was a healthy farmer, æt. twenty-four years, and injured his elbow in February, 1855. In May acute inflammation came on, with suppuration. Excision Dec. 29th. In February, 1856, there were appearances of phthisis, and in May he was discharged; the elbow having been occasionally inflamed, and more or less troublesome since the operation. (Hospital, 67, 71.) 1856.

Dr. H. J. Bigelow.

1400. A second case. The patient was a man, twenty-nine years of age, and of scrofulous appearance. (Hospital, 77, 54.) In 1852 he struck his elbow violently, and from that time had more or less trouble. In July, 1857, fistulæ began to form. In October, bone was felt, and in March, 1858, a portion of the olecranon was removed. His health failed, and in June the joint was excised. After this he improved, and in September he was discharged.

In the preparation the humerus is seen to have been removed just above the olecranon fossa, with the head of the radius, and $2\frac{1}{4}$ in. of the ulna; this last showing the cavity-

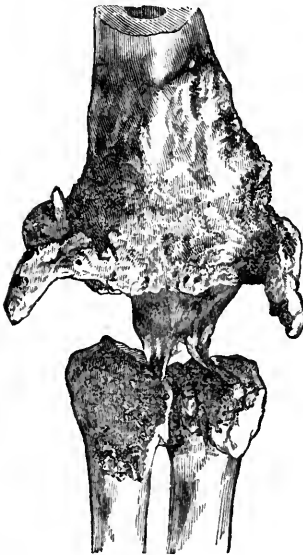that resulted from the first operation. All of the articular surfaces are carious, and externally the bones are rough from new deposit. Structure light. (See No. 1401.) 1859.

Dr. H. J. Bigelow.

1401. A portion of the humerus, and of the bones of the forearm; from the last case.

The patient returned to the hospital in about two months, with several fistulous openings, and a cavity in the former situation of the joint. Amputated Nov. 20th, and he was discharged well in Feb.

The bones, prepared by Dr. Hodges, and shown in the



adjoining figure, are connected by a fibro-cellular band, that, in the recent state, was 1 in. broad, and $1\frac{1}{4}$ in. in length. The humerus, for 2 in. above where it was originally sawed, is enlarged, rough, and somewhat carious. From the lower extremity, anteriorly, there project two defined conical processes of bone, curved forward and inward like horns, and arising, one from the inner, and one from the outer margin of the bone; their length being three-fourths of an inch, and their diameter about one-fourth; and there are also

similar, but smaller, processes posteriorly. The bones of the forearm are less diseased than the humerus; but with a considerable growth of new bone, besides a separate piece that seemed to have been formed in the soft parts.

This case has been published by Dr. B. in the *Med. Jour.* Vol. LXXVI. p. 345. He remarks particularly upon the "reproduction of the condyles of the humerus by the periosteum, — for the insertion of the extensors and supinators." He remarks, also, that caries of the elbow-joint, from dis-

ease, implies a general feebleness of the constitution, and calls rather for amputation than excision.

Dr. Hodges has remarked upon the reproduced condyles in this case, in his monograph on Excision of the Joints (p. 71), and he has copied for the Museum, a drawing of one of Mr. Syme's cases (London Lancet, March 3d, 1855), in which a somewhat similar formation was observed.

Dr. B. states, in his published account of the above case, that the patient died of phthisis about a year after the amputation; there having been indications of the disease before the operation, and the disease of the arm not having been arrested by it. 1859. *Dr. H. J. Bigelow.*

1402. Bony ankylosis of the elbow-joint. From a woman, æt. twenty-eight years. (Hospital, 119, 74.) Abscess about the joint, with caries, in June, '62; resulting in ankylosis. In Nov., '62, necrosis of forearm. Limb quite useless from that time; very painful, and ankylosed at a little more than a right angle. Amputation above the condyles in Jan., '64.

Bones prepared by Mr. C. B. Porter, one of the house-pupils.

Humerus and radius well, excepting the ankylosis. Ulna bent rather abruptly forward, and ankylosed to front of inner condyle. Olecranon seems to have been detached at some former period from the rest of the bone, and subsequently ankylosed to the humerus just below the fossa. The ulna also shows, almost throughout, appearances of chronic inflammation, though none of caries or necrosis. 1865. *Dr. H. J. Bigelow.*

1403. A second specimen, and probably the result of former inflammation confined to the joint. Bones bent to a right angle. 1847. *Dr. J. C. Warren.*

1404. A third specimen; and probably from the same cause. Section through the humerus and ulna, and one-half is shown. 1847. *Dr. J. C. Warren.*

1405. Lower portion of the bones of the forearm ankylosed to a small extent, and to a very irregular piece of bone, which is of considerable size, and must be the remains of a diseased carpus. Structure of the diseased portions light and porous. 1847. *Dr. J. C. Warren.*

1406. Anchylosis of the carpus, and five metacarpal bones, without any marked appearance of disease. Probably from superficial caries, with rapid recovery. 1847.

Dr. J. C. Warren.

1407. Bones of a finger, showing anchylosis of two of the phalanges; a similar case to the last probably. 1847.

Dr. J. C. Warren.

1408. Os innominatum, and upper part of the femur, from a case of acute hip disease.

From a boy, æt. thirteen years, who entered the hospital Dec. 2d, 1846 (30, 517). Feeble through the summer, but previously healthy. Disease of left ankle, wrist, and elbow, of eleven weeks' duration; result of a sprain; inflammation quite acute at first, with active constitutional symptoms, and in two weeks suppuration about all the joints. Ankle quite painful; and bone was felt. Elbow much enlarged, and permanently flexed. Toward the last of the month the first record appears of the hip, and of which, with the knee, he then chiefly complained; abscess opened at elbow. Gradually sank, with great suffering, and died on the 30th of July.

On dissection, the head of the femur was found partially ankylosed to the acetabulum; the cervix broken, but probably after death, as the bone crumbled on the slightest handling, and the cavity of the joint was filled with the reddish, softened debris of the broken-down bone. No tubercular disease in any part of the body. After maceration there was found some caries of the acetabulum, and a very finely marked periosteal deposit to a considerable extent along the inside of the femur, and upon both surfaces of the ilium. Where sawed across, the femur itself is perfectly sound. (See No. 1293 and next case.)

Dr. H. J. Bigelow.

1409. Os calcis from the above case. The whole posterior portion is destroyed by caries; and there was in it a cavity of the size of a walnut, and lined by a smooth membrane. The upper articular surface is carious, but the anterior is healthy. 1856.

Dr. H. J. Bigelow.

1410. Disease of the hip-joint; in spirit. The cartilage is en-

tirely destroyed; and, to some extent, the head of the femur. 1847. *Dr. J. C. Warren.*

1411. Excision of the upper 3 in. of the femur.

From a man, æt. twenty-five years, who entered the hospital Aug. 7th, 1869 (140, 228). Pain for the last two years, and first felt in the knee, with discharge of pus about the hip during the last year. As the local symptoms were urgent, and his strength was failing, the operation was performed on the 30th. Abscesses, however, continued to form; but, toward the last of October, he was able to sit up, and to be carried out of doors; and on the 14th of November he left the hospital with his health much improved.

The head of the bone is in a great measure destroyed by caries, and irregular, but scarcely rough upon the surface. The neck is also absorbed superficially, upon the anterior surface, to some extent, and very definitely; and there is some new bony deposit about it. Otherwise the bone is compact and healthy. The acetabulum, however, was much diseased, and portions of bone were removed at the time of the operation. 1869. *Dr. R. M. Hodges.*

1412. A second case. — The patient was fifty years of age, and entered the hospital Aug. 6th, 1869 (127, 98). Two years previously he injured his hip, was laid up for two months, and had complained of it from that time. In March, '69, he gave up his work; in June there was a discharge of pus; and the pain had been very great. He was very anæmic; and the limb was quite œdematous, with swelling and induration about the hip; discharge free from three or four openings, and denuded bone was felt. On the day of entrance an incision was made, and a large portion of the diseased bone was removed; but it was found to be so extensively infiltrated with pus, and the head of the bone, and also the joint were so diseased that excision was decided upon. For about two weeks after the operation the patient had very much less pain; but he then began to fall off, and on the 7th of Sept. he died.

The bone, which has been sawed through, is 4 in. in length, and very light from the interstitial absorption that

had been going on. The whole of the trochanter, a portion of the neck, and a large portion of the shaft are gone, and were probably removed at the time of the operation. Head of the bone of full size, but quite rough and denuded. Whole surface rough, as from inflammation, but without much new deposit, and without thickening of the parietes of the shaft. The interior of the bone looks as if there may have been a suppurating cavity there, and upon the anterior surface the remains of a cloaca are seen. 1869.

Dr. G. H. Gay.

1413. Disease of the os innominatum and femur; from a female, dissecting-room subject, 60-65 years of age.

“ Previous to dissection, the subject exhibited the following appearances:— There were adduction and flexion of the thigh, inversion of the foot, prominence of the trochanter, scars of old sinuses about the gluteal region, and four or five inches shortening. Motion, excepting rotation, tolerably free.

“ *Os innominatum* very thin and light, diaphanous to a remarkable extent; *dorsum ilii* convex instead of concave. The cotyloid cavity has lost its regular rounded shape; its smooth, circular lip is in a measure absorbed; its place, together with the cavity itself, is marked by bony excrescences that have partly obstructed the latter; and an extremely dense, fibrous tissue in the recent state completed this obliteration. Superiorly, and somewhat posteriorly to the acetabulum is a smooth, articulating surface, half an inch in width by an inch and five-eighths in length, which, when the specimen was fresh, was covered by a smooth cartilage.

“ The *femur* is also atrophied. The head of the bone has disappeared, and but about seven-eighths of an inch of the neck remains, irregularly rounded at its extremity; covered, where recent, on the prominent points with smooth cartilage. The *lesser trochanter* exists merely as a small spiculated process, and the space between it and the neck of the bone is transformed from its normal character to a smooth surface in the recent state, coated with cartilage, from which, here and there, fibrinous bands were thrown off. This surface articulated with that described as existing

about the acetabulum, whilst the lesser trochanter was connected by long fibrous bands with the dense tissue filling the cotyloid cavity. The smooth surface terminating the neck of the bone, extended $1\frac{1}{2}$ in. beyond the border of the acetabulum; but no new cavity or articulating surface exists where it rested on the *dorsum ilii*.

“The specimen is interesting in connection with Dr. March’s statement, that spontaneous dislocation of the hip seldom or ever takes place.” 1856. *Dr. R. M. Hodges*.

1414. The upper third of the femur, of which the articular portion is most remarkably affected; from Paris. There are the remains of a neck for the most part; but it almost at once enlarges or flares out, and terminates, as it were, in an irregularly and somewhat convex surface, about $2\frac{3}{4}$ in. in diameter. This surface, which very much overlaps the neck, has to a considerable extent a somewhat smooth and cicatrized appearance; but in it are many little holes that look like the result of caries; and in a cavity just beneath the surface, and nearly as large as the tip of the little finger, there was found, when the specimen was soaked in water, preparatory to being sawed, a curdy, opaque substance. Otherwise the bone is quite compact and healthy in structure. 1847. *Dr. J. C. Warren*.

1415. A portion of the os innominatum and femur of an adult, showing a very remarkable destruction of the bones from old disease. The acetabulum is deep and much enlarged; inner surface quite irregular; two large, and, for the most part, smooth openings through the bone, with a piece of dead bone still attached in one of them, and a third opening that is still closed by dead bone. The head and neck of the femur are entirely destroyed, with a deep cavity in the substance of the bone; surface rough from new deposit. Structure of both bones very light, as from interstitial atrophy. 1847. *Dr. J. C. Warren*.

1416. Section of the hip-joint of a child, showing complete disorganization from chronic disease. The head of the femur is quite gone, but a considerable portion of the neck remains; and at the junction of this last with the shaft of the bone there is a cavity, and in it a piece of dead bone

not yet detached. The acetabulum also is very much diseased. A dry preparation. 1867.

Dr. J. B. S. Jackson.

1417. Os innominatum, showing the result of former hip disease.

From a boy about fifteen years of age. The deformity was so great that the body was hung up, and a back view taken of the whole subject for Dr. B.'s collection of Surgical Illustrations. A slight depression only remains in the place of the acetabulum, and the bone here has a singularly reticulated appearance. There is also an opening through the bone, at this part, about half an inch in diameter. Just above and behind the acetabulum the femur was ankylosed to the ilium by a very narrow neck, but, having been accidentally broken off, it has been lost. The ilium is for the most part very light, though very thick, and upon the inner surface numerous little pits are seen, but not, apparently, the result of caries. The head of the femur was destroyed; and the lower end of the bone was exceedingly thin, and filled with a clear yellow oil. 1856.

Dr. H. J. Bigelow.

1418. Pelvis, with the upper half of both femora; from a case of former disease and dislocation of both hip-joints; prepared by Dr. C. From a middle-aged woman. There was shortening of both extremities, and great prominence of the trochanters, but no suppuration. The appearances of the bones upon both sides are about the same; neck reduced in length about one half, standing off from the shaft at a right angle, and ending in an irregularly rounded surface rather than a proper head. The acetabulum is quite shallow and irregular; and there is an irregularity upon the outer surface of the ilium just above it, but with no marked appearance as of an attempt at a false joint. 1863.

Dr. D. W. Cheever.

1419. Bony ankylosis of hip-joint, with interstitial atrophy. About 2 in. above the condyles there is a marked projection backward of the femur, with a slight depression upon the anterior face, but without the appearance of an old fracture. A graveyard specimen. 1859.

Dr. Sewell F. Parcher, E. Boston.

1420. Photographs of a case of angular false ankylosis of hip, before and after treatment. Sequel of hip disease four years previously. The femur was flexed and adducted; the knee contracted, and the foot several inches from the ground and everted. On the 1st of June, 1869, the sartorius, tensor vaginæ femoris, and adductor longus were divided, and the adhesions within the joint ruptured by "brisement forcé;" and about the last of Sept. the boy went home with a wonderfully improved limb. The femur was perfectly straight, and on a line with the body; the symmetry of the two sides being nearly if not precisely alike; and with a fair motion of the hip-joint; knee straight. The whole limb one inch shorter than the other, but the shortening was chiefly between the knee and ankle, and is fully accounted for by arrest of growth. 1869.

Dr. Buckminster Brown.

1421. Bony ankylosis of right hip-joint.

From a young man, æt. twenty, who died of leucocythemia at the hospital (273, 96). About five years before, he was kicked upon the hip by a horse, and had been lame from that time. The thigh was strongly inverted, and carried toward the left side, and the hip was quite prominent. Shortly before his death he had severe pain in the hip, and an abscess afterward opened there; abscesses being found, on dissection, upon each side of the lumbar vertebræ, and pus beneath the psoas muscles, as far as the groins.

The head of the bone is about of full size, but drawn somewhat upward and strongly ankylosed. Besides the general displacement there is a strong inward twist of the lower end of the bone. 1868.

Dr. J. Homans.

1422. A fracture of the left femur just below the great trochanter. Union strong, but very irregular, and not complete. The bone is flexed upon the pelvis nearly at a right angle, and inverted; and there is bony ankylosis of the hip-joint.

From a man who died at the hospital (280, 114), of internal disease. The thigh was 4 in. shorter than its mate. The bones overlap to that extent or more; and, a very considerable absorption having taken place of each of the fragments, it appears as if it may have been originally a very oblique fracture. 1869.

Dr. J. Homans.

1423. Caries of the articular surface of the tibia. 1847.
Dr. J. C. Warren.
1424. Thibert's model. Chronic inflammation of the knee-joint of many years' duration. 1847. *Dr. G. Hayward.*
1425. Disorganization of the knee-joint; in spirit. No remains of cartilage. Bones quite denuded, and in some parts eburnated; in others more or less rough, and covered with a soft, shreddy connective tissue. 1847.
Dr. J. C. Warren.
1426. Disease of the knee-joint. — From a man thirty-four years of age. (Hospital, 114, 86.) Sprained his knee twenty-eight years before, and it was not until two years afterward that he could get about with a crutch. In four years abscesses formed; but these healed, and he was able to walk six miles to his work. In Dec., 1863, there was severe pain, and in March an abscess formed that continued to discharge. In August the pain was still very severe, and the limb was amputated. In Sept. two profuse hemorrhages occurred, and the femoral artery was tied. Oct. 26th he died of hospital gangrene.
- On dissection, metastatic abscesses were found in the lungs, with very severe inflammation of the throat, phlebitis, and a large abscess in the thigh.
- The knee-joint, when removed, showed fleshy ankylosis, with permanent flexion; the patella being connected with the inferior surface of the outer condyle of the femur. The bones having been macerated, there is seen to be a great enlargement of the inner condyle of the femur, with irregularity and acute caries of the inner articular surface, and of the corresponding portion of the head of the tibia. Upon the very back part of the outer condyle is a smooth surface, and a corresponding one upon the outer head of the tibia, showing where the two were connected; this last being to a considerable extent absorbed. 1864.
Dr. R. M. Hodges.
1427. Lower portion of the femur, from a case of amputation at the knee-joint.
- From a man, *æt.* thirty years, who for several years had been subject to hemorrhages, but was otherwise healthy.

Having had a large, obstinate, bleeding ulcer over the shin, the leg was amputated below the knee; but the hemorrhage from the tibia was so profuse that disarticulation at the knee-joint was immediately performed. The wound never healed; and a year afterward, on his admission into the hospital (126, 256), there was a large hemorrhagic ulceration. Amputation was performed at once at the lower part of the thigh, with no more loss of blood than usual; but the next morning there were ecchymoses about the upper part of the thigh, with prostration, and the patient died about twenty-four hours after the operation.

On examination of the end of the bone, the cartilage was found to a considerable extent smooth and unabsorbed, though united to the soft parts by slight adhesions. This may be inferred from the prepared specimen, though it has unfortunately been dried. *Med. Jour. Vol. LXXV. p. 384. 1867.*

Dr. R. M. Hodges.

1428. Femur, showing a very marked anterior curvature and the remains of some grave disease of the knee-joint. Bone slender, quite porous, and somewhat rough upon the surface. 1847.

Dr. J. C. Warren.

1429. Portions of bone removed in a case of excision of the knee-joint; with one-half of the patella.

From a man, thirty-six years of age. In Jan., 1857, he was in the hospital with fracture of the right patella, and in Nov., 1858, he re-entered with a fracture of the left; (No. 1129), the separation of the fragments of the right, at this last date, amounting to $3\frac{1}{2}$ in. In August, 1859, he again entered (85, 128); the right knee having become swollen and painful, with suppuration four weeks before. Excision on the 7th of Sept. The condyles were sufficiently healthy, though there were old adhesions with the patella; one-half of the articular surface of the tibia, however, was much diseased. The patient was much reduced by the operation, but on the 6th of Dec. the ankylosis was tolerably firm, and on the 2d of Jan. he was discharged well. (See next specimen.) 1860.

Dr. H. J. Bigelow.

1430. Bony ankylosis of the femur and tibia, two and a quar-

ter years after excision of the knee-joint. (See last specimen.)

Dec. 13th, 1861, the man again entered the hospital (96, 138), with a fracture of the left thigh, and died on the 16th. A long section having been made, there is seen to be a continuous and healthy cancellated structure between the bones; anteriorly, the surfaces are continuous, though with slight flexion, but posteriorly the head of the tibia projects about three-fourths of an inch backward. The half of the patella that remained after the excision has been attached to the board, upon which the other is displayed, and is the smallest and least compact of the two. 1862.

Dr. H. J. Bigelow.

1431. A second specimen of excision of the knee-joint. The condyles are shown, to the outer of which the patella is ankylosed, and upon the cancellated surface of which a defined cavity is seen; this last, which was cut through in the operation, is about 1 in. in diameter, and the surrounding bone appears healthy. One large and two small slices from the tibia are also shown, the articular surfaces of which are irregular, but scarcely carious.

The patient was a woman, æt. twenty-four years. (Hospital, 123, 126.) When four years old she struck her knee, and was laid up for a year; but afterward used the limb freely till the age of eighteen, though with occasional pain and swelling. She then became worse and used crutches for three years, with formation of abscesses. The limb was nearly straight, but with the condyles upon the anterior edge of the head of the tibia. Motion very slight. No pain; and no discharge for the last year. Operation Nov. 10th; silver wire passed through the bones and twisted; and a straight splint applied. Profuse discharge followed, with fever and chills, and the patient died on the eighteenth day. 1866.

Dr. H. J. Bigelow.

1432. A third specimen. Condyles of the femur removed. From a little boy five years of age. (Hospital, 123, 128.) Disease since he was seven months old. Knee bent permanently to a right angle; swollen and inflamed. Operation Nov. 18th, a small piece of the tibia also removed;

both bones carious to a small extent, with an abscess in the popliteal space. Did well for a time, but afterwards lingered with suppuration and diarrhoea, and died May 30th. 1866.

Dr. H. J. Bigelow.

1433. A fourth specimen. Section of the tibia about two-thirds of an inch thick, and a portion of each condyle of the femur. Surfaces carious with eburnation.

From a man, thirty-two years of age. (Hospital, 78, 156, and Med. Jour. Vol. LIX. p. 284.) Disease of the joint of about four and a half years' duration. Recovery rapid; and in about five months there seemed to be a bony union. 1859.

Dr. J. M. Warren.

1434. A fifth specimen. Excision of about 2 in. of the lower end of the femur.

The patient (Hospital, 115, 62) was fifteen years of age, and sprained his knee when he was three years old. Four years afterward he had acute inflammation of the joint, and from that time had been unable to walk upon the limb. The knee was fixed at an angle of 110° , painful and sensitive on pressure, considerably enlarged and distorted, and with an open sinus upon the inside of the leg. The general health being good, excision was performed May 21st, 1864. A transverse incision was made, and carried well down upon the sides for the escape of the pus that might subsequently form. The bone was then removed with the patella, which was consolidated with it, and also a small portion from the tibia; the caries being rather deep, though limited. Considerable force was required to break down the false ankylosis that existed. Hamstring muscles divided. Diseased synovial membrane cut away with the scissors. The rigidity of the nerve and vessels in the popliteal space rendered the straightening of the limb considerably difficult, even after the removal of the bone. During the first forty-eight hours there was a strong tendency to displacement, which was overcome by straps and firm compression; but four weeks after the operation, there was some stiffening of the bones, suppuration had diminished, and after a very long convalescence, he was discharged well, June 14th. 1865.

Dr. R. M. Hodges.

1435. A sixth specimen. Condyles of the femur excised, with the patella, to which they are firmly ankylosed.

The patient, æt. twelve years, entered the hospital Feb. 19th, 1868 (134, 188). Five years before, he received a cut near the knee with a hatchet. Considerable inflammation followed, and a year afterward the joint was stiff at an angle of 45°. On admission, the knee was not enlarged nor painful, but firmly ankylosed. On the 22d, the operation was performed; the head of the tibia not being interfered with. One large and one small thin slice of bone were, however, removed from the femur, in order to bring the bones into good apposition. Holes were drilled in these last, which were sufficiently healthy, and silver-plated wires were passed through and twisted. On the 26th of April the wires were removed. On the 12th of May there was firm union, and on the 12th of June he left the hospital. 1868.

Dr. H. J. Bigelow.

1436. A seventh specimen. The tibia and the posterior portion of the condyles of the femur are extensively, and for the most part deeply carious; and there is caries of the under surface of the patella.

From a man, æt. twenty-six years. Disease of two and a half years' duration. Knee bent at an angle of 40°, and immovable, as well as the patella. Head of the tibia drawn back under the condyles of the femur. Very little enlargement, and no external opening, but considerable pain. General health good. The operation was done Sept. 30th, 1868; suppuration followed, and the thigh was amputated Feb. 12th, after which the man did quite well. (Hospital, 135, 258.) 1869.

Dr. R. M. Hodges.

1437. Portions of the femur and tibia, from the above case after amputation. The opposing surfaces of the bones are denuded and carious, and in some parts there is a considerable loss of substance. 1869.

Dr. R. M. Hodges.

1438. An eighth specimen. From a woman, æt. thirty-two years. (Hospital, 120, 138.) Disease of twelve years' duration. The leg was dislocated backward, and permanently flexed so that the toe just touched the ground when she was erect. Oct. 11th, the femur was sawn through above the condyles,

and a portion of the tibia, three-fourths of an inch in thickness, was removed, besides a second thinner piece; and, on the following day, as the bones were not in proper position, the wound was opened and two silver wires were passed through them. Some suppuration, with discharges of small pieces of bone, continued so long as she remained in the hospital, but she was otherwise doing quite well when she left on the 9th of Dec.

In the preparation the facettes by which the bones are connected are small, but quite marked, and situated far back, in accordance with the position of the limb before the operation. The original articular surfaces are otherwise effaced. 1865. *Dr. R. M. Hodges.*

1439. Bony anchylosis of the knee-joint. — From a man, æt. fifty-nine years. (Hospital, 54, 135.) At the age of twenty-four years he cut into the knee-joint with a broad axe, and nearly lost his limb. Two or three years afterward an ulcer formed upon the leg, continued from that time, and at last required amputation. Died with albuminuria, etc., about two months after the operation.

The bones of the leg, and particularly the fibula, are affected as usual in cases of old ulcer; enlarged, misshapen, solid, and rough upon the surface from spines and bony growths of various forms. 1852.

Dr. S. D. Townsend.

1440. The same between the patella and femur; with old disease of the articular surface. 1847.

Dr. J. C. Warren.

1441. Knee-joint flexed to an acute angle, showing an extensive and bony anchylosis between the patella and the under surface of the condyles of the femur, and also between the inner condyle and the tibia. Between the tibia and outer condyle the union is close, but probably not bony. The outer condyle is mostly absorbed, and there is a considerable growth of new bone from the upper and outer portions of the patella. On section several large shot are seen, more or less battered, in the substance of the bone, and some project into the cavity of the joint; others, that were removed when the specimen was prepared, being shown in a phial. The structure of the bone is sound.

The patient, æt. nineteen, entered the hospital (125, 32) Nov. 8th, 1865. Four years before he was shot in the knee, and for the next year kept his bed, with much swelling and profuse suppuration. No motion in joint for three years, though there was but little pain. The knee was bent to an acute angle; the leg was much atrophied, and the bone could be felt through an old sinus. Amputation on the 11th. On the 21st the bone protruded; much pain followed; and on the 29th of Dec., 5 in. of the femur were removed. To the extent of about 4 in. it was surrounded by new bone from $\frac{1}{8}$ to $\frac{3}{4}$ in. in thickness; and on section, in the recent state, it showed finely the appearances of osteo-myelitis. (See Nos. 1280-1). Feb. 7th he left the hospital, and finally got well. 1866.

Dr. Geo. H. Gay.

1442. Knee-joint ankylosed, with enlargement and other appearances of chronic inflammation of the femur. 1854.

Dr. R. M. Hodges.

False ankylosis; Series **xxi.**

1443. The astragalus, os calcis, and bones of the leg, from a case of disease of the ankle-joint. The astragalus, which seems to have been the chief seat of disease, is very rough and irregular upon its upper surface, deeply carious upon the outer face, and ankylosed to some extent to the os calcis, which last shows the effects of inflammation. Anterior articular surface of both bones healthy; those of the bones of the leg being carious. The other bones of the foot were affected with interstitial atrophy.

From a young man, eighteen years of age. (Hospital, 91, 68.) Disease for six years, and came on without obvious cause; pain, swelling, and stiffness. Two small openings, and bone felt; leg much atrophied; amputated and did well. 1860.

Dr. H. J. Bigelow.

1444. Upper half of the astragalus, from a woman about forty-five years of age, "and of a decidedly scrofulous diathesis." In June, 1865, she complained of having sprained her ankle; and, when first examined, some weeks afterward, there was considerable swelling, with tenderness, and pain on motion; the pain being generally slight. In Dec.

several openings formed, and the patient died, worn out by the disease, on the 1st of March; there seeming to be no time when, from the state of the system, amputation could have been performed.

In the recent state a large portion of the articular surface was not merely entirely denuded of cartilage, but as polished as glass, and this appearance is still quite well shown; the remainder being superficially ulcerated, and covered by a thin opaque deposit. The polished portion seemed to consist of a very thin and delicate lamina of bone that might have been broken through with the thumbnail, and without any of the solidity beneath that exists in a case of eburnation; the bone being very light. The whole corresponding surface of the tibia resembled the ulcerated portion. 1849.

Dr. George Faulkner, of Jamaica Plain.

1445. All of the tarsal and metatarsal bones co-ossified, excepting the fifth, which is not preserved.

From a case of frost-bite, with extensive sloughing. Metatarsal bones pointed anteriorly. A broad spine has formed upon the back of the os calcis; and the whole specimen is very light. 1847. *Dr. J. C. Warren.*

1446. Bones of the foot, from which the fourth toe, with its metatarsal bone, had at some former time been removed. Tarsal bones carious, with some ankylosis. Prepared, in connection, by Dr. H.

From a delicate female, about thirty-five years of age; foot much everted; with sinuses, through which the bone could be felt. 1856. *Dr. R. M. Hodges.*

1447. Cast of a foot, from which the tarsal bones had been extensively removed.

“A man, thirty-one years old, seven weeks previous to his admission to the hospital (118, 216), wounded the dorsum of his left foot deeply with an axe. Abscesses, extensive suppurative inflammation of the soft parts, and disease of the tarsal bones followed. His general health depreciated in consequence. July 22d it was found that the finger could be passed through the tarsus to the sole of the foot. By a transverse incision across the instep, the proximal

heads of all the metatarsal bones, the three cuneiform bones, and the cuboid, all of which were diseased, were removed. A large incision was made longitudinally through the thickness of the sole, to permit the escape of pus. In making the dorsal incision, the extensor tendons were disregarded, as their usefulness had already been destroyed by the primary injury and the subsequent inflammation. Aug. 17th the patient sat up. Aug. 27th he began to walk by the aid of crutches. Sept. 1st the wound was entirely healed.

"Sept. 11. — Having been about the hospital grounds for ten days, the cicatrix being perfectly sound and firm, and his health entirely re-established, the patient was discharged. The foot was somewhat shortened, though otherwise but little deformed. Its plantar aspect was convex instead of concave; the bulging being due to the flexion caused by approximating the surfaces of the gap made in the skeleton of the foot. The pressure of further use promised to remedy this. For walking, the stump was preferable to any which could have been left by an amputation of a portion of the foot, the only alternative of the operation performed."

1865.

Dr. R. M. Hodges.

1448. Cast of a foot, from which all of the tarsal bones had been excised, with the ends of the tibia and fibula.

The patient, a little boy five and a half years old, was run over July 14th, 1865, and three hours afterwards entered the hospital (120, 74). The right foot was very extensively lacerated, but without fracture or dislocation; and the left was similarly, but less, injured. On the 15th numerous punctures and incisions were made, to relieve the tension, which was very great, and with much relief. On the 18th there was a mild attack of scarlet fever, but with prolonged convalescence; and, meanwhile, all active inflammation of the feet subsided, and the left got quite well. Over each malleolus of the right there was broad ulceration, and dead bone could be felt.

Sept. 6th, the general health being sufficiently improved, the foot was examined, and it was found that there was general necrosis of the tarsal bones, and that the ends of the tibia and fibula were also involved. About 1 in. of

these last were therefore removed, and all of the first; an effort being made to leave behind all the periosteum possible. Oct. 6th the wound had healed, the foot had regained its shape, and differed only from its fellow in length and the want of prominence at the heel. The patient could raise and hold it out himself, and wore only a small tin splint, with a foot-piece for support. Oct. 13th he began to walk; and, though the foot was considerably shortened, it furnished a remarkably firm and hard-padded stump, promising advantages over an artificial substitute. General health and flesh entirely restored.

At the end of six months these patients were both doing quite well; the man doing full work as a ship-carpenter, and the boy playing about as freely as any one, though limping somewhat. 1865. *Dr. R. M. Hodges.*

1449-50. Great deformity from an old injury. Casts of the foot, before and after operation.

The patient, a boy, æt. nine years, entered the hospital June 11th, 1867 (132, 96). When two years old he wounded the foot; abscesses followed, and in about five months bone was removed. For nine months the wound did not heal, and the foot did not grow. Ankle had always required support; and for the last two years the foot had been turning out, so that, on entrance, the boy walked upon the inside of the foot and end of the tibia. Foot much smaller than its mate. On the 12th about $1\frac{1}{2}$ in. of the tibia were removed, and about $\frac{1}{2}$ in. of the fibula. No ligatures required. Splints were applied, and subsequently a dextrine bandage. Occasional discharge of small pieces of bone; but on the 30th of Sept. the boy was discharged well.

Nov. 30th, he reported at the hospital. Could walk quite fast and without support, but with a slight limp. Ankle quite healed, and much smaller than when discharged. 1867. *Dr. R. M. Hodges.*

1451. Bones removed from the above case. 1868.

Dr. R. M. Hodges.

1452. The whole astragalus removed, with the two mallcoli and a thin slice of bone from the tibia.

The patient, a man æt. twenty-two years, entered the hospital Aug. 22d, 1867 (132, 160). Disease of one year's duration, and cause unknown. Gradually increasing swelling, but without much inconvenience until the last three months, when an opening formed, and he gave up his work. On admission, the ankle was about twice its natural size, and denuded bone was felt. On the 28th the joint was cut down upon; and, after forcible dislocation, the bones were removed; the tendons being preserved, and two ligatures only being required. Oct. 16th the parts were not doing well, and the leg was amputated. Still further the stump did not do well, and on the 15th of Feb. $1\frac{1}{2}$ in. of the bone were removed. March 24th he left the hospital. Oct. 26th he was readmitted; Dec. 12th bone was again removed, and on the 23d of Feb. he was discharged well. 1867.

Dr. R. M. Hodges.

1453. Bones of the leg, after amputation; from the last case, 1867.

Dr. R. M. Hodges.

1454. Foot from the above case; a ligamentary preparation, and showing some appearance of caries upon the articular surface of the astragalus and scaphoid bone. 1867.

Dr. R. M. Hodges.

1455. Ankylosis between the bones of the leg and the astragalus, os calcis, and cuboid; the result of old disease of the ankle-joint. 1847.

Dr. J. C. Warren.

1456-7. Tarsal and metatarsal bones from different subjects co-ossified, but no sign of other disease. 1847.

Dr. J. C. Warren.

1458. Coccyx co-ossified with sacrum; long. section. 1847.

Dr. J. C. Warren.

1459. Ankylosis between the upper articular surface of the fibula and the tibia; but without any appearance of disease. 1847.

Dr. J. C. Warren.

1460. The same, between these bones, at the lower third, and to the extent of about an inch and a half. An ossification, perhaps, of the interosseous ligament. 1847.

Dr. J. C. Warren.

1461. Lower jaw of an adult, showing a rounded pedunculated,

perfectly defined exostosis, arising from the outer surface, and below the bicuspid teeth; surface rather uneven, and structure hard. Bone otherwise quite healthy. 1847.

Dr. J. C. Warren.

1462. Cast of a skull, showing a most remarkable development of tumors upon the surface. The lower jaw is surrounded by them upon the outer surface. There is also one below each orbit, one about the left zygoma, and a small one some way above the left ear. From the Phrenological Collection.

A similar cast is in the Dupuytren Museum at Paris; and, the curator, having been applied to for information in regard to it, stated that the case is at least a hundred years old, and that there is no clue to its history. 1847.

Dr. J. C. Warren.

1463. Exostosis from the back part of the upper jaw; smooth, rounded, about the size of a horse-chestnut, and contained two molar teeth.

The patient was a clergyman, and the tumor, which was of six years' duration, had troubled him only mechanically. Removed by bone forceps; and the patient did well. 1868.

Dr. H. J. Bigelow.

1464. Photograph of a case of ivory exostosis of the frontal region.

The patient, a healthy farmer, æt. twenty-four, entered the hospital under the care of Dr. H., Oct. 18th, 1864 (114, 244). Three years previously, he fell upon the ice, struck his forehead, and just afterward a tumor appeared, that, on admission, extended from the left temple to just beyond the median line, and from the roots of the hair downward into the orbit. The eye protruded, and was displaced downward and outward. The tumor was 5 in. by 5½ in. in diameter, and protruded 2¼ in. Integument not affected. Surface uniformly smooth, but with an imperfectly marked division into a frontal and an orbital portion. Felt bony and immovable, except at one or two points where there was an elasticity, as from a thin, bony cyst. Not sensitive, though at times very painful. Vision

impaired ; and attempts to raise the lid caused severe pain in the eyeball. Never any cerebral symptoms.

The man stated that the tumor had a bony feel from the first, but that, at the end of a year, a fluctuating spot appeared toward its inner border, was punctured, and discharged a sanious, watery, purulent fluid ; the tumor being then, and subsequently, exceedingly painful. Some months afterward it was punctured again, in the same spot, and with a similar result. At that time, July, 1863, he had typhoid fever ; and the tumor afterward increased with great rapidity.

Oct. 19th an operation was performed, when a thin shell of bone, deficient at various points, was found expanded over the tumor ; and, between the two, a quantity of degenerated pus. Two slices of the tumor were removed by an amputating saw ; and then, with the mallet and chisel, the remaining portion was cut down to a level with the frontal bone, and gouged out from the orbit, so that the eye could be restored to its natural position. Of four chisels that were used, the edge of but one could act upon the dense ivory structure. There was not the slightest sign of vascularity in any part of the tumor.

After the operation he did perfectly well till the 11th of November ; eating steak, etc., with great relish. Then œdema of the forehead came on, followed by severe headache ; but on the 16th he was doing well again. On the 20th he was less well, and had severe pain ; on the 21st, delirium ; on the 23d, coma ; and on the 24th he died.

On dissection, the tumor was found to project internally, as it did externally, and to compress the left anterior lobe of the brain, the whole of which last had been converted into an abscess.

The right hemisphere, where, in contact with the left, was sloughing and purulent for the space of a square inch, but the meningeal inflammation was slight.

In structure, the internal, like the external portion of the tumor was uniformly dense throughout, and nowhere cancellated ; but, from its color and general appearance, it would seem to have undergone necrosis, though, being so devoid of vessels, this could not easily be determined. It

was loose in the framework of the frontal bone; whereas, when operated upon, it was perfectly fixed. There was also a bony shell about the internal portion, as about the external, but without the intervening puriform substance; and the tumor itself was invested with something like a membrane, that was easily wiped off, and that was not observed upon the external portion. The nasal cavities were invaded; and the whole posterior part of the orbit was filled with a series of small lobules connected with the main tumor; but there were no isolated formations. The growth had nowhere separated nor distorted the bones; but seemed to have its origin in the frontal sinus, or the diploe of the frontal bone; the bony shell about it being probably the expanded inner and outer tables of the bone.

In a published report of this case (*Med. Jour.* Vol. LXXI. p. 415), Dr. H. refers to a similar operation having once been done successfully; and also to the treatment by caustics, by means of which the tumor dies, and is cast off. 1864.

Dr. R. M. Hodges.

1465. A portion of the frontal bone, with the tumor, as above described. 1864.

Dr. R. M. Hodges.

1466. A rounded ivory exostosis, as it appears on section, about $\frac{7}{8}$ by $\frac{5}{8}$ in. in diameter, and removed from over the base of the mastoid process of the left temporal bone.

From a girl, twenty-six years of age. Tumor of eight years' duration, and not painful. (*Hospital*, 139, 238.) 1869.

Dr. R. M. Hodges.

1467. A portion of the parietal bone of an old man, showing externally a small but deep depression, and internally a considerable growth of new bone. This last looks superficial, as if it might be scraped off; and a portion of it is not connected with the bone beneath. There was no cicatrix on the scalp; and it is doubtful whether the condition of the bone was caused by disease or injury. 1856.

Dr. R. M. Hodges.

1468. A small, irregular exostosis, upon the outside, and just below the middle of the humerus. 1869.

1469. Cast of a hand, showing a tumor over the back of the

metacarpal bone of the index finger, and taken by Mr. C. H. Hildreth, one of the house-pupils. The patient was an Irish girl, æt. eighteen years. (Hospital, 48, 116.) The tumor, ten years before entrance, was of the size of a bean, and had gradually increased. Never painful nor tender; and the motions of the finger were but little affected. It measured 4 in. in circumference, and $1\frac{1}{4}$ in. in elevation; knobbed in form; bony to the feel, and firmly connected with the bone, though not with the integument; the extensor tendon passing on the ulnar side. Removed by Dr. W., who found it to be altogether a bony formation; and the patient did well. 1851. *Dr. J. M. Warren.*

1470. An osseous growth, about $\frac{1}{2}$ in. in diameter, and surrounded by a thick cartilaginous formation; a section showing that the structure is cancellated. Removed from the back part and anterior extremity of the metacarpal bone. 1864. *Dr. H. J. Bigelow.*

1471. The upper part of the femur, showing a most exuberant coralloid growth of bone in broad, hard, and irregular laminae, arising from the linea aspera, and just below the trochanter minor; the base being quite defined. The bone, otherwise, is quite healthy. Placed with the exostoses, though it may have been the bony skeleton of some tumor. 1847. *Dr. J. C. Warren.*

1472. Upper portion of the femur, showing an exuberant growth of soft bone, about and below the small trochanter. No cancerous disease about it in the recent state. 1854. *Mr. Wm. Henderson, med. student.*

1473. Long. section of the lower portion of the femur; the whole anterior portion of which projects forward, and particularly at one point from which, as Dr. W. stated, a cartilaginous tumor had been removed. Structure of the bone quite healthy. 1847. *Dr. J. C. Warren.*

1474. A patella, showing a considerable and defined growth of new bone from its lower margin, and below the articular surface. Bone otherwise healthy. 1847. *Dr. J. C. Warren.*

1475. A broad, irregular expansion of hard bone, from the upper half, and along the inner surface of the fibula, and

to the extent of more than 4 in. Bone otherwise quite healthy. 1847. *Dr. J. C. Warren.*

1476. The greater portion of the tibia, irregular towards the fibula, from the formation of numerous, small, defined, flat plates of hard bone. Probably a commencing ossification of the interosseous ligament; and so of the last specimen. 1847. *Dr. J. C. Warren.*

1477. A small growth of bone, projecting abruptly from the lower third of the tibia, about at the insertion of the interosseous ligament. 1847. *Dr. J. C. Warren.*

1478. Section of the sternum, showing a growth of compact new bone upon each surface, and to the extent of nearly an inch; not periosteal. 1847. *Dr. J. C. Warren.*

1479. Portion of the tibia sawed open, and showing a node just below the middle of the bone. In the cancellated structure of one section, that has been preserved in spirit, are seen three or four soft, whitish, crumbling, rounded, tubercular-looking deposits, of the size of small peas; and constituting the plastic deposit of tertiary syphilis, as described by Ricord in the bones, liver, and heart (*Clinique Iconographique de l'Hop. des Veneriens*). The lungs, in this case, were perfectly free from tubercles; and the other organs were healthy, excepting the liver, which was hard, granulated, of a dark yellowish or brownish red color, rather dry, and having a peculiar waxy, amyloid translucency. In two of the ribs, however, and in one of the clavicles, there was an opaque, curdy deposit, with caries, or something like it. For the history of the case see No. 1292, p. 226. 1852. *Dr. H. J. Bigelow.*

1480. The other half of the above, dried. The "node" is seen to be a new formation; the limits between it and the original bone being faintly traceable, and the structure rather less compact than that of the old bone. The periosteum, in the recent state, did not seem changed. 1852. *Dr. H. J. Bigelow.*

1481. Cranium, diseased; and marked "syphilitic." Heavy; and porous upon the surface, from the enlarged arterial foramina. No periosteal deposit. 1847. *Dr. J. C. Warren.*

1482. Sequestrum from the lower jaw, 2 in. long, and nearly an inch in width. Disease of several years' duration.— From a man who had tertiary syphilis, and died of the disease within a year after the removal of the sequestrum. 1856. *Dr. H. J. Bigelow.*

1483. A portion of the lower jaw, removed from the articulation to some way beyond the angle. In the ramus is a rounded cyst, nearly or quite half as large as the fist; thin, stiff, as if mostly membranous, and generally smooth and polished upon the inner surface, though in some parts rough as from a deposit of fibrin or some new formation. The coronoid process is lost in the disease, which is confined to the ramus; the bone being healthy where sawed across. 1847. *Dr. J. C. Warren.*

1484. A cyst, about $\frac{1}{2}$ in. in diameter, with very thick, and very dense fibro-cellular parietes; the cavity containing, in the recent state, a synovial-like fluid. Situated over the second phalanx of the middle finger, but not over the joint.

From a middle-aged woman. The tumor, which was of several years' duration, was painless, immovable, had an elastic hardness, and was regarded by Dr. B., before the removal, as enchondromatous, but afterward as a bursa, or something very much like it. 1860.

Dr. H. J. Bigelow.

1485. Myeloid disease of the head of the tibia; and a section having been made through the tumor, and into the bone below, the soft parts have been removed, and the investing bone dried.

From a man, twenty-six years of age. (Hospital, 87, 160.) Eighteen months previously he fell, and a tumor soon appeared over the inner part of the head of the bone; pain never severe nor sharp. An opening had been made not long before, as for an abscess; and at this part a circular fungus had formed, about 2 in. in diameter. The whole upper part of the leg, as far as the knee, was the seat of a very large, and strongly fluctuating tumor. Motions of the joint not impaired. The thigh was amputated; and the man did well for a time; he then got worse, started

for Montreal, and died in the cars. Dr. Ellis found the microscopic appearances of myeloid disease; but unfortunately no record was made of the gross appearances of the interior.

The head and upper part of the bone are distended into a large, rounded cavity, the parietes of which are generally thin, and in some parts destroyed. Inner surface rough and somewhat reticulated. The articular surface looks healthy, and the tibia below the tumor is perfectly so; the limits being remarkably defined.

In the Med. Soc.'s Cabinet is a perfectly similar specimen (No. 1282), in which the gross appearances of the interior were highly characteristic of myeloid disease, but no microscopic examination was made. The ischium is the bone affected.

See Mr. Gray's paper on Myeloid Tumors of Bone, with figures of the microscopical appearances, in the Med. Chir. Trans. Vol. xxxix. p. 121. 1863.

Dr. H. J. Bigelow.

1486. A model in plaster, of the femur, from a case of gelatiniform disease of the bone.

From a man, twenty-two years of age. In April he had inflammation about the left knee, and abscesses soon followed; gelatinous masses, of a reddish color, frequently escaping with the pus. He sank from pain and suppuration; and the limb was amputated in July. The stump did well, but he died with purpura, etc., in about seven weeks.

The periosteum around the lower half of the femur was thickened and granulated with the gelatiniform substance; and, where the tissues were most diseased, the thickness amounted to an inch and a half. Just above the condyles, posteriorly, the femur was largely perforated, as seen in the model; and the substance of the bone was found to be filled with the soft gelatiniform material. The knee-joint was healthy. 1858.

Dr. Alfred Hitchcock, of Fitchburg.

1487. Knee-joint; in spirit. The upper extremity of the tibia, to the extent of 3 in., is entirely destroyed; terminating in a rough, thin edge, and its place being occupied by a

coarse, ragged, fibro-cellular substance, but without any appearance of cancerous structure. The knee-joint and the femur appear healthy, and the cartilage remains in a pretty entire state. 1847. *Dr. J. C. Warren.*

1488. Metacarpal bone of the index finger, and the adjoining phalanx; in spirit. The first, sawed longitudinally, shows an enchondromatous deposit in the substance of the bone, just behind the anterior extremity, nearly half an inch in diameter, and rising somewhat above the surface. A similar but much smaller deposit projects above the dorsal surface of the phalanx, and close to its posterior articulating surface. These two bones are otherwise healthy, but upon one of the bones of the middle finger was a similar deposit. 1856. *Dr. R. M. Hodges.*

1489. A large epithelial, cancerous growth, from about the middle of the tibia.

From a man, æt. thirty-eight, who entered the hospital April 17th, 1838 (19, 19). About seventeen years previously he had fever; and boiling water was poured upon his legs to produce vesication. Extensive ulceration followed, and continued till 1837, when the left leg healed. In 1836 the right leg assumed a fungous appearance. In Jan., 1838, the growth was removed, and the bone scraped; but, on admission, it was larger than ever, very painful, occasionally bleeding, and exceedingly offensive. He had kept his bed for about two years, taken laudanum freely, and was greatly reduced in health. On the removal of the limb, below the knee, he lost a great deal of blood; and two weeks afterward the femoral artery was tied for secondary hemorrhage. July 14th he left, much improved.

The limb having been very fully injected with size and vermilion, the fungous growth assumed at once, and very nearly, the appearance that it had before the operation; as of a mass of exuberant granulations, 6 in. in length, 3 or 4 in width, and rising abruptly 2 in. or more above the surrounding surface, which was quite healthy. A section having been made through the limb, the growth was found to consist of a coarse, fibro-cellular structure; the fibres radiating toward the surface, from an opening in the tibia,

and being mixed with a more opaque and softer material, but without any marked encephaloid appearance. The bone and the periosteum appeared healthy, excepting the opening into the cavity, and which was about an inch in extent. The two sections were put directly into alcohol, so as to preserve the appearances, and one of them is in the Cabinet of the Soc. for Med. Improvement. (No. 286.) 1847.

Dr. J. C. Warren.

1490. A drawing, in water colors, by Dr. S., to show the external appearances, in what must have been an encephaloid disease of the femur.

The patient was a little girl, eleven years of age (Hospital, 70, 62), and the disease was of eight months' duration. Great constitutional affection, with much burning sensation. The limb, at the seat of the disease midway, was $19\frac{1}{2}$ in. larger than the other at the corresponding part; and the regular fusiform enlargement, with the dilatation of the cutaneous vessels, were highly characteristic of the above form of cancer. Date of the patient's death after leaving the hospital unknown. 1857.

Dr. Lucius M. Sargent.

1491. Thibert's model, showing a section of the parts in a case of very extensive cancerous disease of the femur and neighboring parts, with hemorrhage. The diseased mass weighed about 26 lbs. Amputation by Prof. Roux, and the patient lived for some days. 1847.

Dr. Geo. Hayward.

1492. Long. section of the upper third of the femur, and showing a complete encephaloid transformation of the bone, to the extent of some inches; and, being preserved in spirit, it bends by its own weight. When recent, it was opaque, with xanthoid formation, and the appearance of fatty degeneration. The tissues immediately around the bone were involved, but the head was not. The thigh only was examined, as there were no signs of internal disease.

From a woman, æt. seventy-two years, and subject to rheumatism. In December she complained of lameness of her hip; and on the 11th of February the thigh broke, as she was being turned in bed. This was followed by swell-

ing of the part, though no marked irregularity was seen in the bone, on dissection; and on the 20th of July she died. 1859. *Dr. Benj. Cushing, of Dorchester.*

1493. Cancerous disease of the femur, with fracture of the bone; commencing just above the condyles, and being most advanced about $5\frac{1}{2}$ in. above the joint. Periosteal deposit very abundant, and upon the surface very irregular; structure coarse. Fractured extremities irregular, and generally rough; but at one part, and where the bone probably finally broke, the appearance is like that of a recent fracture. To a considerable extent the parietes of the bone are quite gone; and in their place is a small sequestrum. Internal cavity of the upper fragment filled with an amorphous earthy deposit to the extent of about an inch.

From a man æt. forty-three years, who entered the hospital Oct. 29th (141, 242). Had been in the U. S. Navy, and was quite healthy, until about fifteen months ago, when, in S. America, he had intermittent fever, and about the same time began to have a pain beneath the right patella, shooting down the leg. The pain he attributed to passing shot on board the vessel. Last July he arrived in New York, and whilst he was in the Brooklyn Hospital there was discovered a very considerable swelling below the lower ribs upon the left side; and this he still has, though it is very much diminished. There had also been an occasional pain there since the first of his sickness, on taking cold. The thigh was broken when he entered the hospital; but he knew nothing of the accident, and said that he had walked up-stairs only a week before. There was free motion between the fragments; and at the seat of disease the limb was $2\frac{1}{2}$ in. larger than the other; there having been swelling for the last few weeks. There was, also, much pain there on motion, but there never had been any at any other time. Leg œdematous. Health much impaired; and he had done no work since the first of his sickness. Nov. 6th the thigh was amputated about $10\frac{1}{2}$ in. above the joint; and the wound is now (Dec. 7th) doing well.

In the recent state there was a whitish and not very soft,

but malignant-looking growth at the seat of disease; and to a considerable extent the periosteum could be traced over it. In bulk it was larger than the fist. 1869.

Dr. G. H. Gay.

1494. A second specimen, prepared by Dr. Thomas Dwight, Jr., and that contrasts remarkably with the last; the two cases having occurred at about the same time. In this one the disease is mainly upon the back part of the bone, extends longitudinally about 4 in., and laterally involves about one-half of the circumference of the bone. The surface to this extent is quite rough, but the structure looks firm, and there is very little loss of substance. Around this surface is a high wall of periosteal growth, and that is formed, to a considerable extent, of large, broad, thin, flattened laminae, and seeming to have stood off perpendicularly and regularly, like crystals, from the surface of the bone, and the cancerous growth that was formed upon it. The deposit beyond the seat of the disease is not extensive, as in the last case, nor at all thick and irregular; but looked rather like what is often seen as the result of simple inflammation. The whole circumference of the bone is affected; but, anteriorly, there is very much less of the deposit; and the disease is altogether much less marked than upon the back of the femur. Otherwise the bone is quite healthy.

The patient was a lad, about thirteen years of age, and the disease was developed very rapidly. Dr. C. V. Bemis, of Medford, states that he came to see him on the 7th or 8th of Sept.; that there was a little stiffness and tenderness of the muscles just above the knee, but no swelling. He had been riding a good deal upon a velocipede, but suggested no other cause for his disease. Three or four days afterward Dr. B. found swelling, with some pain; and from that time he regularly attended him. The swelling became hard, without any great amount of pain, and it appeared like a case of simple periostitis. There had been but little swelling of the integument, but about the 1st of October it increased, and all at once the hard swelling became soft and elastic, as from a yielding of the bone; the pain, meanwhile, having much increased. Oct. 7th the

limb was amputated by Dr. G. ; and the patient on the 8th of Dec. was recovering well from the operation.

In the recent state a large, soft, cancerous growth was found situated over the diseased portion of the bone, with bony particles scattered through it, and walled in by the periosteal deposit. (Died March 29th.) 1869. *Dr. G. H. Gay.*

1495. A cast, in plaster, of a large part of the lower extremity, in a case of cancer of the upper part of the tibia.

The patient, a young man, nineteen years of age, had pain, with some swelling, at the junction of the middle and upper third of the tibia, in March, 1849. This subsided in a few weeks, and in six months he had another attack. In January, 1850, a third attack; and from this time the swelling went on increasing; pain dull and heavy, and at last lancinating. His general health was good, until 1850, and he worked upon a farm. In 1852-3 his health failed; and in September, 1853, the thigh was amputated. The tumor was then 25 in. in circumference, irregularly hard and soft, and in some parts boggy to the feel; enlargement regular and fusiform. The patient was then exceedingly emaciated, and rapidly sinking.

On dissection of the tumor, it consisted of "bone, flesh, pus, and blood." Bone spongy, and lamellated throughout, and without any trace of its natural shape or structure. Fibula either involved, or partly absorbed by the pressure of the tumor.

The patient's father had his foot amputated, at the age of twenty-nine years, for disease of the bones of the foot, and the appearances were "precisely like" those in the present case. The grandfather also died, of cancer of the bones of the face, at the age of fifty-six years. 1858.

Dr. A. Hitchcock, of Fitchburg.

1496. Section of one of the ribs, showing a defined, rounded, encephaloid mass, about 2 in. in diameter, arising from the bone, and projecting upon the inner surface.

From a man, forty-five years of age, who died at the hospital (85, 138). Several of the ribs were diseased; and the sternum, the dura mater, and the liver, were affected with encephaloid. 1863. *Dr. C. Ellis.*

1497. Malignant disease of the clavicle; in spirit. A section has been made through the bone, and the diseased mass; and this last, which is about the size of two fists, resembles encephaloid, as it usually appears when thus prepared.

From a sufficiently healthy man, twenty-four years of age. (Hospital, 10, 358.) Disease of one year's duration. The clavicle was removed by Dr. W.; and, though the man did well at first, he fell off on the thirteenth day, and died during the fourth week from the time of the operation. Case reported and figured by Dr. W. in his work on Tumors, p. 146. 1847. *Dr. J. C. Warren.*

1498. Encephaloid disease of the lower extremity of the femur, forming a tumor, nearly or quite as large as a foetal head; the bone at this part being entirely destroyed. The articular cartilage, however, which remains, is nearly healthy, and detached to a considerable extent from the encephaloid mass. The knee-joint is for the most part quite healthy, as is the femur where it was sawed across, and also the head of the tibia. Specimen in spirit. 1847.

Dr. J. C. Warren.

1499. Long. section of the ulna, about which are formed two tumors, that are undoubtedly cancerous, though they did not present the characteristic appearances microscopically. One, just below the middle of the bone, was, in the recent state, 3 in. in length, and 2 in. in diameter; marbled, pearly white, with vascular points, some xanthoid, and one small bony deposit; not soft; surface of bone somewhat absorbed, though there was no morbid deposit in the interior. The second was about the lower extremity of the bone, and not far from the size of a horse-chestnut.

Removed, after death, from a man thirty-six years of age. Thirteen weeks previously he struck his elbow, and one of the tumors soon appeared. The lower one fluctuated so distinctly, that at one time it was about to be punctured. Pleurisy came on three weeks before death, and carried him off. On dissection, several pints of blood and serum were found in the right pleural cavity, and a soft, cancerous mass, of the size of the fist, hung from the

lower lobe of the lung, besides numerous deposits on the pleural surface. There was no disease, however, in any other part of the body. The above is from notes by Dr. Ellis. 1854. *Dr. H. J. Bigelow.*

The six following Thibert's models were given in 1847.

Dr. George Hayward.

1500-1. Disease of the horizontal branch of the lower jaw, with openings upon the surface, that communicated with the centre of the mass. Removed at the articulation; and some days afterward the patient died.

Section of the same, showing an encephaloid transformation of the bone, with cavities in the centre.

1502-5. Head, and upper part of the chest of a child, showing numerous, purplish tumors upon the head and face; connected with "fungus hematodes" of the dura mater.

Longitudinal section, showing the interior of the cranium, and from the same.

External and internal view of the same cranium.

1506. A portion of the cranium, from the temporal region, and showing the effects of a cancerous growth; a perforation equal to about $1\frac{1}{2}$ in. in diameter. A large growth of new bone from the outer surface of the sphenoid, a filling up of the cells of the bone, and a growth of short, bristly, bony fibres to some extent, perpendicular to the surface of the bone, and such as are so often seen in cases of cancer. The new bone is generally rather earthy in structure.

From a hospital patient, twenty-two years of age (75, 246). Pain in head began about three years before death, and there was gradually developed an increase of pain, throbbing in the left temple, protrusion of the left eye, with failure of vision, and finally an elastic, pulsating tumor in the temple; her general health being good. Dr. B. punctured the tumor; subsequently tied the common carotid, and ten days afterward, as the tumor threatened to burst, the other common carotid was tied. This last operation was followed by wakefulness, delirium, coma, hemiplegia, and on the fourth day by death. (No. 1748.)

On dissection, a defined and very soft encephaloid tumor

was found situated about equally within and without the cranium, and containing about four ounces of thick liquid blood; the brain remaining, after removal, permanently depressed. Dura mater healthy, and easily stripped off from the tumor. Hard, cancerous mass was also found in back of the orbit. 1858. *Dr. H. J. Bigelow.*

1507. Daguerreotype of the above patient. 1858.

Dr. H. J. Bigelow.

1508. Long. section of a femur, that was surrounded by encephaloid disease, and showing the changes that the bone had undergone; a dry preparation. In structure it is light and crumbling; the walls are thin, and upon the surface there is an abundant new growth in the form of acicular and laminated deposits.

From a little girl, thirteen years of age. Duration of the disease eight or ten months. There was a general and hard swelling of the whole thigh, with very severe pain; skin white, and subcutaneous veins enlarged. Three months before death an opening was made in the popliteal space; and her death was finally caused by erysipelas, and extensive sloughing about this part. The internal organs were healthy. 1857. *Dr. J. S. Jones.*

1509. Outer portion of the upper maxillary bone, with the malar; including the teeth from the second incisor to the second molar.

From a little girl, eleven years of age. (Hospital, 73, 158.) The disease began in March, and the tumor was removed, with the bone, Nov. 8th. The structure was grayish, semi-transparent, soft, and friable; and microscopically fibro-plastic, though partly encephaloid. She did well for a time, but died with thoracic symptoms Nov. 27th. 1858. *Dr. H. J. Bigelow.*

1510. Left upper maxilla, removed for encephaloid disease, of four months' duration.

From a woman, æt. fifty-five years. (Hospital, 75, 174.) The bone, in this case, as in the last, is diseased somewhat, but not, as is usually seen, in cases of cancer. 1859.

Dr. H. G. Clark.

1511. A peculiar form of disease of the cranium, connected

with a disease of the dura mater, that was probably malignant.

From a young man, *æt.* twenty, who applied to Dr. W. for exophthalmos of the left eye, on the 19th of June; vision then perfect, and no cause found for the disease. On the 5th of July he went out in the evening to see the fireworks, and from that time his disease progressed until his death, which occurred on the 8th of August. Discomfort about the eye, with great dimness of vision, followed the exposure; and on the 8th the ophthalmoscope showed haziness of "outline of disc, with slight hemorrhagic effusions near macula lutea;" the right eye being also somewhat affected. On the 10th there was some deafness upon the left side. The eye protruded so that it could not be covered by the lids; the hemorrhage greatly increased; the pain in the eye and head was such as to require morphine; and during the last week there was a wandering of the mind.

On dissection, by Dr. J. Homans, nothing was found in the orbit to explain the exophthalmos, but behind the left eye there was a rather soft growth from the dura mater, about the size of an English walnut. Toward the vertex the dura mater was very greatly thickened to the extent of 2 or 3 in.; and a vascular, flocculent growth upon the external surface penetrated the diseased bone. Otherwise the membrane was healthy, as was the brain. Externally there were also flattened morbid growths between the fascia and the pericranium, and that penetrated the bone. Microscopically, all of these growths presented appearances that much resembled those of malignant disease.

The calvaria, having been removed in the usual way, was found to be diseased throughout the greater part of its extent, internally and externally, but mostly upon the internal surface. A growth of bone arose from this last, in thin laminæ, from a line to a line and a half in height, compact in structure, of a pink color, and very finely convoluted so as to give a somewhat coralloid appearance; the disease being for the most part defined, and commencing with a roughness of the surface. There were also innumerable foramina, and many of them were quite large; but otherwise they resembled those usually seen in chronic

ostitis. There were, however, none of the usual appearances of inflammation; and, altogether, the bone was of about the usual thickness. Externally, the foramina extended as far as the soft parts were diseased; and they were large, but less numerous than upon the inner surface; there was also some roughness, as from inflammation. 1869.

Dr. Henry W. Williams.

1512. Calvaria, showing the effects of cancerous growths from the dura mater.

From a man, forty-six years of age, and of robust health. (Hospital, 224, 248.) Disease began in the sternum, in February; and subsequently a wen-like tumor appeared upon the head. Constitutional affection, but no cerebral symptoms. Aug. 22d one of two tumors over the sternum was opened; bled very freely, and a few days afterward the man died.

The preparation (by Dr. E.) shows an opening, half an inch in diameter, through the frontal bone; diploe considerably more affected than the tables, the edges of which last are delicate and irregular. Tables to some extent, from the opening, quite porous from the enlargement of the nutrient vessels; and beyond this, upon the inner surface, is a delicate, coral-like growth of new bone. In the parietal bone there is the same disease, though much less advanced, and scarcely showing, except upon the inner surface. There are also other little patches, cribriform upon the surface, and showing that the disease began in the diploe. The bone is otherwise quite healthy. The sternum, ribs, and liver were affected with encephaloid; and upon the dura mater, corresponding to the diseased bone, were two "quite soft, reddish, and somewhat laminated" growths. 1859.

Dr. C. Ellis.

1513. A portion of the right frontal bone, from a case of cancerous tumor of the dura mater. There is an irregular opening, about $1\frac{3}{4}$ in. in diameter; edges quite rough, and eroded upon the outer surface all around, to the extent of about $\frac{1}{2}$ in., but not at all upon the inner. No new bone thrown out, nor any other appearance of disease.

The patient was a lady, thirty-one years of age, and the tumor first appeared in March, 1865, preceded by a sting-

ing sensation. It was at first hard and immovable, but during the last few months softened in spots; skin not discolored; exquisitely sensitive to the touch, and with severe pain over the whole head. When first seen by Dr. C., in Oct., there was great intolerance of light, with contracted pupils, constant nausea, and vomiting of all food; but these last symptoms were relieved by diet. Dec. 3d, there was reported diarrhœa or constipation alternately; the dejections when loose being involuntary, and also the urine. Mind clear, but slow. Left pupil sluggish and slightly dilated. Jan. 15th, the tumor was about 3 in. in diameter, and projected about 2 in. Vision in left eye dim. Semi-conscious most of time. Feb. 9th, vision in left eye quite lost, and very dim in right; left pupil permanently dilated. Confined to bed, but sometimes quite bright. She afterward became totally blind, and died April 24th.

On dissection, the tumor, which was 2 or 3 in. in diameter, was decidedly cancerous in appearance, though not encephaloid; connected with and extended to the brain; feeling externally elastic rather than fleshy. Cancerous tumors were also found in the liver and lungs. 1866.

Dr. H. L. Chase, of Cambridge.

1514. Section of a rib and of a portion of the ilium that were affected with a very peculiar form of disease. The sternum and ribs would bend by their own weight; the bony matter having in some parts entirely disappeared, and been replaced in the interior by a soft reddish growth, which, forming in the interior, gradually approached the surface, and reduced the bone to a mere shell, or entirely destroyed it. The whole spine and the right ilium were similarly affected. Microscopically, a delicate fibrous structure was found, almost obscured by granular corpuscles of about the size of the nuclei of the renal epithelium, which they resembled very closely; the addition of acetic acid revealing nothing more.

Dr. E. supposed that a new material was formed in the bone, and that it was of a cancerous nature, though the disease was entirely limited to the bones. He has seen recorded but one similar case (Virchow's *Archiv.* Vol. **xxi.** p. 407).

The specimens here shown were from a man forty years of age, who had had severe pains in various parts of his body for several months, and that could never be explained. Gradually lost flesh, and died after a week's sickness of acute pneumonia. (See Med. Jour. Vol. LXVI. p. 67.) 1863. *Dr. C. Ellis.*

1515. The upper seven inches of the femur removed at the hip-joint. A dried specimen.

The patient was thirty-one years of age, and entered the hospital May 29th, 1868 (138, 35). Two years previously the thigh had been amputated for "osteosarcoma" of the leg. About five months before entrance the stump began to discharge and to feel heavy; and, on admission, the whole end formed a very large and hard tumor, that became smaller above, but seemed to involve the bone as far as the joint. The end was covered with small, red, rounded granulations, and feeling like bone covered by a very thin pellicle of skin. Health rather poor for the last three months. On the 2d of June the operation was performed; and, a tourniquet having been applied over the abdominal aorta, there was but little hemorrhage. Forty-eight vessels were tied, and the flaps required twenty-six sutures. August 1st he was doing well and left the hospital. After that time he improved rapidly, but in Nov. the cicatrix began to be troublesome, and in February the disease had evidently returned. In Dec., 1869, however, his brother states that he is in a fine state of general health, and without much, if any, increase of the local disease for some time.

On section, the morbid growth is seen to be of a rounded, mushroom-like form, and completely surrounds and overhangs the end of the bone; regular and comparatively smooth upon the surface, excepting the granulations at the extremity, but somewhat laminated, as appears upon section, and exceedingly irregular where it looks toward the head of the bone. In structure, it consists almost entirely of a pretty compact bone. The disease extends along the surface of the bone to within about an inch of the intertrochanteric line, in one direction; and the bone itself, where not involved, looks quite healthy. 1868.

Dr. R. M. Hodges.

1516. Photograph of the above patient before he left the hospital. 1869. *Dr. R. M. Hodges.*

1517. Long. section of a portion of the femur, showing a large cancerous tumor investing the bone ; in spirit.

From a lad, sixteen years of age. (Hospital 80, 219, and Med. Jour. Vol. LX. p. 329.) An immovable and slightly painful tumor was first noticed seven months before entrance, and increased slowly. When seen, the thigh was flexed, and the upper half occupied by a firm and painful tumor, which was distinct and somewhat nodulated in front, and in contact with Poupart's ligament ; indefinite behind ; the circumference being 7 in. greater than that of its mate. There was some motion in the joint, and the lad, though very lame, could walk with support. Amputated at the hip-joint, March 28th, 1859, and the artery having been first tied, and the aorta being compressed, scarcely any blood was lost. Secondary hemorrhage occurred on the twenty-fourth day, but the patient rallied from the effects of it, and was discharged well on the 10th of May. He died, however, some months afterward, with pain in his back ; and nothing more is known of the final result.

The diseased growth surrounded the bone, arose from its surface, and extended from the middle of the shaft to the neck ; being cancerous in its general appearance, and also microscopically. In structure there were some spiculae of bone, but it consisted mainly of a firm, coarse, fleshy substance. Parietes of the bone somewhat thickened midway, and the central cavity mostly obliterated ; but otherwise there was nothing remarkable. 1861.

Dr. J. M. Warren.

1518. Long. section of the upper half of the femur, which was surrounded by a cancerous growth ; in spirit.

From a man, thirty-nine years of age. Entered the hospital April 3d, 1858 (78, 48). Struck the thigh about thirteen months previously, and about ten months before admission, pain came on with hardness, and subsequently some external inflammation ; pain at last excruciating, with constitutional affection. On the 17th a piece of the tumor was removed, and found microscopically, by Dr. Ellis, to

be partly fibro-plastic and partly cancerous. Death on the 27th.

The tumor, which was 8 inches in length and about 5 in. in diameter, was lobulated externally, firm, and consisted of a yellowish-white, coarse, fibrous structure with some cretaceous deposit and infiltrated with a glairy fluid. The fibres stood off perpendicularly from the surface of the bone, which was quite rough, with some absorption; and the interior was filled with a very dense ossific matter as far as the tumor extended. Microscopically, "nothing was noticed," by Dr. Ellis, "but a fibroid material containing globules like those of fat." 1858.

Dr. J. M. Warren.

1519. Long. section of the lower half of the femur, and showing a cancerous growth connected with the back part of the bone; in spirit.

From a lad, fifteen years of age. (Hospital, 78, 196.) The disease was of three months' duration, and began with swelling and moderate pain. Whole popliteal space filled with the diseased growth, and amputated at once.

The tumor was 4 in. in extent, and adhered to the bone throughout; structure fleshy, and microscopically cancerous; cavity adjoining the bone, and where the disease is most advanced. Bone soft and gradually merged in the tumor, which is supposed to have arisen from it. At the hospital is a colored drawing of the recent specimen. 1850.

Dr. S. D. Townsend.

1520. A drawing in water-colors, showing the appearances, on a recent section, of a case of osteoid cancer of the upper part of the tibia.

The patient, a delicate little girl, eleven years of age, was kicked on the shin by a schoolmate seven months before entrance into the hospital (74, 178). In four days pain and swelling came on, and increased daily. The pain was constant, deep, generally dull, and often severe. Amputation 3 in. above the condyles; bone diseased, and for some time the stump did not do well. She remained in the hospital for some weeks; and, meanwhile, a tumor, of the size of a hen's egg, formed about the sternal end of the clavicle.

After she left, all that is known of her case is that she lost the sight of her left eye.

The upper half of the bone was enlarged, increasing from below upward, and measuring $3\frac{1}{2}$ in. across the cut surface at the largest part. Structure almost entirely osseous, but with some mixture of a coarse fibroid substance. No unusual vascularity, nor other appearance of inflammation. Neither were there any of the usual appearances of cancer, though the microscope left little if any doubt of the nature of the disease. See the two next specimens. 1857.

Museum Fund.

1521. One-half of the above tibia thoroughly macerated and dried; and showing how very large a portion of the tumor is osseous. The new growth which had formed about the bone is light and fragile, so that several small portions were lost in the preparation; somewhat lobulated upon the external surface in some parts, and very slightly radiated in some others upon the cut surface. The outline of the original bone is distinctly traceable through the tumor; not enlarged, but the walls are for the most part light and earthy; and the cavity is filled up with the morbid osseous growth to the extent of 2 in. below where the disease begins externally, as appears in the next specimen. 1857.

Dr. S. D. Townsend.

1522. The other half of the above tibia, macerated for a few days in water, then in spirit, and then dried; seeming to consist almost wholly of bony matter. An irregular cavity is seen in the centre of the tumor. The fibula is healthy; as is also the cartilage on the head of the tibia. 1857.

Dr. S. D. Townsend.

1523. Osteoid cancer of the bones of the forearm. A longitudinal section having been made through the tumor, and to some extent through the healthy bones above it, one-half has been macerated, dried, and separately mounted; and the other half (No. 1524) has been preserved in spirit. The tumor began at the lower extremity of the bones, extends upward about 4 in., and was nearly half as large again as the first. The form was rather oval, and the surface smooth, but deeply grooved by the tendons. The sur-

rounding parts, being quite healthy, have been removed. The structure is mainly osseous, light, brittle, and fibrous; many parts externally suggesting the idea of some kind of coral or of sponge; some of the spiculæ being very delicate. Nowhere foliated, compact, nor at all pulverulent. The fleshy portion of the tumor consisted of a white, dense, fibrous tissue. The two bones were firmly connected by the morbid growth; the outline of the ulna being throughout sufficiently distinct; and the very lower extremity quite healthy. The radius, in which the disease seems to have commenced, is traceable to a considerable extent, but below this it is quite lost in the tumor; the bones not being enlarged so far as they are traced, and their cavities being obliterated so far as the tumor extends. In the present dried specimen a large section has been made near the surface, to show the structure, and some fragments are seen that were detached by maceration. A piece is also seen of the size of a large nutmeg, but of a flattened, oval form, and that in the recent state was entirely distinct from the main tumor, though in close apposition with it; this piece being movable as a distinct mass, before the amputation.

From a healthy young lady, twenty-four years of age. In 1857 she sprained her wrist. Six or eight weeks afterward a tumor appeared on the radius, and slowly increased; and subsequently others on the ulna. In 1860-1 portions were removed at three different times. In April, '62, when she entered the hospital (101, 174), the tumor was 12 in. in circumference, having doubled in size the previous year; regarded beyond question as enchondroma, from its somewhat knobbed form and densely elastic feel. The limb was amputated 4 in. below the elbow, on the 12th, and she was discharged May 12th. At the end of a year or more there was no return of the disease. 1863.

Dr. H. J. Bigelow.

1524. The other half of the above; in spirit. 1863.

Dr. H. J. Bigelow.

1525. Portion of the calvaria, showing the effects of an old burn, and of an epithelial cancerous growth from the dura mater. (Series XXIII.) 1861.

Dr. J. H. Warren, of Dorchester.

1526. Remains of the lower jaw, from a case of epithelial cancer in a middle-aged man. The disease began in the lip, which was removed, and it subsequently reappeared about the lower jaw; a very large cavity opening externally, and from which fatal hemorrhage at last occurred.

From the dissecting-room; and, having been injected, the arteries about the seat of disease were found obliterated. Upon the right side a portion of the ramus remains, but otherwise it is destroyed nearly to the median line. Upon the other side the structure of the bone is light where it terminated in the disease; but there is very little deposit upon the surface, and none of the delicate spiculæ so often seen in encephaloid disease. 1858.

Dr. R. M. Hodges.

1527. Effect of a cancerous tumor developed in the ramus of the lower jaw. The preparation consists of a quantity of loose, dry, white, crumbling bone; the head and condyloid process in connection, and looking as if they might be rubbed down between the thumb and finger. The bone is sound where it was cut through, but the ramus and neighborhood of the angle are quite destroyed.

From a man thirty years of age. Tumor over the ramus, of the size of a hen's egg, hard, tense, and inflamed. Removed at the articulation. 1858.

Dr. H. J. Bigelow.

1528. Thibert's model. "Osteo-sarcoma" of upper jaw. Removed from a young man, seventeen years of age; perfectly relieved, but died a month afterward from pneumonia. Teeth separated from each other, and scattered over the tumor. "Tumor formed mostly by a hypertrophy of the upper maxillary bone, without softening." External appearances shown.

1529. The above tumor after removal. 1847.

Dr. Geo. Hayward.

1530. Humerus, showing a roughness with some absorption for some distance above the inner condyle; the result of its connection with a large cancerous tumor. The bone is otherwise sound. 1858.

Dr. H. J. Bigelow.

1531. Lower half of the femur, showing a cancerous growth just above but partially involving the condyles; nearly as large as the two fists, and situated mostly about the inner condyle, but investing the whole bone more or less. In structure it consists mainly of an earthy, crumbling substance. A dried preparation. 1847. *Dr. J. C. Warren.*

1532. One-half of the lower jaw of an animal (Bos) showing an extensive destruction of the alveolar portion, as from some malignant disease; elsewhere healthy. 1853.

Dr. Henry Bryant.

1533. A defined tumor, as large as a foetal head, that seems to have originated from the upper bone of the sternum; structure very coarsely granular, but not distinctly encephaloid. Very little, if any, of the upper bone remains; but the clavicles and first ribs, which are preserved, appear to be healthy. In spirit. 1847. *Dr. J. C. Warren.*

1534. Malignant disease about the knee-joint. The femur and tibia are almost entirely destroyed to the extent, each, of about 3 in.; but otherwise there is no appearance of disease of these bones. The articular cartilages remain, and are somewhat adherent. In the soft parts, outside of the bones, there is anteriorly and laterally a very large cavity, the inner surface of which has a most remarkably fibrous and reticulated appearance. Directly behind the joint, and connected with it only by the soft parts, is a defined tumor nearly as large as the fist, and that, having been sawed open, seems to consist about equally and uniformly of soft substance and earthy matter. 1847.

Dr. J. C. Warren.

1535. Adult skull; calvaria very thin, but sufficiently compact. 1867. *Dr. Francis Dana.*

1536. Lower portion of an adult cranium. Orbital portion of the frontal bone upon each side very thin and somewhat perforated. Structure compact. 1847. *Dr. J. C. Warren.*

1537. A plaster cast of the skull of an old negro, showing a broad, deep, and symmetrical depression upon each side between the parietal protuberances and the vertex. There is also a remarkable flattening in the temporal regions. The structure was very light and spongy; and, at the de-

pressed portion, the tables having nothing between them, and being themselves very thin, light was readily transmitted. Dr. W. has met with this form of atrophy in three other cases, and does not think it due to the action of the tendon of the occipito-frontalis muscle, as some have supposed.

Cases are also referred to by Mr. Humphry in his work on the Skeleton (p. 142).

The rounded form of the external nasal opening in this case was remarked upon by Dr. W., as showing well one of the characteristics of the negro skull. 1848.

Dr. J. Wyman.

1538. Cast of a "Calvarium, from Wenzel's collection, Frankfurt;" showing the same change as the last. From the Phrenological collection. *Dr. J. C. Warren.*

1539. Parietal bone very thin, and of a light, earthy structure. 1847. *Dr. J. C. Warren.*

1540. Several ribs much atrophied, and several of them ankylosed to a small extent.

Several fractures are also seen, which are very imperfectly if at all united; no new bone being thrown out about them. 1847. *Dr. J. C. Warren.*

1541. Upper portion of an adult humerus sawed lengthwise; a very fine specimen of interstitial atrophy. The walls are very thin; and the bony fibres within, so far as they extend, very delicate and peculiarly arranged. 1859.

1542. The os innominatum, femur, tibia, and fibula of a young adult, preserved in connection. The bones are sufficiently long, but so remarkably light and slender, smooth and rounded, as to suggest the idea of the bones of a bird; the roughnesses that characterize the muscular attachments being scarcely seen. On section, the walls of the femur are extremely thin, though compact; and within the bone is almost entirely hollow, as in a bird. 1847.

Dr. J. C. Warren.

1543. Tarsal bones of full size, but extremely light, as they not unfrequently are in cases of disease of the knee-joint,

and when the limb has been for a long time kept perfectly at rest. No appearance of disease. 1847.

Dr. J. C. Warren.

For other cases of atrophy, see hydrocephalus, rickets, chronic arthritis, bones after amputation, etc.

1544. Articulated skeleton of an adult female, showing the effects of rickets. From Europe.

Pelvis and long bones of the lower extremities very greatly deformed; the position of the sacrum being horizontal; and the broad, thin, sickle-shaped form of the fibulæ very characteristic. Strong lateral curvature of the spine. Head, upper extremities, and feet well formed; and the thorax very nearly so. Structure of the bones perfectly healthy. 1857.

Museum Fund.

1545. A second skeleton, greatly deformed.

Dr. W. reported, in the *Med. Jour.* Vol. xxvi. p. 171, of this case as follows: "The subject of this skeleton was an Indian, one of the Six Nations, and died at the age of twenty-one. His mode of locomotion was by a large wooden bowl, in which he sat and moved forward, by advancing first one side of the bowl and then the other, by means of his hands. He was very unhealthy, and had the characteristics of a rickety subject. I always considered the adventitious joints as the result of imperfect ossification; or, in other words, of motion before ossification was completed."

The long bones of all of the extremities are very greatly distorted, and the pelvis still more so. Spine sufficiently well; and also the head, except that the loss of the teeth gives the appearance of advanced age. The whole skeleton, excepting the head, is more or less atrophied, or deficient in earthy matter; and many of the bones, when soaked in water for preparation, were very soft. The "adventitious joints" are very numerous in the long bones and ribs, and present the usual appearances of partial fracture in a young bone, — nodosity, without displacement.

In the original preparation the muscles were preserved; but some years ago they were removed, and most of the skeleton was articulated by Dr. N. B. Shurtleff. 1847.

Dr. J. C. Warren.

1546. A portion of the spine, showing a very marked lateral curvature; the line of the spinous processes being straight, as compared with that of the bodies of the vertebræ. From a girl, eighteen years of age, who died of phthisis and had had the spinal affection for six or seven years. 1866.

Dr. J. S. Jones.

1547. The dorsal vertebræ, with portions of the ribs, showing an extreme lateral curvature.

From a man, æt. twenty-four, who died of disease of the heart. (Hospital, 228, 36.) 1860. *Dr. C. Ellis.*

1548. Eight dorsal and three lumbar vertebræ, preserved in their natural connection, and so sharply curved at the ninth dorsal, that the spine seems almost doubled upon itself; the ninth dorsal being only one-fourth of an inch in thickness upon the concave side. The processes and laminae of four of the vertebræ are co-ossified; and the structure of the bone is very light as from interstitial atrophy. 1847.

Dr. J. C. Warren.

1549. A second and similar specimen, but in which the curvature is very much less marked; six dorsal and three lumbar vertebræ preserved. The line of the spinous processes is much straighter than that of the bodies. Structure as in the above case. 1847.

Dr. J. C. Warren.

For the external appearances in case of lateral curvature, see next series.

1550. The whole spine, as low as the sacrum, with the thorax. Curvature of spine both lateral and backward. Great lateral compression of thorax, with projection anteriorly; but this must be more or less due to the preparation,—the ribs being very much atrophied and yielding. 1847.

Dr. J. C. Warren.

The three following specimens have been described and figured by Dr. J. Wyman, in his "Observations on Crania,"—1868.

1551. A deformed cranium, "from a somewhat aged subject. The sagittal suture is wholly, and the coronal, lambdoidal, and squamous sutures are partially closed. The index of the foramen magnum is 43.9, showing that the head has been lengthened forward more than backward." The long.

diameter of the cranium, according to Dr. W.'s method of measurement, being considered 100, 43.9 represents the distance from the anterior edge of the foramen magnum to the most projecting part of the occiput. In the crania of twenty whites, Dr. W. found the mean index of the foramen magnum to be 45.6. "A third articular surface exists in the middle of the fore edge of the foramen magnum, and corresponds with the apex of the odontoid process of the axis. It is a smooth, oval depression, with slightly raised borders, and has the appearance of having been covered with an articular cartilage; it is supported by a very slight elevation of bone, as in the cases of *condylus tertius*, described by Dr. Halbertsma. When viewed from behind, this cranium is remarkable for the manner in which the lateral walls slope toward the vertex." 1847.

Dr. J. C. Warren.

1552. A second specimen. "Supposed to be from a subject about three years old. The sagittal suture is wholly obliterated; the median ridge and the vascular openings, with a peculiar radiated appearance, as also the appearance of a median centre of ossification, exist here in a marked degree. This cranium is remarkable for its great length; the index of breadth being only 62.6. The foramen magnum is central; the increase in length having taken place equally forwards and backwards. This also appears from the equal protuberance of both forehead and occiput. The occipital region presents outwardly, as it were, a cast of the cerebellum; two bulgings, corresponding with the lateral lobes, project downwards beyond the tips of the mastoid processes. The hinder lobes of the cerebrum can also be traced in a similar way, and form a third bulging in the outer surface of the occiput." 1847.

Dr. J. C. Warren.

1553. A third specimen. Cranium of a fœtus, in which the deformity from elongation of the head was, in the recent state, very strongly marked.

"The lengthening of the head is almost wholly forwards; the index of the foramen magnum being only 32.2. The anterior fontanelle is largely open, and is prolonged between the frontals, by a space with parallel sides, twenty

millimeters in breadth, extending nearly to the nasals. The sagittal suture is completely obliterated in the middle portion, for the space of nearly an inch; for the rest of its extent it is open, the two parietals approaching each other quite closely; in the fore part the edges are smooth and straight, and in the hinder somewhat serrated, but do not touch. The frontals are very protuberant, and on the inside of each, corresponding very nearly with the frontal eminences, are two marked depressions, causing the bone to appear diaphanous in some parts; but, in others, extending quite through; each of these is surrounded by a ridge of dense bone, quite unusual in a fœtal cranium. These deformities may be compared to the digital impressions of the adult crania." 1867.

1554. A fourth skull; deformed, but less so than the above.

1555. A fifth; cast in plaster.

1556. A sixth; elongated and depressed; cast in plaster.

1557. A seventh; from Paris. Very remarkable distortion posteriorly; the left side being protuberant.

1558. An eighth; a Cretin, from the Haut-valais. Low; large posteriorly, and bulging upon each side of the median line just behind the vertex.

1559. A ninth; very marked protrusion of the upper half of the occiput. Ossa Wormiana very numerous along the lambdoidal suture, and the serrations strongly marked.

All of the above were given in 1847.

Dr. J. C. Warren.

1560. A tenth; very similar to the last, with many quite small Wormian bones. 1858.

Dr. R. M. Hodges.

1561. Occiput, very protuberant. 1847.

Dr. J. C. Warren.

1562. Portion of a skull, showing a very marked obliquity posteriorly. 1856.

Dr. H. J. Bigelow.

1563. Cast of the head of Bentegosse, a banker; flattened laterally.

1564-6. Casts of deformed skulls.

These last four are from the Phrenological collection.
1847. *Dr. J. C. Warren.*

1567-72. Models of deformed pelves; and of which the originals are in the Dupuytren Museum, at Paris. 1857.

Museum Fund.

1573. Distorted pelvis, from an adult female. Left sacro-iliac synchondrosis anchylosed. Skeleton otherwise sufficiently well, so far as observed. 1856. *Dr. R. M. Hodges.*

1574. Lateral distortion of the pelvis, with partial anchylosis upon each side, between the sacrum and ilium. 1860.

Dr. R. M. Hodges.

1575. One-half of the thorax, to show the effects of a former and extensive pleurisy; contraction and deformity of the ribs. These last, midway, are closely approximated and flattened from above downward. 1868. *Dr. C. Ellis.*

1576. Longitudinal section of the humerus and femur of a little girl, who died from the effects of rickets, at the age of ten and a half years; in spirit. — When sixteen months old, one elbow enlarged; and soon afterward she had ophthalmia, which resulted in total blindness. At the age of two and of four years, the ankle and knee joints enlarged; and from this last period she was confined to her bed; the lower extremities being drawn up upon the abdomen, and the upper extremities distorted. There were occasionally slight spasms lasting through the day; sometimes intense pain; a gradual loss of muscular power, and during the last month much dyspnoea. Mind quite bright.

On dissection, there was found strong lateral curvature of the spine. Shafts of all of the long bones, so far as examined, very slender and thin, and the epiphyses greatly enlarged; or, at least, by comparison. Muscles generally in a state of fatty degeneration. One kidney contained some small calculi; but the organs otherwise were sufficiently healthy. 1859. *Dr. C. D. Homans.*

1577. A femur, flattened laterally, and curved anteriorly. Transverse section midway.

1578. Tibia flattened laterally, and misshapen.

1579. Two tibiae, apparently mates, and somewhat distorted laterally.

1580. Tibia; inward curvature more than in the two last cases.

1581. A specimen, very similar to the last.

These last were from adult subjects. 1847.

Dr. J. C. Warren.

1582. Tibia of an adult, compressed laterally, curved antero-posteriorly, and very dense and heavy. Sawed lengthwise by Dr. H.; walls generally much thickened, and particularly along the concavity. 1860. *Dr. R. M. Hodges.*

1583. The scapula, humerus, radius and ulna, femur, tibia and fibula, from a young civette. Light from atrophy; and most of the bones much curved as from rickets; but otherwise healthy in appearance. There is an old fracture of the femur, regularly united; and the other femur, which Dr. W. has with the other bones, had also been fractured. 1858.

Dr. J. Wyman.

1584. A portion of the skull of an edentulous old woman, showing a large and defined depression, corresponding to the situation of the lachrymal sac, which was about as large as a marble. The contents of the sac were ropy, and somewhat brownish; and the duct was quite closed near the opening, into the nostrils. 1858.

Dr. R. M. Hodges.

1585. A portion of the skull, showing deep pits, in which were lodged the Pacchionian bodies; one of them almost amounting to a perforation. — From a man, forty years of age. 1855.

Dr. C. Ellis.

1586. Three ribs compressed into close apposition, and to a considerable extent flattened vertically; the result, undoubtedly, of a former pleurisy, though no reference was made to this disease.

From a man, æt. twenty-three, who died at the hospital of renal disease (222, 230). General appearance sufficiently healthy. Over the left lung were universal and strong adhesions; the fifth, sixth, and seventh ribs are here shown, with an extensive cretaceous deposit upon the inner surface. Posteriorly in the false membrane there was a soft curdy substance; and a few tubercles were found in the apices of the lungs.

The ribs and cretaceous matter have been dried in connection. 1859.

Dr. C. Ellis.

1587. About 2 in. of the tibia and a portion of the fibula removed from a stump nine months after amputation. Bones rounded at the end; sawed open, and look healthy; end of tibia closed.

From a woman, æt. fifty years; the stump had been troublesome for six months. (Hospital, 81, 129.) 1859.

Dr. H. J. Bigelow.

1588. The same, showing the rounding of the bones twenty weeks after amputation. (Hospital, 95, 116.) 1861.

Dr. H. J. Bigelow.

1589. About 2½ in. of the tibia and fibula, removed by Dr. B. The patient was a man, twenty-three years of age, who had had his leg amputated during the Civil War. The stump did not heal for a long time, was very painful, and he had never been able to wear an artificial leg. Feb. 12th, 1868, he entered the hospital (134, 180), with much pain at the end of the stump, and a firm attachment of the cicatrix to the ends of the bones at that part. On pressure between the ends of the bones, the limb was instantly thrown into violent convulsions. A year previously a sequestrum had been removed. On the day of his admission the bones were removed, and on the 11th of March the man was discharged well. The tibia is enlarged, and, besides the usual appearances of chronic inflammation, shows upon the inner surface a considerable cavity that must have contained the sequestrum. The two bones are ankylosed at the lower extremities. Prepared by Mr. B. B. Kent, one of the house-pupils. 1869.

Dr. H. J. Bigelow.

1590. The same, one and three-quarter years after amputation, and prepared by Mr. J. L. Hale, Jr., one of the house-pupils. The bones are small and firmly ankylosed at the rounded extremity. (Hospital, 131, 144.) 1867.

Dr. H. J. Bigelow.

1591. Upper 3 in. of the tibia, with the fibula, after amputation. Ends rounded. 1868.

1592. The same, five and a half months after amputation of the leg for a wound.

From a soldier, æt. twenty-five years. (Hospital, 112,

- 212.) Stump in a bad condition, and removed very near to knee-joint. Sloughing, suppuration, and ulceration followed, and the man was discharged for the benefit of the country air. 1864. *Dr. R. M. Hodges.*
1593. Bones of the leg, one and three-quarter years after amputation an inch above the ankle-joint, for injury of the foot. Re-amputated for disease about the stump. The bones are quite healthy, though united strongly at the lower extremity. (Hospital, 131, 144.) 1868. *Dr. H. J. Bigelow.*
1594. Small portion of the femur, showing the rounding of the bone eleven months after amputation. (Hospital, 84, 23.) 1861. *Dr. S. D. Townsend.*
1595. The same; nine months after amputation just below the small trochanter; well cicatrized, but with some new growth of bone.
From a man, æt. forty, who had had cancer about the sciatic nerve, and died of the same disease internally. (Hospital, 122, 108.) 1867. *Dr. R. M. Hodges.*
1596. The same; portion of femur from a N. A. Indian. The bone is not atrophied, and the very extremity is remarkably smooth and rounded, though there is some new growth about the margin. 1867. *Dr. Sidney H. Carney.*
1597. Cast of a long. section of the femur, and showing inflammation with periosteal deposit.
From a soldier, who was wounded June 16th, 1864, had his limb amputated on the 20th, and died Dec. 6th. Military Hospital, at Albany, N. Y. 1860. *Dr. G. H. Lyman.*
1598. Portion of the tibia, 2 in. in length, and that may have been removed from a stump. It ends in a blunt point, and is sufficiently healthy. 1847. *Dr. J. C. Warren.*
1599. A small portion of the femur, in spirit, and evidently from an amputated stump. The bone looks healthy; but granulations are seen springing from the medullary cavity. 1847. *Dr. J. C. Warren.*
1600. A small portion of bone, pretty evidently sawed off from the rounded extremity of an amputated stump. The origi-

nal bone is surrounded by, and closely connected with, a recent periosteal deposit; the first is thin and compact, and the second, by contrast, light in structure and quite thick. 1847. *Dr. J. C. Warren.*

1601. A transverse section from the extremity of an amputated femur. The original bone is thin, rough upon the surface, as usual in sequestra, and shows at the extremity the smooth cut of the saw. Loosely surrounding this is a thick, coarse, and almost earthy-looking periosteal deposit. 1847. *Dr. J. C. Warren.*

1602. Exfoliation from the femur, after amputation, 6 in. in length and rough upon the surface, but involving almost throughout the entire circumference of the bone.

From a man who entered the hospital (33, 162), Nov. 27th, 1847, with a recent wound of the femoral artery, and for which the vessel was tied by Dr. H., Dec. 18th. Mortification soon followed, and the limb was amputated by Dr. Parkman on the 10th of Jan. On the 20th the end of the bone was exposed, and the following June it had become loose; the whole stump being enlarged and indurated as by a new osseous deposit around the sequestrum. This last was removed on the 22d of June, and considerable force was required. August 5th, 1848, the stump was doing well, and the man was discharged.

This specimen and the two last form, together, an interesting series, as showing the progress of exfoliation from an amputated stump. 1848. *Dr. Geo. Hayward.*

1603. Upper two-thirds of the femur, removed after death, and about seven weeks after amputation. (See No. 1439.) The stump healed rapidly and thoroughly, except at one point, from which a discharge was almost constant until death. On dissection, the periosteum was found inflamed, and the cavity of the bone closed at its extremity by a soft substance. Artery plugged up to the extent of 4 in.; and the sciatic nerve was larger than usual, but not bulging where divided. In the prepared specimen, a small exfoliation is seen to be going on from the end of the bone; and the surface of this last shows the effects of inflammation. 1852. *Dr. S. D. Townsend.*

1604. A portion of femur, $3\frac{1}{2}$ in. in length, removed from a stump, and showing the effects of inflammation; enlarged, rough upon the surface, and with a sinus in its substance, containing a delicate sequestrum.

From a man, æt. twenty-five, whose limb was amputated by Dr. H. J. Bigelow, for disease of the knee-joint, Nov. 12th, 1864. A flap was taken in front, and a direct cut made down upon the bone behind; the periosteum was then scraped up; and, after sawing the bone, it was brought down and secured by a suture; after which the anterior flap was brought down. The stump never healed, and the end of the bone came away, with, occasionally, smaller pieces. On readmission into the hospital (127, 224), the bone was enlarged and very prominent; the soft parts being closely attached, and the whole very tender. Amputated by Dr. H., Dec. 8th, 1866, and the man was discharged well Jan. 11th. 1867. *Dr. R. M. Hodges.*

1605. Inflamed bone from a stump; and a very fine specimen.

From a soldier, æt. twenty-three, whose thigh was amputated July 21st, 1866, for a recent injury. The wound never healed, and he entered the hospital June 15th, 1867 (132, 102), very much exhausted, with swelling of the stump; protrusion of the bone, and a copious and very offensive discharge. July 17th, about $2\frac{1}{2}$ in. of the bone were removed, and on the 19th of August the man was discharged well.

The bone is very much enlarged, and shows the result of chronic inflammation. By the side of it is a pretty thick semi-cylindrical sequestrum, from the cavity of the bone, 5 in. in length, and that was sawed across midway at the time of the operation. 1867. *Dr. R. M. Hodges.*

1606. Exfoliation $3\frac{3}{4}$ in. in length, from the end of a stump; four and a half months after amputation of the femur, for a railroad accident.

From a man, æt. thirty-two years (Hospital, 85, 220); discharged well in about six months. Whole circumference of bone involved inferiorly. 1860.

Dr. H. J. Bigelow.

1607. About 2 in. of the femur removed from an amputated stump.

From a healthy man, æt. forty-two. (Hospital, 39, 80.) Thigh amputated for necrosis, May 30th. Extensive suppuration followed; and, after a time, about 2 in. of bone were discharged, including the entire circumference where it had been sawed. (No. 1608.) July 21st, the end of the bone was removed; surrounded by a thick mass of fleshy vegetations. The patient, having previously been much reduced, recovered rapidly after the operation. 1849.

Dr. J. M. Warren.

1608. Exfoliation from the above case. 1849.

Dr. J. M. Warren.

1609. Longitudinal section of a portion of the femur after amputation; dried.

From a boy, æt. thirteen years. (Hospital 118, 224, and Med. Jour. Vol. LXXIII. 218.) A horse-railroad accident. Amputated at once; and there was profuse hemorrhage from the medulla. On the 9th day a portion of the stump was ununited; and a large fungous growth, protruding from the medullary cavity, was removed. On the 13th day tetanus came on, and on the 18th the boy died.

A very exuberant growth of new bone surrounds the femur about a third of an inch above where it was sawed; and above this, to the extent of about 3 in., is a thin periosteal deposit. The very extremity of the bone is smooth externally, and was preparing to exfoliate. The medulla, so far as the bone was removed, was of a dark chocolate color, infiltrated with lymph so as to render it firm and resistant; filling the medullary cavity tightly as if swollen, and bulging out from the end of the bone in the form of a flattened button. No pus was anywhere found.

Dr. H. remarked upon the hemorrhage from the medulla, the late period at which the tetanus appeared, and their pathological connection with the osteo-myelitis; referring to Dr. Allen's paper upon this last subject in the *American Journal of the Med. Sciences*, Jan., 1865.

1610. The other half of the femur, from the above case; in spirit. 1865.

Dr. R. M. Hodges.

1611. Portions of the tibia and fibula, from an old stump, and

affected with chronic osteitis. Structure light; surface very rough; cavity obliterated; ends rounded, and from the fibula there had probably been a sequestrum discharged. 1847. *Dr. J. C. Warren.*

1612. Portion of the femur from a stump eleven and a half weeks after amputation. The extremity is closed, and there is a considerable growth of new bone about it. (See No. 1426.) 1864. *Dr. R. M. Hodges.*

Encysted disease of the ramus of the lower jaw, and nearly or quite half as large as the fist; in spirit. The parietes look thin and stiff, as if mostly membranous. The inner surface, which is pretty fully exposed, looks generally smooth and polished, though in some parts rough as from a deposit of fibrine. Removed from the articulation to some way beyond the angle. 1847. See No. 1483.

Dr. J. C. Warren.

For a case of dropsy of the antrum, connected with a misplaced tooth. (See No. 577.)

SERIES XXI.—SOFT PARTS CONNECTED WITH THE BONES.

- 1614-5. Old and transverse fracture of the cartilage of one of the upper ribs. A long section having been made, one-half has been preserved in spirit, and the other half dried; showing that the union is not by bone, though there is a small cretaceous mass adjoining the line of fracture. This last is probably due to the age of the subject, as the same change is seen in the cartilage at a distance from the fracture. 1855. *Dr. J. B. S. Jackson.*

1616. Cast of a part of the chest, showing a large and very deep hollow cavity about the lower part of the sternum.

The subject is rather a feeble man, and attributes the deformity to a fall upon a wash-tub when he was two years old. It has existed as long as he can remember, and has been as large as it is now, proportionally to his size. 1868.

Dr. Henry H. A. Beach.

1617. Transverse and very extensive rupture of the right rectus abdominis muscle, at the junction of the middle and lower thirds; with a considerable amount of effused blood about it in the recent state.

From a woman, æt. twenty-three, who died after the operation of tracheotomy; phthisis, with ulcerated larynx.

There was no explanation for the rupture; and one or two other similar cases have been observed here. 1861.

Dr. J. B. S. Jackson.

1618. Extensive rupture of the tendinous portion of the diaphragm upon the left side. From a man who was run over by a loaded wagon, and died just after his arrival at the hospital (69, 43). The greater part of the stomach and omentum, with the spleen and a large portion of the descending colon had passed through into the left pleural cavity; these organs, excepting the colon, being preserved in connection with the diaphragm. The left kidney also is seen to be very extensively fractured, and almost torn away from its attachments; the pancreas was nearly torn across, and there were several pints of effused blood, with other minor injuries. 1855.

1619. The last phalanx of the thumb torn off, and the whole of the long flexor drawn out; a dry specimen.

From a boy, who made no complaint of the forearm, excepting a slight tenderness for the first two or three days; and who returned to his work on the nineteenth day after the accident.

Dr. M. remarked upon this case as showing how the reparative processes are carried on in wounds that are entirely excluded from the air, and its bearing upon the safety of subcutaneous incisions. Several similar cases have occurred here, and the same remark might be made of all of them. 1854.

Dr. Henry O. Martin, of Roxbury.

1620. Flexor muscle of the index finger forcibly drawn out; in spirit.

From a lad, thirteen years of age, who fell violently forward, and struck his hand upon a nail which lacerated the palm extensively, and drew out the muscle, but did not detach the tendon from the finger. Mr. D. cut away the ten-

don, and the boy did perfectly well; the wound having nearly healed in two weeks. 1859.

Mr. Ezra Dyer, med. student.

1621. The last phalanx of the little finger, amputated at the joint by a finger-ring, and 10 in. of the flexor tendon drawn out; in spirit.

From a man, who fell from the upper deck of a steam-boat, caught the ring, that he had upon his finger, upon a nail, and left it hanging there with the finger. The middle phalanx being denuded of integument, Dr. K. removed it, and the man did quite well; there being very little pain or soreness in the stump or forearm. 1856.

Dr. John B. King, of Nantucket.

In the Soc.'s Cabinet is a little finger that was amputated by a ring, another that was nearly so, and the skin of a third that was taken off. Mr. Annandale (Malformations, etc. of the Fingers and Toes) refers to a similar case.

1622. A hand that was blown off by the premature explosion of a cannon, and thrown to some distance; the little finger being detached, and the tendons drawn out from almost the whole length of the forearm. A dry preparation, by Mr. C. B. Porter, one of the house-pupils. The limb was amputated at the shoulder-joint, by Dr. H., and the patient did well. (Hospital, 114, 146.) 1864.

Dr. R. M. Hodges.

1623. A gangrened foot, removed after death; the toes being completely sphacelated.

From a man, æt. seventy-eight years. Disease of about four months' duration, but for the last four or five weeks had ceased to extend. Separation was going on, but there was redness of the leg, with much pain, as there had been in the toes. Gradually sank under the disease. The arteries were very extensively ossified (No. 1756); but no internal disease was found. Twelve years before, the patient had had the other foot amputated for the same disease, and fully recovered. 1855.

Dr. H. G. Clark.

1624. Portion of a foot, that had been amputated by disarticulation of the tarsal bones. The toes had sloughed off; and

the anterior extremities of the metatarsal bones are quite exposed. The effect of frost-bite. 1847.

Dr. J. C. Warren.

1625. Portion of a lower extremity, showing a very perfect stump after partial amputation of the foot. 1847.

Dr. J. C. Warren.

1626. Cast of the lower part of the leg, showing a very perfect stump after amputation at the ankle-joint, by Dr. H., for a railroad injury; the astragalus being removed, with both the malleoli. (Hospital, 132, 220.) The cast was taken by Mr. Thomas Waterman, Jr., one of the house-pupils, about ten weeks after the operation. 1868.

Dr. R. M. Hodges.

1627. A frog; one of whose extremities terminates in a perfect stump at the junction of the femur and tibia. It was quite active when alive. 1858.

Dr. H. I. Bowditch.

Amputation at shoulder-joint, Nos. 996-8; hip-joint, No. 1515; and partial, of hand, No. 1044.

1628. A scalp from an Indian squaw (Arapahoe), taken last summer, by the Utes, in or near Colorado. The amount of scalp removed is, as usual, not large; but there hangs from it a long braid of coarse, black hair. 1868.

Dr. Samuel A. Green.

1629. Cast, in plaster, of the hand of a man, who had had lead palsy for a year and a half. (Hospital, 193, 102.) The muscles of the ball of the thumb were so remarkably atrophied, that there is a marked concavity in their place. The last joint of the thumb could be freely flexed; but there was no perceptible action of the short flexor, and scarcely any of the muscles of the ball. 1854.

Mr. Geo. G. Tucker, med. student.

1630. Gastrocnemius muscle, showing a complete fatty degeneration. From the same patient as No. 1439. 1854.

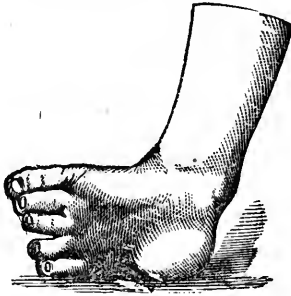Dr. S. D. Townsend.

1631. Photographs of a child, whose head was very much drawn over, in consequence of disease of the cervical vertebrae, that followed measles in 1867. She has been under treatment but a few weeks; and the head is now (Sept.

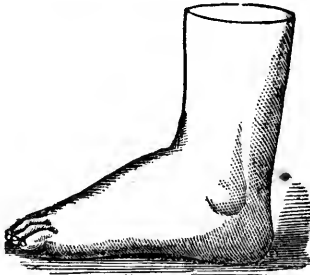
- 27th) nearly upright, as shown in a second photograph. 1869. *Dr. B. Brown.*
1632. Photograph of a severe case of lateral curvature of the spine, in a little boy; hip very prominent. A second, taken some months afterwards, shows a great improvement. Case xv. in Dr. B.'s Orthopedic Surgery. 1869. *Dr. Buckminster Brown.*
- 1633-4. Congenital varus, before and after operation, by Dr. H. A hospital male patient, æt. nineteen (22, 57). 1847. *Dr. Geo. Hayward.*
- 1635-6. Both feet of an adult, affected with varus, with a large callus over each tarsus. 1856. *Dr. H. J. Bigelow.*
1637. Varus of the right foot. Callosity over the tarsus often much inflamed for the last one and a half or two years; and the limb, as a useless and troublesome one, was amputated by Dr. B. above the ankle. A female hospital patient, æt. thirty-four (33, 40). This and the last four specimens are casts. 1860. *Dr. H. J. Bigelow.*
1638. Dissection, by Dr. R. M. Hodges, of the foot last referred to; to show the condition and action of the muscles and plantar fascia; in spirit. 1860. *Dr. H. J. Bigelow.*
1639. A ligamentary preparation of the foot, to show the state of the bones, in case of varus. In spirit. From a little boy, three years old. (Hospital, 81, 83.) 1858. *Dr. H. J. Bigelow.*
- The two following photographs, and twenty-five casts, were presented by Dr. Brown, and show most remarkably successful results. For further details see Dr. B.'s Cases in Orthopedic Surgery (1868), with photographs of the casts. The illustrations here shown are from wood-cuts that Dr. B. used when he published his cases in the Medical Journal, and that he has very kindly loaned.
- Dr. Buckminster Brown.*
1640. Photographs of a little girl, before and after treatment; a case of genu valgum of one limb, and genu varum of the other. Apparatus only used, and not tenotomy. Case xiii. in Dr. B.'s orthopedic surgery. 1869. *Dr. Buckminster Brown.*

1641. Varus in an infant. 1863.

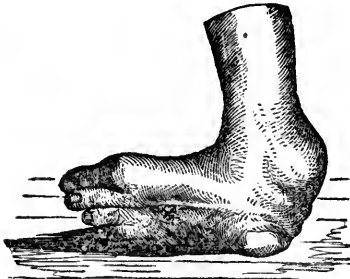1642. Varus in a boy, *æt.* five years, before operation. *Tendo achillis*, *tibialis ant.* and *post.*, *adductor pollicis*, *plantar fascia*, and *flexor comm. dig.* cut by the father of Dr. B. Oct. 24th, 1860; followed by mechanical treatment by Drs. B., Sen. and Jr. 1863.



1643. The same foot, in March, 1861. 1863.

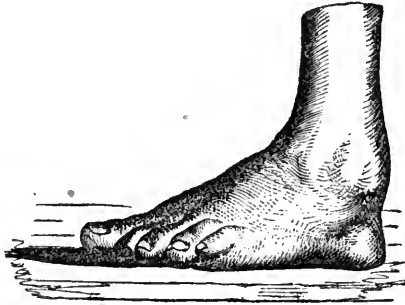


1644. Varus, in its worst form, of the right foot; before treat-



ment. Locomotion was effected on the anterior extremity of the os calcis, and the proper superior surface of the os cuboides ; or, in other words, upon the top of the feet. As shown in the casts, there was a longitudinal doubling, or complete folding inward of the soles, forming a deep groove, by which the great and little toes were brought almost in contact. The prominence of the head of the astragalus upon the dorsum of each foot is also shown. The other was similarly affected. 1863.

1645. The same foot, twelve years afterward. The man, meanwhile, had been a sailor, and stated that he had never experienced any inconvenience from his feet ; and, when he exhibited himself at one of the meetings of the Society for Med. Improvement, there certainly was very little, if any, trace of the former distortion. The accompanying figures give a perfect idea of the two casts, except that it is the left foot that has been represented. 1863.

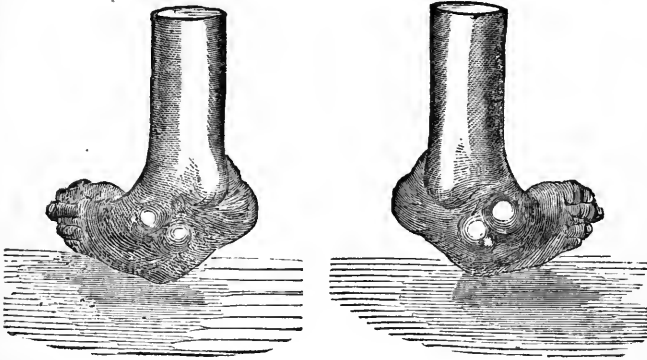


1646-8. Varus of left foot, before treatment. Tendo-achillis, tib. ant. and post., and the flexor long. pollicis divided twice.

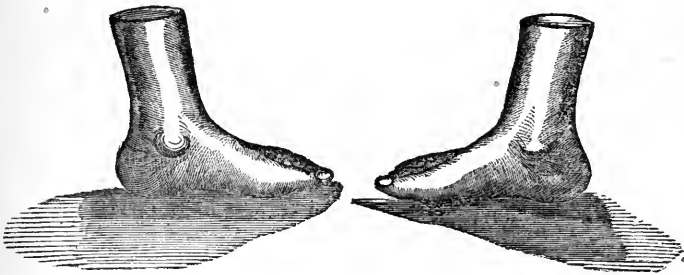
The same, immediately after treatment ; and again, thirteen years afterward. The foot was in every way as perfect as the other ; and the patient had for a year or more been pursuing the laborious occupation of an engineer. 1863.

1649-50. Congenital varus of both feet, before treatment. Bones standing out upon the dorsum in rounded prominences ; feet turned completely inward, and thrown one over

the other when he walked, as usual in such cases. Age, eight years. The patient had undergone ten operations, and worn apparatus, made in New York, for five years.



1651-2. The same, after treatment. The left foot was nearly in the condition shown by the cast in about six weeks. In the other the cicatrices and adhesions resulting from previous operations were far less yielding. 1863.



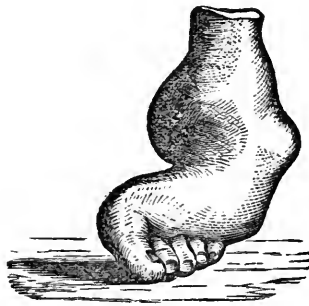1653. Valgus of left foot. A little girl, eight years of age, had paralysis of the whole left lower extremity, and of that only, when two years old. Recovered, excepting her foot, "which hung like a dishcloth;" so that she walked upon the tibia. Tendo-achillis and peronei cut; and apparatus applied.

1654. The same, three months afterward, when she was discharged. 1863.

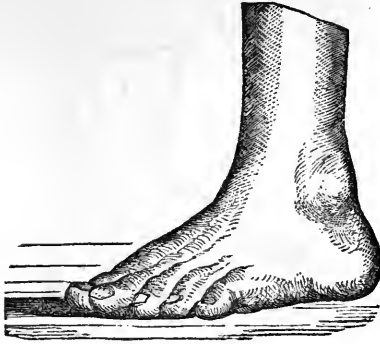1655-6. Paralytic calcaneo-valgus of both feet, in a girl *æt.* eleven years, and the result of spina bifida; the astragalus projecting on the inside of the foot, and making no part of the ankle-joint. The front of the foot was higher than the *h el*; and the tendo-achillis was lengthened, instead of being shortened as usual. The three peronei muscles of the left foot, *extens. longus comm., ext. poll. pedis, tib. ant.* and tendo-achillis were divided; and the same of the right, excepting the *tib. ant.* and tendo-achillis.

Four months after treatment the patient was able to walk upon the soles of the feet. 1869.

1657. *Pes equinus* in a lad, thirteen years of age, before treatment. Metatarsus doubled and twisted upon the tarsus, so as to form at the line of union a sharp and prominent ridge upon the top and side of the foot. Astragalus luxated, and very much diminished in size; so that, in the course of treatment, it was almost impossible to keep it in place. Toes pressed backward so that the fifth was in contact with the back of the foot.



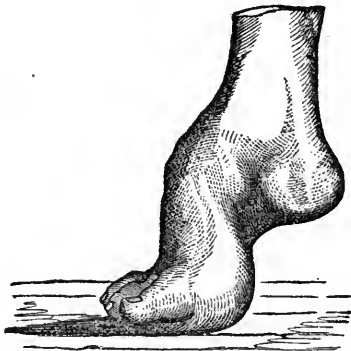1658. The same, after treatment. Shows the wrinkles in the skin where it was stretched over the astragalus and tarso-metatarsal prominences. Tendo-achillis cut four times; *tib. ant., flex. longus pollicis,* and some fasciculi of the plantar fascia; adductor pollicis twice; also the hamstring muscles for a contraction of the leg upon the thigh. Dr. B. subsequently heard of the foot as still further improved. 1863.



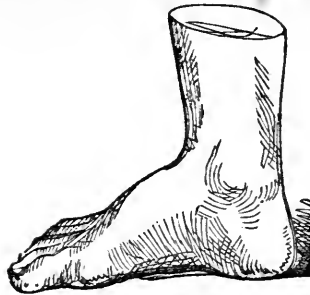1659. Pes equinus of right foot, before treatment. Case of a little girl, *æt.* fourteen years. Palsy of right lower extremity when three years old. Improved, excepting the foot; but stationary for about five years. General atrophy of limb, with shortening by $1\frac{1}{2}$ in.

1660. The same, after treatment. 1863.

1661. Equino-varus, before treatment. The patient, a boy, *æt.* eleven years, walked upon the ends of the metatarsal bones. Metatarsus flexed and rotated upon the tarsus. Astragalus projecting and displaced, so that the tibia rested upon its posterior surface. Heel elevated $3\frac{1}{2}$ in. Probably a congenital equinus, and becoming an equino-varus as he walked.



1662. The same, after treatment. Case remarkable for the rapidity of the cure. Operation on the 22d of September, and on the 30th his toes were straight; and he, for the first time in his life, put his heel upon the floor. 1863.



1663. Calcaneum ; before treatment. The following is the only note that Dr. Brown has of the case: "Paralytic calcaneum. Boy, æt. thirteen. Operation April 12th, 1860, and patient went home July 19th, with a good foot, and walking well." (See No. 1666.) 1863.
1664. Deformed foot and leg, in an infant three months old. Tibia wanting. Fibula bent to a semicircle, so that the great toe was in contact with the inside of the knee. Tendo-achillis, and tib. ant. and post. cut; and a great variety of mechanical appliances used. In six months tib. ant. again cut.
1665. The same, at the end of seven months, when the child went home, and walking on the sole of the foot. Deficiency of the tibia supplied by external support; and in the length of the leg by an addition to the shoe. 1865.
1666. Cast, to show a case of calcaneum (No. 1663) after treatment by Dr. Brown. 1865. *Museum Fund.*
1667. "Measly pork." A portion of muscle from beneath the tongue of a hog, that contains great numbers of cysticerci, as did also the voluntary muscles, and the heart. The cysts differ from those of the *C. cellulosa*, in being quite distinct and isolated. Examined by Dr. W. 1867.
Dr. J. C. White.
1668. An irregular bursal cyst, or collection of small cysts, nearly 2 in. in length, and $1\frac{1}{2}$ in. at its free extremity; parietes thin and fibrous. It was closely connected with the tendons and ligaments behind the knee-joint, and contained a synovial fluid. 1860. *Dr. R. M. Hodges.*

1669. An index finger, amputated by Dr. Bigelow; and showing a tumor connected with the extensor tendon, that he regards as a "hypertrophy of its investing membrane."

From a man, æt. forty-two, who entered the hospital Nov. 11th (141, 253). Tumor around the metacarpo-phal. articulation, of the size of an English walnut, extending somewhat towards the palm; painless, and feeling like an enchondroma. Integument not affected; and motion of the joint good. Duration five years. In the spring it had been incised; and about a drachm of fluid, like the white of an egg, was discharged.

On the 13th Dr. B. removed the finger, with nearly the whole of the metacarpal bone. The tumor extended nearly to the carpus, was about the size of a pullet's egg, white, dense to the feel, somewhat knobbed, and discharged, on incision, a yellowish, gelatinous substance, that was contained in fine meshes of a white fibrous tissue. The tendon, beneath the bone and the tumor, seemed to be merged in this last.

The man did well, and left the hospital on the 26th. 1869. *Dr. H. J. Bigelow.*

1670. A portion of one of the tendons of the foot; and, closely attached to it, a small tumor about an inch in length. This last seemed to be made up of little cysts, filled with a clear, reddish, and very viscid substance; but, on puncturing one or two of them, this last seemed rather to be contained in a coarse fibro-cellular structure. The surrounding parts were healthy. 1855.

Dr. R. M. Hodges.

1671. Casts, to show the external appearances in the "Housemaid's knee." There was a cyst over each patella, very prominent, and fluctuating most distinctly.

From a woman, æt. twenty-five, whose chief business was to wash floors. (Hospital, 54, 101.) Disease of about two years' duration. Both cysts evacuated with a grooved needle, and compression applied. The right did perfectly well; but upon the left side there were inflammation and suppuration, that extended to the thigh. Dis-

charged well in about six weeks. Casts taken by Mr. Thomas H. Gage, one of the house-pupils. 1852.

Dr. S. D. Townsend.

1672. A quantity of fibrinous substance, in irregular masses, from a synovial cyst behind the knee.

From a man, æt. thirty. Three years before he entered the hospital (79, 226); the knee was inflamed for a time. Two months before entrance it got worse again, and a red and tender spot appeared over the inside of the tibia, and 3 in. below the joint. On pressure there, a fluid retreated as if into a cavity behind; and, on making an opening, a clear, synovial fluid was discharged, and there were pressed up, apparently from behind the external head of the gastrocnemius muscle, about a pint of a buff-colored, feebly organized lymph. Inflammation and suppuration of the joint followed; five weeks afterward the thigh was amputated, and the patient did well.

In the upper back part of the tibia was a small excavation, connected with the original cyst; and at that part this last was supposed to have communicated with the cavity of the joint. 1859. *Dr. H. J. Bigelow.*

1673. A cyst, that contained a large quantity of "melon-seed bodies," and that was removed by Dr. Bigelow, from over the shoulder.

From a man, æt. thirty. About a year before he entered the hospital (83, 241), the tumor appeared; and, when seen, was as large as a cocoa-nut, soft, rounded, quite fluctuating, and with little or no pain. About two ounces of fluid having been drawn off, the movement of the bodies within was felt; and, on incision, about $\frac{3}{4}$ x. of them were removed. The finger was passed under the deltoid, and about the head of the bone. Cavity lined by a light-colored, serous-looking membrane, with bands in the parietes of the cyst; soft, velvety red masses adhering and covering the outer surface of the bone and capsule, whilst the smoother parts were lined by flakes of recent false membrane.

The cyst was dissected out, and the patient was discharged well in three weeks and a half. The loose bodies,

the largest of which were from one-half to three-fourths of an inch in diameter, were formed of concentric layers; several sometimes adhering together; and having a common envelope; much larger than those that adhered to the capsule, and not vascular as they were. 1859.

Dr. H. J. Bigelow.

1674. Bodies from the above cyst. 1859.

Dr. H. J. Bigelow.

Different appearances of the loose bodies from the above case:—

1675. 1. Irregularity, and mutual cohesion by intermediate lymph.

1676. 2. More intimate cohesion, with a uniform smooth wall upon one side.

1677. 3. Similar adhesion, but covered on all sides by the plastic deposit which has become smooth by attrition, and leaving a lobulated surface.

1678. 4. Plates of lymph and fragments.

1679. 5. Bodies torn open, to show the laminated structure. 1859.

Dr. H. J. Bigelow.

1680. Bodies similar to the above, and such as may have been removed from a synovial sheath about the wrist. 1847.

Dr. J. C. Warren.

1681. The same, and remarkable for their minute size. Removed from over the front of the forefinger; the cyst extending into the hand.

From a woman, about forty years of age. Pretty severe inflammation followed, but after some months she had a fair use of her hand. 1862.

Dr. S. D. Townsend.

1682. Four loose bodies, from the elbow-joint; three or four lines in diameter, and as hard as bone, though thinly coated with cartilage; in spirit. They were quite free in the joint; and the articular extremity of the humerus, which is in the same jar, is seen to be grooved upon the surface, as in a case that is figured by Cruveilhier.— From a middle-aged woman.

1683. A fifth body, from the above case, and dried to show that it consists mainly of bone or earthy matter. 1852.

Dr. Samuel Kneeland, Jr.

1684. Two bones, from the cavity of the elbow-joint, and in which they were quite free; one is $\frac{1}{4}$ in., and the other nearly $\frac{1}{3}$ in. in diameter. Dry when received; of a rounded form, quite compact, and without any appearance of dried cartilage upon the surface.

From a large, middle-aged negro. The joint looked quite healthy, and without any appearance of chronic arthritis. 1864.

Dr. D. W. Cheever.

1685-6. Casts, in plaster, of two very large bodies, that were removed from the knee-joints by the late Dr. Charles H. Stedman.

The patient was a very intemperate man, and an inmate of the House of Correction. Swelling of the knees began when he was seventeen years old, and the loose bodies were discovered three years afterward. The second knee was operated upon only ten days after the first; and not the slightest inflammation followed either operation. The bodies, which are in the cabinet of the Soc. for Med. Improvement (No. 1027), are composed, about equally, of bone and fibrous tissue, and of a flattened oval form; one $2\frac{1}{8}$ in. long, and the other $2\frac{3}{8}$ in. Case published in full by Dr. S., in the Amer. Jour. of Med. Sc., Oct., 1848. 1855.

Museum Fund.

1687. Acute inflammation of the knee-joint; with chronic disease connected with a "loose cartilage;" in spirit.

From a healthy man, æt. twenty. (Hospital, 24, 121.) Twelve years before entrance he struck the inside of the patella. Severe inflammation followed, but passed off in three or four weeks, and for six months he had no further trouble. The knee then swelled, and the loose body was first felt. From that time he had frequent attacks of pain and swelling, but complained mostly of the loose body slipping between the femur and tibia. The body was cut out, and the patient died with violent local and constitutional symptoms on the tenth day.

The joint shows a deposit of recent lymph in every part

that is not covered by cartilage. This last, over the under surface of the inner condyle of the femur is irregularly absorbed to a very considerable extent, and to a small extent along the opposite edge of the tibia; but there is nowhere any marked appearance as of a piece of bone having formerly been broken off. The "loose cartilage," is in the Med. Society's Cabinet (No. 311), and, now that it is dried, it measures $16\frac{1}{2}$ lines in length, from 6 to $8\frac{1}{2}$ in width, and from $1\frac{1}{2}$ to 2 in thickness. In the recent state, one-third or more of it consisted of cartilage, and the rest of bone. 1847. *Dr. J. C. Warren.*

1688. Elbow-joint, showing an entire removal of the articular cartilage as the result of acute inflammation; dried. When recent the articular surface was as smooth and denuded as it now appears, except to a small extent around the circumference, where there was a thick, red, pulpy structure, that it was thought might be the remains of a diseased synovial membrane. The periosteum also was thickened, red, and friable for 3 in. or more above the joint; and there was a free external opening into the cavity of the joint, with a large abscess in the neighboring parts.

From a sailor, æt. fifty-two (Hospital, 55, 40), who had had an ulcer on the penis a year before, aphonia with dysphagia for three months, connected with ulceration of the larynx and disease of the cartilages, and a node upon the tibia; general health poor. The inflammation of the elbow-joint was severe, and was fatal on the twenty-fifth day; swelling as high as the shoulder; abscess broke on the fifteenth day, and continued to discharge; pain always severe on motion, but easy when at rest. A very large abscess was also found between the left scapula and the ribs. (See No. 1444.) 1852. *Dr. J. B. S. Jackson.*

1689. Fleishy anchylosis of the knee-joint. Bones atrophied; and the femur, of which a large portion is preserved, is curved and flattened laterally. 1847.

Dr. J. C. Warren.

1690. The same, with much more fibrous substance about the knee-joint. From a young subject. 1847.

Dr. J. C. Warren.

1691. The same ; long. section. 1847. *Dr. J. C. Warren.*

1692. Knee-joint flexed to a right angle ; and there must have been false ankylosis, from the amount of fibrous adhesions that seem to have existed. Cartilage destroyed to a considerable extent, with caries of the bone beneath, but it is mostly healthy. 1847. *Dr. J. C. Warren.*

1693. A hand, preserved entire in spirit, and showing the appearances usually seen externally in scrofulous disease of the carpus. 1847. *Dr. J. C. Warren.*

1694. The lower extremity of the femur and the bones of the elbow-joint, showing the gout-deposit. The articular surfaces look, to a considerable extent, as if they had been whitewashed. A few of the other articulations were examined, and traces of the same were found ; as it was also about the ligaments and tendons of the hand. 1860.

Dr. R. M. Hodges.

1695. One of the great toe-joints in spirit, and showing the gouty deposit upon the articular surface in the form of a fine white powder ; the other great toe being similarly affected, and also the metatarso-cuneiform articulations. There was, also, immediately beneath the skin, and over one of the joints, a white, pasty substance in an ill-defined cavity, about $1\frac{1}{2}$ lines in diameter, with a trace of the same in the neighboring cellular tissue. This was found, by Dr. John Bacon, to consist of the "urate of soda, with a little chloride of sodium and phosphate of lime, and a considerable proportion of animal matter ;" microscopically, it had a "granular appearance, but no distinct crystals."

From a man, *æt.* fifty-two, of intemperate and dissolute habits, much subject to gout, and who died at the hospital (172, 186), of Bright's disease. 1852.

Dr. J. B. S. Jackson.

1696. A collection of over sixty bones from a dissecting-room subject, dried, and showing the gouty deposit upon the free articular surfaces. They consist of the small bones of the hands and feet, bones of the forearm and leg, scapula, and patella. The hip and knee were also affected, and in a few places the tendons ; of which last one specimen is shown.

Dr. J. Bacon found the deposit to consist "essentially of urate of soda with animal matter." 1854.

Dr. R. M. Hodges.

1697. The two last phalanges of a finger that was amputated, for gout; dried.

The patient was a man, about seventy years of age, who had been crippled by the disease for many years; numerous "chalk stones" forming about the fingers and toes, and also upon the external ear. The finger had been discharging pus, mixed with the earthy matter, and was very painful; and the bones, about the last articulation, are seen to be surrounded by a large mass of the whitish material. 1867.

Dr. R. M. Hodges.

1698. Cast in plaster of a hand that was affected with gout; joints much swollen and the little finger distorted.

From a man, æt. fifty-nine, who was in the hospital (106, 143) for fracture. Habits intemperate. Gout not recorded; but Dr. Hodges, who had charge of the patient, stated that he had had the disease for years, and that in some places the white deposit could be seen through the cutis. He also had general "rheumatism," but was not prevented from doing the work of a hostler. 1863.

Museum Fund.

SERIES XXII. — ORGANS OF CIRCULATION.

I. PERICARDIUM.

1699. Cavity exposed, and shows everywhere a thick layer of recent lymph; contained, in the recent state, 12 oz. of thick pus, and seemed, before it was opened, to fill both sides of the chest. Heart apparently healthy.

From a boy, five years of age. Duration of disease about a month; and preceded by slight rheumatism in one knee. The symptoms were pain and distress in the chest, and increased by motion; rapid and oppressed breathing; pulse rapid, but regular; some fever at first; pallor with

some œdema; emaciation; no appetite until the last, when it became very strong; lay usually upon the back, and without elevation of the shoulders. There were three distinct paroxysms; and after the two first a remarkable intermission of the symptoms. The physical signs were dulness on percussion, with circumscribed fulness over the heart; but without souffle. Case in the practice of Dr. Walter Channing, and published in the *Boston Med. Magazine*, for Aug. 15th, 1834. 1847. *Dr. J. C. Warren.*

1700. The pericardium so distended as to have contained, by estimate, five pints of pus and fibrin, and to have filled the whole front of the chest. The heart, which is shown in connection, looks healthy.

From a lad, æt. seventeen. Attacked five weeks before death with pain and great dyspnoea. On the third day these symptoms disappeared and never returned; but there came on at once violent nervous symptoms, — delirium, strabismus, etc. Dr. Bowditch saw him six days before death, and found signs of “pericardial effusion to a considerable extent,” but without the nervous symptoms. See *Med. Jour.* Vol. LXXIV. p. 29. 1866. *Dr. C. Ellis.*

1701. “Ossified pericardium.” Universal, old adhesions existed; and the amount of earthy deposit is seen to be very considerable. The heart, which was healthy, has been distended and dried. 1849.

II. HEART.

1702. Heart from a young man, æt. twenty-one, who was stabbed with a common dirk-knife; died in twenty or thirty minutes; about a pint of blood oozing from the wound meanwhile. The external wound was $\frac{1}{2}$ in. long; and the right ventricle was wounded, to the same extent, 1 in. from the apex. The cartilage of the seventh rib was also nearly cut across. — In the preparation a portion of the skin, cartilage, and heart are shown. 1854.

Dr. H. G. Clark.

1703. Spontaneous rupture of the right ventricle; a ragged opening about midway from the apex, and nearly an inch in length.

From a woman, æt. sixty-five, who died instantly. $\frac{3}{4}$ viij. of blood in the pericardium. The structure of the heart was not remarkable about the rupture, nor elsewhere. 1859.

Dr. Richard L. Hodgdon, of West Cambridge.

1704. A second specimen. — From a man, æt. fifty, who had been previously healthy, but had suffered for eight weeks before his death from pulmonary symptoms and occasional palpitation, after sleeping in a cold, damp room. There was also a cardiac murmur. Death at last sudden, and in an exceedingly severe paroxysm of dyspnœa.

The cavity of the pericardium contained $\frac{3}{4}$ ij. of fluid blood. The rupture was $1\frac{1}{8}$ in. from the apex, anteriorly, nearly over the septum, five lines in length, looked like an incised wound, and was found to communicate with the cavity of the right ventricle; a stream of dark blood issuing from it when the heart was raised. The organ itself weighed $17\frac{1}{2}$ oz.; and all of the cavities were dilated, with disease of the aortal valves and of the aorta.

The patient had been in the hospital (271, 64) under the care of Dr. S. 1867. *Dr. G. C. Shattuck.*

1705. Extensive laceration of the interventricular septum. From a man who was crushed between two railroad cars, and died very soon afterward. The fourth, fifth, and sixth ribs upon the left side were fractured midway; and the sternum, but without displacement. (Hospital, 109, 24.) 1863. *Dr. C. Ellis.*

1706. Interventricular opening, — congenital or the result of rupture; with an aneurism, at the origin of the aorta, that projected and finally burst into the right ventricle.

The patient was a robust and perfectly healthy young man, nineteen years of age. About five months before his sickness he arrived in New York harbor in a war-vessel; and, to escape from it, jumped overboard, swam about one-eighth of a mile, and then walked to his home, a distance of about two hundred miles; and all this he bore perfectly well.

About Dec. 1st, 1860, when lifting a heavy stone, he was suddenly seized with a sharp and severe pain across the

lower front part of the chest and extending around to the back; the pain lasting through the day with slight cough and hemoptisis; and from this time he had dyspnœa on any unusual exertion. When Dr. Gage saw him on the 21st, a very distinct purring thrill was felt over almost the whole front of the chest, — very strong over the heart, and most intense over the aortal valves. Dulness over the heart to the extent of 4 in. Systolic and diastolic bellows murmur very superficial, and heard 1 or 2 inches from the chest; most marked over aortal orifice, and heard along the aorta and great vessels from the arch. Impulse increased, and strong in the subclavians. Pulse about 80, small, thrilling, and occasionally intermitting.

On the evening of Jan. 20th he went, as a spectator, to a dance; was out late, and drank somewhat freely. After his return home he had great dyspnœa, and vomited severely. On the 21st he had frightful paroxysms of suffocation, with cold perspiration and great lividity; and during the following night he was in extreme agony. On the 22d he was kept quiet by opiates, but he died that night.

On dissection, a serous effusion was found in the cavities of the thorax and abdomen. The heart was more than twice its usual size; the right ventricle being relatively thicker than the left. The interventricular opening had the form of a half circle, and would easily admit the little finger; the crescentic edge toward the septum being thick and rounded. The pulmonary valves were nearly or quite normal. The aneurism, which arose from one of the pouches just at the aortal valves, was extremely delicate and thin, and would just admit the last phalanx of the fore-finger and about one-fourth of the next. These points are, nearly all of them, shown in the preparation.

Dr. G. supposed that the aneurism dated from the lifting of the stone, but that the interventricular opening was congenital. It appeared to me, however, that both of these conditions were due to the lifting, insufficient as the cause may seem to have been, — in consideration of the previously perfect health, the date of symptoms from that time, the condition of the pulmonary valves, which seem to be so very generally abnormal in one way or another in

case of interventricular opening, and the existence of the aneurism, which must be exceedingly rare if it ever occurs as a complication of interventricular opening, and which would therefore predispose one to look upon this case as not one of common interventricular opening. The rupture of the aneurism, of course, occurred a day or two before death. The question must have been between a congenital opening and rupture; for there was no appearance of disease at the opening, though there was the aneurism quite near to it.

In May, 1869, the case was submitted to Dr. Thomas B. Peacock; of London, who has written a very full and excellent work upon Malformations of the Heart; and his answer was that he "should feel disposed to think that the opening must have resulted from disease or accident, and this mainly in consequence of the absence of any evidence of congenital defect of the pulmonary artery." See *Med. Jour.* Vol. LIX. p. 273, and Vol. LXXII. p. 209. 1863.

Dr. Thomas H. Gage, of Worcester.

1707. Rupture of a diseased mitral valve and of the cordæ tendineæ.

From a physician, æt. thirty-five. (Hospital, 228, 90.) Two months previously, and being then as well as usual, he had rheumatism, which in two weeks left him, and cardiac symptoms then came on, that obliged him to give up his business. There was dyspnœa, but scarcely any palpitation; a systolic bellows murmur over the mitral valve, and a slight aortic soufflé after the second sound. Death very sudden on the third day after admission.

The heart weighed $17\frac{1}{2}$ oz. and was universally thickened and dilated. Aortic valves thickened and retracted; with a soft, whitish deposit upon the under surface of one, and also upon the mitral valve and the inner surface of the left auricle. The laceration in the valve would admit the last joint of the little finger, when recent. There was also a large serous effusion in the cavities of the pericardium and right pleura; with disease of the spleen. (Series XL.)

In the preparation the mitral and aortic valves are shown. 1860.

Dr. C. Ellis.

1708. The tricuspid valve, which alone is preserved, looks as if it had been torn across and afterward firmly cicatrized, except at one point; the rest of the valve being sufficiently healthy. The heart was thickened and dilated; the aortal valves almost quite healthy, but the mitral very greatly diseased.

From a man, æt. twenty-eight years. Disease of eight years' duration; and symptoms urgent the last twenty months. (*Med. Jour.* Vol. LXX. p. 182.) 1864.

Dr. C. Ellis.

1709. A "bovine" heart injected, with the vessels about it. 1847.

Dr. J. C. Warren.

Thibert's models. 1847.

Dr. G. Hayward.

1710. Hypertrophy of the right ventricle, with old pericarditis.

1711. Second. — "Concentric hypertrophy" of the left ventricle; transverse section.

1712. Third. — Another section of the same.

1713. A heart preserved entire, that weighed nearly $2\frac{1}{4}$ lbs., and that was generally enlarged, but without valvular disease.

From a man, æt. seventy, who had symptoms of organic disease of the heart, but no souffle; also Bright's disease, with œdema, ascites, and hydrothorax. A patient of Dr. John Ware. 1860.

Dr. J. Homans.

1714. A second specimen. The left ventricle is very much dilated, but the valves are healthy. Foramen ovale, — valvular opening. Eustachian valve strongly marked. 1847.

Dr. J. C. Warren.

1715. A third. Left ventricle is much dilated, but not at all thickened. Morbid, soft growths are seen upon the aortal valves, but the orifice is sufficiently large. 1847.

Dr. J. C. Warren.

1716. A fourth. Weight of heart $17\frac{1}{2}$ oz. Mitral and aortal valves much ossified, with old fibrinous clots on the last; but the mitral orifice is not contracted; left ventricle thickened.

From a man, æt. fifty, who died at the hospital (231, 50) of rheumatism, and with rather slight cardiac symptoms. 1860.

1717. A fifth; showing "ossification" with great disease of the mitral valve; the orifice being contracted to a diameter of $2\frac{1}{2}$ or 3 lines, and the columnæ carneæ being inserted directly into the valve. The left auricle was dilated and thickened; the left ventricle rather thin and small; and the right auricle and ventricle somewhat thickened. The aortal valves are seen to be healthy. 1849.

Dr. J. B. S. Jackson.

1718. Aortal valves atrophied and perforated. 1847.

Dr. J. C. Warren.

1719. The same very extensively ossified; a dry specimen.

From a negro, æt. seventy-one. Cardiac disease never suspected; but, after his death, his wife reported some dyspnœa occasionally after work. On the day of his death he had been in his usual health; complained of very severe pain in the left breast, soon leaped from his bed, and in a few minutes died.

On dissection, there was found old and very extensive adhesion of the pericardium, some dilatation and thickening of the left ventricle, with considerable disease though no ossification of the mitral valves. The passage through the aortal valves was not greatly obstructed; the portions that were not ossified not being particularly diseased. Two inches of the aorta, sent with the valves, were almost quite healthy. 1852. *Dr. Morrill Wyman, of Cambridge.*

1720. The same; ossified, with extreme disease. In spirit. 1861.

Dr. J. B. S. Jackson.

1721. The same; dried. The valves consist of a thick, rough pile of cretaceous matter, with only a narrow, unyielding, semilunar chink for the passage of the blood. The mitral valves were somewhat involved, though able to perform their functions pretty well; tricuspid nearly healthy. Parietes upon the left side much thickened.

From a machinist, æt. forty-nine, who had had two severe attacks of rheumatism, and gave up his business twelve years before death. The symptoms and signs of cardiac disease were very marked, with great œdema the last few weeks. (*Med. Jour. Vol. LXVII. p. 363.*) 1863.

Dr. G. L. Collins, of Providence, R. I.

1722. Aortal valves thick, dense, and contracted, but not ossified. Asc. aorta healthy. In spirit. 1847.

Dr. J. C. Warren.

1723. Two of the aortal valves so completely fused as to form one continuous cavity, excepting some remains within of a septum. This last may, after a time, have disappeared by atrophy, and the case would then have been one of a two-valved aorta. The third is quite distinct, and they are all thickened. 1847.

Dr. J. C. Warren.

1724. Very great disease of the aortal valves. Many yellow vegetations upon them, one or two lines in diameter; and one large group projects from the free edge. One third or more of one of the valves is so far destroyed that the lining membrane of the heart is continuous with that of the aorta, and quite smooth, excepting a few very small vegetations. The heart weighed $15\frac{1}{2}$ oz.

From a woman, *æt.* forty-seven, who died of pulmonary disease. (Hospital, 212, 29.) 1861. *Dr. C. Ellis.*

1725. A heart which, when recent, weighed between $2\frac{1}{4}$ and $2\frac{1}{2}$ lbs. The aortal valves are diseased, and the mitral somewhat so.

From a man, *æt.* twenty, who entered the hospital (87, 118), for a gun-shot wound, Dec. 18th. On the 6th of Jan. a very irregular action of the heart was noticed, and the sounds were very loud, with souffles. On the 16th, much distress about the heart, and on the 17th he died. 1860.

Dr. H. J. Bigelow.

1726. A heart that weighed, when recent, 34 oz. Left ventricle thick, and greatly enlarged; with much disease of the aortal and some of the mitral valves.

From a hand-cartman, thirty-eight years of age, and healthy in appearance. For three or four years he had been subject to paroxysms of distress, coming on every two or three months, and lasting about three hours; but not being quite free from trouble during the intervals. He died during one of these attacks, having worked as usual the day before. 1850.

Dr. Richard H. Salter.

1727. Portion of the heart, showing disease of the aortal and mitral valves.

- From a man, *æt.* twenty-eight, who had had cardiac symptoms for thirteen years; also disease of the brain. (Hospital, 227, 142.) 1859. *Dr. C. Ellis.*
1728. Hypertrophy of both ventricles, without dilatation. Mitral and aortal valves ossified, and otherwise much diseased. 1847. *Dr. J. C. Warren.*
1729. Extensive ossification of the mitral valves, with great thickening of the left auricle. Left ventricle thin. Adhesion of two of the aortal valves. Tricuspid valve opaque, thickened, and contracted. Right auricle somewhat dilated and thickened. Eustachian valve remarkably developed. 1849. *Dr. J. B. S. Jackson.*
1730. Thickening and opacity of the tricuspid valve, with such contraction that it only admits the end of the finger. Right auricle much thickened and dilated. Mitral valves ossified and greatly diseased; with the carious appearance about the cretaceous matter that is not unfrequently seen. Aortal valves much diseased, but not ossified. 1850.
1731. Left auricle, distended and dried, to show an extensive cretaceous deposit upon the inner surface. The cavity, when recent, was very much dilated, the lining membrane opaque, and the calcareous plates were equal to from one to six lines in diameter; the smallest of them only being covered by a delicate pellicle. There were universal, and old, but slight pericardial adhesions, dilatation and thickening of both ventricles, with much disease of the mitral, and some of the other valves, aorta, and pulmonary artery.
- From a man, *æt.* twenty-three, who died of gangrene of the lungs. From the age of seven years he had had severe attacks of rheumatism, and cardiac symptoms with the first. *Dr. J. F. Jarvis* found him, six weeks before death, with a pale and anxious countenance, hurried respiration, irregular, unequal, and occasionally intermittent pulse, and *œdema* of the extremities; no decided pain about the heart, but something much worse. The region of the heart was prominent; the impulse slow, labored and heaving; with an occasional soufflé toward the last; and there were, also, the symptoms and signs of pulmonary disease. 1854. *Dr. C. Ellis.*

1732. A portion of the heart, showing an irregular, cretaceous deposit upon the inner surface of the right ventricle, $1\frac{3}{4}$ in. in length, and from 1 to $\frac{3}{8}$ of an inch in thickness. It is just below the valve, the membranous portion of which is deficient to the extent of $\frac{1}{4}$ of an inch, as from some old disease; the inner surface of the heart being opaque-white immediately about it.

From a boy, æt. seventeen, who died suddenly, with general dropsy, and various indefinite symptoms. The right auricle of the heart was dilated, the ventricle smaller than usual, and the left cavities healthy. (Med. Jour. Vol. LIV. p. 519.) 1856.

Dr. G. L. Collins, of Providence, R. I.

1733. The left auricle laid open, and showing the cavity apparently quite filled with old fibrine. When recent, this last was partially decolorized, and firmly adherent in part, with passages through for the blood. Auricle thickened and dilated. Mitral valve so contracted as hardly to admit the tip of the little finger; as shown in the preparation.

The aortal valves, and left ventricle were well; but the right cavities were thickened and dilated. Pulmonary apoplexy was also found, with some dropsy.

From a woman, æt. twenty-eight (Hospital, 266, 78), who had very severe rheumatism fifteen months before death, with pain in region of heart, and much palpitation. For the last year much dyspnoea, with pain about the heart, œdema, ascites, and cough with hemoptisis. When seen she was greatly prostrated, and could not speak without severe cough; pulse small and irregular; and the breathing was rapid and labored. Death four days after entrance. 1866.

Dr. C. Ellis.

1734. A portion of the heart, showing a rounded, smooth, adherent, old coagulum in the cavity, and at the apex of the left ventricle; dryish, and of a dull red color, when recent.

From a tailor, æt. thirty, who died in a few hours after his entrance into the hospital (224, 81); active delirium; pulse regular, very small and weak, and quite rapid. 1859.

Dr. C. Ellis.

1735. A small portion of the heart, showing fibrinous vegetations attached to the mitral valve, with extensive laceration. 1847. *Dr. J. C. Warren.*

1736. Heart entire, and showing a peculiar form of the organ, as if both of the ventricles, but particularly the right, were dilated in their circumference. 1847.

Dr. J. C. Warren.

1737. A fibrinous mass from the heart of a right whale; dried. It is of a flattened, pyriform shape, 6 in. in length, $4\frac{1}{2}$ in. across the widest part, and $1\frac{1}{2}$ in. in thickness. Dr. G. received it from an experienced whaler, who said that the animal was an old one, and in good condition, though it had been previously harpooned, and that it was taken last year, near the Azores. The growth was attached by its small extremity to the adherent edge of one of the valves; and in another cavity of the heart was a perfectly similar formation.

Dr. J. C. White, who examined the specimen, found, externally, a very dense, organized, fibrous material, about $\frac{1}{2}$ in. in thickness; and within this shell a very loose, spongy substance, somewhat fatty, and containing a large quantity of inorganic matter, with carb. and phosph. of lime. 1867.

Dr. Alfred C. Garratt.

1738. Aneurism of the heart. — A portion of the organ preserved, and shows a circumscribed dilatation of the left ventricle at its apex; the parietes at this part being thin, white-opaque, fibrous, and inelastic. Rupture had taken place into the pericardial cavity, which last contained, in the recent state, a large quantity of blood. Otherwise, the organ was healthy.

From a man, æt. fifty-nine, who had had cardiac symptoms for two or three years. During the last month he was seen by Dr. W.; and the chief symptoms were urgent dyspnoea, a severe pain beneath the sternum, and occasionally an irregular pulse. He was sitting up, and talking quite cheerfully, when he fell back and died instantly. 1856.

Dr. Charles E. Ware.

1739. Heart entire. Circumscribed aneurism of the left ventricle, extending to the apex; with fibrine in the cavity. 1861.

1740. A small portion of the heart, from a man who died from Addison's disease. It shows a defined aneurismal pouch, about the size of a filbert, at the very upper part of the septum, opening largely from the left ventricle, and projecting into the cavity of the right. The parietes are formed by a distension of the thin, fibro-cellular tissue that is found at this part of the septum; and, if it had ruptured, the case might have been regarded as one of congenital opening. 1860. *Dr. C. Ellis.*

1741. The heart of a sheep, completely and thickly enveloped in fat, externally. The muscular substance is infiltrated with the same, and upon the right side has nearly disappeared; thick masses of fat standing out into the cavity of the right ventricle, and covered only by the lining membrane. Organ altogether much enlarged. Valves healthy. Foramen ovale open.

The animal was slaughtered for the market, and had not been thought of as in any way remarkable. 1852.

Dr. Samuel Parkman.

The bearing of the above case upon that of fatty degeneration of the heart in man, and to which so much importance is generally attached, deserves a remark.

1742. Thibert's model. Numerous, distinct, opaque tubercles upon the inner surface of the right ventricle of the heart. 1849. *Dr. J. Ware.*

1743. A portion of the heart, showing an old tubercular-looking mass in the parietes.

From a man, æt. thirty-six, who died at the hospital (216, 231) of tubercular meningitis; heart not suspected. "Near the appendix of the right auricle, and equally in the wall of the latter, and of the right ventricle, was a firm, yellowish-white, caseous, and almost cretaceous mass, about 1 in. in diameter. Some portions bluish-white, fibrous in appearance, and consisting, microscopically, of fibroid tissue; in other parts minute globules like those of fat, though with darker margins, and not readily dissolved by ether." 1858. *Dr. C. Ellis.*

1744. Small melanotic deposits in the substance of the heart. From a woman, who had melanosis of the eye, liver,

pancreas, and serous membranes; specimens being preserved in this Museum, and in the Med. Society's. (See Amer. Jour. of Med. Sc., April, 1848, p. 379.) 1849.

Dr. J. B. S. Jackson.

1745. A very marked constriction of the aorta, just where it formerly received the ductus arteriosus. The remains of this last are shown, but the cord is impervious. — From a young man, nineteen years of age, who had an aneurism of the left axillary artery, and died after a ligature of the subclavian by Dr. Hodges. There had been no symptoms, however, previously of the constriction.

This specimen should have been entered rather as a malformation. 1868.

Dr. Chas. H. Spring.

Ossification of the coronary artery; No. 1755.

III. ARTERIES.

1746. Laceration of the aorta, about an inch above the iliacs.

From a man who was jammed between two railroad cars, and died in about two hours. (Hospital, 34, 173.) The rupture is in the posterior parietes, extends through all of the coats about an inch longitudinally, and half an inch transversely at the upper extremity. There was about half a pint of blood in the peritoneal cavity, and a large amount in the cellular tissue; but the organs were not injured. 1852.

Dr. J. M. Warren.

1747. Ligature of the common carotid, and cut open to show the coagulum. — The patient lived about seventy-six hours after the operation.

From the same patient as No. 947. 1863.

Dr. R. M. Hodges.

1748. Arch of the aorta, with the carotids; both of which last were tied near the bifurcation. The right is plugged up throughout about one-half its length; and the left almost from its origin to the ligature. There is a plug, also, in the right internal carotid. From the same patient as No. 1506. 1858.

Dr. H. J. Bigelow.

1749. A specimen, labelled by Dr. W., "Ligature of the carotid." Probably from a man, æt. twenty-eight, who died of phthisis, and whose carotid had been tied four years

previously, for a supposed aneurism. (Hospital, 7, 28.) The vessel was obliterated, and towards the upper part was scarcely traceable. 1847. *Dr. J. C. Warren.*

1750. A preparation, to show the state of the arteries four years after the left subclavian had been tied. Case published by Dr. J. C. Warren, in the twenty-ninth volume of the *Med. Chirurg. Trans.* (London, 1846), after the performance of the operation; and the final result by Dr. F. S. Ainsworth, in the *American Jour. of Med. Sciences*, Jan., 1850.

The patient, a man, *æt.* thirty-five, entered the hospital Dec. 23, 1843 (27, 281). The left shoulder had just been dislocated and reduced; but there was great swelling and pain, with ecchymosis; and the axillary artery was supposed, without question, to have been ruptured. He became worse; the radial pulse ceased, and a tumor in the axilla opened on the 28th of January, and discharged a thin, bloody fluid, after which a feeble pulse returned. Oozing of blood continued; and, a copious hemorrhage having occurred on the 7th of February, the artery was tied on the following day, above the clavicle, by Dr. W. The pleural cavity was accidentally punctured during the operation, but without any bad consequences. On the thirteenth day the ligature came away; and on the twenty-third and thirty-third days hemorrhages took place to the amount of a pint and a half; but these were checked by a sponge tampon, and from that time he had very little trouble with the wound above the clavicle. The swelling in the axilla, however, continued to discharge pus, and was very painful; and on the 23d of March a large coagulum came away, with a copious discharge of pus, and relief to pain. From this time, until he left the hospital in September, 1845, he gradually improved; but the axillary abscess continued to discharge, and the shoulder-joint was immovable. Some months after his discharge he entered the almshouse, and there acted as a ward-tender until he died of dysentery in Oct., 1848.

Having given up his body for dissection, the arteries were injected by Dr. Ainsworth, and the preparation made by him; one-half of the thorax, with the scapula, being

preserved. The subclavian, where it issues from between the scaleni muscles, is reduced to a mere cord, but regains nearly its natural size at the distance of three-fourths of an inch. The collateral circulation was carried on by the intercostal branches of the int. mammary artery, and the thoracic branches of the thoracico-acromialis; and by a large inosculation between the suprascapular artery, and a branch of the subscapular. A communication was also traced between some small muscular branches of the transverse cervical, and the thoracico-acromialis.

The dense cellular tissue that invested the axillary artery was not entirely removed when the preparation was made; but Dr. A. having recently (1866) done this, after thoroughly softening it, the artery is seen to be continuous, and of full size. It must, then, have been some large branch, only, that was ruptured at the time of the accident. 1849.

Dr. J. C. Warren.

1751. A portion of the aorta, showing the cœliac artery completely closed by old fibrine; the clot projecting slightly into the cavity of the vessel, and having a ragged look, as if a "prolonged thrombus," as Virchow calls it, may have been broken off. Rather more than an inch above this is a second old clot, $\frac{1}{2}$ in. long, and less than two lines in width. This last is attached by one extremity, and hangs off into the cavity of the aorta, but no vessel can be seen from which it has protruded. A portion of the femoral, and of one other artery from the left lower extremity is also shown, filled with fibrine. The aorta, generally, was very much diseased, as shown by the specimen.

From a lady, æt. sixty-eight, who had been much subject to headache for many years; also to cardiac symptoms for about three years, though no disease of the heart was found. About three months before her death she was attacked with a very intense pain in the region of the left kidney, and which Dr. M. connected with the disease of the cœliac artery. In the course of a week this had subsided; but the large amount of opium and of chloroform that was required to relieve it caused a great deal of nausea and vomiting, that lasted for some time, and that never entirely left her. Two months before her death she began

to have pain and numbness in the left lower extremity; the pain being mostly below the knee, and gradually increasing until it became very intense. Three weeks before death the left foot became gangrenous, and the outer half of the foot and leg at last sphacelated; the inner portion never becoming affected. A line of demarcation having formed below the knee, Dr. M. amputated the thigh, but only as a palliative; the branches of the profunda bleeding freely, though the femoral was closed. The operation quite relieved the pain in the leg, and the patient died on the sixth day.

The right external iliac artery was filled with recent fibrine; and, upon the left side, some of the arteries below the knee, as well as the femoral, were filled with old fibrine. (See *Med. Jour.* June 11th, 1868.) 1868.

Dr. Henry A. Martin, of Roxbury.

1752. Thoracic aorta ossified; dried. 1847.

Dr. J. C. Warren.

1753. Abdominal; ditto. 1850.

Dr. C. D. Homans.

1754. Tibial; ditto. The cretaceous deposit is granular, as usual in the small arteries; and not in plates, as in the aorta. 1869.

Dr. H. H. A. Beach.

1755. Coronary artery of the artery of the heart; ditto. 1854.

Dr. J. B. S. Jackson.

1756. Arteries of the leg, extensively ossified; from a case of gangrene of the foot. (No. 1623.) 1855.

Dr. H. G. Clark.

1757. Iliac arteries, with the lower portion of the aorta, injected. The arteries are much dilated, elongated, and tortuous. 1856.

Dr. R. M. Hodges.

1758. Dilatation of the asc. portion of the aorta, towards the right side and front; and of the arch to beyond the great vessels. Injected. 1847.

Dr. J. C. Warren.

1759. Aorta injected to beyond the arch, and showing a fusiform dilatation above the valves. 1851.

1760. Thoracic aorta, much diseased and somewhat ulcerated, but with very little ossific deposit. — From Dr. R., of this city; æt. sixty-nine. Death from disease of the heart. 1847.

Dr. J. B. S. Jackson.

1761. A large part of the aorta, with part of the iliacs. Dilated and greatly diseased. Inner coat detached extensively in some places, and exposes an abundant yellow deposit.

From a man, æt. ninety, and who had always been healthy. 1856. *Dr. C. Ellis.*

1762. A very great, and apparently uniform dilatation of the aorta, from its origin to the vessels at the arch; one small sac only being engrafted upon it. The cavity must have been large enough to have contained a foetal head, and the parietes are greatly diseased. Just beyond the arch the vessel contracts abruptly to its natural size, and is perfectly healthy. The heart, which is also preserved, has been cut open into the left ventricle, and with the aortal valves is seen to be healthy. In spirit. 1849.

Dr. J. B. S. Jackson.

1763. Aorta greatly enlarged and diseased, and the art. innominate three times its usual size. Every one who had examined the patient from whom this specimen was taken, felt confident that there was an aneurism of one of these vessels; and the surgeons of the hospital (134, 237) unanimately advised a distal ligature upon the right carotid and subclavian; but no trace of an aneurism was found.

There was a distinct and strongly pulsating tumor above the top of the sternum, with souffle; and from this tumor the car. and subcl. seemed to arise. There was also cough with dysphagia and dyspnœa; and toward the last these symptoms became very urgent. The ligatures were therefore applied; and the patient died, on the eleventh day, apparently from exhaustion. Dr. H. has fully reported this case in the *Med. Jour.* Aug. 6th, 1868. 1868.

Dr. R. M. Hodges.

1764. Dissecting aneurism. The laceration is less than an inch above the valves; and the false passage reopens into the aorta at the arch; the appearances seeming to indicate that the patient had lived for some time after the accident occurred. The vessel itself is sufficiently healthy. 1847.

Dr. J. C. Warren.

1765. A second specimen. — From a healthy man, æt. fifty-six. About 9 p. m. severe pain came on in the epigastrium,

extending through to the spine, and continuing until he died at 4½ P.M. on the following day. He was unable to lie down, and during the night there was vomiting.

Two or three ounces of blood were found in the pericardium; and the aorta was ruptured just above the valves, and to the extent of about two-thirds of its circumference. The internal coats had given way, and the blood had dissected a passage for itself as far as the internal iliacs, where the inner coat of the right iliac again ruptured, and the blood had returned into its proper channel. The branches from the arch were also dissected. This dissection of the aorta involved mostly the posterior parietes of the aorta, and nearly or quite one-half of its circumference; the fibres of the middle coat being seen upon both surfaces along the false passage. The tissues of the artery were nowhere much diseased; and apparently quite healthy at the place of rupture, though there was an appearance near it as of an old laceration that had been cicatrized. (*Amer. Jour. of Med. Sc.*, Oct. 1848, p. 300.) 1848.

Dr. J. B. S. Jackson.

1766. A third specimen. This case and the last occurring within thirteen days of each other. From a patient of Dr. B. E. Cotting; sixty years of age, and a healthy-looking man, though dyspeptic. Ate heartily of ham at breakfast, to which he was not accustomed, and again at noon. In the evening he had nausea, and took an emetic; but nothing unusual occurred until about 2 A.M., when his wife was awoke by his oppressed breathing, and he soon died.

The cavity of the pericardium contained about six ounces of fluid and blood; and in the aorta was a laceration, about half way between the valves and the arch, through the entire thickness of the vessel, and extending spirally so as to more than involve its circumference. The pericardium is stripped up from the anterior face of the aorta, and forms a large cavity that was filled with blood, and finally burst. In structure the asc. aorta was almost perfectly healthy, and the desc. portion only moderately diseased; the edges of the laceration being as smooth as if cut with a knife. The heart and other organs

were well. (Amer. Jour. of Med. Sc., Oct. 1848, p. 301.)
1848. *Dr. J. B. S. Jackson.*

1767. A fourth specimen. The laceration commences 2 in. beyond the left subclavian artery; and the blood was mostly between the outside of the thoracic aorta and the spine, though to some extent the parietes of the vessel have been dissected apart. Rupture took place into the left pleural cavity; and the appearances seemed to show that this did not occur until some little time after the vessel gave way.

From a gentleman, æt. fifty-six, who had disease of the heart, and symptoms of it for eight months or more.
1847. *Dr. J. B. S. Jackson.*

1768. A fifth specimen. At the arch, posteriorly, is a longitudinal laceration, 2 in. in length, and extending through the inner and middle coats. The blood had forced its way between the middle and external coats as far as the iliacs, upward into the right subclavian and carotid arteries, and down toward the heart, near which is a small opening into the pericardium; the cavity of this last containing a large amount of blood. In the arch of the aorta were two or three small atheromatous spots, but not along the rupture; beyond this there was more disease, but nowhere much.

From Dr. H., æt. fifty-nine, and always healthy. His death at last was instantaneous; but five days before, he had what seemed to be an attack of apoplexy, and to which he seemed predisposed. He complained, however, just as the attack was coming on, of a "disagreeable" feeling in the left breast, and, on the day before his death, of an "uneasiness" in the chest. The laceration was supposed to have occurred when he was first attacked, and the opening into the pericardium at the time of death. (Med. Jour. Vol. LII. p. 418.) 1855. *Dr. C. Ellis.*

1769. A sixth specimen.—The laceration commences just above the valves, and extends an inch and a half upward, posteriorly, and through the inner and middle coats. Middle and outer coats separated to the extent of about one-half of their circumference, and as far as 4 in. from the iliacs; portions of the middle coat being separated with

the outer, as shown in the next specimen. The artery is atheromatous, but not ossified. Rupture into the cavity of the pericardium, which was filled, in the recent state, with effused blood. The greater part of the aorta is preserved in two pieces.

The patient was a perfectly healthy man, æt. fifty. Pain across the abdomen just above the umbilicus, drowsiness, and chilliness were the chief symptoms, and for about thirty hours. (*Med. Jour.* Vol. LXV. p. 371.) 1861.

Dr. C. Ellis.

1770. A portion of the aorta, from the above case. 1861.

Dr. C. Ellis.

1771. A seventh case, and which occurred within twenty-four hours of the last. — From a patient of Dr. Stearns; a negress, over ninety years of age; and always healthy, excepting some cardiac symptoms the last two years. Fell and died immediately.

The pericardium was filled with blood; and a short distance above the aortic valves, posteriorly, was a vertical laceration from two to three-eighths of an inch in length, extending through the middle coat, and separating this from the outer, around two-thirds of the circumference of the vessel, and upward to within an inch of the art. innominate. The cellular tissue toward the lungs was also infiltrated with blood. Aorta dilated, and atheromatous. 1861.

Dr. C. Ellis.

1772. An eighth case. — The patient was a clergyman, æt. fifty-five, and a large powerful man, though not healthy. An attack of pain along the back came on, that was overpowering in its severity; but some relief was got from opiates and ether. At last, and for the first time, severe pain came on in the front of the chest, extending through from the back; an hour afterward he started up, groaned heavily, and fell back dead, not quite four days from the first attack of pain.

The left pleural cavity contained about six pints of blood and serum; and near the lung was a large, ragged opening through into the surrounding tissues. Just beyond the subclavian artery there is, as seen in the preparation, a

ragged laceration, more than an inch in length; and from this point the blood had worked a passage for itself between the middle and outer coats of the aorta as far as the iliaes, into one of which it had burst through again into its proper channel. There was atheromatous disease of the artery; and considerable hypertrophy of the left ventricle of the heart, though without valvular disease, or previous symptoms.

Here, again, the rupture of the aorta must have taken place when the pain came on, and that into the pleural cavity at the time of death. (Med. Jour. Vol. LXXII. p. 80.) 1865. *Dr. C. Ellis.*

1773. A ninth case. — From a patient of Dr. Minot; a man of delicate health, and about forty years of age. He had been sick for a week with very obscure constitutional symptoms, and died at last, suddenly.

In the back part of the aorta is a longitudinal rupture of the internal and middle coats, and commencing from one-half to three-fourths of an inch above the valves. The blood had forced its way between the middle and external coats as far as the right renal artery, where it re-entered the natural channel, as it had also in the thoracic aorta. There was also a rupture into the right auricle, by a slit an inch in length, as seen in the preparation. The heart was universally hypertrophied and dilated; pericardium universally adherent; and there was considerable atheromatous disease of the aorta.

The hypertrophy of the heart, and disease of the arteries in this and in the last case were thought to sufficiently explain the rupture. (Med. Jour. Vol. LXXII. p. 81.) 1865. *Dr. C. Ellis.*

The coincidence in the occurrence of rare cases has been observed here as well as elsewhere; but in none has it been more remarkable than in these of dissecting aneurism: Nos. 1765-6; 1769 and 1771; 1772-3, — these two last patients having died within less than four days of each other.

1774. Cast, in plaster, of the front of the chest, and showing a tumor about as large as the fist, that extends from above the sternum to the third rib. From a case of aortic aneu-

rism, that arose from the arch of the aorta, was about 6 in. in diameter, and filled with old fibrine; the sternum being absorbed to the extent of the tumor.

The patient was a woman, æt. twenty-six. In May, 1861, she received a violent blow on the chest, and shortly afterward had acute pain across the upper part of the chest and shoulders, with slight cough. In September she had a deep-seated "smarting" beneath the upper part of the sternum, with dyspnœa, hoarseness, and dysphagia. In May, 1862, a tumor appeared, and her disease progressed. In December (Hospital, 246, 146) a double pulsation was quite marked over the tumor; aneurismal bruit below the right clavicle, and over the carotid, but not in the tumor. Respiration loudest over right side; and over the left it was somewhat bronchial. Occasional, hollow, hard, hoarse cough. April, 1863, she raised a few ounces of aerated blood, and died in about ten minutes.

The left primary bronchus was much flattened, and closely adherent to the sac; an opening having undoubtedly taken place there, as blood was found in the bronchi upon both sides. The right lung was distended and healthy. The left pleura was adherent, except at the lower part where was a cavity containing about a pint of pus; and the lung was small, compressed, and contained numerous small purulent cavities. (Med. Jour. Vol. LXVIII. p. 463.) 1864. *Museum Fund.*

1775. A second and similar cast. The tumor is about in the same situation, but smaller and more diffused than in the above case.

The patient was a man, æt. forty-eight. (Hospital, 266, 194.) About a year before, whilst helping to carry a heavy timber, one end was dropped, and he felt his right shoulder severely jarred. Recovered at once, but a month afterward a pulsating tumor appeared, and increased from that time, with much pain and considerable dyspnœa. 1866.

Mr. J. Collins Warren, one of the house-pupils.

The exciting cause of the disease, in these two last cases, seems to have been unquestionable, however impossible it may be to explain its operation.

1776. Thibert's model. Double aneurism of the aorta, forming two large pouches. The one in the ascending portion contains no coagula. The second, which is just beyond the arch, contains a large old clot that is hollow in the centre; and the entrance into the descending aorta is quite abrupt. In the first sac are small ossific patches throughout the internal surface. Orifices of the heart healthy. 1849. *Dr. J. Ware.*

1777. Aneurism of the asc. aorta, that must have been at least half as large as the fist; cavity filled with fibrine. Orifice just above the valves, about an inch and a half in diameter, circular, and very defined. The sac presses upon, and distends the pulmonary artery so as almost entirely to obliterate the valves. It also presses upon the right ventricle below the valves, as shown in the preparation; and it evidently might, at some future time, have ruptured at either point. 1847. *Dr. J. C. Warren.*

1778. The heart, with the ascending portion and arch of the aorta, dilated into a true aneurismal sac, that is larger than the two fists; the inner surface of the sac showing small cretaceous plates, and looking altogether like that of a common diseased artery. From the upper part of the sac a false aneurism arises, with a defined orifice, and pressing against the lower half or more of the trachea. The vessels that arise from the arch seem healthy. 1861.

1779. Aneurism of the arch of the aorta; opening into the trachea.

From a strong, healthy man, about forty-five years of age, and who had had palpitation, with increased and irregular action of the heart "for years." Whilst sitting quietly, he coughed twice, blood poured from his mouth, and in a few minutes he died.

The sac, which is about the size of a goose-egg, arises from the back of the aorta; and the opening into the trachea is between one and two lines in diameter, and $1\frac{1}{4}$ in. above the bifurcation. There are old fibrinous clots in the cavity; and the vessels at the arch arise from near the mouth of the sac. 1867. *Dr. H. G. Clark.*

Aneurism at the origin of the aorta, and that burst into the right ventricle. (See No. 1706.)

1780. Aneurism at the origin of the aorta. The sac is about 2 in. in diameter; somewhat atheromatous within, and between it and the pulmonary artery is an opening about half an inch in length, with smooth, rounded edges, and presenting none of the appearances of a recent rupture.

From a man, æt. forty-eight, who had been subject to dyspnœa on exertion for five or six years; became at last generally dropsical; and died whilst sitting up to fan himself. (Med. Jour. Vol. LV. p. 164.) 1856.

Dr. C. Ellis.

1781. A portion of the parietes of the chest, with an aneurismal sac, showing an extensive destruction of the sternum; dried.

From a woman, who had been subject for the last sixteen years to rheumatism, with dyspnœa and palpitation; and for more than two years to paralysis of the right arm. Nine weeks before death a pulsating tumor appeared in the upper sternal region, and rapidly increased, so as to measure before death $7\frac{1}{2}$ in. transversely and $6\frac{1}{2}$ vertically. A distressing cough and frequent sense of suffocation were constant symptoms toward the last; and the slightest pressure upon the tumor caused severe cough and dyspnœa. She, however, maintained herself, by work, until the last six weeks; but for the last two weeks was confined to her bed, and suffered much.

On dissection, the tumor extended from just above the line of the second ribs to the lower edge of the larynx upon the right side, and from the anterior extremity of the second rib upon the left side to beyond that upon the right. The aorta was dilated immediately above the valves, and the asc. portion and arch formed an immense sac. Posteriorly the vessel was wrinkled and atheromatous; and, anteriorly, the sac was formed by the eroded sternum and expanded pectoral muscles; the cavity containing much old and recent coagulum. Right subclavian artery flattened. Heart perhaps large, but otherwise well. 1857.

Dr. C. Ellis.

I have very generally, if not always, found the heart quite healthy, when an aneurism arose from the aorta at its origin; and do not remember to have seen it remarked.

1782. Arch of the aorta, showing a defined, false aneurism
 • about as large as a hen's egg. 1862.

1783. A portion of the aorta, showing two aneurisms about two inches and a half beyond the left subclavian artery. One is about the size of an English walnut, the other about half as large again, and they are upon the same level, and about an inch apart. Apparently of the mixed variety. The smaller sac had burst into the left pleural cavity, in which last was a large quantity of serum, and nearly a washbowl full of coagulated blood; the opening being a ragged slit, and not much more than a line in length. The larger one, as seen in the preparation, encroached upon the œsophagus, the inner surface of which was discolored. An additional portion of the aorta shows a third sac just above the valves, one-third of an inch or more in diameter, and of the true variety. The vessel itself is considerably diseased.

From a gentleman, æt. twenty-nine. Cough for seven or eight months, and urgent for the last three or four; not much expectoration. Some dyspnœa; and about a month before his death spoke of pain in the region of the heart. He was considered, however, as a healthy man. Went to his room to smoke a cigar; and about two hours afterward was found dead. 1866.

Dr. H. J. Bigelow.

1784. A portion of the aorta, showing a defined, rounded aneurism, 7 in. in length, and just above the diaphragm; orifices very defined. The sac seems to be formed, mainly, by a dilatation of the artery; the inner surface of which is much diseased, but not ossified. The aorta, otherwise, is moderately diseased, but of the natural size.

From a man, about fifty years of age, who had had for more than two years pain in the lumbar region, became much emaciated, and died from a rupture of the sac into the left pleural cavity; this last containing about six quarts of blood. The bodies of three of the vertebræ were extensively absorbed; and the head of the ninth rib was detached. 1861.

Mr. J. E. Cobb, med. student.

1785. The heart, with a large portion of the aorta distended, dried, and cut open, to show two aneurismal sacs. One of these last is situated at the passage of the artery through the diaphragm, defined and regular in its outline, and larger than the two fists. The other is about half as large, more irregular, situated just above the first, and connected with it. The openings from the aorta are quite abrupt, but not large; and between the two sacs is a larger and very defined opening. 1847. *Dr. J. C. Warren.*

1786. Aneurism of the aorta where it passes through the diaphragm; of the size of two fists. The sac was nearly filled with old fibrine; and, this last having been removed, the cavity has been distended and dried. The bodies of the vertebræ are seen to be eroded anteriorly, and so far to form a part of the parietes of the sac, with the posterior portion of the aorta. Entrance to and exit from the sac quite abrupt.

From a man, æt. forty-five. No indications of disease, except pain in the back; and he died from a rupture of the sac into the left pleural cavity. 1862.

Dr. D. W. Cheever.

1787. A portion of the aorta, showing a defined, rounded opening, about 2 in. in diameter. This led into a large aneurismal sac that was situated between the aorta and the spine, just below the diaphragm, and that burst into the right pleural cavity. The cœliac and right renal arteries, though not involved, are seen to be completely obliterated at their origin, though just beyond this they are of full size. The aorta itself is much diseased.

From a negro, æt. fifty-eight, who had had "lumbago" for four years. 1847. *Dr. J. B. S. Jackson.*

1788. A portion of the upper part of the abdominal aorta, showing an aneurism, of a flattened oval form, about the size of a hen's egg, and of which the orifice is nearly as large as the cavity. This last is about one-third filled with old, whitish fibrine; the surface of which is smooth, as if an adventitious coat were forming, and the whole deposit so thick and firm, or even dense, that the disease may be considered as having been entirely cured for a long time

before death. A similar plastering-up, as he would call it, is shown by Curveilhier. (*Anat. Path.* liv. xxviii. pl. 3.) From the lower part of the sac the cœliac artery arises; but at its very origin there is a linear obliteration, and so complete that no trace of it was seen upon the inner surface of the sac. A portion of the vessel is preserved, and shows that it was smaller than usual. The sup. mesenteric artery also arises just within the sac, and is very much contracted at its origin, as if undergoing obliteration. Directly by the side of this aneurism was another, as large or larger than the two fists, and that burst into the left pleural cavity.

The patient, a negro, æt. thirty-three years, and a strong laboring man, entered the hospital (275, 118), with obscure pains over the abdomen, that he had had for two weeks; having, previously, been quite well. A few days afterward there came on an effusion into the left pleural cavity, the result of a very moderate amount of inflammation; and about three weeks after admission he died almost instantly. There had been pulsation in the left epigastric region, and his chief complaint was of the left hypochondrium; but aneurism had not been suspected. A large amount of blood was, of course, found in the chest. 1868.

Dr. J. Homans, Jr.

A complete and linear obliteration of a large artery, where it arises from an aneurismal sac, I have met with three times (*Med. Jour.* Vol. lvi. p. 174); and think it cannot have been generally noticed that the obliteration may be confined to the orifice and leave the vessel itself free. (See Rokitanski and Hasse.) See also the next case.

1789. The aorta, from the arch downward, showing a defined aneurism, of the size of a hen's egg, and situated just at the origin of the upper mesenteric artery, which last is entirely obliterated where it arises from the sac, but becomes of full size immediately afterward. The vessel is cut open behind, and is generally nearly healthy.

From a man, æt. thirty-three, who had complained for three months of epigastric pain and costiveness; and died, in fifteen hours, after a rupture of the sac into the general cellular tissue.

This case and No. 1787 occurred at the almshouse within twenty days of each other. 1847.

Dr. J. B. S. Jackson.

1790. Aneurism of the aorta, anteriorly, just above the bifurcation, about as large as the fist, and nearly filled with old fibrine. The artery is very much diseased, and also the iliacs; the left iliac being aneurismal near the aorta, and the sac filled with fibrine.

From a gentleman, æt. seventy-one, who enjoyed fine health, but about six months before death had severe pain that it was thought might be owing to the passage of a renal calculus. A strongly pulsating tumor was then first felt in the abdomen, continued ever afterward, and was regarded as an aneurism by his brother, who was a physician; but he never had the slightest trouble from it, excepting a pain in the corresponding part of the back. Death occurred in about an hour and a half after a rupture of the sac into the general cellular tissue; this last being attended with severe pain and great pallor, though the amount of effused blood was small. 1861.

Dr. J. Homans, Sen.

Pain in the corresponding portion of the back I have met with several times in aneurism of the abdominal aorta.

1791. The heart, with a portion of the aorta, showing an aneurism of the art. innominata, and somewhat involving the arch; sac nearly as large as the fist, and filled with old coagulum. The pressure upon the trachea is well shown.

Case fully detailed by Dr. W., in the *New England Med. Jour.* Vol. i. p. 121, 1812. In the autumn of 1808 the man had pains in the right shoulder, arm, and leg. In the spring of 1809, a pulsating tumor between the second and third ribs upon the right side; and soon afterward symptoms of disease of the heart. In the spring of 1810, he became much worse; respiration laborious and suffocating; cough incessant with urgent dysphagia, and pain in chest more severe than ever; often starting from sleep, with a dread of suffocation. From this time his symptoms occurred in paroxysms of two or three days' duration, but during the intervals he was comparatively comfortable, and able to attend to his business. Gradually got worse; the

pulsation diminished in the right carotid and subclavian arteries; and in August, 1811, he died in one of his paroxysms.

The sac pressed upon the second and third ribs, and the edge of the sternum had become carious; the skin over the third rib looking as if ready to burst. A second, smaller and separate aneurismal tumor arises from the back part of the arch of the aorta, extended backward, and pressed upon the trachea at its bifurcation, and upon the œsophagus. 1847.

Dr. J. C. Warren.

1792. The heart and aorta, showing an aneurism of the art. innominata, two-thirds as large as the fist and completely filled with firm, old fibrine. Carotid free. Right subclavian completely obliterated where it arises from the sac, but of full size beyond this. A large false aneurism is also seen, where the aorta passed through the diaphragm, and the laceration by which it opened into the left pleural cavity. The aorta itself is diseased throughout.

From a gentleman, æt. fifty-five, who had been sick for about two years and a half, and without pulse in the right wrist for two years or more. 1847.

Dr. H. J. Bigelow.

1793. The art. innominata, showing a little aneurism arising from and entirely limited to this vessel. The cavity is an inch or more in diameter; the orifice one-third of an inch or more in diameter, and smooth, as it also is just within.

From a man, æt. twenty-four, who died from the rupture into the pericardium of a large aneurism of the asc. aorta. 1859.

Dr. C. Ellis.

1794. Cast in plaster showing a small, nipple-shaped tumor in case of traumatic aneurism of the left common carotid artery. Sent to Dr. W. by W. R. Beaumont, Esq., under whose care the patient was treated in Toronto, C. W. Clinical lecture upon the case published by Mr. B. in the London Lancet, July 19th, 1854.

The patient, æt. twenty, entered the hospital Jan. 2d, 1854. Stabbed about eight weeks before, and signs of aneurism were well marked. Cast taken on the 9th. Treatment: low diet, fifteen or twenty minims of Tr. of Digitalis three times a day, and venesection three times. On

the 15th the tumor appeared smaller, became so from that time, and on the 20th of March no vestige of it could be felt. A loud, continuous bruit, however, was still heard; and a vibratory thrill along the internal jugular vein, which Mr. B. thought may have been wounded simultaneously with the artery.

1795. A second cast taken March 20th. 1857.

Dr. J. M. Warren.

1796. Cast in plaster, by Mr. G., showing the tumor in a case of subclavian aneurism.

The patient was a man, æt. twenty-eight, who, four months before entrance into the hospital, on the 15th of August (264, 134), fell down a hatchway. Ten weeks before entrance a tumor appeared behind the right clavicle. After lifting a heavy weight pain came on; and this, with the tumor, increased from that time. On admission, the tumor was of the size of a goose-egg, and pulsating; with a marked systolic souffle and a distinct aneurismal thrill. Pain pretty constant, quite severe, and extending down the arm, and into the chest. Arm somewhat swollen, and radial pulse very faint. On the 26th the tumor was gently kneaded, with a view of breaking up the contents; pressure was afterward applied, and the patient was kept upon the lowest diet. Under this treatment the tumor diminished somewhat in size; but on the 15th of Sept. two ulcers had formed under the apparatus that had been applied. On the 17th a small slough appeared, and on the 20th he left the hospital. The whole limb subsequently gangrened, and he died within a few weeks after his discharge. The cast was taken by Mr. J. O. Green, one of the house-pupils. 1866.

Dr. H. J. Bigelow.

1797. Aneurism of the left subclavian artery.

From a woman, æt. thirty-five. (Hospital, 75, 118.) There had been some numbness of the extremity for eleven months; and a tumor, which was 3 in. in diameter, had existed for seven months. Operation by Dr. B. The artery was dilated just outside the scalenus; and, to get at the sound part, one-third or more of this muscle was divided, and one-half of the mastoid. Instead of tying the ligature, a string of beads was run down upon it, so that the pressure

might be graduated. Pulsation returned in twenty-four hours, but the patient died four days after the operation from a rupture of the artery at the point of the ligature.

The sac is 4 or 5 inches in length, 1 or 2 in diameter, and was filled with recent coagulum. There was also a firm, rounded, and older coagulum, as seen in the preparation, toward the distal extremity of the sac, and resulting, it was thought, from the distal circulation. The ligature has been left about the vessel; and the rupture of the vessel is seen. 1857.

Dr. H. J. Bigelow.

1798. Thibert's model; aneurism at the elbow. 1847.

Dr. Geo. Hayward.

1799. An abscess between the œsophagus and left subclavian artery, and opening into each.

From a man, about thirty-five years of age, who, whilst eating his dinner, Nov. 13th, was seized with a sense of constriction in the œsophagus, at about the level of the upper edge of the sternum; and, though not conscious of having swallowed any hard substance, he was convinced that something was lodged in his throat. Probangs were passed with perfect ease, and again on the following day, with a sense of relief. On the 22d copious hemorrhage came on from the stomach and bowels, with faintness and great prostration; and, after having recurred a number of times, he died on the afternoon of the 24th. From the 14th he complained much of numbness, and loss of power in the left arm, and especially of the two middle fingers.

The abscess was 2 in. in length, with dark, loose, offensive walls; and contained, besides an offensive fluid of the same color, a shaving of wood, about three lines in length, one in breadth, and exceedingly thin. The opening into the œsophagus was $\frac{1}{4}$ in. in length, and $\frac{1}{2}$ in. below the lower edge of the thyroid; the one into the artery being two lines in diameter, and about an inch from the aorta. The abscess and the openings from it are marked by colored glass rods.

Dr. L. was quite sure that there had never been a bone in the throat, and could not account for the bit of wood that was found. (Med. Jour. Vol. LXIII. p. 403.) 1868.

Dr. G. H. Lyman.

1800. Cast in plaster, showing the external appearances in a case of circumscribed, traumatic aneurism just below the elbow.

The patient, who was forty-one years of age, and always healthy, was shovelling coal, when a large lump fell from his shovel as he was in the act of lifting it. Severe pain at the elbow instantly followed, obliging him to quit work; preventing sleep, and followed in ten days by swelling and discoloration. When this last subsided, at the end of three weeks, a tumor was discovered, as large as a small egg. On admission into the hospital (122, 74), Oct. 25th, and seven weeks after the accident, it was as large as a man's fist, and slowly increasing; the transverse diameter being double that of the longitudinal. It was elastic, but not fluctuating, sensitive, nor movable; pulsating feebly, and only on its inner side, with an aneurismal thrill, when examined with the stethoscope; not compressible, and not modified by compression of the artery above, except as to pulsation. There was no pulsation at the wrist, and the hand was sublivid, cold, and numb. On the 28th the tumor was exposed by an incision, and was found to consist wholly of recent coagula, contained within a circumscribed sac. These were turned out; and the artery, which lay superficially upon the tumor, was tied above and below an oval opening which involved about one-half the calibre of the vessel, as though a transverse rupture had occurred, the edges of which had subsequently separated. A small fibrinous clot protruded from each end of the artery at its point of rupture. The collateral circulation being in part established, there was a little bleeding from the sac of the aneurism; but, otherwise, no blood was lost. Nov. 3d the wound was granulating finely, and the ligatures came away, though pulsation had not returned at the wrist; and on the 12th he left the hospital. 1866.

Dr. R. M. Hodges.

1801. Popliteal aneurism cured by compression.

The patient, a weicher and ganger, forty-nine years of age, and a brother of Dr. O., was thrown from a wagon about the month of June, 1861, struck his left knee, and was laid up for two days. To this accident he always re-

ferred his disease, though he was quite well until Oct., 1865, when he first had pain in the left popliteal region. Early in Dec. a pulsating tumor was found there, about the size of a hen's egg; and by the end of the month it had increased to the size of a fist. About the first of Jan., Dr. O. commenced a system of compression of the femoral artery, and it was continued until the 20th of May, when all pulsation had ceased in the tumor. The compression was never entirely stopped but once, and then he suffered severely. The tumor, which seemed to be distended almost to bursting, began to subside in April, and did not exist in any marked degree during the last year, though the popliteal space remained filled out and the knee bent. Different means were used, but Dr. O. thought that digital compression, which was used during the last three weeks, was decidedly the best. Pain in the ham and down to the foot was very considerable before compression was used, and much more severe afterward, so that opiates were required; but there was none in the ham after the pulsation ceased, though it continued in the foot. There was swelling of the foot soon after the treatment was commenced, and it continued till Sept. In April, sloughing of the foot came on, but this at last did well. The patient was reduced from one hundred and forty to ninety pounds; lost a great deal of strength, and kept his bed until Sept., 1866, when he was able to get about on crutches; and even during the last year he was obliged to use a crutch and a cane. In Jan., 1868, he died of pneumonia.

In the preparation the sac is seen of a regular, elongated form, about $5\frac{1}{2}$ in. in length and $2\frac{1}{4}$ in. in diameter, and completely filled with decolorized, and rather crumbling fibrine. The femoral artery is somewhat diseased, and to the extent of about $1\frac{1}{3}$ in. above the sac there is complete obliteration. At the lower extremity of the sac, and within the cavity, some pus was found at the time of the dissection; there having been great pain in the part for three weeks before the pneumonia began. 1868.

Dr. John P. Ordway.

1802. The spleen, with its artery, preserved in spirit, and showing along the course of this vessel and its branches ten

defined, rounded dilatations, and varying in size from nearly two to six lines. They involve, generally, a portion only of the circumference; and, to some extent, the sacs were situated regularly along one side of the vessel. The parietes of most of them were thick, hard, and cretaceous; the cavity being more or less encroached upon, and in some nearly obliterated, though in a few it was well marked. Otherwise the artery was healthy, as was the spleen itself.

From an old woman, who died of ileus. 1856.

Dr. C. Ellis.

I have met with the above disease of the splenic artery quite a number of times, and am not aware that it has been described, if even noticed. It seems to be not very uncommon, and will probably explain the cases of phlebolites in the splenic vein that are occasionally referred to. (Med. Jour. Vol. LVI. p. 297.)

1803. A second specimen; dried. One sac ossified, and very greatly thickened where it has been cut through.

From an old woman, who died of cancer. 1859.

Dr. C. Ellis.

1804. A third specimen; in spirit; from the same patient as the last. Dilatation and ossification of the parietes of the artery are just commencing. 1859. *Dr. C. Ellis.*

1805. A fourth specimen; cut open and showing a small and quite defined aneurism, the parietes of which are ossified. — From an old woman who died of pneumonia. 1861.

Dr. D. W. Cheever.

1806. Aneurism of the right common iliac artery, about the size of a goose-egg; cut open, and shows that it is formed, mainly at least, by a dilatation of the parietes; also that it is filled with coagula. A small portion of the aorta, just above the sac, is seen to be diseased; and the ext. and int. iliacs just below it are dilated.

From a man who died of apoplexy. (Hospital, 251, 78.) 1862.

Dr. C. Ellis.

1807. A defined, rounded, aneurismal tumor, about as large as the fist, and situated at the left groin; the external iliac having been tied by Dr. W. One-half of the pelvis has been preserved, and the arteries, with the sac, are injected.

The patient was fifty-six years of age, unhealthy, and intemperate for many years. The tumor was of three or four months' duration; and rapidly increasing, during the last three weeks, with severe pain. Swelling of the limb also came on soon after the appearance of the tumor. On the second night he got out of bed in a fit of delirium, and on the following day he died, about fifty-four hours after the operation. (*Med. Jour.* Vol. xv. p. 309; and *Hospital*, 15, 82.) 1847. *Dr. J. C. Warren.*

1808. Thibert's model. "Aneurism of the inguinal artery in a child twelve years old," but with every appearance of a defined abscess. 1847. *Dr. G. Hayward.*

1809. Aneurism of the inguinal artery and ligature of the iliac.

The patient, a watchmaker, æt. thirty-two, and previously quite healthy, got a severe cold on the 15th of Sept., 1867, followed by constitutional symptoms. Dec. 10th he had cramp in the leg; afterward pain in the groin; and on the 14th a swelling there. On the 31st swelling seemed to give way in the groin, with a snap; the pain and swelling increased at once, with numbness down the leg, and a thrilling pulsation in the tumor. This last went on increasing; and, when he entered the hospital (134, 144), on the 6th of Jan., it was of an ovoid form 8 by 5 in., and thrilled strongly. There were lancinating pains throughout the limb, and insensibility from the ankle to the lower part of the thigh. Jan. 11th the external iliac was tied by Dr. B. On the 18th the patient began to sink, and on the 26th he died.

The original aneurismal cavity seemed to have been about the size of an English walnut; and the opening into it was $1\frac{1}{2}$ in. below Poupart's ligament, and 3 or 4 lines in extent. The sac having burst, there was found an effusion of nearly $\frac{3}{4}$ xi. of coagulated blood and fibrine into the surrounding parts, and as low as the middle of the thigh.

A very handsome dissection has been made by Mr. H. H. A. Beach, one of the house-pupils, of the diseased artery and its relations; and the preparation is shown in spirit. 1868. *Dr. H. J. Bigelow.*

1810. Thibert's model. "Aneurism of the popliteal artery; flexor tendons pushed aside." 1847.

Dr. G. Hayward.

1811. A cast in plaster of the hand and greater part of the upper extremity, from a case of varicose aneurism.

The patient, a girl, *æt.* nineteen, entered the hospital (76, 54) Oct. 21st, 1857. When two years old the palm of the hand was injured by a stone, and very shortly afterward a small pulsating tumor appeared there. About five years before entrance, and when first seen at the hospital, a large tumor seemed to be held in and to fill the palm of the hand; firm at some points, and soft and pulsating in others, with a strong aneurismal thrill on compression; the blood seeming, in some parts, to be contained in large aneurismal sacs, and in others in arteries as large as the carotid. There was also quite a firm tumor along the whole front of the forearm, under the muscles, but without pulsation. Amputation was advised, but refused; and a cast of the hand and forearm that is in the Med. Soc.'s Cabinet (No. 1425) was then taken. When seen the second time, the tumor in the palm and forearm had more than doubled in size, with a distinct aneurismal thrill along the brachial artery, a highly varicose state of the surrounding veins, and a sound like that of machinery in the palm. The arm was quite unwieldy, very painful at times, and the disease was rapidly increasing; the cast here shown being taken at this time. Amputation was performed Nov. 7th, about the middle of the arm, and nearly twenty vessels were tied; it being soon found that the veins carried arterial blood; a tourniquet, however, being applied quite high up and very tightly, an extremely small quantity of blood was lost. After a long convalescence the patient was discharged well, Dec. 24th, 1857; there never having been any hemorrhage nor any evidence of remaining erectile tissue. (See next specimen.) 1858.

Dr. J. M. Warren.

1812. The limb (see last specimen) was injected by Dr. H. J. Bigelow; the wax having been thrown in by the veins and returned by the arteries; and it was then dissected and prepared by Dr. R. M. Hodges. The muscles had disap-

peared, and nothing remained but the blood-vessels and a very dense fibro-cellular tissue. The whole of this last, however, was removed with very great care and skill, and the preparation now consists of the bones of the extremity and of the vessels only. The vessels are placed in their proper relation to each other and to the bones, which last are surrounded by the veins, as in a piece of basket-work; and the large and free communication between the arteries and veins is well shown upon the back of the hand and near the first metacarpal bone. The arteries and veins, generally, are only moderately enlarged; but, where they communicate, they are considerably so, though only for a short distance.

Dr. Bigelow imported Breschet's Memoir on Aneurisms (Paris, 1834), with reference to this case, and found that it would correspond to his "Varix arterielle;" the communication with the vein being a complication. 1858.

Dr. J. M. Warren.

1813. Thibert's model. "Erectile tumor formed by the radial artery and palmar arch." From birth. 1847.

Dr. G. Hayward.

1814-5. Daguerreotypes of a case of varicose arterial tumor.

The patient was a female, thirty-five years of age. (Hospital, 59, 211.) The tumor was of the size of a large hen's egg, directly over the right eye, projecting upon the forehead, and dipping beneath the orbit; surface convoluted, of a brilliant red, pulsating heavily, and filling to its utmost capacity in about three seconds after the blood had been pressed out of it as from a sponge. It was painless, of about twenty years' duration, gradually increasing, and originally near the hair, from which situation it seemed to have gravitated to its present position. Numerous dilated arteries radiated from its circumference. At the operation, the larger trunks were secured by ligature, but the tumor continued to fill with blood until nearly the whole periphery had been included in successive ligatures. With a view to its radical extirpation, it was then rapidly excised within the ligatures, when the exposed surface bled obstinately, and even after the use of the actual cautery. The wound healed rapidly; and the patient was discharged six weeks

and a half after the operation. (See next specimen.)
1858. *Dr. H. J. Bigelow.*

1816. A wax injection of the above tumor, from which the skin has been dissected, and which resembles in form, a solid bundle of common earth-worms. The convoluted arteries suddenly expanding and contracting, mutually to inosculate, were inextricably interwoven.

Dr. B. reports that he has seen two cases of this disease, in each of which the finger was affected; one of the patients was a young girl, and the other an old woman. He also refers to Breschet's description of the disease in the work above referred to. (No. 1812.) 1858.

Dr. H. J. Bigelow.

1817. Naevus, from the foot of a little girl two years old, who was brought to the hospital April 28th, 1868. (133, 232.) A tumor, of the size of a pullet's egg, occupied nearly the whole dorsum of the foot, and encroached upon the toes, of which the second and third were widely separated. It was very firm to the feel, adherent to the integument, scarcely movable, and occasionally exuded blood from a purplish spot upon the summit. There was no appearance of disease in the sole of the foot, and no pain; and the motions were not impaired. At birth, the tumor was bluish and equally large, but translucent and swayed about. It seemed to have undergone a spontaneous cure.

On the 29th it was removed, with the second and third toes, and was found to be quite defined; and on the 14th of May she was discharged well. 1868.

Dr. R. M. Hodges.

IV. VEINS.

1818. Cast in plaster of the entire lower extremity, and showing a varicose state of the superficial veins from the middle of the thigh to the dorsum of the foot; the other being similarly affected.

From a man, æt. sixty-eight, who had been subject to ulcers upon the legs for forty years. (Hospital, 125, 120.) Taken by the house-pupils. 1864.

Dr. H. J. Bigelow.

1819. Thibert's model. Veins of leg; varicose; from a woman, æt. sixty. 1847. *Dr. G. Hayward.*
1820. The same; upper back part of leg. 1847. *Dr. G. Hayward.*
- 1821-2. Superficial and deep-seated veins of the leg; varicose. From the same patient as No. 1835. 1856. *Dr. H. J. Bigelow.*
1823. Thibert's model. Veins of the spermatic cord and of the upper part of the thigh; varicose. 1847. *Dr. G. Hayward.*
1824. — Varicocele; tunica vaginalis laid open. 1847. *Dr. G. Hayward.*
1825. The same; veins injected. 1859. *Dr. R. M. Hodges.*
1826. A portion of the liver, in spirit, and showing a very great dilatation of the hepatic veins.
From a man, æt. forty-three, who died of organic disease of the heart of three years' and a half duration. (Hospital, 244, 206.) 1865. *Dr. C. Ellis.*
1827. Thibert's model. Erectile tumor of the int. labia; congenital. The veins were the seat of disease. 1847. *Dr. G. Hayward.*
1828. — Erectile tumor of the knee, in a child ten years of age; not congenital. 1847. *Dr. G. Hayward.*
1829. Portions of the iliac and femoral veins cut open, and showing the cavity completely filled with fibrine, most of which was very adherent. Vessel considerably thickened. Color of the fibrine in many parts yellowish, as in an old apoplectic clot. The vena cava was filled throughout with fibrine or more recent coagulum; and also the femoral veins, as far as they were examined, to the middle of the thigh. Along the course of the vessels, and apparently external to them, were three or four abscesses.
From a man, æt. forty, who entered the hospital (66, 8) July 30th, with a severe wound of the elbow, followed by delirium tremens. Aug. 19th, active constitutional symptoms came on, and he died on the 25th of Sept. There was great swelling from the first, and pitting on pressure,

but with scarcely ever any tenderness along the veins.
1856.

Dr. J. B. S. Jackson.

1830. The upper vena cava and its great branches dissected out and showing the effects of former phlebitis; the following appearances being noted in the recent state. Vena cava, very nearly from its termination in the heart, vena innominata, and left subclavian filled with a soft, pultaceous fibrine. Left jugular, to the extent of $\frac{1}{2}$ an inch, reduced to a cord $\frac{1}{3}$ of an inch in diameter, and filled with whitish, crumbling fibrine. The common trunk of the right jugular and subclavian was reduced to a cord $\frac{1}{4}$ of an inch in diameter, and filled with dense fibrine. The right subclavian, to the extent of $\frac{2}{3}$ of an inch from its origin, was more diseased than any other part, and so completely atrophied that it was with difficulty found, but the cavity was at last traced and laid open. Beyond these parts there was in the vessels coagulated blood and fibrine. Two veins upon the right side of the neck were most remarkably adherent to some extent by the inner surface, and formed a thick flat band, but without a trace of fibrine within. The fibrine had in several places more or less of an ochre-yellow color; but it could generally be separated from the inner surface of the vessels, and left this last with its natural polish.

The parietes of the veins were generally thick and opaque, and blended with the surrounding cellular tissue, where they were reduced to a cord. The vena azygos is seen cut off just at its termination in the great vein, and of full size, though a portion of fibrine lies loosely across its orifice. There was also recent coagulum and fibrine in the right ext. iliac vein and fibrinous deposits upon the inner surface of both auricles of the heart.

From a woman, æt. thirty-nine, who died at the hospital (133, 131), of general tuberculosis, after about a year's sickness; phlebitis having never been thought of. There was considerable œdema of the face and all four of the extremities; but this may have been owing to Bright's disease, which was well marked. 1849.

Dr. J. B. S. Jackson.

1831. Thibert's model. Inflammation of the veins of the spermatic cord. 1847.

Dr. G. Hayward.

1832. Pulmonary artery filled with an old clot from a short distance above the valves; and its branches upon the left side to the extent of about 4 in. Clot smooth, and in contact only with the vessel; except just beyond the great division, where it adhered slightly; rounded toward the valves. In the largest part were several cavities, containing a puriform fluid, which, as well as the substance of the clot, had a granular appearance, microscopically. Inner surface of the vessel healthy, excepting a loss of polish in some parts. The right branch contained a little old coagulum. In the preparation the vessel is cut open, and the cavities in the clot are shown.

From a woman, æt. sixty, who died at the hospital (225, 160), of phthisis; nothing having been observed that was particularly referable to the above appearances. 1860.

Dr. C. Ellis.

1833. Phlebolites, from various subjects. 1852.

Dr. J. B. S. Jackson.

1834. A small portion of the liver, showing the vena cava, where it passes through the organ, and also its branches, completely filled with soft, white, encephaloid substance; this organ, as well as others, containing a great amount of the same.

From a woman, æt. sixty, who had been out of health for several years. 1857.

Dr. H. R. Storer.

V. LYMPHATICS AND LACTEALS.

1835. Cast, in plaster, of a lower extremity, in which the lymphatics and the veins were enlarged.

From a man, æt. twenty-two, who entered the hospital (57, 16) Feb. 5th, 1853. For twelve years he had had swelling of the limb, with varicose veins, and frequent attacks of inflammation. Four and a half years before, he began to have an oozing of a milky-looking fluid from the skin, over the lower part of the leg. This last continued for a few days, with subsidence of the swelling, and during the following year it recurred every few weeks, but never afterward. Three years before entrance the inguinal glands began to be much swollen during the acute attacks, with

discharge from the popliteal space, which last continued from that time at intervals, and was increasing. The last acute attack was a year before; and he had kept his bed from that time.

On admission, the discharge amounted in three or four days to a pint, and was found to be coagulable. The limb was very much enlarged, flabby, and shrivelled about the knee, and covered with perspiration that had a sweetish odor; temperature considerably increased; lower two-thirds copper-colored. On several parts were clusters of bullæ that were but little elevated, and had a deep cavity beneath, so that they could be inverted; reappearing slowly when pressure was removed, and discharging a milky fluid when pricked. The discharge oozed guttatim, from a discolored spot on the ham a few lines in diameter; the surface of the skin not being indurated, elevated, nor broken. The inguinal glands were considerably enlarged, and the knee anchylosed. As to his general condition, the man looked bright, and reported himself as quite well, excepting the limb. In a few days spots appeared like those of erythema nodosum, and continued for some time; and in July red lines along the thigh were noted. In December, the thigh being very stiff, the adhesions were broken down; and he afterward exercised more freely about the wards. In June, 1854, he left the hospital, and in April, 1855, he returned; having had, meanwhile, about a dozen discharges from the limb. On the 19th of May the thigh was amputated at the upper third. The hemorrhage from the enlarged veins was so great that several of them were tied, and the patient died on the 31st, with tetanic symptoms.

On dissection, the whole limb was very œdematous; and enlarged lymphatics were seen, as before death, and especially upon the inner and posterior surfaces, and about the popliteal space. The bullæ, above referred to, marked the points where the lymph was confined, only by a thin, transparent cuticle, the rupture of which exposed its interior to the depth of a fourth of an inch in some cases. These cavities communicated with adjoining and similar ones by minute orifices in a dense and fibrous tissue, and these

again communicated with others; the whole forming a cavernous tissue like some old erectile tumor; the disease here being probably of the oldest date. The deeper lymphatics, and chiefly along the blood-vessels, were also dilated, and very regularly tortuous. The superficial veins were extensively varicose; and also, and to a very marked degree, the deep venæ comites (Nos. 1821-2). There was no inflammation of the limb, nor any other disease found after death. (See the four next specimens.) 1856.

Dr. H. J. Bigelow.

1836. Colored drawing, to show the lymphatics of the lower and inner part of the leg, in the above case; they having been injected by Dr. B., and the skin removed. The dilated vein is also shown. 1858. *Dr. H. J. Bigelow.*

1837-8. Daguerreotypes of the limbs from the above case; taken in May, 1855. 1858. *Dr. H. J. Bigelow.*

1839. A portion of the small intestine; dried, and showing a distension of the lacteals by tubercular matter. From a case of phthisis. 1858. *Dr. J. B. S. Jackson.*

Distension of the lacteals, in a case of cancerous disease; Thibert's model. (See No. 2219.)

1840. Mesenteric glands, from a case of typhoid fever; much enlarged and softened, and, when recent, reddened. From the same case as No. 2266. 1860. *Dr. C. Ellis.*

The same. Thibert's model. (See No. 2264.)

1841. Inguinal glands enlarged by venereal disease. A wax model. 1847. *Dr. J. C. Warren.*

1842. Abscess in the bronchial glands, communicating by three small openings with the left primary bronchus.

From a man, æt. fifty-nine, who was quite feeble, but died with very little local trouble. (Med. Jour. Vol. LIII. p. 167.) 1855. *Dr. C. Ellis.*

1843. Bronchial glands, enlarged and softened by tubercular disease; with a large and irregular opening into the right primary bronchus, just at its origin. 1867.

1844. Bronchial glands, softened by tubercular disease, and with an opening into the œsophagus, a line in diameter.

- From a man, æt. twenty-two, who died of phthisis. (Hospital, 229, 148.) 1860. *Dr. C. Ellis.*
1845. A large mass of mesenteric glands. The surrounding tissues having been dissected away, the individual glands are seen to be very much enlarged by tubercular disease. No. 2335 was from the same subject. 1860.
1846. Mesenteric glands, greatly enlarged by tubercular disease; with a portion of ulcerated intestine attached.
From a little girl, nine years of age, who died of general tuberculosis. 1857. *Dr. C. Ellis.*
1847. Mesenteric glands, extensively tubercular, and lacteals filled with the same deposit. From a Flat-head Indian. 1860.
1848. A collection of diseased axillary glands, about two-thirds as large as the fist. They hang like a bunch of grapes, and vary from the size of a pea to that of a pullet's egg. One has been cut open, and looks soft, but not curdy. 1847. *Dr. J. C. Warren.*
1849. A small quantity of white, friable, earthy matter. From a woman who had had enlarged cervical glands. Erysipelas came on; the glands supplicated, and this material was discharged, with much more subsequently. 1865. *Dr. F. F. Patch.*
1850. "Ossified" bronchial glands, from various subjects. 1858. *Dr. J. B. S. Jackson.*
1851. Mesenteric glands; ditto. 1859. *Dr. C. Ellis.*
1852. A portion of small intestine, inflated and dried; with the mesentery, and in this last a cretaceous mass, about as large as the top of the finger.
From a man, æt. thirty-seven, who died of acute phthisis, with the remains in the lungs of a former tubercular affection. (Hospital, 238, 154.) 1861. *Dr. J. B. S. Jackson.*
1853. A white, cretaceous mass, about as large as an English walnut; perhaps from the mesentery. 1847. *Dr. J. C. Warren.*
1854. A compact, cretaceous mass, about $\frac{1}{2}$ in. in length, and removed from beneath the skin over the neck of a healthy-

looking girl, eleven years of age. A swelling had existed for three years, and for the last year it had increased more rapidly; but never with any pain. 1869.

Dr. G. H. Gay.

1855. A specimen that was formerly in spirit, and then described as a heavy, defined, subcutaneous mass, of the consistence of hardened putty, but without any distinctly earthy deposit, $3\frac{3}{4}$ in. in length, by nearly 2 in. in diameter; and looking like the result of some former tubercular disease.

Having been dried, it was described by Dr. J. Bacon as organic in its composition. Dry and hard, but rather friable, and having a granular appearance. Color, dull grayish-white. Burned with the odor of burning ham, and left a minute white residue. A little phosphate of lime, after treatment with hydrochloric acid. In hot nitric acid it assumed a lemon-yellow color, and gas was evolved. No appreciable amount of fatty matter shown by ether. The chemical reactions were those of fibrine, or some proteine compound. Microscopically, it was seen to be wholly composed of nucleated cells, arranged in regular layers, in the manner of pavement epithelium. The cells were more or less distorted, probably from drying, but appeared to be epithelial in their character. 1847.

Dr. J. C. Warren.

1856. Diseased, subcutaneous glands, having a scirrhus appearance, forming altogether a mass as large as the fist. 1847.

Dr. J. C. Warren.

1857. A hard glandular mass, removed from the neck of a healthy-looking boy, eight years of age. The tumor had existed for a year, and grown very rapidly the last month; without any tendency to soften, but beginning to cause dyspnœa by pressure upon the nerves and trachea. It was as large as the two fists; extending from the ear to beneath the clavicle, and from the median line to the trapezius. Lobulated, movable, and feeling like a chain of glands; skin not adherent.

It was found to be situated mainly beneath, and partly behind, the mastoid muscle; and everywhere very strongly adherent. Microscopically, it was composed of uniform

cells, about two-thirds the size of the blood corpuscle, and filled with from four to six granular nuclei. There were a few spindle-shaped fibrous cells; but no larger cells, nor evidence of any malignant disease.

The boy recovered well, and it was thought that the disease would not return. (*Med. Jour.* Vol. LXXVIII. p. 259.) Eight months after the operation, however, the disease did return, and at the end of a year the tumor was two-thirds as large as before. Other glands were enlarged, with a failure of the general health, and the patient probably soon died. (*Med. Jour.* Vol. LXXII. p. 20.) 1863.

Dr. D. W. Cheever.

1858-9. Photographs of the above patient, before and after the operation. 1863.

1860. And the same, after the return of the disease. 1866.

Dr. D. W. Cheever.

1861. A collection of enlarged cervical glands, from a case of leucocythemia.

The patient, a boy, eight years old, entered the hospital Oct. 12th, 1864 (117, 174). Always quite healthy until a severe burn on the chest a year and a half before. Soon after recovery a tumor appeared just below the left ear, and steadily increased. He was anæmic, with two or three "scrofulous sores" on the head, and two irregularly lobulated, and quite movable tumors in the neck,—one just below the ear, and the other just above the clavicle. Spleen somewhat enlarged, and easily felt. Number of white corpuscles in the blood very little if at all increased. At the time of removal the glands were found in large numbers, extending in all directions, and even beneath the sternum; from the size of a pea to that of a pigeon's egg; and a few were left, as, from the loss of blood, and the patient's condition, it was not thought safe to prolong the operation. On the 26th the wound had nearly healed, and the boy left the hospital. 1864. *Dr. H. J. Bigelow.*

1862-3. Ambrotypes of the above case. 1864.

Dr. H. J. Bigelow.

SERIES XXIII.—NERVOUS SYSTEM.

I. BRAIN.

1864. A portion of the brain, showing the effects of a gun-shot injury.

From a soldier, who was wounded Aug. 30th. For the first three days he was about the wards during a part of the time, perfectly conscious, with a good appetite, and without pain; and insisted that a ball had not entered his head. Sept. 3d he was found comatose, and on the morning of the 5th he died.

A defined fracture of the frontal bone was found half an inch above the centre of the right supra-orbital ridge; and in the brain, where the ball entered, an abscess of the size of a walnut, with bits of bone. The ball had evidently traversed the whole length of the lateral ventricle, and entered the posterior hemisphere, from which last it dropped when the brain was removed. The parietes of the ventricle were considerably abraded, and infiltrated with pus, as was the brain along the track of the ball. It was supposed that the ball penetrated no deeper than the anterior portion of the brain at first, but that it subsequently gravitated to where it was at last found. 1863.

Dr. Francis H. Brown.

The following nine models by Thibert were presented in 1849.

Dr. John Ware.

1865. Brain congested, with small drops of blood upon the cut surface.

1866. Three separate and defined effusions of blood, on section of brain.

1867. A larger effusion.

1868. Large effusion into the left ventricle.

1869. Very extensive and defined capillary apoplexy upon the surface of the convexity of the brain. The membranes are stripped off, the convolutions are flattened or effaced, and the surface is of a dark, purplish-red color.

1870. Inflammation of the substance of the brain. A mottled

rosy tint on section, with an appearance of swelling of the organ.

1871. Appearances very similar to the last.
1872. Purulent effusion into the cortical substance ; seen through the injected membranes.
1873. Several defined, rounded abscesses near the surface of the brain.
1874. A defined, chronic abscess in the posterior portion of the brain.

The patient, a lad, thirteen years of age, entered the hospital Sept. 18th, 1843 (27, 132). In May, of the same year, he had "typhoid fever," and headache from that time; pain mostly in the forehead, and not severe until the last of June. In June there was dimness of vision, and ever afterward. From July 10th till Aug. 9th he was in the country, and able to play about somewhat. About the middle of July he was struck upon the back of the head by an andiron. The accident was a slight one, but in about a week a swelling appeared over the occiput, and on the 13th of September it was opened and discharged slightly. During the last three or four weeks he had daily attacks of general tremulousness, with much excitement, and commencing with pain in the back of the neck. Never any loss of consciousness, convulsions, or paralysis. Stomach sufficiently well. Death almost instantaneous the morning after his entrance into the hospital.

The abscess is in the very posterior part of the left hemisphere of the brain, of a regular circular form, and contained $\frac{3}{4}$ iv. of healthy-looking pus. A sort of cyst, that lined the cavity, is most remarkably distinct, and was readily separable from the surrounding parts; about half a line in thickness, moderately firm, not fibrous, not generally opaque, a little reddened in some parts, without any trace of lymph, and somewhat resembling a mucous surface, as Lallemand remarked that it may be in such cases after some years. The cerebral substance, anteriorly, was somewhat gelatiniform, and in some parts, just around the abscess, it was very soft and disorganized. The brain, generally,

was swollen and rather firm. Ventricles large; with serous effusion; membranes remarkably free from moisture; strongly adherent to dura mater, over the abscess, to the extent of about $1\frac{1}{2}$ lines, with a direct opening through the bone (No. 1279), between the abscess within and the one external to the bone. 1847.

Dr. J. C. Warren.

I published the above case, with eight others, of abscess of the brain, in the *Med. Jour.* Vol. LXXII. p. 353.

II. MEMBRANES.

Four models by Thibert. 1849. *Dr. J. Ware.*

1875. Uniform redness from congestion of the membranes over the convexity of the brain.
1876. Small effusion of blood at the base.
1877. Extensive effusion of blood into the membranes at the base of the brain.
1878. The same appearances as in the last.
1879. Cysts from the arachnoid cavity, and in connection with meningeal apoplexy.

The patient, æt. sixty-five, received a severe blow upon the back of the head and neck, in July, 1857, and had pain from that time. July 14th, 1858, he entered the hospital (217, 188), with his memory much impaired, but having never had paralysis nor anything like an apoplectic attack. His health had been rapidly failing for the last few weeks, and he died comatose, July 26th.

The cysts, which extended nearly from the longitudinal sinus to the base of the brain, were thick, firm, and opaque. One upon the right side contained about two ounces of thin blood, and soft, blackish coagula, with some yellowish fibrine adhering to the inner surfaces. Within about an inch of the periphery, and all around, the two walls united, and then, as a single layer, became thinner until they were gradually lost in the dura mater. Upon the left side, the walls of the cavity seemed to have been in contact. Both hemispheres were flattened beneath the cysts, which adhered very slightly, if at all, to the arachnoid, but pretty firmly to the dura mater. The brain was healthy.

See Mr. P. Hewett's article in the *Med. Chir. Trans.*, Vol. xxviii.,—also a case with a figure, in the *Trans. of the Patholog. Soc. of London*, and in which a large cyst lay loose in the arachnoid cavity. 1859.

Dr. C. Ellis.

Four models by Thibert. 1849.

Dr. J. Ware.

1880. Acute inflammation of the membranes over the convexity of the brain.

1881. Extensive formation of false membrane over the convexity, and in defined, thick, white patches; the result of chronic inflammation.

1882. Acute inflammation of the membranes at the base of the brain, with purulent effusion.

1883. Tubercular meningitis. Very extensive acute inflammation of the membranes at the base of the brain; with granulations of the same.

1884. Cysts in the plexus choroides upon each side.

From a man, *æt.* forty, who had been long subject to "nervous headache," and who died from an effusion of blood into the pons varolii. 1852.

Dr. J. B. S. Jackson.

1885. Plexus choroides cut open and dried; and which, in the recent state, contained a firm yellowish, oval body, more than $\frac{1}{2}$ an inch long, and consisting of cretaceous matter and fibroid tissue.

From a man, *æt.* sixty-three, who died at the hospital of phthisis (217, 162); and with some minute granulations in the pia mater about the cerebellum.

1886. Mate to the last and similarly affected; in spirit. 1858.

Dr. C. Ellis.

1887. Hydrocephalic skull of a child between two and three years old. Anterior fontanelle quite large, but ossification is otherwise complete, excepting some Wormian bones. Greatest circumference $24\frac{1}{2}$ in.; and from one meatus to the other, over the top of the head, $17\frac{1}{2}$ in. Internal capacity 188 cubic inches,—measured with rice; the mean int. capacity of fifty-two adult Caucasian skulls being, according to Dr. Morton, 87 cubic inches. This specimen belonged to

the anatomical collection of the first Dr. John Jeffries, the grandfather of Dr. J. 1865. *Dr. B. Joy Jeffries.*

1888. A second specimen. From a patient of Mr. B.; and the following facts in the case were obtained by him, chiefly from the mother, but partly from his own observation.

“The child, a female, was three years old, to within a month, at the time of its death, which was occasioned by a slight diarrhœa of a week’s duration. The head was about twice the natural size at birth, and the anterior fontanelle very large; the enlargement increasing gradually, so that about a week before death it measured in its greatest circumference $27\frac{3}{4}$ inches. It was never able to sit up and support the head, nor even to turn it from the left side, upon which it always lay. It never spoke, and seemed to have no intelligence. The vision was always very imperfect, and occasionally quite lost; and there was also a slight strabismus from birth. For a time there was slight deafness, but this increased; so that it could only hear when the mother spoke in a very loud tone of voice. It slept generally not more than one and a half in twenty-four hours; and was very restless, moaning much of the time, as from distress, and requiring a free use of opiates, but not crying out as from sharp pain. Never convulsed. Fæces generally passed involuntarily, and sometimes the urine. In regard to its general health, it was feeble, thin, and pale, but sufficiently warm; nursed its mother heartily until the time of its death, and took cow’s milk, but never any solid food.

“On examination, which Mr. B. made alone, he found the cranial cavity filled with serum, and the cerebellum sufficiently natural in appearance; but of the cerebrum he found very little remains.

“The specimen, which is an uncommonly fine one, and was very finely prepared by Mr. B., shows all the characteristics of a hydrocephalic skull,—the great disproportion between the facial portion and the vault of the cranium,—the thinness of this last and the great deficiency of bone in place of the anterior fontanelle,—the disappearance of the supra-orbital ridge, and the numerous Wormian bones, one of which is of large size. Sutures deeply serrated.

The greatest circumference is 27 in.; and from one auditory meatus to the other, over the top of the head, and allowing for the deficiency at the anterior fontanelle, it measures $20\frac{1}{2}$ in. Internal capacity 257 cubic inches." 1866. *Mr. Walter C. Blaisdell, med. student.*

1889. A third specimen, with the following history of the case by Dr. S.:

"It was the cranium of a girl born in this city. Becoming an orphan at a very early age, she was admitted to the House of Industry, where she was instructed in the usual branches of knowledge taught in our common schools, until at length, such was her capacity, she was entrusted with the teaching of the other pauper children. She was of excellent character for intelligence and moral worth, and gave much satisfaction to the officers of the House. Being fitted, as was thought by the Directors, to earn her own support, she was discharged from the House, and found employment in a private family in the city. Here, from exposure incident to her situation, she contracted a cough. A decline soon followed, and she was compelled to return to the House, where at last she died of consumption, at the age of sixteen.

"The skull measures $24\frac{1}{4}$ in. in its circumference, and over the head, from one auditory meatus to the other, $17\frac{1}{4}$ in. There is nowhere any deficiency of bone, and yet it is in no place more than $\frac{1}{8}$ of an inch in thickness. Its greatest diameter is from the centre of one parietal bone to the other, but presents no unseemly deformity.

"On examination after death, the brain was found floating, as it were, in a large collection of water, throughout which many patches of lymph apparently were diffused.

"She died peacefully, and retained her consciousness as long as she was able to respire." Internal capacity 176 cubic inches. 1866. *Dr. Charles H. Stedman.*

1890. A fourth specimen; bones of the vault separated, and imperfectly developed. The head was very large, and felt like a loose bag; the fluid being in the lateral ventricles, which formed one enormous cavity. There was also spina bifida (No. 851), and the right lower extremity was imperfectly developed, besides varus and irregularity of toes.

Internal organs well. Male, and born at full period, though the testicles were above the groin. The breech presented, and a hook was required to remove the head. 1848. *Dr. J. B. S. Jackson.*

The three following casts of hydrocephalic subjects are from the phrenological collection, and the two last from the collections of Dr. Spurzheim and Mr. Holm. 1847.

Dr. J. C. Warren.

1891. Head of a young child.

1892. Head of an older child.

1893. Distended brain.

1894. Drawing of a hydrocephalic child; head of an enormous size. Copied from a drawing in the Med. Soc.'s Cabinet; and this last from the well-known drawing of Mr. Cruikshank's case in the Museum of the Coll. of Surgeons, London. 1861. *Museum Fund.*

1895. Dura mater, ossified along the longitudinal sinus.

From a female dissecting subject, twenty-five or thirty years of age, who was said to have died of epilepsy. 1859.

Dr. R. M. Hodges.

1896. A second specimen. 1853. *Dr. J. B. S. Jackson.*

1897. A third and large mass, $2\frac{1}{2}$ in. in length. From a man, sixty-seven years of age. 1868.

Dr. R. M. Hodges.

1898. A fourth. Extensive ossification along the longitudinal sinus. Preserved in connection, with a portion of the calvaria.—From an old man. 1869.

Dr. H. H. A. Beach.

The formation in the above cases consists of true bone.

1899. A cretaceous tumor, that arose from the inner surface of the dura mater, and pressed in upon, but did not adhere to, the brain. This last was healthy, as were the membranes, excepting some serous effusion. The tumor, of which a portion has been removed, must have been about as large as the top of the thumb; consists of the carb. of lime, and the structure is light and crumbling.

From an old lady, æt. seventy-two, who had had disease of the heart, and for several years had complained of

numbness of the fingers and thumbs, but never of headache. Unable to control her evacuations the last few days, though conscious. Convulsions, with coma, came on at last, and she died in the course of the day. 1867. *Dr. C. Ellis.*

1900. Cancerous growth, from the outer surface of dura mater. (See No. 1512.) 1859. *Dr. C. Ellis.*

1901. An extensive, epithelial, cancerous growth, from the outer surface of the dura mater.

From a man, who was an exhibitor of wild animals. At about the age of two years the top of his head was severely burned, and bone came away, leaving an opening about an inch in diameter. From that time there was a constant discharge until about seven years before his death, when a grizzly bear tore his scalp down over his eyes. His head then healed, and continued so until two years before death, when a "man-monkey" clawed, bit, and tore it open again. The epithelial disease then appeared, rose an inch above the surrounding surface, and looked like the crest of a fowl; the extent being 4 by $3\frac{1}{2}$ in. Pain, hemorrhage, convulsions, and at last hemiplegia were the consequences.

The bone was extensively destroyed (No. 1525); and an abscess was found in the brain beneath the seat of the disease. (*Med. Jour. Vol. LXIII. p. 414.*) 1861.

Dr. J. H. Warren, of Dorchester.

For other cases of cancerous disease, connected with the dura mater, see Nos. 1502 and 1506.

III. SPINAL CORD AND MEMBRANES.

Six models, by Thibert. 1849. *Dr. J. Ware.*

1902. Apoplexy of the spinal cord, with inflammation of its substance.

1903. Inflammation of the cord, with an extensive and defined purulent deposit.

1904. Inflammation, with softening of the cord.

1905. Cancerous disease of the cord.

1906. Increase of the cerebro-spinal fluid.

1907. Acute inflammation of the membranes of the cord.

IV. NERVES.

1908. A portion of the lower jaw, removed from the articulation to about one-fourth of an inch beyond the angle, in a case of very intense neuralgia.

The patient was a man, thirty-two years of age, who had suffered the greatest agony from the disease, for twelve or thirteen years. About the year 1860 the infra-orbital and one other nerve of the face were divided. In 1861 and again in 1863 a portion of the lower jaw and of the nerve were removed at the hospital; and in 1864 the facial nerve was freely divided. June 24th, 1869, he again entered the hospital (140, 183). On the 30th the bone was removed; and the nerve, as nearly as possible, to its exit, from the base of the skull; the hemorrhage being very copious. There was a loss of motion and sensibility in the side of the face; and on the 3d of July, and again on the 4th, there was a return of very severe pain. There was no more, however, after this last date, and on the 13th he was discharged.

The surface of the bone is somewhat irregular, but healthy, and the opening that resulted from the former operations is about $\frac{7}{8}$ by $\frac{1}{8}$ in. Dec. 9th, the man reports no pain since operation, but face continues paralyzed. 1869.

Dr. R. M. Hodges.

1909. Neuromatous tumors about a stump.

The patient was a young man, eighteen years of age, who had his arm amputated when he was nine years old. For the first two years he had a good stump, and then the bone began to project. On admission into the hospital (115, 54), the integument was thin, and shining over it to the extent of an inch, but the cicatrix was not involved. There was severe pain, and the tumors were easily felt. Two inches and a half of the bone were removed, with a part of the integument, — the bone tapering to a point. All of the nerves terminated in large bulbous tumors; and a bursa over the end of the bone contained a great number of minute loose bodies. The relief was perfect.

Dr. H. regarded this, not as a common conical stump, but as a case in which the bone grew with the lad's growth;

and he referred to several such cases in his work on Excision of the Joints. (Med. Jour. Vol. LXX. p. 499.) 1864.

Dr. R. M. Hodges.

1910-11. A neuralgic stump.

Aug. 24th, 1867, the patient fractured his arm and forearm, and amputation was performed below the elbow. Nov. 10th he entered the hospital (134, 84), with pain shooting up from the stump, anteriorly and posteriorly; and on the 7th of Dec. a second amputation was performed at the junction of the middle and lower thirds of the humerus. The wound suppurated; and on the 28th of January, when it had nearly or quite healed, he reported that he had had for some days a deep-seated pain in the middle of the humerus, which was the seat of the fracture. This pain continued to be so severe, that on the 22d of Feb. a third amputation was performed at the upper part of the bone; and the musculo-spiral nerve was found caught between the fragments of the broken bone, so that it could not be withdrawn, as shown in the second specimen. Both specimens are preserved in spirit, and show the connection of the nerves with the cicatrix below the elbow, and with the fractured humerus. 1868.

Dr. H. J. Bigelow.

SERIES XXIV. — SKIN AND INTEGUMENTS.

Many of the specimens in this series may perhaps have been as appropriately entered in Series No. XXI.

1912. Emphysema of the cellular tissue beneath the sternum; a dry preparation. The anterior portion of the lungs was quite extensively affected with interlobular emphysema, and the rest did not collapse on incision.

From a man, æt. twenty-two years, who died of acute inflammation of the joints. (Hospital, 218, 80.) 1858.

Dr. J. B. S. Jackson.

The next forty-six models, by Thibert, were presented in 1847.

Dr. Geo. Hayward.

1913. Punctured wound above the elbow ; tissues inflamed.
1914. The same, upon the dorsum of the foot ; phlegmonous abscess.
1915. The same, upon the front of the leg ; with gangrene.
1916. Gunshot wound in the forehead ; parts contused and torn.
1917. The same, of the knee. Parts extensively injured, with surrounding inflammation.
1918. The same, of the leg ; with extensive inflammation and gangrene.
1919. Contusion of the forearm ; ecchymosed, but the skin is not broken.
1920. The same, of the forehead, from a fall.
1921. The same, of the calf of the leg, with extensive gangrene.
1922. The same, of the foot, with gangrene.
1923. Contusion of the leg.
1924. The same, over the side, with much surrounding inflammation.
1925. Foot crushed. Surface of wounds bathed with pus ; ulceration burrowing.
1926. Suppurating wound of the scalp ; surface covered with healthy granulations.
1927. The same, over the tibia ; cicatrization arrested by inflammation of the subjacent parts.
1928. The same, over outside of knee ; suppuration suppressed by some internal derangement.
1929. The same, of the forearm ; completely indolent, with an abundant serous exudation ; parts swollen, white, and cedematous.
1930. Ulcer ; inflammatory.
1931. The same, over the outer ankle ; chronic, and apparently indolent, but not particularly foul.
1932. The same ; gangrenous, as seen in old persons.
1933. The same, in an old person, over the outer ankle ; with retraction of the little toe.

1934. The same, over front of leg, midway ; callous.
1935. The same. A large ulcer over inner ankle, and several quite small ones above it ; fungous.
1936. The same, upon cubital edge of forearm ; scrofulous.
1937. The same ; one large ulcer over inner ankle, and two small cicatrices above it ; " scorbutic."
1938. The same, upon lower part of leg ; " dartsous."
1939. The same ; varicose.
1940. Several openings over front of leg, with much inflammation about them ; connected with syphilitic inflammation of the bone and periosteum.
1941. Burn over the thigh ; skin reddened.
1942. The same ; arm and elbow ; vesication.
1943. The same, on the shoulder ; surface suppurating.
1944. The same, on the leg ; parts more deeply affected than in the last.
1945. The same ; lower extremity ; destruction of the integuments.
1946. The same ; foot of a child ; tissues charred.
1947. Phlegmonous inflammation of skin, and integuments of thigh.
1948. The same, of cellular tissue of forearm, after amputation ; swelling, with suppuration.
1949. The same, of tendinous sheaths of foot, with swelling and gangrene ; sloughs separating.
1950. The same ; acute abscess over elbow and forearm.
1951. Boils upon the forearm ; of different sizes and degrees of inflammation.
1952. The same, over the hip ; one opening.
1953. The same, upon the thigh of a child ; with gangrene of the skin and tissues. Deep and extensive discoloration of the inner surface ; the skin, however, not being broken.
- Psoas and lumbar abscess, connected with caries of the vertebræ. See Nos. 1381-2.
1954. Carbuncle, with gangrenous eschar. Simple form of carbuncular inflammation ; upon anterior and outer portion of leg.

1955. The same, over shoulder. Three openings have formed upon the inflamed surface, and show the sloughs beneath, with foul discharge.
1956. The same, after incision. Integuments destroyed.
1957. Hospital gangrene; leg affected.
1958. Gangrenous ulceration over the sacrum, in a case of typhoid fever.
1959. Thibert's model. Sloughing of the skin and integuments, in case of typhoid fever. 1849. *Dr. J. Ware.*
1960. The same, of a blistered surface in typhoid fever. 1849. *Dr. J. Ware.*
 Nine models, by Thibert. 1847. *Dr. G. Hayward.*
1961. Malignant pustule, upon the back of the hand. Just commencing.
1962. The same, in the region of the clavicle. Tissues œdematous.
1963. The same, in the cheek; gangrenous.
1964. Bite of a viper, upon the edge of the hand. Simple and limited inflammation just after the accident.
1965. The same, upon the dorsum of the foot. Swelling, with lurid spots; just after the accident.
1966. The same, in the groin and thigh; gangrenous.
1967. Cicatrization of a simple wound, over the back of the hand. Surface smooth.
1968. The same; deep wound after removal of the clavicle. Surface depressed.
1969. The same, over tibia; loss of substance, and surface irregular.
1970. A small portion of skin, dissected from about the umbilicus of a negro, and showing the entire absence of cicatrix. 1858. *Dr. R. M. Hodges.*
1971. A cast, in plaster, showing a very extensive cicatrix after a burn.

The patient was a girl, nineteen years of age, and the accident happened twelve years before; the chin and surface of the chest becoming united as the parts cicatrized. The under lip was completely everted, the lower jaw very

much elongated, and the lower front teeth projected almost horizontally forward. An operation was performed for her relief Feb. 26th, 1842; laryngitis came on April 13th, and she died on the 25th.

The cast was taken after death, and shows the face and upper half of the chest. (Hospital, 24, 133.) 1847.

Dr. J. C. Warren.

1972. A second cast of the neck, lower part of the face, and upper part of the chest.

A little girl, æt. seven years, was burned seventeen months before entrance into the hospital (54, 18). The chin was drawn down nearly to the sternum, and obliquely toward one side; lower lip drawn out of place, and jaw distorted. An operation was performed, but at the end of three months she was discharged without much relief. Cast taken before the operation by Mr. T. H. Gage, one of the house-pupils. 1852.

Dr. J. M. Warren.

1973. A cast, in plaster, of the elbow, showing a contraction from burn, three years before.

The patient was nine years of age; and the forearm could be extended upon the arm, to an angle of 80°. Feb. 28th an autoplasmic operation was performed by Dr. Hodges; a portion of skin being brought down from the outside of the arm. May 2d the transplanted portion had united well; but, the angle at the elbow being about the same, a second operation was performed, in which a piece of skin was taken from the side of the chest. This last, however, united but very imperfectly; and the patient left the hospital (120, 238) on the 18th of July, without much improvement. The cast was taken soon after her entrance. 1866.

Dr. R. M. Hodges.

1974. A very large cicatrix, dissected out from the face.—

• From a laboring man, æt. twenty-one years. Fifteen months before, he had severe inflammation of the cheek, from a bad tooth, resulting in abscess, and followed by a deep, puckered cicatrix. The deformity was perfectly relieved. (Hospital, 77, 230.)

Dr. H. J. Bigelow.

For great distortion of the foot, resulting from cicatrization, and this last from external injury, see No. 2030.

1975. A portion of the scrotum is shown, the discoloration of which was very striking. Upon the face, neck, and arms, it was also quite marked; and upon the serous surface, as figured by Dr. Addison.

From a male dissecting-room subject, who was said to have died from old age; the renal capsules, as well as the other organs, being healthy. (Med. Jour. Vol. LVIII. p. 20.) 1858. *Dr. R. M. Hodges.*

1976. A second specimen; and, decomposition having commenced, the cuticle is partially detached, and the cutis itself is seen to be quite colorless.

From a man, æt. seventy-five years, who died suddenly, and had complained only of debility. The discoloration of the forearms and genitals was strongly marked, and more or less so upon the face, legs, and abdomen; spots irregular, but distinct in outline.

The renal capsules, which are shown with a portion of the skin, are not more than half as large as usual, though not diseased, so far as appears externally; the right weighing 36 gr. and the left 44. (Med. Jour. Vol. LVIII. p. 19.) 1859. *Dr. R. M. Hodges.*

Diseases of the renal capsules in Series XL:

1977. Thibert's model. Rose spots, as they appear in typhoid fever towards the ninth day. 1849. *Dr. J. Ware.*

1978. —. Sudamina of typhoid fever. 1849.

Dr. J. Ware.

1979. A wax model, showing a form of erythema upon the leg. From Paris. 1860. *Dr. Geo. C. Shattuck.*

Seven wax models; from Paris. 1847.

Dr. J. C. Warren.

1980. Marked "Lichen"; but Dr. J. C. White thinks that it looks like the leg of an old person, that may have been affected with pruritus, and had been severely scratched, producing papules, but much larger than those of lichen.

1981. Old psoriasis, with recent eczema along the front.

1982. Psoriasis upon the upper extremity.

1983. Variola over the face.

Variolus eruption in trachea. (See No. 2126.)

1984. Seborrhœa of the face, according to Dr. White; an inflammation of the follicles, and pouring out of a fluid that concretes.

1985. Sycosis; the region of the beard being affected, as usual.

1986. Favus upon the scalp. Marked "porrigo."

1987. A mouse, affected with favus.

The specimen has been examined by Dr. White, who describes the whole head as nearly concealed by a parasitic, vegetable fungus (*achorion Schönleini*), and which he considered as the cause of the disease; the honey-comb form, color, odor, and mealy consistence being the same as when the disease is seen in the human subject; and the fungus the same, as he showed by the microscope. — Within the last three months twenty other mice, that were killed in the same store, were said to have had the disease, and in some of them it extended to other parts of the body; the cat that killed them being, meanwhile, unaffected. (Med. Jour. Vol. LXIV. p. 395.) 1862.

Mr. S. W. Abbott, med. student.

1988. A second, and very much finer specimen; in the same jar with the last. 1867.

Dr. H. O. Marcy, of Cambridgeport.

1989. Skin of the scrotum, dried, and showing numerous, rounded bodies, on an average about as large as a pea, and which, when recent, were evidently cretaceous to a considerable extent. Probably a follicular disease. 1858.

Dr. R. M. Hodges.

1990. Thirteen little cretaceous bodies, from the integuments over the front and very lower part of the legs; of a flattened and rounded form, yellow color, nearly smooth, and, on an average, about a line in diameter. In the recent state some were soft and crumbling. They were not connected with the veins, and the structure was not concentric. Analyzed by Dr. Bacon, and found to consist of the phosphate and carb. of lime, with some animal matter. From an adult negress. (Amer. Jour. of Med. Sc., April, 1855.) 1855.

Dr. R. M. Hodges.

1991. Seven or eight very light bodies from the size of the tip of the little finger, to that of the thumb, and referred to by Dr. Warren, in his work on Tumors (p. 19), under the head of Icthyosis cornea.

From a girl, æt. fourteen. — Examined by Dr. White, who made out epidermal scales on their exterior. 1847.

Dr. J. C. Warren.

1992. A fleshy excrescence, about as large as the top of the thumb, and arising from the scalp; scarcely covered by cutis, and resulted, perhaps, from a sebaceous follicle. 1847.

Dr. J. C. Warren.

1993. An excrescence, smaller than the last, and having, perhaps, the same origin. 1847.

Dr. J. C. Warren.

1994. A soft, shrivelled, brownish, cutaneous excrescence, about the size of the top of the finger. 1847.

Dr. J. C. Warren.

1995. A wax model of the face, showing a horny growth from the forehead, about 10 in. in length, and $1\frac{1}{2}$ in. in diameter at the largest part. From Paris, and well known in anatomical museums. In 1845, Dr. J. M. Warren received from old Dr. Souberbelle, of P., a history of this case; and, having translated the manuscript, it was published for the first time in the American Jour. of Med. Sciences, Jan. 1851.

The patient was eighty-two years of age; the horn had been growing for six years, and was readily removed by Dr. S. A small one is seen upon one of the cheeks; and she had formerly had one removed from the hand. 1847.

Dr. J. C. Warren.

1996. Cast, in plaster, of a horn that grew from just above the eyebrow of an old woman, ninety-two years of age, and that was of six years' duration. The form was conical, and the extremity curved downward; length, along its convexity, $3\frac{7}{8}$ in. Base soft, and bulging; the circumference being $4\frac{7}{8}$ in. The rest of the growth was hard to the feel, fibrous in appearance, and grooved upon the surface. Several similar growths existed upon different parts of the face, elsewhere, but none of them projected more than a line or two; two of these are shown upon the cast. A few

months after this last was taken, the inflammation that previously existed about the growth, increased; and, after poulticing it for some weeks, the dense portion was thrown off. (See next specimen.) Ulceration of the base followed; and, at the end of a year from the time when the patient was first seen, it had extended over a large portion of the forehead, and had all the appearance of an epithelial cancer. The grandmother of this patient was said to have had a cutaneous horn in the same position as in the above case, and that terminated in cancer. The above history is from a detailed account, with a figure of the case, by Dr. D. in the *Med. Jour.* Vol. LXXIV. p. 9. 1866.

Dr. Silas Durkee.

1997. The horn above described. 1866.

Dr. R. L. Hodgdon, of W. Cambridge.

1998. Horn removed from a cicatrix.

From a man, thirty years of age, who had had both of his hands amputated through the metacarpal bones when he was six years old. At the age of twenty-five years the horn began to grow from one of the stumps; and, as the man thought, from the irritation of a strap that he wore. About a year before his admission into the hospital, on the 11th of August (140, 232), the horn was removed; its dimensions being then 3 in. or more by 1 in. In four or five months it reappeared; and, when seen by Dr. H., it was about 2 in. in height, $1\frac{1}{2}$ in. transversely at the base, $\frac{1}{2}$ in. at the apex, and curving towards the radial edge of the hand. The cicatricial tissue over both stumps was very tense; and at the base of the horn it was inflamed, and occasionally ulcerated. After the horn was removed, the investing membrane was dissected off from the stump, the ends of the metacarpal bones were sawed off, and the man left the hospital on the 26th.

For some years before the formation of the horn this man had supported himself as a clerk, and held his pen between the two stumps as he wrote.

Since the above was in type, a note has been received from the patient, dated Dec. 28th, and saying that the horn has once more returned. The note was written in a

flowing, flourishing hand, and was accompanied with specimens of his writing, which will be preserved in the museum. "A more formal handwriting it takes him much longer to write." 1869.

Dr. R. M. Hodges.

1999. A horn, removed by Dr. C. from near the chin of a half-witted lad, nineteen years of age. Duration of the growth eight years.

The following description was given of it by Dr. H. J. Bigelow:—

"The growth is a blunt cone, 2 in. long, by an inch and a half at the base, and split into two parts, with a third smaller division at the root. It is roughly striated, lengthwise, hard at the point, and softer at its insertion, emitting also the fœtor of epidermic secretion.

"On section, a limited, epidermic, columnar structure is seen sprouting from a dense fibrous tissue beneath the base. The structure is irregular, and broken at intervals, but is harder and drier as it approaches the surface and summit. Microscopically, the whole is a mass of epidermic scales and nuclei, originally arranged in papillary form, of the probable growth of which the following will give an idea. A central body of nuclei in each papilla grows out from the skin, its top and sides developed into concentric scales, by which it is, as it were, shingled and slated. This outer layer is raised by another beneath, which in its turn is elevated by a third, so that the section of a papilla resembles a pile of inverted cups, of which the centre is occupied by nuclei, and the sides by more developed scales.

"Drying as it grows, the hardened extremity of this so-called 'horn' consists almost wholly of epidermic plates, while the interior of its soft base is filled with papillary growth, containing nuclei. At the line of insertion of the whole mass, nuclei are abundant, entangled in fibrous tissue. This epidermic structure has some affinity to that of horn, but in its papillæ and columnar arrangement more resembles epitheloid cancer, without the globes characteristic of that growth." 1862.

Dr. H. G. Clark.

2000. A horn, removed from the prolabium of the lower lip; it

is about 1 in. in length, and $\frac{1}{4}$ of an inch in diameter; and by its side is a second, about as long.

The patient was a man, thirty-one years of age. Duration of the disease nine years. At the end of three years it had reached its present size, and was removed for the first time. The rest of the lip was healthy. (Hospital, 116, 18.)

An aunt of the patient had had a horn removed from her side; and Dr. H. remarked upon the fact, as adding confirmation to the relation between horns and epithelial cancer, as has been pointed out by Mr. Paget. 1864.

Dr. R. M. Hodges.

2001. Cast of a leg affected with elephantiasis; taken after death. The limb, removed at the knee-joint, weighed fifty-two pounds, after losing much of the serum, with which it was infiltrated. At the largest part it measures $16\frac{1}{2}$ in. transversely; but just above the ankle, and also below the knee, it very suddenly diminished, and the foot is of the natural size; not much extension above the knee, — the greater part of the mass by far being upon the back of the leg. The surface, to a large extent, was rough from the collection of sebaceous matter or epidermis, cracked, in some parts excoriated, discolored, and brawny to the feel. The skin gradually became very greatly thickened, but blended with the immense amount of fibrous tissue that mainly constituted the mass. Upon the outer ankle is a similar little mass about the size of a nutmeg and very defined. The microscope showed a fibrous structure, and nothing more. Muscles separated from it, apparently, by a layer of adipose tissue; and blood-vessels seen in all parts.

The patient was a man, about forty-seven years of age, who died in the spring of 1867; a Virginian by birth, but a resident of this State from childhood. When six years old he injured his foot; swelling of the leg came on at once, with a shooting pain in the limb, and the disease progressed from that time. At the age of thirteen he went on a whaling voyage; and the leg that had before been smooth became rough, tuberculated, and cracked, with a serous discharge, which continued more or less abundant

so long as he lived. At the age of twenty-one he entered the hospital (24, 93) to have the limb removed; and a cast of it was taken at that time, which is now in the Med. Soc.'s Cabinet (No. 415); the greatest circumference then being 28 in. For many years he was subject to violent attacks of fever, with severe pain in the limb, though it generally troubled him only by its weight. He had also been subject to severe headache, hemorrhage from the bowels, derangement of the digestive organs, pulmonary symptoms, and for two years to dyspnoea, which last seemed to wear him out; there being found, on dissection, disease of the lungs, heart, liver, and kidneys. 1867.

Museum Fund.

2002. Thibert's model. Elephantiasis of the upper extremity. The enlargement is very great to near the shoulder, where it seems to be suddenly girt in, and becomes at once of its natural size. 1847. *Dr. J. C. Warren.*

2003. Photograph of a case of elephantiasis of the scrotum. Taken in Chicago, Ill.

The subject was a healthy negro, æt. twenty-two, and was afterward successfully operated upon by Dr. J. S. Thebaud, of New York. The penis was saved; and the tumor, after removal, weighed 51½ lbs. For a full report of the case, with illustrations, see N. Y. Med. Jour., May, 1867. 1868.

2004-5. Elephantiasis of the scrotum and of the lower extremities. A front and side photographic view of a healthy-looking Chinaman. Taken in Canton in 1861, and the next at the same time. Sent to Mr. B. from C. 1868.

James Blake, Esq., of Dorchester.

2006. Photograph of an elderly, but healthy-looking man. Case of molluscum? The disease is thickly scattered over the trunk, so far as seen, and a large mass hangs from the neck. 1868. *James Blake, Esq., of Dorchester.*

2007. Photograph of a case of elephantiasis of the face.

The patient was a sailor, from the Cape de Verd Isl., and the disease of three years' duration. Always most upon the face, but some disease upon the breast and extremities. He had used Fowler's Sol., Iod. of Potash, and

Quinine, and locally the Tinct. of Iodine; and had improved very much before the photograph was taken. 1866.

Mr. John Southwick, med. student.

Ear-ring tumors. Series xxxviii.

2008. Lithograph of a specimen of fibro-cellular hypertrophy of the skin over the mamma. — Disease began at the age of eleven years, removed at the age of twenty-two, and returned at the age of twenty-eight. The figure shows it as it appeared after it was removed by Dr. B. Four or five years afterward the disease had not returned. It consisted of hard, dense masses, involving the skin, and inseparable from the fat, sometimes growing around the fatty masses, but generally by itself. Structure uniformly dense, white, and unyielding. Microscopically fibro-cellular. 1858.

Dr. H. J. Bigelow.

2009. Thibert's models. Four representations of the result of inoculation from a venereal chancre. 1858.

Museum Fund.

2010-11. Daguerreotypes, showing a front and side view of a chancre of the thumb. It was indurated, and other remedies having been tried without effect, it yielded when treated as for secondary syphilis. Origin of disease unknown. — The patient was a physician. 1858.

Dr. H. J. Bigelow.

2012. Cast of the knee; showing a congenital nævus.

The patient was twenty-one years of age, and entered the hospital Dec. 25th, 1852 (56, 67). There were four dusky red spots, from $\frac{1}{2}$ in. to 2 in. in diameter; and during the last two years they had increased in size, and become so sore that he was obliged to hold his dress off when walking. They were hard to the feel and very tender; and at one spot they were so, without discoloration. Ice and salt were applied to produce cold; but the part was frozen. Free subcutaneous incisions were afterwards made, and the patient was discharged March 20th, very much relieved, though the discoloration remained the same. Cast taken by Mr. Wm. N. Lane, one of the house-pupils. 1853.

Dr. J. M. Warren.

2013. Thibert's model. Glanders in man; colored. Skin of the shoulder affected. 1858. *Museum Fund.*

2014. —. The same. Scattered pustules upon the face in different stages, with small gangrenous patches. Also extensive ulceration, with destruction of the mucous and sub-mucous cellular membranes of the nasal cavity and pharynx, very abundant muco-purulent discharge from the nostrils, and great congestion of the pharynx. 1847.

Dr. J. C. Warren.

2015. Cast in plaster of the front of the chest, showing two patches of cheloides; colored by Mr. Clarence J. Blake.

From a woman, æt. thirty-one years. (Hospital, 101, 141.) Disease of nine years' duration. One of the patches extended across the upper front of the sternum, and measured 3 by 2 in. The other, over the lower extremity of the bone, was more prominent, and an inch in diameter. This last was excised by Dr. C., after the cast was taken; and was found by Dr. Benj. S. Shaw to consist of condensed and hypertrophied cellular with fibrous tissue; being composed mostly of fibres, with a few scattered pale cells and nuclei. 1864.

Dr. H. G. Clark.

2016. A patch of cheloides, $2\frac{1}{2}$ by 2 in., with $\frac{1}{2}$ an in. of the surrounding integument, removed from the forearm. The result of a scald twelve years before.

From a woman, æt. twenty-five years. One scald healed well. The other suppurated freely, was frequently touched with lunar caustic, and finally healed. The cicatrix, however, afterward enlarged, and became exceedingly painful, — the pain darting up and down the arm, and feeling as if a knife were thrust into it. About $\frac{1}{2}$ an inch above it another patch of cheloides appeared, and the two enlarged together. After the operation the pain was quite relieved, and at the end of a year the disease had not returned. 1847.

Dr. J. M. Warren.

2017. Photograph of a powerful negro whose back is most extensively scarred by lashing. Taken in Louisiana during the Civil War; and it is stated in connection with it that, amongst twenty-seven thousand four hundred contrabands, a large number were as badly scarred as this man. The

- cicatrices in this case look as if they may have become affected with cheloides. 1868.
2018. A cast in plaster of the end of the finger of a healthy infant, and upon which there had formed a very thick and strongly defined tumor that seemed to resemble cheloides. It was of about four months' duration, and painless; growing rapidly, already overlapping the nail, and would before long have surrounded the finger; firm, translucent, not discolored, and covered with a thin adherent cuticle. Microscopically fibroid. No cause assigned. Amputated by Dr. B., and cast taken by Mr. Henry Hooper, one of the house-pupils. 1869. *Dr. H. J. Bigelow.*
2019. Thibert's models. Lupus exedens; of the nose. 1852. *Dr. J. C. Warren.*
2020. —. The same upon the nose and cheek, with destruction of the tissues; "serpiginous." 1852. *Dr. J. C. Warren.*
2021. —. Lupus non exedens of the cheek and forehead, with hypertrophy of the tissues of the cheek. 1852. *Dr. J. C. Warren.*
- Cases of lupus. 1858. *Dr. H. J. Bigelow.*
- 2022-3. Daguerreotypes of a girl, æt. nineteen years, whose nose had been destroyed by lupus, and for whom Dr. B. made a new one. There was also an opening through the palate. Front and side views. (Hospital, 63, 90.)
2024. Daguerreotype of the above case, showing the new nose.
2025. Daguerreotype of a second case of serofulous lupus. The patient was a girl, æt. nineteen years. (Hospital, 69, 33; and Med. Jour. Vol. LXXVI. p. 347.) Disease of ten years' duration. The nose, uvula, and gums were destroyed; exposing the roots of a few remaining teeth. An upper lip was made from the cheeks, which came together with great tension; and some months afterward, and when the lip had become pliable, a new nose was made from the forehead.
2026. Daguerreotype of the last case, after the operations, and showing a very great improvement.

2027. Daguerreotype of the last of the above cases before, and of the first after, the operation.

Exfoliation of bone from the forehead, after a rhinoplastic operation. (See No. 1309.)

2028. Cast, in plaster, by Mr. John O. Green, one of the house-pupils, of the face of a man, upon whom M. Nélaton, of Paris, had done a very unsuccessful operation two years before. (Hospital, 125, 48.) Five years before his entrance he was struck upon the nose; in six months it sloughed, and a few weeks afterward it healed. A flap was taken from the cheek to supplant the deficiency; and he entered the hospital for some further operation, but nothing was done. 1866.

Dr. H. J. Bigelow.

For Dr. Warren's case of "Eiloides" see No. 3055.

2029. The hand, with a part of the forearm of an old man, that was amputated at the hospital, and has been preserved entire in spirit; bearing a very striking resemblance to Mr. Paget's figure of a case of epithelial cancer in the same place. (Surg. Pathology, p. 567.) The disease arises from the back of the hand, is of a nearly circular form, and about 3 in. in diameter, considerably raised above the surrounding surface, with the edges overlapping the base, coarsely granulated, and firm to the feel. 1847.

Dr. J. C. Warren.

2030. A leg and foot, preserved entire in spirit, and showing a strong flexion, with distortion of the foot, extensive cicatrization over the lower half of the leg, and a large epithelial cancer below the knee, in a state of open ulceration.

From a man, *æt.* twenty-six years. Reported on admission into the hospital (75, 83) that when three years old a log fell upon his leg, and broke both bones, ruptured the tendo-achillis, and stripped the skin completely off. This was followed by eversion of the foot, and a tilting up of the toes; and for the last eleven years he had walked entirely upon his heel. For the last three years there had been an ulcer below the knee, and that occasionally healed. During the last year, after a long walk, and getting wet, an ulcer broke out above the ankle, and extended half way up the front of the leg, but soon healed. As this healing

went on, the first ulcer, that was then about an inch in diameter, increased to the size of a man's hand; the edges being raised and well defined, the centre deeply excavated, and the whole very offensive.

Amputated below the knee, and discharged well in five weeks. 1857. *Dr. H. J. Bigelow.*

2031. Cancer of the lip. Ulceration deep, and edges everted. 1847. *Dr. J. C. Warren.*

2032. Daguerreotype of a patient with epithelial cancer of the lip.

A woman, æt. thirty-five years, and of robust health. Disease of two years' duration, and rapidly increasing the last six months. Pain dull and smarting. Ulcerated surface $\frac{3}{4}$ of an inch in width, and covered with a dirty slough; edges everted, and very offensive. Removed by Dr. B., and a new lip made from the cheek; and in four weeks and a half she was discharged, with the wound healed, and a good cicatrix, but with some threatening of disease in the cicatrix upon the cheek. About eight months afterward she was seen with a return of the disease below the jaw, and death soon followed. (Hospital, 51, 94.) See next specimen. 1858. *Dr. H. J. Bigelow.*

2033. A lithographic print, illustrative of epithelial cancer.

1. The above daguerreotype. 2. A colored view of the cancer, and section of the same. 3. A small cancer upon the prolabium, and section. 4. A large cancer upon the outside of the lip, and section. 5. Three figures, to show the columnar structure. All colored, excepting the first and last. 1858. *Dr. H. J. Bigelow.*

2034. A colored drawing, by Mr. B., of a case of very extensive epithelial cancer of both lips.

From a man, æt. forty-seven years, of good general health, and under the care of Dr. D. W. Cheever, at the City Hospital. Disease of four years' duration; began with a "wart" upon the upper lip, and for the last three months there had been ulceration, with severe pain. His father died of cancer; and another relative had had the disease. The disease affected both lips upon the right side, and extended from the median line into the cheek, about

half way from the angle of the mouth to that of the jaw ; the diseased mass protruding considerably from the side of the face, and filling up densely the space between the alveoli and the cheek. The whole was excised by Dr. C., and seven weeks afterward, as the man was doing well, an attempt was made, with partial success, to close the deficiency that was left. 1866. *Mr. C. J. Blake.*

2035. Epithelial cancer of the thumb.

The patient was a physician, over seventy years of age ; and the disease began as a wart. Four months before, and after attending a case of midwifery, the tumor increased in size, and became extremely painful. It was situated over the joint, and was somewhat larger than the thumb nail. The last phalanx was removed ; and the microscope showed the nature of the disease.

About two years afterward he died ; and, meanwhile, an epithelial disease formed upon the side of his nose. 1858.

Dr. Chas. D. Homans.

2036. A lithographic print of a case of extensive epithelial cancer of the thumb ; colored. Two views of the entire hand ; and a third to show the columnar structure of the diseased growth.

From an old man, whose forearm Dr. B. amputated at the hospital about the year 1852. 1858.

Dr. H. J. Bigelow.

2037. Cast, in plaster, of the back of a man who had a cancerous tumor about the elbow (No. 3047.) There were numerous, small, flaccid, wrinkled, pedunculated tumors, receding through the skin upon the slightest pressure, and most numerous over the back, though scattered sparsely over the front of the trunk. A few of the largest were in the cellular tissue of the amputated arm ; and, in structure, resembled the main tumor. 1858. *Museum Fund.*

2038. Development of melanosis upon a discolored portion of skin.

From a man, æt. forty-four years, and of sufficiently good general health. The discoloration, which was undoubtedly congenital, was upon the lower part of the abdomen, about 10 in. in extent, and of a brown color, though

not uniformly so. The surface was not hairy; and, excepting some increased sensitiveness, was otherwise healthy. About eight months before its removal, melanotic tumors, of a rounded, button-shaped form, began to appear; and several of them had been removed by the patient himself, by ligature. The whole was excised by Dr. M., and the wound healed almost at once; but the man died within a few months after the operation.

The specimen shows a portion of the skin discolored, but otherwise healthy; other parts more or less rough from the disease; and one dark melanotic mass, $1\frac{1}{2}$ by 2 in. in diameter, and half an inch thick; the disease being confined to the skin. 1858. *Dr. Wm. Mack, of Salem.*

2039. Melanosis developed upon a boil.

From a healthy man, æt. twenty-five years, who had had a common boil upon the thigh, that ran the usual course, and was about well, when the tender cicatrix was bruised, and there sprouted forth the morbid growth, which, after resisting treatment for three months, was at last removed. It was not larger than a filbert, was confined to the skin, and presented the usual appearances of melanosis. (*Med. Jour. Vol. LXIV. p. 92.*) 1860. *Dr. R. M. Hodges.*

2040. A drawing, in water-colors, by Mr. D., of a case of encephaloid disease of the thigh, taken after death. The microscopic appearances are also shown. (See No. 2165.) 1859. *Mr. John Dean, student of medicine.*

2041. Hypertrophy of the great toe-nail; from a woman, æt. sixty-two years. 1853. *Dr. D. H. Storer.*

2042-3. The toes of a mulatto woman, over ninety years of age, removed after death, and preserved in spirit, showing a remarkable growth of all of the nails, that had been growing from the time that she froze her feet, fifteen years before.

The toes of the other foot, dried, and showing the same. 1866. *Dr. Henry K. Oliver.*

SERIES XXVI. — DISEASES OF THE EYE.

Blind-fish, and blind craw-fish, from the Mammoth Cave, Ky. See Nos. 526-7.

2044-5. Daguerreotypes of a case of protrusion of the eyes, in connection with an enlarged thyroid gland; front and profile view.

The patient was a delicate and chlorotic young lady, twenty-one years of age. The protrusion and the enlargement had existed for some months; and she could not say which first appeared. The globes could be pressed back a little into the sockets, but in a second or two they again protruded, with a wild and staring look. Vision not affected. The thyroid was moderately enlarged, and pulsating, with an interrupted bruit that became continuous on pressure. The hair had already begun to turn gray; a fact that Dr. B. had observed in another case of exophthalmia, and that appeared after typhoid fever.

Dr. B. remarked upon the resemblance of his case to those published by Mr. Cooper, in the London Lancet for May 29th, 1849. (Med. Jour. Vol. LXI. p. 37, with a figure.) 1858. *Dr. H. J. Bigelow.*

2046. A true bony growth, from the bottom of the globe of the eye. Form rather crescentic, but about an inch in length, 7 lines in width, and $1\frac{1}{2}$ lines in thickness; edges thin.

From a young man, æt. nineteen, who, at the age of four years, received a blow upon the eye, which was followed by loss of vision, and from that time frequent attacks of inflammation. The globe was removed, as there was some threatening of disease in the other eye; and the following appearances were described by Dr. D.

The globe was of normal dimensions; the sclerotic being in the posterior half so thin in many places, as distinctly to reveal the line of the choroidal pigment. On section, the cornea was found much thickened, and the lens shrunken and chalky. The retina was wholly detached from the choroid, hanging away from the ora serrata on all sides,

and extending in the shape of a funnel to the optic nerve, around the edges of which it was closely applied. Overlying the choroid, and easily separable from it was the bony shell or scale "accurately moulded on the eye, and with a well-marked foramen at its outer edge, for the passage of the retina to the optic nerve." (Med. Jour. Vol. LXXI. p. 269.) 1865. *Dr. Hasket Derby.*

2047. Globe of the eye, cut open, and showing upon the inner surface a considerable amount of whitish, fibrinous-looking substance. Something of the kind is seen upon the outside of the sclerotic and in its substance, with much thickening of this coat. 1847. *Dr. J. C. Warren.*

2048. An extirpated eye, showing a very great thickening, with opacity of the cornea. 1867. *Dr. C. Ellis.*

2049. A section of the eye, showing at the bottom of the globe a defined, hemispherical, dark brown tumor, 4 or 5 lines in diameter, of a soft, fleshy consistence, uniform in appearance, and non-malignant in its character. It is broadly and closely connected with the sclerotic coat, which is otherwise healthy; and the choroid and retina were easily separable from it. Dr. Ellis found it "composed of long fusiform cells, with fine prolongations, such as are figured in Virchow's work on Tumors (German ed. Vol. II. p. 197)."

From a woman, æt. fifty-two, who applied to Dr. H. Derby, Jan. 23d, 1867. Vision of the left eye had been failing for eight years, and within the last year had become extinct. Considerable pain in and about the eye for six weeks, but none before. There was deep ciliary redness, a stony hardness of the globe, anæsthesia of the cornea, dilatation of the pupil, and haziness of the vitreous. Iridectomy was attempted; but, on account of the diseased state of the iris, it was with great difficulty that a reasonable amount could be excised. In a week the patient returned home; the pain having entirely, and the redness nearly, disappeared; anterior chamber still half full of blood, and very slowly absorbing. May 9th, no pain, but constant discomfort. Complete obliteration of anterior chamber; the iris being in contact with the cornea. After the 16th her

sufferings were agonizing, and on the 23d the eye was removed; the right eye being healthy. 1868.

Dr. C. Ellis.

2050. A wax model of the face of a man, showing a large, cancerous-looking tumor, projecting from the orbit. From Paris.

In the Dupuytren Museum is a similar model; and a second, showing the appearances after the removal of the mass by M. Gerdy; the wound having cicatrized. 1847.

Dr. J. C. Warren.

2051. Cavity of the sclerotic, about two-thirds filled by a nearly uniform, whitish, soft, solid substance, and having the well-marked microscopic appearances of cancer. Otherwise the cavity is free; and the tissues, where not involved in the disease, are healthy. The globe, however, is enlarged, and bulges at the upper part.

From a feeble woman, æt. thirty-five years. Uneasiness constant, and pain occasionally severe. Loss of vision complete. Removed by Dr. H., and did well. (Amer. Jour. of Med. Sc., June, 1850.) 1852.

Dr. Robert W. Hooper.

2052. Globe, filled with a cancerous deposit. 1857.

2053. A melanotic mass, nearly or quite as large as an English walnut, and connected with the globe of the eye externally. The sclerotic, where not involved in the disease, is healthy, but this last is just encroaching upon the cavity at the bottom of the globe. 1847.

Dr. J. C. Warren.

2054. A smooth, but somewhat irregular melanotic mass, about $\frac{3}{4}$ in. in diameter, $\frac{1}{4}$ in. thick, and arising from the anterior third of the globe of the eye; the organ being otherwise healthy externally.

From a healthy farmer, æt. sixty-five years. A pterygium appeared twenty years before, and was stationary for the first fifteen; the disease then increased, and at the end of a year he could only discern the light; pain severe for the first two years, and for some months before the operation, which was performed by Dr. B. at the Eye and Ear Infirmary. (Amer. Jour. of Med. Sc. Feb. 1850.) 1850.

Dr. G. A. Bethune.

2055. Melanosis of the eyeball.

From a man, æt. thirty-six years. Duration of the disease sixteen months. Pain through the organ, with redness and soreness from the first; vision gradually affected, and none for the last six months. Swelling began six months before; and when Dr. B. saw him there was a disorganized mass, of the size of a small apple, red, firm, and covered at the lower part by the everted conjunctiva.

After removal the mass had an ovoid form, was somewhat knobbed upon the surface, and measured upon incision, antero-posteriorly, a trifle over $1\frac{3}{4}$ in., and transversely $1\frac{1}{4}$ in. The outline of the globe upon this surface was distinct throughout, had somewhat the form of a chestnut, and was completely filled by a uniform, black mass, but not enlarged. Upon one side the sclerotic appeared quite healthy. A trace of the cornea was seen, but not of the lens nor anterior chamber. Just outside of the globe was a large and similar black mass. The remainder, which constituted a majority of the whole, varied much in color, and consisted partly of a uniform, close, compact white structure, without any trace of discoloration, though by far the greater part was more or less discolored, and passed almost gradually into the black portion. These differently colored portions were distinct, and seemed almost composed of separate lobules. From the posterior extremity of the mass to the globe of the eye the distance was $1\frac{1}{2}$ in.; the optic nerve being nowhere distinctly seen.

Dr. B. remarked that this was the fifth case of cancer of the eye that he had operated upon; and of these, three were of the melanotic form. Also, that the subject of the above case was the youngest of all of the patients. (*Am. Jour. of Med. Sc. Vol. xxi. p. 41.*) 1852.

Dr. Geo. A. Bethune.

2056. Globe, not enlarged, but filled with a black melanotic mass; with a mass of the same external to it, and nearly an inch in diameter. Sclerotic quite distinct, on section; and there is a small, and very hard, cretaceous body in place of the lens. 1861. *Dr. C. Ellis.*

2057. Globe filled by melanotic deposit; and the same external
to it. 1861.

2058. Atrophy of the left optic nerve, as far as the commissure,
but not appreciably beyond or behind this. The left eye
is much shrunken, as seen in the preparation.

From a man who died at the hospital (178, 107) of apo-
plexy, and had not seen with the left eye for thirty years.
1852. *Dr. J. B. S. Jackson.*

SERIES XXVI. — DISEASES OF THE EAR.

2059. Polypus from the ear. 1849. *Dr. R. W. Hooper.*

Caries of the temporal bone, in phthisis. (See No.
1261.)

SERIES XXVII. — DISEASES OF THE NOS- TRILS.

Thibert's models, illustrative of glanders. 1847.

Dr. J. C. Warren.

2060. Disease in the horse. Septum furrowed with ulcerations;
and the mucous and sub-mucous cellular tissues
swollen and greatly congested; giving rise to an abundant
muco-purulent secretion.

2061-2. The same.

2063. The same, in the human subject; and for the same dis-
ease as seen upon the skin, and in the larynx, see Nos.
2013-4 and 2135.

2064. A large, fleshy, pyriform, flattened, nasal polypus. 1847.

Dr. J. C. Warren.

2065. A second, larger specimen; in three lobes. 1847.

Dr. J. C. Warren.

2066. A third specimen, firm, and of considerable size.

From a healthy old woman, over ninety years of age.
Had had the disease for ten or twelve years, and six or

eight times Dr. P. had removed tumors that were sometimes soft, and sometimes firm; the nostrils being considerably obstructed. The present specimen was removed from the posterior nares, and from which it had been hanging down for some months, though it had only recently troubled her much. 1849. *Dr. Marshall S. Perry.*

2067. A fourth specimen, of the gelatinous form, that was infiltrated with lymph, as well as serum, and almost as large as a horse-chestnut.

From a mechanic, æt. about twenty-eight years. Both nostrils obstructed for less than a year; and a small polypus was seen upon one side. The forceps were applied so as to embrace the neck of the large tumor that was supposed to exist; but, after many unsuccessful attempts to extract it, the operation was abandoned. The man went to the back of the room to wash his face, the tumor descended into the throat, was hawked up, and he came forward with it in his hand. (Med. Jour. Vol. LXX. p. 62.) 1864. *Dr. H. J. Bigelow.*

2068. A cyst, about the size of a horse-chestnut, that was filled with clear serum.

Removed by Dr. T. from the posterior nares of a young girl. Dr. Bigelow, who examined it, described it as a "coarse fibroid structure, with some tendency to a circular disposition of its fibres, and lined with a structureless membrane." He regarded it as a cyst, developed in a fibrous nasal polypus, and of rare occurrence. 1857.

Dr. S. D. Townsend.

2069. A very large fibroid polypus, the removal of which required the removal of the upper jaw.

The patient was a healthy man, twenty-three years of age, who entered the hospital Nov. 17th, 1866 (127, 204), with a polypus in the left nostril, of six years' duration. Portions had been occasionally removed; and, in 1863, thirteen operations had been performed, with free hemorrhage each time. Two years before admission a tumor appeared in the left cheek, painless, and of slow growth. On the 17th Dr. B. cut down upon the tumor; and, having ascertained the extent and depth of its connections, he

decided to remove the bone, which was done at once, and with very little hemorrhage. The form of the bones was somewhat changed by the pressure of the tumor, but they were not diseased. The tumor adhered strongly to the nasal walls, and was at last deeply imbedded in the sphenoid cells, from which last it was entirely removed. On examination, after removal, it appeared to be a benign, fibroid growth, dense and white, but in some places traversed by vessels, so as to give some appearance of a cavernous structure. Its length was about $3\frac{1}{2}$ in.; its weight, after having been for some time in spirit, 2 oz.; and in form it was very much lobulated. Dec. 19th he was discharged well. (See the two next specimens.) 1867.

Dr. H. J. Bigelow.

2070. Upper jaw, from the above case. 1867.

Dr. H. J. Bigelow.

2071. Ferrottype of the above patient; presented by himself a few months after the operation, and showing very much less deformity than would have been expected. 1867.

Mr. D. W. Brooks.

2072. The upper maxillary bone, removed to get at a tumor in the posterior nares.

The patient was a man, thirty-three years of age, and left the hospital, well, in two weeks from the day of the operation (130, 210). 1867.

Dr. R. M. Hodges.

2073. Photograph of the above patient, some months after the operation; presented by himself, and showing a very slight deformity. With the aid of artificial teeth, and a palate, he did perfectly well, and his voice was scarcely, if at all, affected. 1869.

Mr. John S. Ives.

2074. Photograph of a man who had the left upper maxillary bone sawed through, and depressed in order to get at a polypus. The lip was cut through from the left nostril; the flap dissected back from the maxillary bone, and the section of this last was made just below the floor of the orbit. The two upper maxillaries were then divided upon the median line, without involving the soft palate, the left maxillary was depressed, and the polypus having been torn away from the ethmoid bone, the maxillary was restored

to its place, and secured. Six weeks after the operation a sequestrum was discharged, about 1 in. by $\frac{1}{3}$ in.; but two days afterward the man left the hospital (132, 190), without any tenderness of the teeth upon the left side when he chewed. On this date the photograph was taken; there being no deformity, excepting, of course, a very slight cicatrix in the hip. 1869. *Dr. R. M. Hodges.*

2075. A piece of rag, that was removed from the nostrils of a little girl, nine years of age, and upon the supposition of its being dead bone, as it was folded up and infiltrated with earthy matter. There had been obstruction of the nostrils for five years, with tenderness, purulent discharge, and occasional epistaxis. Nasal bones widely separated. (Hospital, 99, 150.) 1862. *Dr. H. J. Bigelow.*

2076. A cretaceous body from the nostril, or "rhinolite," as described by Dr. Gross; of a very irregular form, fully equal to a nutmeg in size, and much discolored upon the surface, but of a whitish color within.

The patient was a young girl, who, about eight years ago, received a severe blow upon her nose, which was followed by copious hemorrhage. Within a year afterward one nostril became obstructed, and remained so from that time, with pain, a constant and fetid discharge, and a pushing outward of the bones upon the affected side. The other nostril was free. The mass was considerably broken in its removal by the forceps; and shows a small rounded cavity, in which was found what Dr. H. supposed to be the remains of the effused blood, and the nucleus for the formation of the mass. Relief from the operation complete.

Analysis by Dr. White; phosph. and carb. of lime; coated with mucus and epithelial matter. 1868.

Dr. J. M. Harlow, of Woburn.

2077. Hypertrophy of the gums, extending to the roof of the mouth, as shown in a cast that was taken by Dr. B., before the first operation.

From a woman, æt. twenty-seven, who entered the hospital June 25th, 1867 (130, 134). Had had the disease from the first of her recollection, though her mother had

told her that it was not congenital. Had often had gum-boils, and was subject to nasal catarrh. Deglutition difficult, and speech thick; and she was obliged to breathe with her mouth open when she took cold. The gums were hypertrophied in each jaw, and upon each side of the teeth, though not uniformly. Two large masses in the roof of the mouth came together in front, but not posteriorly. There was a dull pain in the jaws most of the time; and the growths had quite a hard, cartilaginous feeling. On the 26th Dr. J. M. Warren removed all of the upper teeth, and most of the disease in the palate.

In October she returned to the hospital, and on the 9th Dr. Hodges removed the disease in both jaws with the scissors, gouge, and saw; the hemorrhage being considerable. On the 18th the entire surface was granulating, and on the 21st she was again discharged. (See two next specimens.)

In connection with this case, Dr. H. referred to one that is reported by Dr. Gross in his work on Surgery, Vol. II. p. 534, and one in Mr. Holmes' System of Surgery, Vol. IV. p. 18. Dr. Hodges also reports that he saw some years ago a very strongly marked case of this disease in a woman who was covered with hair, and exhibited as the "Bear woman;" there being an unusual development of hair in the case reported in Holmes' Surgery. 1868.

Dr. John H. Batchelder, of Salem, dentist.

2078. Cast, showing the above disease in the upper jaw, before Dr. Hodges' operation. 1868. *Dr. J. H. Batchelder.*

2079. Portions of the diseased gum, removed from the above case by Dr. H. 1868. *Dr. R. M. Hodges.*

SERIES XXVIII.—PARTS ABOUT THE MOUTH.

Diseases of the Lips. (See Nos. 2032, etc.)

2080. A section of a portion of a large African elephant's tusk, showing a small iron ball at some distance from the sur-

face, and observed to have been nearer to the tip than to the root. Some structural change is seen about the ball.

This specimen and the next were sent to the Museum by Mr. R., the son of the proprietor of the large cutlery establishment, at Greenfield, in this State. 1863.

Mr. Frank Russell, of G.

2081. A section of the tusk of a small African elephant, including the pulp cavity, and showing a large iron slug embedded in its substance; with a growth of new substance upon the outer surface, and a little of the same within the cavity. 1863. *Mr. F. Russell, of G.*

2082. Cranium of an Alpine marmot, showing a lateral deviation of the incisors, and their consequent elongation. The lower jaw is somewhat necrosed; the result, perhaps, of fracture. 1856. *Dr. H. J. Bigelow.*

2083. The same, in a woodchuck. The left upper incisor has perforated the right maxillary bone, and thus forms considerably more than a circle. A large portion of the right upper incisor is gone, and the whole anterior portion of the cranium is remarkably deflected toward the right side.

The simple perforation in this case shows well how a bone may yield to long-continued pressure, and without becoming diseased. 1859. *Mr. J. E. Cobb.*

2084. Two upper, adult, molar teeth, strongly united by the fangs. 1862.

2085. Section of an adult, molar tooth, showing how, in caries of the crown, the pulp cavity is encroached upon by the formation of new material, so as to prevent an external opening. 1857.

Mr. William A. Thurston, med. student.

2086. A large spermaceti whale's tooth, upon the fang of which there is formed a very large and irregular tumor, consisting, apparently, of a mass of dentine. One longitudinal half is shown, and the other half is in the museum of the Boston Soc. of Nat. History. 1859.

George H. Folger, Esq.

2087. A section of an irregular mass of dentine; and that probably lay as a loose body in the cavity of the tooth of a

sperm whale, as it was picked out from a barrel of teeth. It is $3\frac{1}{2}$ in. in length, about an inch in diameter, and pointed at one extremity. The structure is very compact, with granules upon the external surface; and upon the cut surface is a convoluted look, as if it were made up of irregularly cemented granules.

The Dental College, in this city, has a similar formation from the pulp cavity of an elephant's tooth; and minute granules of free dentine are said by Dr. Thomas B. Hitchcock to be sometimes found in man. 1862.

Dr. Henry A. Martin, of Roxbury.

2088. An adult, bicuspid tooth, upon the fang of which, and toward the point, is a small granule, apparently of enamel. 1859.

Mr. Wm. Nichols, Jr., med. student.

2089. A very considerable bony deposit about the fang of a bicuspid tooth. 1868.

Dr. P. Pineo, of Hyannis.

2090. A very large canine tooth, with a considerable portion of the alveolus adherent. 1861.

Mr. W. B. Gibson, med. student.

Dropsy of the antrum, caused by a tooth in the cavity. (See No. 577.)

2091. A misplaced left lower molar tooth. (Hospital, 130, 196.)

The patient, a negress, æt. forty-one, reported that she had never had any permanent molars upon the left side in the lower jaw; and she thought that she had never had any molars there of the first set. About ten years before entrance a tumor formed in the place of the molars, and five years afterward was removed, but soon returned. During the last six months it had grown more rapidly, and was so painful that she was ready to submit to any operation for relief. On inspection, a dense, lobulated, and very tender tumor was found, about as large as the thumb, and $1\frac{1}{2}$ in. in length. The mass being removed, the tooth was found beneath it, lying horizontally, and entirely surrounded by a delicate fibrous cyst, in which it lay quite loose. The crown was covered by a pulpy capsule, and this is shown in the preparation. The cut surface of the mass above it was white, dense, and fibrous, with some spiculæ of bone. The woman did well, and was discharged in about three weeks. 1868.

Dr. R. M. Hodges.

2092. Casts, in plaster, from two different subjects, to show the notched and crescentic appearance of the edges of the upper central incisors, and the pegged and irregular appearance of some of the other teeth, as observed by Mr. J. Hutchinson, of London, in cases of inherited syphilis. This has been noticed particularly in the upper teeth, and about the period of the second dentition; and with it there may be other indications of disease.

Dr. W. has given two other casts to the Med. Soc., and has met with many cases of the affection. 1869.

Dr. H. W. Williams.

2093. A salivary calculus, of an irregular form, equal in bulk to one-third of an inch, or more, in diameter, and that was supposed to have formed in the sublingual duct. It consisted, as usual, of the phosphate, with a little of the carb. of lime, and organic matter.

From a man, forty years of age, who for some months had had severe neuralgic pain, with a considerable drawing down of the right side of the face; an external swelling then appeared below the lower jaw upon the right side, and it was thought a fistulous opening would form. In about a week, however, this subsided, and a corresponding swelling came on, internally, about opposite the canine tooth. In a few days the calculus appeared at a small opening, and was readily extracted by the forceps, with entire relief to the pain, and improvement of the general health, which had previously declined. 1860.

Mr. Frank D. Beer, med. student.

2094. A second specimen, of similar composition, one-fourth of an inch or more in diameter, and weighing 15 grs.

From a man, æt. forty-eight years, who first had severe pain under the side of the tongue, followed by a swelling, and at times excruciating pain. Suppuration at last took place, and the calculus was discharged with perfect relief. The whole duration of the disease was fourteen years. 1860.

Dr. H. B. Burnham, of Epping, N. H.

2095. Two salivary calculi; one about $\frac{1}{4}$ in. in diameter, and the other about one-third as large; from a man, æt. twenty-eight. The largest was discharged, in 1863, through an

opening at the root of the left lower middle molar tooth. There was swelling, equal in size to that of a large hen's egg, with a great deal of pain; and he suffered from it for six weeks. The second was discharged in 1865, and with less pain; the swelling being even with the jaw, and attended with some suppuration, which the first was not. The duration of his second sickness was three weeks. 1868. *Dr. Amos B. Bancroft, of Charlestown.*

2096. A sublingual calculus, 1 in. in length, and $\frac{1}{16}$ in. in diameter. The patient was a middle-aged man, and Dr. B. was called to see him for a "sore throat," of two or three weeks' duration; the whole mouth being very tender, with salivation, swelling of the tongue, and dysphagia. On the following day the calculus was found and readily removed. 1869. *Dr. H. J. Bigelow.*

2097. A lower incisor tooth, almost buried in "tartar." The gum gradually separated, and it was at last picked out. From a middle-aged woman, who had lost a tooth before in the same way. 1852. *Dr. C. E. Ware.*

2098. Thibert's model, showing a dark, foul coat upon the tongue, in case of typhoid fever. 1849.

Dr. J. Ware.

2099. Tonsil enlarged. 1847. *Dr. J. C. Warren.*

Four models by Thibert. 1849. *Dr. J. Ware.*

2100. Epidemic diphtheritis. Acute inflammation of the fauces, with lymph.

2101. Deep inflammation of the fauces, tending to gangrene.

2102. Acute inflammation of the fauces, without lymph; mucous and sub-mucous cellular membrane swollen.

2103. Ulceration of the pharynx and œsophagus, "that occurs in fever."

2104. Great swelling of the soft tissues at the upper orifice of the larynx, as in laryngitis. 1847.

Dr. J. C. Warren.

2105. Very extensive and destructive ulceration of the pharynx and larynx.

From a middle-aged woman, who had had dysphagia, with frequent and alarming choking for ten years. For

nearly a year before Dr. D. saw her there were sore throat, hoarseness, and sometimes aphonia. When seen, she was very feeble, and had not slept for four days; great dyspnoea, with long, stridulous, and convulsive inspirations; and with acute pain in the ears on swallowing. The trachea was opened, and a canula left in, through which the patient ever afterward breathed freely. The dysphagia, however, increased, and for the last eight days she was wholly unable to swallow; fluids passing out at last through the canula. She became extremely emaciated, partially delirious from the want of food, and died fourteen weeks after the operation. Miliary tubercles were found in the lungs, but there was no softening. 1854.

Dr. Jas. Deane, of Greenfield.

2106. Contraction of the fauces, so extreme, that a catheter will hardly pass. Parts thickened and condensed, but perfectly cicatrized. The remains of the soft palate upon each side, and the whole epiglottis, so far as can be seen without cutting quite through the stricture, are closely and strongly adherent to the base of the tongue; the entrance to the larynx being so drawn upon that what was a mere chink has come to be a long and deep fissure.

From a woman, æt. thirty-seven, who was in the hospital, for a short time, for what appeared to be a syphilitic ulceration of the leg, and who died a few days after her discharge, probably from brutal treatment by her husband. In regard to her throat, she reported that five years previously the greater part of the soft palate and tonsils was destroyed by ulceration, that had only recently cicatrized, and was still liable to break out. Denied any syphilitic taint; and reported her health as previously good. Appetite good; took solid, as well as liquid food, and was well nourished. No dysphagia, but sometimes choked when asleep. Breathing always labored and stertorous, and particularly on exertion. Voice sufficiently loud, and not hoarse, though hollow and peculiar. She would take in a full breath, and then speak so long as she expired. (*Amer. Jour. of Med. Sc.*, Oct. 1850.) 1852.

Dr. J. S. Jones.

Case of enchondromatous tumor in the palate. No. 3025.

2107. Cancerous disease of the pharynx, extending to the upper part of the œsophagus, and to the larynx.

From a woman, æt. thirty-two years. Disease of ten months' duration. An aching pain constantly in the throat, with a feeling as if there was a large hollow there, beyond which the food did not pass. Strangled on swallowing, toward the last, and had to be supported by enemata. Much salivation. Hawked up a bloody fluid for some weeks before death. Voice clear, though feeble, until the last week; and afterward spoke in a whisper, though with effort she could speak aloud, even to the last. Some swelling of the cervical glands from the first; and at one time much swelling of the throat, externally, with much dyspnœa. Breathing otherwise easy until the last two or three weeks, when, on swallowing, it would be extremely difficult. Became much emaciated, and was confined to her room the last two months.

On examination of the specimen, in the recent state, the whole interior of the pharynx was in a state of open, cancerous ulceration, as high as where it was cut off. Inferiorly, the disease extended to just below the cricoid cartilage, which was in the process of being detached by sloughing. The inner surface of the larynx, posteriorly, was cancerous; and there projected into the upper back part of the trachea, as seen in the preparation, an encephaloid mass, half as large as a nutmeg. No appreciable contraction of the passage at the seat of disease. The organs of the thorax and abdomen were healthy. 1849.

Dr. John Randall.

Sequestrum from the palatine bone; retained for some months, and, as it was supposed, in the air-passages, though more probably in the pharynx. (See No. 1308.)

SERIES XXIX.—VOCAL AND RESPIRATORY ORGANS.

I. AIR-PASSAGES.

2108. Portion of the lung and trachea of a young pig, containing great numbers of filariæ. The lung was considerably inflamed. 1854.

Mr. Benj. W. Kinsman, med. student.

2109. Portion of the lung of a porpoise, containing two filariæ, about 5 in. in length.

Dr. W. has found this parasite very generally in the air-passages of the porpoises that he has examined. 1854.

Dr. J. Wyman.

Parasites from the lung of a serpent. (See No. 3084.)

2110. The air-passages laid open, and showing a bean in the cavity, and partially imbedded in the substance of the right primary bronchus; the walls of this last being softened and deeply eroded, but without the usual signs of inflammation. A limited portion of the lung was partially hepatized.

From a little girl, who was playing with beans, eight days before her death, when she was attacked very suddenly with urgent dyspnœa, and stretched herself out as she gasped for breath; but in half an hour she was entirely relieved. After being better and worse for the first three days, she was in such a condition upon the fourth day that it was thought hardly possible for her to live many hours. But as there was pneumonia, and no positive evidence that a bean had been swallowed, the trachea was not opened. For several days the case had been regarded as one of croup. In the evening she became more comfortable, and the symptoms of inflammation afterward subsided. She died, however, very suddenly while sitting up, and apparently convalescent.

Dr. H. J. Bigelow remarked, upon this case, that it is comparatively safe to leave a hard body; but if, on the other hand, it is one that can swell, the operation should not be delayed. 1863.

Dr. C. Ellis.

2111. A second, and almost precisely similar specimen. The bean, which was tightly wedged into the right primary bronchus, had swelled so as to distend its calibre. The right lung was collapsed and solidified, so as to sink in water; and the left was infiltrated with lymph.

From a little girl, two years old, who had been playing with beans, and fell as she was running down hill. She was picked up, choking and gasping, and it was thought that one of the beans had passed down the larynx. Twenty-four hours afterward Dr. H. saw her at the hospital as an out-patient, with moderate dyspnoea, sublividity, a feeble pulse, anxious countenance, and an occasional cough; but at no time had there been any paroxysm of cough, or of sudden dyspnoea. On percussion there was a greater dulness upon the left side of the chest than upon the right. On auscultation the air seemed to enter both lungs, with a strong tubular sound; and over the left, where this was most marked, there was a hoarse, croupy murmur, so that the foreign body was thought to be upon that side. An opening was then made into the trachea, and up into the larynx; but no foreign body was expelled, nor was any felt by the curved forceps. Inversion, and slapping smartly upon the back, were also tried without effect. After the operation the child gradually sank, and died thirty hours after the accident. Dr. H. remarked upon the error of diagnosis in regard to the position of the bean, in consequence of the pneumonia, which came on so rapidly, and had been overlooked. (Med. Jour. Vol. LXIX. p. 298.) 1864.

Dr. R. M. Hodges.

2112. A silver half-franc piece, that was accidentally swallowed. Six weeks afterward Dr. O. saw the patient, who was a Frenchman; and, though the man was very sure that the coin was somewhere in the larynx, Dr. O. could not, on the most careful laryngoscopic examination, detect it, nor were the symptoms at all urgent. The patient was placed upon a couch, with his head and chest hanging over the side, so that his body was nearly in a perpendicular position; and in this position he coughed forcibly, and was struck several times upon the back. The cough became suffocative, and something was felt to move in the

larynx. This experiment was repeated twice; and after the third and last trial, on regaining the upright position, he coughed out the piece of money, with perfect relief. 1869.

Dr. H. K. Oliver.

2113. An irregular piece of bone, about 1 in. by $\frac{1}{2}$ in. in diameter, that was removed from the larynx.

The patient was a man, thirty-five years of age; and the bone, which is a portion of the lamina of a vertebra, was swallowed at 6 p. m. At 11 p. m. the upper part of the trachea was opened, and the bone was removed. There had been a hissing sound with the respiration, but much less distress than would have been expected. The man did well, and was discharged in two weeks; the wound not having quite closed, though no air passed through it. (Hospital, 135, 200.) 1868.

Dr. R. M. Hodges.

2114. A tracheal tube, removed from the right primary bronchus; $\frac{5}{16}$ in. in diameter, and 2 in. along its convexity.

The patient was a man, æt. forty-five, who had had the operation of tracheotomy performed three times within eight years, and for the last time in December, 1864. The same tube had been worn since the last operation, and for two months it had not been removed.

On the morning of Oct. 26th, 1868, he found that it was detached from the plate that was secured about his neck, and at noon he entered the hospital (135, 201); as there was, however, very little irritation, he was left until the next day, when the tube was easily removed with the polypus forceps, and on the 31st he was discharged, with a new tube.

In connection with this case Dr. H. referred to another, in which the tube simply became unsoldered; and to a third, in which fragments of the tube became detached, and fell down into the air-passages. 1868.

Dr. R. M. Hodges.

2115. The whole upper right cornu of the thyroid c. broken off, with partial fracture upon the median line.

From a Sandwich Islander, who hung himself. 1861.

Dr. R. M. Hodges.

Case of cut-throat. (See No. 2169.)

2116. Croup. Larynx and trachea cut open, and shows the membrane extending from the bottom of the trachea to the tip of the epiglottis. As usual, it is much more adherent in the larynx than below. 1847.

Dr. J. C. Warren.

2117. Larynx and trachea, from a case of croup, in which Dr. B. opened the trachea on the seventh day. Dilators were used to keep the sides of the opening apart; and a double canula was also used.

The child, a little girl, five and a half years old, was much relieved by the operation, but died, on the twelfth day, of pneumonia. An abundance of lymph, however, was found, as seen in the preparation; some of it being a primary formation, and some being formed where a deposit had already been thrown off. (*Amer. Jour. of Med. Sc.*, July, 1853.)

The dilators are shown; but, being of iron, they rusted the preparation, and silver ones have been put in their place. 1853.

Dr. H. J. Bigelow.

2118. Thibert's model. Larynx and trachea, with patches of false membrane upon the mucous surface, and inflammation around them. 1849.

Dr. J. Ware.

2119. —. False membrane, very adherent to the inner surface of the larynx. 1849.

Dr. J. Ware.

2120. The larynx and trachea, from a case of diphtheria.

The subject of this case was Dr. Horace W. Adams, of this city, and the specimen is preserved in the Museum, by permission. On the 6th of February he took charge of one of his friends, who had what seemed to be an acute tonsillitis, of moderate severity, with a whitish exudation on the fauces, and who died very suddenly on the 10th; Dr. A. endeavoring to resuscitate him by clearing the throat, and by attempted inflation of the lungs. Having had a severe cold, and been subsequently exposed from the 5th to the 10th to much vicissitude of weather, he returned from the country on the 11th with sore throat. On the 13th he attended the funeral of his friend, but felt quite unwell on his return, and sent for Dr. M. The disease was then established, and he died on the morning of

the 17th, in a sudden fit of strangling. The tonsils and uvula were much swollen, with an exudation upon the surface, and a copious secretion, which he was constantly hawking from his throat. On the afternoon of the 16th, he threw up, with much effort, and symptoms of strangling, a membrane that looked like a piece of white kid; 5 in. long, 1 in. broad, and tubular in two places; and during the night two smaller pieces were raised without difficulty. (See next specimen.) There were external swelling, hoarseness, and sometimes aphonia. Respiration labored at times during the last night; but, previously, no dyspnœa. Dysphagia from the first, but not enough to prevent him from taking liquids freely to the last. Pulse 84 to 108, but during the last night rose to 132. Throughout his sickness he was cheerful, and retained his strength so far as to be able to walk about his room without effort the day before his death. The treatment consisted of stimulants, nourishment, and tonics; and, locally, the use of nitrate of silver, and of chlorate of potash.

On dissection, the neck was much swollen; the epiglottis and upper orifice of the larynx swollen, and a false membrane extended from the fauces to the secondary bronchi. This last was somewhat ash-colored; and in the trachea quite firm, and about $\frac{1}{8}$ in. thick; easily separated, and without any very marked change of the subjacent surface. (Med. Jour. Vol. LXIV. p. 106.) 1861.

Dr. Francis Minot.

2121. Membrane expectorated. (See last case.) 1861.

Dr. F. Minot.

2122. "Bronchial polypi," raised, in great numbers, by a man thirty years of age, before his death from phthisis, and during a period of six weeks. The casts are from the larger and smaller bronchi; and some are between one and two lines in diameter, and over 2 in. in length. 1868.

Dr. H. I. Bowditch.

Seven models by Thibert. 1849. *Dr. J. Ware.*

2123. Simple, acute inflammation of the larynx; redness, with swelling of the mucous and sub-mucous cellular membranes.

2124. Laryngitis. Inflammation of the sub-mucous cellular tissue, with much œdematous swelling about the vocal cords and epiglottis.
2125. Intense, acute inflammation of the mucous membrane of the trachea and bronchi; uniform and deep redness, but without ulceration or much swelling.
2126. A fine variolous eruption over the mucous surface of the trachea.
2127. Deep tubercular ulceration of the anterior and upper part of the trachea; rings exposed.
2128. Tubercular ulceration of the larynx and trachea. Aphonia was almost complete.
2129. Deep tubercular ulceration of the larynx; ventricles and cartilages involved.
2130. A defined, circular, superficial ulcer, about 1 in. in diameter, just above the vocal cords anteriorly; and two similar ones, about $\frac{1}{4}$ in. in diameter, upon the under surface, and toward the tip of the epiglottis. The right vocal cord is also ulcerated; and there is one small ulcer in the trachea.

From a man, æt. thirty-one (Hospital, 215, 246), who died of phthisis of ten months' duration. He had "unpleasant sensations in the throat" from the first; and about a month before death complained much of sore throat, and of difficulty of swallowing even water. 1859.

Dr. C. Ellis.

2131. Entire destruction of the epiglottis, with ulceration about the root of the tongue.

From a man, about thirty years of age, who had had phthisis for years, and aphonia for several months. 1861.

Dr. C. Ellis.

2132. Extensive ulceration of the larynx and under surface of the epiglottis. — From a man, æt. thirty, who died of phthisis; and with aphonia for the last six months. (Hospital, 160, 170.)

As usual there was no tubercular deposit about the ulcers. 1850.

Dr. J. B. S. Jackson.

2133. Deep ulceration, with tubercular deposit, in the anterior, upper part of the trachea; the mucous membrane being otherwise healthy. 1861. *Dr. J. B. S. Jackson.*

2134. Larynx, with a small portion of the trachea, showing very numerous, defined, and small ulcers scattered over the whole surface. And the same were found throughout the trachea and into the primary bronchi.

From a young man, æt. seventeen years, who died of phthisis at the hospital (204, 246). 1856.

Dr. C. Ellis.

2135. Thibert's model. Glanders in man. Pustules and ulcerations upon the under surface of the epiglottis. 1847.

Dr. J. C. Warren.

2136. Extensive ulceration of the larynx, and probably of syphilitic character.

From a man, æt. thirty-eight, who had been under the care of Dr. J. for five years before his death, and had been treated for the same disease for one year previously. There was extensive ulceration of the nostrils, with occasional discharges of bone, and a falling in of the septum; and every portion of the throat was successively attacked; the velum, uvula, and tonsils becoming curiously joined together by cicatrized bands. The voice was husky, and there was considerable pain, with dysphagia. The disease would be apparently arrested for some months, but would reappear upon the suspension of treatment. During the last year he had severe cough, with loss of flesh and appetite; and died finally from acute pneumonia.

The inner surface of the pharynx looked as if cicatrized after a burn. Upon the edge of the epiglottis, and as low down as the vocal cords, are little, smooth, rounded nodules; with an appearance of cicatrization between them. The cords themselves are ulcerated; and the lower portion of the larynx is nearly surrounded by a ragged, burrowing ulcer, the surface of which was covered with pus. Below this the mucous membrane was sufficiently healthy. 1856.

Dr. J. S. Jones.

2137. A warty-looking growth from about the ventricle of the

larynx, upon the right side ; with ulceration and roughness of the membrane upon the left.

From a little boy, ten years of age, who for several years had had frequent attacks of what was thought to be croup. After one of them, in Nov., 1850, he lost his voice, and never recovered it. In May, 1851, he was seen by Dr. J. Crosby, of Manchester, from whom this history of the case was received. He was then pale and emaciated, with an anxious expression, great dyspnœa, and making strong voluntary efforts during inspiration. Larynx not enlarged nor tender. Cough and expectoration slight ; with no physical signs of disease of the lungs or heart ; and Dr. C. regarded the case as one of low inflammation, and thickening of the mucous membrane of the larynx. The symptoms increased, and the patient died the following winter or spring. Dr. M., who made the dissection, reported a soft, polypoid growth, of a pinkish color, about the size of a chestnut, conical in form, attached by the apex, and nearly filling the cavity of the larynx ; so that the patient died from suffocation.

The specimen was sent to Dr. W., who had seen the case during life. 1859. *Dr. J. Ware.*

2138. A well-defined, rounded, fleshy growth, rough upon the surface like a syphilitic wart, and attached broadly just below the ventricles of the larynx. Having been cut through when the larynx was opened, it had a fibro-cellular appearance ; and, microscopically, was found to be epithelial in structure.

From a man, æt. about fifty years, very fleshy, and in robust health, excepting his local disease. For twelve years, or more, there had been hoarseness, with wheezing, and for the last two or three years complete aphonia. There was also much dyspnœa on over-exertion ; and, when asleep, a distressing noise, as from impending suffocation. Death at last was rather sudden, and seemed owing to congestion of the lungs. 1850.

Dr. Augustus Mason, of Brighton.

2139. A polypoid growth from the trachea. It was described by Dr. F., in the recent state, as firm in consistence, of a rosy color, and about the size of a small grape. The ped-

icle being attached to the trachea, at the entrance to the right primary bronchus, it had acted as a ball-valve, allowing expiration, but forbidding inspiration. Dr. Ellis, who examined it microscopically, found it composed of small granular corpuscles, and with nothing like lobular structure, though to the naked eye it appeared to separate into many minute and very loosely coherent lobules.

From a young married woman, who had a violent attack of asthma in May, 1859, relieved by the inhalation of ether, and followed for some days by profuse expectoration of thick mucus. The attacks became more frequent and more severe; and from March, 1860, till August, she never lay down in bed. She then had measles, after which she rapidly grew better, and remained in tolerable health during the winter and spring. About the 1st of July she was compelled by poverty to give up her only child; a severe attack soon followed, and she died about a fortnight afterward. (*Med. Jour.* Vol. LXV. p. 309.)

Dr. F. remarked that he had consulted many authors, but had found no allusion to polypus of the trachea. 1861.

Dr. Wm. C. B. Field.

II. LUNGS.

2140. A large portion of one lung, showing strongly marked pulmonary emphysema; from a male subject.

2141. And a small portion of the same, cut open. Dilatation of the air-cells excessive; and without any appearance in either specimen, of the interlobular form of the disease. Dried specimens. 1859. *Dr. R. M. Hodges.*

2142. A thin cyst upon the surface of the lung, of the size of an English walnut, and that was filled with air. Dried, and cut open. 1854. *Dr. R. M. Hodges.*

Emphysema between the pericardium and sternum. (See No. 1912.)

2143. The entire left lung, showing the effect of very great compression, by effusion into the pleural cavity. Length of the organ $4\frac{1}{2}$ in., and largest diameter 1 in. Form elongated, and sufficiently regular, excepting a small process, $\frac{3}{4}$ in. in length, and which, though not itself adherent,

may have resulted from the separation of an old adhesion; the lung being otherwise free. The amount of serum in the pleural cavity was only $\frac{3}{4}$ viij.

From a lady, æt. forty-four years, who had been out of health for three or four years, and died of cancer of the abdominal organs. For many years previously she had suffered from "asthma," but with the general appearance of good health. 1860. *Dr. C. Ellis.*

2144. Spurious melanosis. No. 440, in the Cabinet of the Soc. for Med. Improvement, was from the same subject, and the following history of the case is from the catalogue. Nearly the whole left lung was almost coal-black, and uniformly so. It felt, also, as if it contained tubercles, but none were distinguished; though about midway, posteriorly, there was a small cavity filled with pus. On the right side the middle lobe was similarly affected, the lower somewhat so, and in the upper there was a cavity as large as the fist. No black matter was found in the other organs.

From a man, about forty years of age, who died of "phthisis;" the expectoration being generally characteristic, but for two months unusually dark. 1847.

Dr. J. C. Warren.

Five models by Thibert. 1849.

Dr. J. Ware.

2145-6. Pulmonary apoplexy; ext. and int. view. From a child eight months old.

2147. Hepatization, with minute tubercular granulations.

2148. Large abscess in the lung; and limited by perfectly healthy tissue.

2149. Hepatization of a portion of the lung, with softened tubercles. A large, gangrenous-looking cavity at the apex, and small cavities upon the cut surface. Upon the serous surface long streaks of softened, opaque deposit.

2150. Two microscopic preparations, by Dr. E., of a hepatized lung. 1868. *Dr. Robert T. Edes.*

2151. Abscess of the left lung, the result of acute disease.

From a woman, æt. sixty-five, previously healthy, and attacked with acute disease, during the first week of May.

Entered the hospital May 31st (197, 168), with "lung fever." The acute symptoms soon subsided, but on the 2d of July she had a paroxysm of cough, with hæmoptisis. The cough, which had not been at all urgent before, increased. On the 6th the expectoration became quite profuse, purulent, and tinged with blood; and so continued for some days, but finally diminished. Great prostration followed, with dyspnœa, and she died on the 20th.

There was subacute inflammation of both pleuræ. The base of the left lung was compressed; and in its substance was a cavity about 3 in. in diameter, containing a brownish fluid, communicating freely with the bronchi, and traversed by delicate bands; inner surface flocculent, and formed by the pulmonary tissue. In the ant. inf. portion of the right lower lobe was an abscess about the size of a hen's egg, and similar to the one upon the other side. There was no appearance of pneumonia about these cavities; and, excepting the remains of former tubercular disease at each apex, the lungs were otherwise healthy. (Med. Jour. Vol. LIII. p. 367.) 1855. *Dr. C. Ellis.*

2151½. A portion of the lung of an ox, showing the great thickening of the interlobular cellular tissue, generally observed in the "pleuro-pneumonia," or "cattle disease," that was so prevalent in this State a few years ago. (See Report of the Mass. Board of Agriculture for 1860, p. 68.) 1863. *Dr. C. Ellis.*

2152. A section of one of the lobes of the lung of a dog, minutely injected by Mr. John Arthur, of the University of Edinburgh, and given by him to Dr. J. in 1851.

There was a mass of disease larger than a hen's egg, consisting of an infiltration of an opaque, whitish, crumbling material, and within this a compact, uniform, earthy structure, so that the greater part of the mass would be described generally as "ossified." This last does not appear in the preparation, which is in spirit; but was well shown in the other half, which was dried. The disease is tolerably defined; and the structure of the lung is otherwise healthy. 1852. *Dr. J. B. S. Jackson.*

2153. A defined, old, rounded cavity, at the apex of the left

lung, 4 in. or more in diameter, and opening freely into the bronchi. It is traversed by a firm band, but the inner surface is regular, and the parietes are in part thin.

From a man, æt. thirty-seven, who had active hæmoptisis, violent cough, and hectic in 1853. In March, 1854, he was seen by Dr. Bowditch, who found the respiration quite obscure over the upper two-thirds of the left lung, and with some râle, but without bronchial respiration or bronchophony. The symptoms continued, and in April he raised a pint and a half of blood, but was at work on the following day. In Oct. he was able to walk to the office of Dr. B., who then found dulness on percussion in front, upon both sides, and with coarse crackling over the upper two-thirds of the left. Failed rapidly, and died in Feb., 1855.

One or two small cavities were found in the upper left lobe, besides the large one; and numerous miliary granulations throughout both lungs.

The point of interest in the case is, negatively, the want of correspondence between the actual disease and the physical signs. 1856.

Dr. C. Ellis.

2154. A cretaceous mass, from the lung, about $\frac{1}{2}$ in. in diameter, and surrounded by a dense cyst. Cut open and dried. 1859.

Dr. C. Ellis.

2155. A few minute cretaceous bodies, that were expectorated by a middle-aged man, who had an acute tubercular attack after measles. He was a physician, and was sick for several months, but fully recovered; the whole amount of the concretions that were thrown off being about a teaspoonful. 1869.

Dr. H. J. Bigelow.

2156. Echinococci.

The apex of the left lung is shown, upon the surface of which is a white, dense, fibrous tissue, about an inch in diameter, and 1 or 2 lines in thickness; with other thin patches of the same near it. Beneath this was a layer of pulmonary tissue, of about the same thickness; and beneath this a cavity $\frac{3}{4}$ in. or more in diameter, filled with serum, and lined by a thin, bluish-white membrane, which was everywhere studded with yellowish-white points. Most of the serum was lost; but that which remained was of a

yellowish color, and contained a large number of echinococci, detached hooks, and a few concentric corpuscles. The lining membrane was covered with the same parasites; and presented the usual striated appearance. The lungs, otherwise, were quite healthy.

From an old man, who died of disease of the bladder. (Med. Jour. Vol. LVII. p. 218.) 1857. *Dr. C. Ellis.*

2157. A portion of thick, false membrane, dissected off from the lung; the result of former pleurisy. No. 1575 was from the same patient. 1868. *Dr. C. Ellis.*

2158. Pneumothorax.

A portion of the upper back part of the right lower lobe, showing a cavity, about the size of a large nutmeg, and from this a perforation into the pleural cavity, about 2 lines in diameter; with another small cavity near it, and a small, old tubercular mass. There was another small cavity, also, at the apex of the lung; the whole disease being evidently of long duration, and in a state of arrest. The lung was much compressed; the cavity of the pleura containing nearly a quart of pus, and the whole surface being thickly covered with recent lymph.

From a young sailor, who had had cough, and was seen by Dr. B. a week before his death, with much dyspnoea, great prostration and suffering, and a very rapid pulse. The right side of the chest was very prominent, resonant, and without respiratory murmur; and metallic tinkling had been heard. 1852. *Dr. H. I. Bowditch.*

2159. Empyema.—The patient, æt. twenty-three years, had been sick about five months, and entered the hospital July 4th (237, 162). There was pointing between the ribs, upon the left side, and in two places. On the 5th four pints of pus were drawn off, and on the 22d four more; and on the 17th of August he died from copious hemorrhage into the pleural cavity.

The whole left pleural surface was covered with a firm, thick, false membrane, and in many places the costal pleura and parietes were deeply eroded; the ribs being denuded at several points. The lung was tubercular.

A portion of the parietes of the chest shows the appear-

ances well, and also an opening between the ribs, about $\frac{1}{3}$ in. in diameter; air entering freely into the chest before death. 1863. *Dr. C. Ellis.*

2160. A cyst between the lung and the diaphragm of one of the cattle that was killed during the summer of 1861, and when the "cattle disease" was prevalent. It is about 6 in. in diameter; the parietes are thick and dense; and the contents, which have been removed, consisted of a yellow fibrinous material, and calcareous matter. (See Report of the Mass. Board of Agriculture, for 1860, p. 68.) 1862.

Dr. C. Ellis.

2161. A thick, cretaceous plate, that in the recent state almost lined the whole inside of the chest upon the left side. There was great contraction of the side, great compression of the lung, and universal, thick, and very strong pleural adhesions. Some adhesions, also, upon the right side, and tubercular disease of the lung.—From a middle-aged woman. 1856.

Dr. Wm. Bushnell.

2162. A small plate of cretaceous matter, about 2 in. in length, and that was situated in a thick layer of condensed fibro-cellular substance, that bound the right lung to the costal parietes.

From a man, æt. sixty-five; the result, probably, of a disease that occurred about fifteen years before death, and that lasted about a year.

The resemblance between these formations, that result from inflammation of the pleura, and those that are found in the bronchial and mesenteric glands, as the result of "tubercular" disease, is often very striking, and tends to show an alliance between this last and the process of "inflammation." 1853. *Dr. J. B. S. Jackson.*

2163. A third specimen; mostly in one piece, and altogether larger than the palm of the hand.

It was from an adult, and situated in the midst of universal, fibro-cellular pleural adhesions. 1858.

Dr. R. M. Hodges.

A fourth specimen; in connection with the ribs. (See No. 1586.)

2164. Cast, in plaster, of the trunk of a child, showing a great

degree of contraction of the left side of the chest, after paracentesis for effusion into the pleura. There is, also, a great degree of shortening, and consequently a strong inclination toward this side. The situation of the former punctures is seen.

The following history of the case was obtained by Dr. C. Ellis, who purchased the specimen for the Museum in 1851, in London; and who, at the same time, visited and examined the child. She was then eight years old. When three years of age she had what was thought to be "fever." At the end of six weeks the side was much enlarged, and was punctured, with great relief, at the London Hospital; and during the next twelve months the operation was repeated five times. Finally, a spontaneous opening took place near the cartilage of the seventh or eighth rib, and the discharge continued until the last eighteen months or two years. Contraction of the side began immediately after the first operation; and the mother thought that it was still going on. Dr. E. found the respiration puerile upon the right side, and absent upon the left. The child was then perfectly well, and was attending school regularly. 1852.

Museum Fund.

Large fibro-nucleated tumor in left pleural cavity. (See No. 3002.)

2165. A portion of the parietes of the chest, showing numerous cancerous growths upon the pleural surface.

From a woman, *æt.* seventy-two years, who had a large encephaloid tumor removed from the thigh by Dr. G. H. Gay, in Sept., 1858. (Hospital, 79, 250.) The disease, which was of five or six months' duration, was removed a second time in Nov., reappeared in Dec., and she died on the 9th of Jan. From the 23d of Dec. she complained of a sharp pain in the left side of the chest, and some cough; and, on examination, there was found dulness on percussion, with diminished respiration over the lower half of the side.

On dissection, the left pleural cavity contained five pints of serum. Lung partially adherent. Upon both pleural surfaces were many bright red, smooth nodules, from a line to 2 in. in diameter; most numerous, and largest over the

diaphragmatic and lower part of the costal pleura, where they were almost continuous. Among these were a few small, whitish, semi-gelatinous, pediculated growths, and entirely different from the above. There was no disease of the kind in the other pleural cavity; but in both lungs were soft, whitish, encephaloid masses, and the same was found in the bronchial glands, and in the liver. Microscopically, there were found elongated cells, and many of them were quite long; in these were elongated nuclei, some with distinct and large, but more with indistinct nucleoli. All were more or less granular. A few large, round or oval bodies were seen; probably free nuclei, and some contained well-marked nucleoli. The tumor upon the thigh showed cells that contained many granules, or minute globules, and which were evidently degenerating, though to the naked eye the color did not indicate it. There were also a few large and well-developed nuclei and nucleoli; and in the tumors removed during life there was a marked difference of appearance in different portions. 1859.

Dr. C. Ellis.

2166. A drawing, in water-colors, by Mr. D., of the pleural disease, in the above case, and as it appeared in the recent state. 1859. *Mr. John Dean, med. student.*

Diseases of the bronchial glands. (See No. 1842, etc.)

SERIES XXX. — ALIMENTARY CANAL.

I. ŒSOPHAGUS.

2167. Laceration, nearly 2 in. in length, and just above the stomach.

From a man, who was struck by a railroad train, and lived about two days. The œsophagus was torn away from the spine, so that the hand passed freely from one pleural cavity into the other. Other grave injuries were also found. (Hospital, 116, 64.) 1864. *Dr. C. Ellis.*

2168. Wound by a chicken bone. Case reported by Dr. Wm. Osgood, in the Med. Jour. Vol. LXVI. p. 165.

The bone was swallowed on the 22d of Nov. by a little girl, eleven years of age, but it seemed to pass down as Dr. O. depressed the tongue. Two days afterward severe symptoms came on, and she died on the 1st of Dec.

A longitudinal and sharply cut slit is seen in the œsophagus, anteriorly, just below the larynx, about one-third of an inch in length, and extending through all of its coats. Extensive, diffuse, cellular inflammation was also found, extending to the ant. mediastinum, with pericarditis, pleurisy, and peritonitis. 1862. *Dr. C. Ellis.*

Hemorrhage into the œsophagus, from the subclavian artery. (See No. 1799.)

2169. Cut-throat.

From an insane woman, æt. fifty-six years, who had previously attempted suicide. A cut was made, with a very dull carving-knife, down to the spine, between the thyroid and cricoid cartilages, and completely divided the œsophagus; the carotid, jugular vein, and par vagum, as afterward appeared, being uninjured. An elastic tube was carried into the stomach; and the divided extremities of the œsophagus were brought into perfect contact by a suture upon each side, and one in front. The larynx and trachea were then brought together by a strong suture upon each side, and the integuments by two stitches; leaving an opening through which the patient could breathe. The patient was very tractable, seemed to suffer but little, and died within twenty-four hours.

On dissection, the cellular tissue between the œsophagus and spine was perfectly infiltrated with thin pus from the wound to the diaphragm, though the patient lived so short a time; and the two portions of œsophagus, though gaping posteriorly, are otherwise in perfect contact. In the preparation this last is shown, but the stitches in the larynx, and in the integument have been cut away; and a glass rod has been passed into the carotids. The knife and tube are also shown. (*American Jour. of Med. Sc.*, Jan. 1853, p. 95.) 1854. *Dr. B. E. Cotting.*

2170. Stricture of the œsophagus, from a woman, æt. forty-seven years, who had had dysphagia for ten or twelve years, and seemed at last to die from inanition. Several

ineffectual attempts had been made to pass an instrument ; and shortly before death considerable force was used.

“The stricture commences quite abruptly about opposite the upper edge of the cricoid cartilage, is about 1 in. in length, and not more than 3 or 4 lines in circumference upon the inner surface, at the narrowest part. The parietes are firm to the feel, consist of a homogeneous, pearly white, condensed tissue, without any appearance of muscular structure, and, at the time of the dissection, cut like gristle. The mucous membrane, however, is continued over it, and seems to be very little altered in structure. Just above the stricture is something like a small ulcer, but confined to the mucous membrane ; and a little higher up is a small opening, leading downwards into an irregular abscess in or about the thyroid gland, capable of holding about a drachm, and containing some moderately thick pus. Immediately above the stricture, and upon the right side, there is a fresh laceration, leading downwards, and evidently made by an instrument. There was no dilatation of the fauces, but the mucous membrane just above the stricture was a little red, and perhaps excoriated.” 1861.

Dr. B. E. Cotting.

Of several cases that I have examined, and that had been regarded during life as stricture of the œsophagus, all, excepting the present one, have proved to be some form of malignant disease ; and the same remark may be made of the rectum, but in this case without a single exception.

Opening into the œsophagus, from suppurating bronchial glands. (No. 1844.)

2171. Extensive and foul ulceration of the whole lower portion of the œsophagus, without thickening, or any appearances of cancer.

From a man, æt. sixty-eight, who had had many of the symptoms of stricture for more than a year. (Med. Jour. Vol. LII. p. 222.) 1855. *Dr. J. B. S. Jackson.*

2172. Ulceration of the œsophagus, and opening into the lower part of the trachea. — The disease involves the whole circumference of the canal, and is more than 2 in. in extent, more than 1 in. in width where cut across, and without

thickening of the surrounding tissues, or any appearance of cancer. The opening into the trachea is about $\frac{1}{2}$ in. in diameter.

From a woman, *æt.* forty-two, who reported that she had had "stricture of the *œsophagus*" for twenty-four years, and that it was owing to her having swallowed a chicken bone. For the first two or three years she could take only very small quantities of food, and her health was greatly reduced. She was then relieved by bougies; and from that time her disease gave her very little inconvenience until about three months before death, when the obstruction increased, with soreness and pain, and toward the last most distressing dyspnoea. Swallowing of food became almost impossible; and the paroxysms of dyspnoea resembled the spasmodic croup of infants. There had been cough from the first, but no expectoration until the last few days; there being, at last, occasional gushes of purulent matter, and in considerable quantities. (*Med. Jour.* Vol. LXIX. p. 275.) 1863.

Dr. T. H. Gage, of Worcester.

2173. Encephaloid disease of the pharynx and *œsophagus*.

From a woman, forty-two years of age, who, for five or six years before death, had had dysphagia, and been disturbed in her sleep by a peculiar sonorous sound about the larynx. About ten months before death the dysphagia increased, so that she could not take her usual food; with a cough, to which she had been subject, and great irritation about the larynx. By the use of a probang the passage was enlarged, and deglutition became so much easier that she left the city on a journey; but, on her return, four or five weeks afterward, she was worse than ever, and there was a great deal of pain in the back of the neck, and through the ears. From this time she sank, with very little pain or cough; but suffering mostly, toward the last, from the accumulation of viscid mucus in the throat.

The disease was remarkably limited; extending as high as the top of the arytenoid cartilages, and as low as the lower edge of the thyroid. Posterior and lateral portions of the canal affected, but the anterior portion was throughout quite healthy. The diseased structure was from one-

fourth to more than one-half an inch in thickness, white, soft, and upon the inner surface uneven ; the passage through it being sufficiently free. Just above the limits of the disease was the opening of a dark and offensive cavity, that burrowed down between it and the larynx, and that would have held about two drachms. The other organs were healthy. In the preparation the œsophagus is cut through posteriorly. 1855. *Dr. Charles E. Ware.*

2174. Deep cancerous ulceration opposite the lower half of the trachea, with much induration of the surrounding cellular tissue ; and surface quite rough. The disease begins rather abruptly somewhat below the upper part of the trachea, and extends about 3 in. downward. Œsophagus quite healthy above the disease ; but, below, it is superficially and irregularly ulcerated as far as the stomach, though neither indurated nor much thickened. A portion of the stomach is shown, and appears healthy.

From a man, æt. fifty-four years, who had had "stricture of the œsophagus" for about fourteen months ; was after a time told that his disease was malignant ; and in two days he committed suicide. (Hospital, 89, 158.) 1861.

Dr. C. Ellis.

Cancerous disease of the pharynx, extending to the œsophagus. (See No. 2107.)

II. STOMACH.

2175. Gizzard of a fowl, transfixed by four pins ; given to Dr. H. by a dealer in poultry, who observed nothing otherwise unusual about it. The cavity was filled with food. Dried. (See No. 2318.) 1859. *Dr. R. M. Hodges.*
2176. Hour-glass contraction, midway, and strongly marked. Distended and dried. 1855.
Dr. Wm. D. Buck, of Manchester, N. H.
2177. Thibert's model. Gelatiniform softening, with perforation. 1849. *Dr. J. Ware.*
2178. Cadaveric softening, with perforation of the diaphragm. From a healthy infant, twenty-two months old, that died with acute pulmonary symptoms of about thirty-six hours'

duration, and had had no symptoms whatever referable to the stomach. On examination, fifteen hours after death, the whole left extremity of the stomach was found open, and the contents of the organ effused into the cavity of the abdomen; with a defined brownish discoloration of the surface of the spleen, where it had been acted upon by the secretions. In the membranous portion of the diaphragm were two perforations through into the left pleural cavity; they were not more than 2 lines in diameter, and but little of the fluid had passed through. No inflammation of either serous membrane, and no softening of the œsophagus. The whole stomach is shown, with a portion of the diaphragm. 1854. *Dr. E. H. Clark.*

2179. Colored cast of the external appearances in a case of extensive rupture of the stomach in a horse.

It was supposed that the animal strained himself in attempting to draw a very heavy load, about 11 A. M., and that a partial laceration then occurred. He worked, however, as usual through the day, though he did not eat very well at noon. In the evening, as he appeared to be sick, Dr. Stickney was sent for, and was with him until midnight; there being pain in the abdomen, with eructations of flatus. About 4 A. M. he became very much worse, and at 8 A. M. he died.

On dissection, not far from a bushel of undigested food was found in the stomach and peritoneal cavity. The laceration was in the anterior parietes of the organ, and near the small curvature; extended about 11 in. through the peritoneal coat, and $7\frac{1}{4}$ in. through the mucous; the muscular being extensively laid bare by a stripping up of the peritoneal.

It was supposed that the stomach must have been distended by food at 11 A. M., that a laceration of the peritoneal and muscular coats took place then, and that the mucous coat gave way at 4 A. M. 1868.

Museum Fund.

2180. A portion of the stomach of a horse, showing several larvæ of the bot-fly hanging from the cuticular portion, and several depressions upon the adjoining mucous sur-

face, from which others (No. 3088.) had been detached. 1868. *Dr. J. P. Stickney.*

2181. Thibert's model. Mucous membrane ecchymosed. Hæm-atemesis. 1849. *Dr. J. Ware.*

2182. A stomach, showing the "hemorrhagic erosion" of Cruveilhier.

From a little boy, six years old, who died with cirrhosis, ascites, and cerebral symptoms, but with nothing referable to the stomach. (Hospital, 237, 182.) Within 2 in. of the pylorus were very numerous "depressions, about a line in diameter, round, sharply defined, and without a trace of vascularity; bases formed by the sub-mucous cellular coat." 1861. *Dr. C. Ellis.*

2183. Thibert's model. Inflammation, acute and chronic. 1849. *Dr. J. Ware.*

2184. —. Acute inflammation, from poisoning; ulceration quite defined. 1849. *Dr. J. Ware.*

2185. Ulceration of the stomach from a man, æt. fifty-nine years, who had had dysenteric diarrhœa more or less for about fifteen months. The appetite was good; and the prominent gastric symptom was a sense of sinking.

"In the pyloric portion of the stomach were many ulcers, more or less irregular, and the largest from a third to half an inch in diameter. They presented none of the appearances usually found in chronic ulcers, but resembled those found in the intestine; margins undermined, and bases formed apparently by the muscular coat. The mucous membrane was not materially changed."

The intestines also (No. 2286) were extensively and similarly ulcerated. (Med. Jour. Vol. LXIV. p. 549.) 1861.

Dr. C. Ellis.

2186. A portion of the stomach, showing about the middle of the small curvature a defined ulcer, about an inch in diameter, and another about one-third as large; base smooth, and formed by the muscular coat. Surrounding mucous membrane corrugated; and, when recent, dark red or slate colored. Near these were several smaller ulcers, irregular and superficial.

From a woman, *æt.* sixty years, who died of phthisis. Stomach scarcely referred to. (Hospital, 225, 160.) 1860.

Dr. C. Ellis.

2187. Two ulcers in the small curvature, $\frac{1}{3}$ in. and $\frac{1}{2}$ in. in diameter. Circular, and sharply defined; base formed by the muscular coat, and partially blackened. The organ was otherwise sufficiently well.

From a woman, *æt.* fifty-eight years, who died of disease of the heart, and without any suspicion of the stomach. 1861.

Dr. C. Ellis.

2188. Chronic ulcer, in the small curvature, midway; $\frac{3}{4}$ in. in diameter; circular; base formed by sub-mucous cellular tissue, which has a deep brown color; edges defined, but not at all thickened.

From a man, *æt.* thirty years, who died from an abscess of the liver opening into the lung; the stomach having never been suspected. (Hospital, 208, 177.) 1857.

Dr. J. B. S. Jackson.

2189. An ulcer in the small curvature, midway; and about 1 in. by $\frac{3}{4}$ in. in diameter; parietes about it very greatly thickened, indurated and contracted.

From a woman, *æt.* thirty-two years, who had had symptoms of the disease for eighteen years. 1852.

Dr. C. G. Mann, of Newton.

2190. An ulcer, more than 2 in. in diameter, very defined, without thickening or other change of its edges; and throughout its whole extent the base was formed by the pancreas, as in a case figured by Cruveilhier.

The following facts in the case were received from Dr. James Jackson, the attending physician for many years:—

“The patient was eighty-one years of age; had always been an active merchant, and continued to attend somewhat to business until the last year of his life. General health good, until the spring of 1858, when he began to complain of pain in or near the epigastrium, passing through to the back, and recurring frequently every day. He also felt weak, and was troubled by his food. In July, he vomited a large quantity of blood, fainted from the effects of it, and was enfeebled, so that he was upon his

couch for one or two weeks. Dr. J. then regarded the case as one of chronic ulcer of the stomach. The pain was immediately relieved, and there was no return of it until December. It then came on again, and was rather increasing, when, in January, 1859, he fell, and injured his hip. In consequence of this accident he kept his bed for a month, and the house for two months; and during this time his stomach was much better than it had been before, — showing the effect, as Dr. J. supposed, of entire rest, and a rigidly simple and abstemious diet. For some months he continued better, and went on tolerably well, until towards the latter part of the summer of 1860, when he began to have dyspeptic symptoms, with loss of flesh and strength; the pain returned about midsummer, and increased in severity, so that, during the last few weeks, opiates were required. The appetite failed in November, and never returned; food caused great distress, though he was very cautious as to the quantity, and generally as to its quality. Vomiting came on, and by this the distress was temporarily relieved; the matters vomited consisting mainly of the food, though, towards the last, mixed with a dark matter, probably the secretions colored by blood. The bowels were sufficiently well, until he began to use the opiates; and no tumor was ever felt in the epigastrium. Finally, in January, he became limited to very small quantities of nutritious liquids and stimulants; being confined to the house, and mostly to his couch. He sat up, however, more or less, until a week before his death, enjoying his friends, and being able to go up two flights of stairs to bed, every night. An acute pulmonary affection then came on, and under this he sank." (Med. Jour. Vol. LXIV. p. 307.) 1861.

Dr. J. B. S. Jackson.

2191. Ulcer from a man, æt. forty years, who had been subject for several years to constipation and nausea; the latter never severe, and generally relieved by vomiting his food. Died at last from perforation, after an illness of about thirty-six hours. The stomach adhered toward its right extremity, to the under surface of the liver, and the parietes there were vere very much thickened to the extent of

two inches and a half. In the centre of this thickened portion an old ulcer, about $\frac{3}{4}$ in. by $\frac{1}{2}$ in. in diameter, with bevelled edges, and extending through to the liver; and at the lower edge perforation had taken place. (Med. Jour. Vol. LXII. p. 21.) 1861.

Dr. T. E. Francis, of Brookline.

2192. The ulcer here commences at the pylorus, and involves the entire thickness, and almost the entire circumference of the organ. Parietes very little thickened or indurated; but beneath the ulcer is a cavity larger than itself. The base of the ulcer, or rather of the cavity beneath it, which is formed by the pancreas, is perfectly smooth, with a free opening upon one side, into the peritoneal cavity.

From a gentleman, æt. seventy-two years, who had been subject to pain in the epigastrium for about twenty years, coming on two or three hours after taking food, and passing through to the back. He suffered also from dyspepsia, flatulence, foul eructations and constipation. About a month before his death he was in bed, with a very morbid countenance, and was supposed to have a malignant disease of the stomach; there being a vomiting of blackish matter, and a very distinct tumor in the epigastrium. This last, however, disappeared in a week or ten days; and as the patient was otherwise relieved, the diagnosis was then doubtful.

The symptoms of perforation were less marked than usual; and the patient had been out, and about as well as usual, a few days before. 1861.

Dr. J. B. S. Jackson.

2193. An ulcer, $1\frac{1}{2}$ in. long, of an oval form, and without thickening. Perforation 2 or 3 lines in diameter, and looking as if a piece of the base had been punched out. 1862.
2194. Ulcer from an insane woman. It is in the small curvature, midway, and about as large as the finger-nail. The perforation, from which the patient died, is quite large. 1865.
Mr. R. L. Dryer, med. student.
2195. The same. From a woman, æt. forty-eight years, who had been generally healthy, and died about fourteen hours

after perforation took place. The ulcer, which is in the anterior parietes, midway, is about the size of the thumb-nail; and the perforation is about $\frac{1}{2}$ in. in diameter. (Med. Jour. Vol. LXVII. p. 421.) 1862. *Dr. F. E. Oliver.*

2196. A shallow, ovoid, chronic ulcer, in the small curvature midway, about $1\frac{1}{2}$ in. by $\frac{1}{2}$ in., and in the base a perforation about three lines in diameter. Almost directly opposite, and in the posterior parietes of the organ, is a second ulcer, deeper and more defined, and in extent $1\frac{1}{2}$ in. by $\frac{3}{8}$ in.; perforation being only prevented by external adhesions. The organ was collapsed, and otherwise healthy. The peritoneal cavity contained a large amount of pus, and of offensive gas; and the liver was pushed very much upwards and backwards.

The patient was an ice-dealer, æt. twenty-six years, and of good general health. Served in the civil war for four years, and was well during that time, excepting an attack of intermittent fever. Had also occasional cramps in the stomach, with vomiting of a greenish fluid. About two years ago, while pushing a large block of ice up an inclined plane, it slipped; and, as he caught it with his pole, the end of this last came against the pit of his stomach, or near there. He was obliged, on account of the injury, to stop work; and, $\frac{3}{4}$ ij. of senna having been prescribed, he took, by mistake, the same amount of the tincture of arnica. Soon after this he vomited a dark substance that is said to have looked like blood; and from that time he was never well, though he attended to his business until the fatal perforation occurred.

There was generally free vomiting of a yellowish fluid, about two hours after eating; without the food, but with relief, and usually without much nausea. Sometimes a day or two would pass without vomiting; and several times he thought he saw blood in the matters vomited. Oppression at the stomach was nearly a constant symptom, and there was quite often a pain that he compared to the "cutting with a dull knife," with an occasional cramp for an hour or two; and, when going about in his wagon, he would lean forward and press upon the epigastrium. His appetite was quite good, and his bowels rather costive. In his

general appearance he did not look sick, though he had lost flesh.

Early in the night of Feb. 9th perforation took place, and he died on the 28th at 7 P. M. The pain at first was intense, and was very greatly increased by motion; afterwards it was very considerably diminished, but occurred in paroxysms, and towards the last it was rather dull. Pressure, however, was very tolerably borne, and as well over the epigastrium as elsewhere. At first there was great pain, also, in the left shoulder, but this gradually subsided at the end of a week. To relieve the pain, there was given throughout about three grains of morphine daily, by enema. Tympanites was slight at first, but became very great after the ninth day, and so continued till death, causing great dyspnœa. Respirations from 30-50 per minute; and the pulse, which was about 70 at first, rose at last to 120.

The very unusual time that the patient survived the perforation in this case was remarkable, as death usually occurs within forty-eight hours. And it may be a question whether the external injury above referred to, or the arnica, could have had anything to do with the formation of the ulcers, inasmuch as there were some gastric symptoms before these suspected causes occurred. (*Med. Jour. Vol. LXXX. p. 168, April 8th, 1869.*) 1869.

Dr. Chas. E. Hosmer, of Waltham.

2197. Two ulcers in the small curvature, and toward the pylorus, about half an inch in diameter, very defined, with firm, smooth, sharply cut margins, and firm bases that seemed formed by the submucous cellular coat.

From a man, æt. thirty-eight years, who had had diarrhœa for about nine months, and commencing with dysentery. On admission into the hospital (71, 241) he had a feeling of oppression and pain after taking food, that led Dr. Minot, the attending physician, to suspect chronic ulcer of the stomach. (*See No. 2285.*) 1864. *Dr. C. Ellis.*

2198. A portion of the stomach, showing an elongated, superficial, ill-defined ulcer, about an inch in length. Surface partially discolored, with considerable thickening upon one side, and an appearance as if it had advanced far toward

cicatrization. The situation of the ulcer was in the small curvature, and toward the pylorus.

From a woman, æt. twenty-six years, who died at the hospital (89, 144) of disease of the breast, with pleural effusion. She had had vomiting for four months, and it was urgent toward the last, with great distress, and a gnawing sensation at the stomach rather than pain; there was also much thirst, which she freely indulged. 1860.

Dr. C. Ellis.

2199. A defined ulcer, about $1\frac{1}{2}$ in. by $\frac{2}{3}$ in. in diameter; and from the base there projects the open orifice of a vessel.

From an intemperate man, who entered the hospital (277, 68) with albuminuria, and had been subject to jaundice and constipation. Not long afterward vomiting of clotted blood came on to the amount of one or two pints; and two days afterward, when it recurred, he died. 1868.

Dr. G. C. Shattuck.

2200. The entire stomach is preserved. Just at the pylorus, and extending into the stomach, is an irregular chronic ulcer, equal to about $\frac{3}{4}$ in. in diameter; not deep, without thickening, and having a brownish base. The pyloric orifice is extremely contracted, and led to a most prodigious distention of the organ, so that it occupied the greater part of the cavity of the abdomen. The stomach contained several pints of a homogeneous, blackish, soft-solid substance, that had undoubtedly been accumulating there for a long time.

From a woman, æt. twenty-eight years, who had had gastric symptoms as long as she could remember, and very urgent vomiting during the last eighteen months; her emaciation during the last few months being perfectly extreme. (Hospital, 250, 216.)

An enormous dilatation of the stomach is reported and figured in the Proc. of the Pathological Soc. of London, Vol. iv. p. 137; but the organ was certainly no larger than it was in the present case. 1863.

Dr. J. B. S. Jackson.

2201. A cast, in plaster, showing a portion of the stomach and

duodenum, with the ulcer; from the above case. Colored after nature by Mr. C. J. Blake. 1863.

Museum Fund.

2202. A polypous growth, about an inch from the pylorus, quite defined, of a soft, fleshy consistency, and about as large as the end of the little finger. It is cut open, and seems to be formed from the mucous and submucous cellular tissues; the surrounding parts being quite healthy. 1852.

Dr. J. B. S. Jackson.

2203. A very defined, smooth, regular, and prominent tumor, about the size of a nutmeg, and within an inch of the pylorus. It is fleshy, evidently benign in its character, and is probably a growth from the mucous and submucous cellular tissues; not cut through. The stomach, otherwise, was healthy.

From an old woman, who had had symptoms, for some months, that led to the suspicion of scirrhus pylorus. 1854.

Dr. J. B. S. Jackson.

2204. A very large, fatty, and fibrous tumor in the parietes of the stomach.

From a woman, æt. forty-two years, who had been growing very corpulent during the last year of her life, but was quite healthy until the middle of September, 1866; having always had a good appetite, and never made the slightest complaint of the stomach. About the time referred to she felt some discomfort on active exercise, and this gradually increased, but was attributed to her corpulence.

Nov. 5th, Dr. R. first saw her. She had been attacked in the night with pain in the abdomen, and what was reported as diarrhœa, though it was undoubtedly hemorrhage from the bowels. Under treatment, the discharges ceased for twenty-four hours, and then returned, with great pain, and a great feeling of discomfort in the bowels; described as tarry, black, offensive, and scybalous. With the looseness, there was noticed pulsation of the carotids, a waxy complexion, and slight œdema of the face, but none of the extremities. On the 9th there had been no discharge from the bowels; but she complained very much of a noise in her left ear, which was audible at a distance of two feet

from her head, and was like the chirping of a bird, or the sound of the hair-spring of a watch. During the following night the looseness returned, and before the next day she had had five or six discharges that were evidently bloody. Vision began to fail, was soon quite lost, and never returned so long as she lived. Pupils completely dilated, but became strongly contracted under the use of opiates. Two dejections only after the 11th. Gradually sank, and died on the 17th.

The stomach, which has been preserved entire, shows the tumor "confined to the anterior parietes, of a regular and flattened oval form, and sufficiently well defined. It measured $6\frac{1}{2}$ in. in length, $4\frac{1}{2}$ in. in width, and $1\frac{1}{2}$ in. in thickness, and did not approach within 3 in. of either orifice. The mucous surface over it was the seat of extensive ulcerations; one of these measured about 4 by 3 in., two others from $\frac{3}{4}$ to 1 in. in diameter, and there were others that were quite small. The edges of these ulcers were neither thickened, indurated, nor at all reddened; though the mucous membrane in the neighborhood of some of them was, in the recent state, ecchymosed. The substance of the tumor was fully exposed, so as to form the base of the three largest ulcers; and the appearance was that of a white, flaccid, tough structure, neither fibrous nor fatty, though, on incision, it seemed to be composed of these two last elements. An incision having been made into it through the serous surface, it seemed to consist of a fatty mass, with no more than the usual amount of fibrous tissue. With regard to position, it was shown to be between the mucous and the muscular coats. The stomach, which was otherwise quite healthy, weighed, since the examination, 2 lbs. $2\frac{1}{2}$ oz., and a healthy one $6\frac{1}{2}$ oz. No appearance of a malignant character in the tumor."

The intestines were full of disorganized blood. Cavity of the abdomen and anterior parietes loaded with fat; and, microscopically, fatty degeneration was shown to have taken place to a great extent in all of the tissues.

Dr. R. suggested the possibility of the tumor becoming enucleated, as fibroid tumors of the womb occasionally are, if the patient had survived the hemorrhage.

For a more detailed history of this case see *Med. Jour.* Vol. LXXVI. p. 141. 1867. *Dr. William Reed.*

2205. A large fibroid tumor in the parietes of the stomach.

From a woman, æt. fifty-six years, who died at the hospital (217, 176) of disease of the heart and kidneys. There were no symptoms referable to the stomach during the last two weeks that she was there, though she had a little nausea, on entrance, that was attributed to the motion of the carriage, in which she was carried to the hospital. A tumor, however, was felt on the left side, on a line with the crest of the ilium, between that and the umbilicus, and traceable down deep into the iliac region; nodulated on its surface, and yielding under pressure.

On dissection it was found to occupy the large curvature and anterior wall; and it was an exceedingly firm, irregularly oval, nodulated tumor. A small portion of the external surface was of a yellowish-white color, and had an almost cartilaginous appearance. The mucous membrane of the stomach extended over the part, which projected internally. At several points were cavities, caused by a loss of substance. The largest of these, about half an inch in diameter, contained a brownish slough, and extended quite deeply into the tumor. On incision, the growth was found to be very firm, of a whitish color, and presented an indistinct fibrous appearance. Examined microscopically, it proved to be purely fibroid in character. The mucous membrane of the stomach was everywhere of a bright red color, and particularly over the tumor. The other organs were examined and found healthy.

In the preparation, a large portion of the stomach is preserved, and the structure of the tumor is shown. (*Med. Jour.* Vol. LIX. p. 83.) 1859. *Dr. C. E. Ware.*

2206. A fibrous tumor, from the stomach of a tiger. — The animal was from a menagerie in this city, that was destroyed by fire. Altogether there were six of these tumors, and they were scattered throughout the body of the organ. They were quite defined, of a nearly circular form, from about three-fourths of an inch to an inch and a half in diameter, and projected very prominently into the cavity of the organ, but not at all externally; nor were there any

peritoneal adhesions about them. Three of them having been cut through, were white, very dense, apparently fibro-cellular in structure, and without the slightest appearance of malignant disease; the others had the same feel. They were evidently formed in the submucous cellular tissue, though the muscular and mucous coats had become attached in all excepting the smallest, and which was undoubtedly the one last formed. The most remarkable peculiarity in these tumors was the formation of a deep, defined central cavity, of considerable size, existing in four, with an apparent indication of it in a fifth, in the form of a dark-gray line; in the smallest tumor there was no distinct trace even of such a line. The cavity opened always upon the summit or centre of the tumor; and in two the orifice was so small, though the cavity within was of considerable size, that the idea of a follicular origin was suggested, though altogether precluded by the general character of the formations. The two smaller tumors certainly seemed to show that the cavity was a secondary formation. In the centre of one of the two largest was a deep, defined old cavity, about three-fourths of an inch in diameter; and in the hard base of it was a small opening leading into another cavity that was still deeper, and of considerable size.

Another curious fact was the crowding of the cavity of three of the tumors with some kind of small parasite, in accordance with the well-known tendency that some species have to crawl into any opening that they may happen to find in the parietes of the alimentary canal. Upon the surface of one of the largest tumors were four small ulcers just penetrating to the dense mass beneath; but otherwise the mucous membrane over the tumors generally was quite healthy, as it was elsewhere.

2207. A second tumor, from the same stomach, cut open to show the cavity within. A small portion only of the organ is preserved with the tumors. 1862.

Boston Soc. of Nat. History.

2208. A very large and anomalous tumor in the parietes of the stomach. It was situated in the posterior parietes, about equidistant between the orifices, and extended lengthwise to the organ 3 in.; the diameter was about $1\frac{1}{2}$ in., and it

projected abruptly into the cavity from five-eighths of an inch to an inch; outline smooth, but form slightly lobulated. Externally, it also projected very abruptly into the peritoneal cavity; the form was more rounded than that of the internal tumor, and there projected from it several well-defined little tumors, the largest of which was about the size of a nutmeg. The diameter of this external portion was about 2 in. As the muscular portion was very distinctly traceable to a considerable extent over this last portion, and the mucous membrane was continuous over the internal tumor, it was evident that it was situated in the submucous cellular tissue.

The structure was most remarkable. At the very extremity of the external portion was a mass, nearly the size of an English walnut, and which looked like the result of an old tubercular deposit; being quite firm or tough, pearly, with a large number of small, opaque, white spots, and a trace of cretaceous matter, but without any soft deposit. This mass was for the most part well defined, and there was nothing like it seen in any other part of the tumor. The mass above referred to, as being of the size of a nutmeg, was of a dark-red color, uniform in appearance, and as soft as a quite soft spleen. The remainder of the external portion looked not very unlike this last, but it was firmer and very much coarser in structure. The internal portion was firm at one extremity, but less so than a fibrous tumor would be. Towards the other extremity it was quite soft, as if the structure beneath was similar to that of the external portion, and in two places it looked as if the surface was about to give way. The interior of the tumor was occupied by a cavity of some size, well defined, but rather disposed to branch, having two free openings upon the mucous surface, and extending nearly through to the old tubercular-looking mass. The other organs were healthy.

The patient was a woman, sixty-seven years of age. For about a year before death she had nausea, gastric pain, and anorexia. Vomiting very rarely occurred, although nausea and a distressing faintness existed nearly all the time for the last four months. Rising in bed, or turning from side to side, would increase these symptoms.

Just before death there was vomiting of glairy mucus, with minute 'coffee-ground' particles, and for three months before death a movable tumor could be felt in the epigastric region. 1862.

Dr. Alfred Hitchcock, of Fitchburg.

2209. Colloid disease, from a very healthy-looking woman, forty-five years of age, who had been dyspeptic for about a year; with frequent vomiting, distress at the stomach, and loss of appetite for five or six weeks. Tumor in epigastrium when Dr. S. first saw her, two weeks before death. Her appearance of health was preserved to the last; and she was out as usual within a month of her death.

The disease was strongly marked anatomically; involving the whole pyloric portion, to the extent of 4 or 5 in., and just encroaching upon the duodenum. The mucous membrane was first affected, and afterward the muscular; the submucous cellular being but little if at all implicated. Maximum thickness two-thirds of an inch. Surface slightly ulcerated. From the anterior face of the organ there projected externally a mass of the same disease, of considerable size; and from the posterior face a similar, but smaller mass. There were also two or three small masses near the small curvature, with traces of the same in the omentum near the large curvature; but not elsewhere. The stomach was large; and the mucous surface, where not diseased, was uniformly red, but without any other change. In the preparation one-half of the pyloric portion is preserved; the other half being in the cabinet of the Soc. for Med. Improvement (No. 957). 1850.

Dr. D. H. Storer.

2210. Pyloric portion of the stomach scirrhus. 1847.

Dr. J. C. Warren.

2211. A second specimen. The whole circumference is involved
 • to the extent of an inch and a half; and the thickening of the muscular coat is well shown. 1847.

Dr. J. C. Warren.

2212. Cancerous disease of the whole pyloric portion, to the
 • extent of 3 in. It is firm, if not dense, to the feel; and

the disease of the mucous membrane, the ulceration, and especially the thickening, etc., of the muscular coat are finely shown. Lymphatic glands enlarged. The other organs were healthy.

From a woman, æt. fifty, who had been sick more than two years. Dyspepsia and occasional vomiting, with loss of flesh and strength. Vomited grumous matter six or eight weeks before death. Tumor in the epigastrium, towards the left side, with tenderness. 1862.

Dr. John C. Dalton, Sen.

In cancerous disease of the pyloric portion of the stomach, I have always found the tumor, when there was one, upon the median line, or upon the left side, but never upon the right, where we should expect to find it.

2213. Cancer of the pyloric portion. The entire circumference is not involved; but, in the midst of the disease, the parietes are perfectly healthy, and in the form of a narrow strip, connecting the stomach and duodenum.

From a lady, æt. sixty-one, who had been dyspeptic for years, but without severe pain until the last ten days, when it was of a darting character. Two weeks before death there was soreness at the epigastrium, with frequent vomiting of coffee-ground matter. 1862.

Dr. D. H. Storer.

The preservation of a portion of healthy tissue between the stomach and duodenum, and sometimes when the disease was extensive, has been observed here in other cases, and seems as if it may be a provision of nature to aid the stomach in the performance, however imperfect, of its functions.

2214. The whole organ preserved. It is very much contracted, much thickened, and seems to be scirrhus, if not quite universally; as in a figure of Cruveilhier's. (Anat. Path. liv. xxvii.) 1866.

Dr. J. B. S. Jackson.

2215. Extensive ulceration, from malignant disease, of the pyloric portion of the stomach, but without the microscopic appearances of cancer.

From a man, æt. forty-four, who had had gastric symptoms for about fourteen months. (Hospital, 229, 10.)

Distress after food, pain, occasional vomiting, hæmatemesis twice, constipation. Appetite pretty good on admission, two months before death, but much emaciated. 1860.

Dr. C. Ellis.

2216. Cancer of the small curvature, extending from the cardiac orifice to within 2 in. of the pylorus. There is an abrasion rather than ulceration; with two small ulcers, one of which penetrated through into a cavity that was external to the organ, and formed by an adhesion of the neighboring parts.

From a man, æt. thirty-two, who had vomited blood nearly two years before. Perforation probably two and a half months before death. (Hospital, 228, 98.) 1861.

Dr. C. Ellis.

2217. Cast of a well-marked, well-defined, and quite thick mass of soft encephaloid disease, extending about 4 in. from the pylorus, and involving the whole circumference of the organ. The pancreas was somewhat involved; but, otherwise, the organs were healthy.

The patient was a man, about fifty-three years of age, who had been under the care of Dr. H. E. Davidson, of Gloucester, and had been sick about two years. The first symptoms were pain in the epigastrium, coming on about two hours after eating, constipation, and occasional vomiting. Sept. 1st, 1863, he had a severe attack, and from that time his health steadily declined. Oct. 10th, 1864, Dr. D. was called to attend him, and found him much emaciated, anæmic, and sallow; had kept his house for some weeks; was using milk as causing less distress than any other food; rejection of all solids; much dizziness on standing; bowels very costive, — the discharges being attended with great distress, and sometimes followed by blood. To the left, and a little above the umbilicus, a tumor, of the size of a large hen's egg, was quite evident. The case was fully diagnosticated by Dr. D., as one of cancer of the pyloric portion of the organ, and the patient, gradually sinking, died on the 28th of the following March. 1866.

Museum Fund.

2218. Firm encephaloid disease of the pyloric portion of the

stomach; a narrow strip of healthy tissue extending partly across the diseased portion. 1861.

2219. Thibert's model. Disease of the pylorus, and apparently encephaloid. Numerous enlarged, mesenteric glands are similarly diseased; and great numbers of lymphatics between them and the small intestine are enlarged and filled with a puriform fluid. 1849. *Dr. J. Ware.*
2220. —. A very large encephaloid growth around the cardiac orifice of the stomach. 1849. *Dr. J. Ware.*
2221. Very extensive encephaloid disease of the cardiac orifice, and extending to the œsophagus. The diseased mass is thick, soft, and in a state of open ulceration. The œsophagus is somewhat dilated, but not particularly thickened; and the stomach is contracted, rugous, and mammillated. 1847. *Dr. J. C. Warren.*
2222. Encephaloid disease, extending $2\frac{1}{2}$ or 3 in. from the cardiac orifice, and quite limited. The diseased surface is ulcerated, firm to the feel, and was, in the recent state, of a yellowish color. The edges are raised, somewhat rounded and vascular, and softer than the rest. Œsophagus perfectly healthy, and neither dilated nor thickened. The other organs, also, were quite healthy.

From a woman, æt. fifty-three, who died in Feb. 1861, and had had dyspepsia from her girlhood. In August, 1859, there was much distress in the stomach and œsophagus; in the spring of 1860, nausea and vomiting, and in July the vomiting after food was constant. In December, when Dr. F. first saw her, there was a peculiar sense of distress on first taking food, and which was generally relieved by its rejection. The case was regarded as one of stricture of the œsophagus, from the fact that she persistently felt and said that the food stopped at an exact spot, about half way down the œsophagus. She was then taking liquids and pap nearly all the time, and vomiting nine-tenths of it within ten minutes. Instruments, however, were passed without resistance. During the last two months her appetite was keen, and she took large quantities of food, which she constantly rejected, and without discomfort. Five days before death she raised a pint of

dark, bloody, grumous mucus, but never at any other time. Until the last few days she kept about the house. (Med. Jour. Vol. LXIV. p. 432.) 1861.

Dr. George Faulkner, of Jamaica Plain.

2223. Cast, in plaster, of the stomach and œsophagus above described; colored. 1861. *Museum Fund.*

2224. Very extensive cancerous disease of the pyloric portion of the organ, and involving the whole circumference. A cast in plaster, and colored. 1868. *Museum Fund.*

2225. A portion of the stomach and œsophagus, showing encephaloid disease of the cardiac portion of the organ. 1847. *Dr. J. B. S. Jackson.*

2226. The entire stomach, showing a soft, and very dark encephaloid mass, projecting into the cavity of the organ. It arises from about the small curvature, and toward the anterior face is of an oval form, perfectly defined, and as large as the fist. Otherwise the organ is perfectly healthy; the disease being so limited to the inner coats, that the muscular is, to a considerable extent, quite healthy beneath it, and, upon the corresponding surface externally, no trace of the disease is to be seen. There was, however, some disease of the glands near the small curvature, and in the liver extensive encephaloid disease. (See the next specimen.)

From a man, æt. fifty-five, who died Nov. 28th, 1857, and apparently from exhaustion. In 1856 he began to have oppression at the stomach after food or drink, lasting for two or three hours, and sometimes amounting to severe pain; and this symptom continued throughout his disease. In Sept., 1857, there was a constant uneasiness at the epigastrium, with constitutional symptoms; but he continued to work, as a stove-maker, until the last of Oct. Nov. 10th Dr. A. first saw him; and food was then relished, though the appetite was small. The liver formed a large tumor, but at the end of a week was still larger.

The most striking fact in this case was the absence of vomiting, and even of nausea, throughout the whole course of the disease. 1858. *Dr. F. S. Ainsworth.*

2227. Colored cast of the stomach, above described. 1858.

Museum Fund.

2228. The entire stomach, showing an unusual form of encephaloid disease; and of which the following description was given, in the recent state.

The disease is not continuous, but in separate patches, circular or irregularly oval, about $\frac{1}{2}$ in. to rather more than 2 in. in diameter. Altogether there may be about a dozen of them; but those that seem to be the most recent are indicated by little else than an opacity of the mucous membrane, though their outline is sufficiently well defined, as is that of the patches generally. The larger patches, of which there are four or five, are raised from two to three lines above the surrounding surface, soft in appearance and to the feel, and of a dull yellowish opaque color, with some small dark-red ecchymoses over the surface of two or three. The whole surface of one of these last is deeply ulcerated, but without any induration about it; and there may be a trace of the same in one of the others. Otherwise the stomach is perfectly healthy; there being no disease within some distance of the orifices.

There was a tumor, however, externally to it, and closely connected with the stomach and duodenum, which was nearly as large as the fist, and in structure a marked soft encephaloid, with traces of effused blood.

From a lad, fifteen years of age, who had had intermittent fever in the West, but was regarded as perfectly well until the 7th of Sept., when he jumped from the back of a wagon, and fell with considerable force upon his "face" or front of his body; followed by an occasional and paroxysmal pain in the epigastrium, and which would be quite severe on exertion. About four weeks afterward he was running behind a buggy; and, as the horse was going very fast, when he let go his hold, he again fell upon his "face," and with great violence. It was with great difficulty that he walked home; and, on his arrival, threw himself upon a sofa, very much exhausted, and with great distress at the epigastrium. He, however, recovered so far as to go to school for two weeks; and, at the end of that time, to go to Boston, where he walked about most of the day, seeing

the sights of the city, and eating pie several times in the course of the day. On the following day he vomited after his dinner; and from that time was sick with what was regarded, by Dr. Dearborn, of Saugus, as typhoid fever; death occurring on the 16th of Nov. During this last sickness there was a disgust for food, and he vomited three times.

The youth of the subject, the short duration of the disease, presuming that it did not exceed ten weeks, its comparative latency, and, anatomically, its peculiar form, are very remarkable points in this case.

A comparative latency of the disease is not unfrequently noticed in cases of common encephaloid, as distinguished from "scirrhus of" the organ; this last affecting particularly the pyloric portion, and involving more or less the pylorus, whereas the encephaloid is often found in a large, single, defined circular patch in the small curvature, and not far from midway between the two orifices; the rest of the stomach being sometimes perfectly healthy, and the latency complete. (Med. Jour. Vol. LXXI. p. 409.) 1864.

Dr. J. M. Nye, of Lynn.

2229. A colored cast of the interior of the stomach above described. 1864. *Museum Fund.*

2230. Encephaloid disease of the pyloric portion of the organ.

From a man, æt. forty-five, who discharged blood from the bowels, and vomited the same, eight months before death; but did not vomit, otherwise, until the last three weeks. There was loss of flesh and strength, and a tumor was felt in the abdomen.

The disease involves the whole circumference of the organ, and to the extent of about 3 in. from the pylorus; excepting a small portion of this last. The edges are much elevated, rounded, opaque white, as compared with the rest of the organ; and, on section, $\frac{1}{2}$ in. to 1 in. thick, quite firm, and having a pearly, translucent look, with many, small, yellowish spots. The surface was extensively, though not deeply ulcerated; and where it was not, it resembled the edges. The disease seemed to begin in the submucous cell. tissue; but this and the mucous were

very soon merged, and the muscular, which seemed at first healthy, was quite lost about half an inch from the commencement of the disease. There was contraction at the pylorus before it was cut through; and the organ was otherwise healthy, as it very generally seems to be in cases of cancer, as observed here. 1867.

Dr. J. B. S. Jackson.

2231. Encephaloid disease of the stomach. The contraction is such that it measures only $6\frac{1}{2}$ in. along the large curvature, and $3\frac{1}{4}$ in. along the small. Not much if at all thicker or firmer, generally, than usual; and it was strongly adherent, and to a considerable extent, to the subjacent parts, in which there was a marked encephaloid deposit. Mucous membrane diseased, excepting the last inch toward pylorus; and in the cul-de-sac is an ulcer more than an inch in diameter, defined and deepest near cardia, which it approaches within about $\frac{1}{2}$ in., but ill-defined toward the body of the organ. No cancer in the other organs.

From a woman, æt. sixty-three, who had been sick about a year. The food was regurgitated as soon as it reached the stomach, and very frequently, but with scarcely any nausea or vomiting; and this was her chief symptom. Pain and distress at the epigastrium; appetite very strong; habitually very costive, and became very much so toward the last; loss of flesh and strength, with cancerous hue. Death at last seemed owing to a serous effusion into the pericardium. 1868.

Dr. Wm. Reed.

2232. Encephaloid disease of the last 4 or 5 in., and whole circumference of the pyloric portion of the stomach; limits sharply defined; surface irregular and deeply ulcerated, and communicating with a large abscess in and beneath the left rectus muscle.

From a man, æt. fifty, who had been subject for about a year to nausea and occasional vomiting; and with the general appearance of one who was suffering from great anæmia. Three months before death a slightly movable tumor appeared beneath the ribs, and upon the left side. (Med. Jour. Vol. LIX. p. 143.) 1858.

Dr. C. Ellis.

2233. Encephaloid disease of the pyloric portion of the stom-

ach. The diseased mass is well defined, of a circular form, about 4 in. in diameter, and rises about half an inch above the surrounding surface, in soft, regular masses, that project beyond the base; situated mainly in the posterior parietes, and within an inch of the pylorus. The organs of the abdomen were matted together as by former peritonitis; but there was no other cancerous disease.

From a bootmaker, æt. forty-eight years, who had long been subject to dyspepsia and constipation. Gave up his work in Feb.; kept his bed from July, and died in Dec. Dysphagia was an urgent symptom, though the disease was far away from the cardiac orifice. Vomiting one or two hours after taking food; never much pain; great emaciation. Tumor in the epigastrium during the last three weeks.

It may be questioned whether the pressure that he must have been in the habit of making, in the exercise of his trade, may have had anything to do with the development of his disease. (*Amer. Jour. of Med. Sc.*, April, 1852.) 1852. *Dr. Wm. C. B. Fifield, of Dorchester.*

2234. Cancer of the stomach, terminating in perforation.

From a man, sixty-eight years of age, who for eighteen months had been subject, a short time after eating, to pain in the epigastrium. Never any hemorrhage or vomiting. The difficulty was attributed to ordinary dyspepsia. The night before his death he was attacked with severe pain just below the epigastrium, and this continued until his death, which took place suddenly on the following morning.

On examination. about two pints of serous pus were found in the peritoneal cavity. Slight redness of the external surface of the upper part of the intestines. In the small curvature of the stomach was a deep excavation, occupying the greater part of a soft, whitish growth, between 2 and 3 in. in diameter, which extended nearly to the pylorus. The margin of this was elevated and undermined. In the centre of the diseased portion was a circular opening, about four lines in diameter, into the peritoneal cavity. There was the acute peritonitis, but no other disease. (*Med. Jour.* Vol. LXII. p. 324.) 1860.

2235. Epithelial cancer of the stomach. The pyloric extremity of the stomach is nearly surrounded by a soft, white growth, which extends inwards 2 or 3 in. from the valve. Its margin is undermined, and somewhat elevated above the surrounding surface, but the remainder of the growth appears to have lost a part of its substance; the base being sunken and irregular, and formed by the exposed disease, long shreds of which floated up, on placing the part in water. There was no disease elsewhere.

Dr. E. found that on microscopic examination, the disease was composed of cells and nuclei, more or less granular, but not larger than those of cylinder epithelium. They were round, more or less elongated, some being fusiform, or pointed at one end only. A few had a decided columnar arrangement.

From a gentleman, *æt.* fifty-nine, who died after eleven months' sickness, and whose previous health had been perfectly good. The disease began with "cholera-morbus," followed by loss of flesh and strength, some nausea and distress after eating, and occasional diarrhœa. As it advanced, the vomiting occurred at intervals of from ten to twenty days, not violent, nor preceded by nausea, but sudden, and followed by extreme exhaustion. No tumor ever felt. (*Med. Jour.* Vol. LXIV. p. 546.) 1861.

Dr. C. Ellis.

III. INTESTINES.

2236. Small intestine, torn entirely across, and mesentery to the extent of 3 in., as shown in the preparation.

From a man, *æt.* twenty years, who was jammed between two railroad cars, and died, in twenty-one and a half hours, in great agony. There was a prominent tumor in the left side of the abdomen, with some ecchymosis, and hematuria.

A large amount of blood was found in the peritoneal cavity, and there was free escape of air. Laceration of intestine 51 in. from pylorus; mucous membrane much everted, and peritoneum stripped off to some extent. Considerable effusion of blood in mesentery, and still more along psoas muscle. Superficial laceration of inner sur-

face of bladder, anteriorly and toward outlet; pelvis not examined for fracture. Kidneys and other organs uninjured. (Hospital, 39, 40.)

The appearance of external injury, in case of rupture of the organs of the abdomen by external violence, seems to be very exceptional; and, as the fact is so different from what would be expected, it deserves especial notice in reference to diagnosis. 1849. *Dr. J. B. S. Jackson.*

2237. A portion of the rectum, showing the mechanical injury that was done by the passage of a bougie.

From a gentleman, æt. sixty years, who died after a short sickness, with symptoms of obstruction, connected with an annular stricture, $15\frac{1}{2}$ in. from the anus. 1861.

Dr. J. B. S. Jackson.

The above is only one of several cases that I have examined, and in which the passage of some instrument into the rectum has been the immediate cause of death.

2238. Pelvic organs, apparently from an old woman. The lower portion of the rectum is greatly distended, as from fecal accumulation; but not thickened. 1847.

Dr. J. C. Warren.

2239. A portion of large intestine, showing the hypertrophy of the muscular coat that occurs in case of mechanical obstacle. 1850.

Dr. J. B. S. Jackson.

2240. A few inches of the lower portion of the large intestine, cut open, and showing the orifices of numerous little sacs, formed by a hernial protrusion of the mucous coat; the intestine being loaded with fat, as it usually, if not always, is in such cases. 1852.

This affection I have met with very frequently in the large intestine, but never in the small; excepting two cases (No. 2242; and No. 486, in the Med. Soc.'s Cabinet); but these two were otherwise exceptional. Others, however, have found it only in the small intestine; and a case has been figured by Sir A. Cooper, in his work on Hernia.

Dr. J. B. S. Jackson.

2241. A second and very remarkable specimen; the arch of the colon being the part affected. The sacs are much larger than they are generally seen, and so numerous in some

parts as to be crowded together. The fat, with which the whole intestine was perfectly loaded, having been removed by a laborious dissection, the intestine has been inflated and dried; the sacs being extremely thin. No. 1017, in the Med. Soc.'s Cabinet, was from the same individual, has been similarly prepared, and shows the sacs scattered along as far as the rectum.

From a gentleman, æt. sixty-five years, who had had cardiac symptoms, was very corpulent, and a great eater. 1852. *Dr. J. B. S. Jackson.*

2242-3. Sacculated dilatation of the intestine; cut open and preserved in spirit; and a second, inflated and dried, with a portion of the intestine.

From a farmer, æt. seventy-two years, who died, after a sickness of twelve hours, with "coffee-ground" vomiting.

Nine or ten hernial protrusions of the mucous membrane were found, as large, or larger than the intestine itself; and nearly all of them were in the upper part of the jejunum, though one or two were nearer the ileum. There were also several quite small sacs. Some of them were within 2 or 3 in., and others some feet apart. Some were on the attached portion, as in Sir A. Cooper's case, above referred to, and others upon the free portion of the intestine. 1856.

Dr. Jas. R. Wellman, of Fitchburg.

2243½. A portion of small intestine, from an infant that lived three days, and greatly dilated; inflated and dried. Thirty-seven inches below the duodenum the intestine was completely closed by a membranous diaphragm, and measured, at the largest part, 1¼ in. in diameter; the diameter below the obstruction being about two and a half lines. (See No. 945, with a figure, in the Catalogue of the Med. Soc.'s Cabinet.) 1869. *Dr. J. B. S. Jackson.*

2244. A portion of intestine that protruded from the anus, after much straining, on the sixteenth day of dysentery, and was cut off with a pair of scissors; a few drops of blood only following the incision.

The patient, æt. six months, had prolapsus daily for the first six days, and occasionally afterward, but in the course of three months was quite well.

The specimen is about 4 in. in length; and was found by Dr. J. Wyman to consist of mucous membrane, vessels, and areolar tissue. He also found what he supposed to be circular muscular fibres under the microscope; and in the preparation he has passed bristles into an artery, and a vein. It was stated that, two or three days after the removal of this portion, a second was expelled by the natural efforts, about an inch in length. 1855.

A similar case, with recovery, is recorded in the Proc. of the Pathological Soc. of London, Vol. III. p. 370; all the tissues of the intestine being included.

2245. Intussusception, from a case of typhoid fever (Hospital, 251, 198); cut open to show the inverted portion. There were four or five others in the jejunum; of the simple form, and, as usual, from above downward. 1863.

Dr. J. B. S. Jackson.

2246. Cast, in plaster, of two of the above intussusceptions, with the intervening intestine. Colored by Mr. C. J. Blake. In the case of one of them the outer portion of intestine had begun again to be inverted upon itself about midway. 1863.

Museum Fund.

2247. Intussusception, at the junction of the small and large intestine. The first has passed onward, and the cæcum retains its place; the appendix projecting from the neck of the invagination. 1847.

Dr. J. C. Warren.

The fatal, as distinguished from the simple form of intussusception, is found, according to some authors, sometimes in the small intestine, sometimes in the large, and sometimes at the junction of the two. In every case, however, that I have examined, excepting one, and in which it was confined to the rectum (No. 509, in the Med. Soc.'s Cabinet), I have found it at the junction of the small and large intestine; and, further, the inverted cæcum has invariably been found at the extremity of the invaginated portion, excepting one case (No. 492, in the Med. Soc.'s Cabinet).

2248. Intussusception, from a child five months old. Taken sick on Sunday evening, but no alarm felt until Tuesday, at 4 A. M., when it passed clotted blood from the bow-

els, and moaned with pain. From 2 until 8 P. M., on that day, there was no further discharge; but from that time until Wednesday, at 5 A. M., when it died, there were frequent and small discharges of fresh blood and mucus.

The invaginated portion is 8 in. in length; and, upon the middle portion of the intestine, there was a thinly scattered deposit of lymph, with some mucus, but no blood. The orifice of the appendix cæci is indicated in the preparation, by a glass rod. 1866.

Dr. A. H. Johnson, of Salem.

2249. Intussusception, from a child, æt. three years. April 2d it had a short attack of colic; and on the 3d the same, with vomiting. On the 14th the pain at the navel became fixed; but until the 18th it ate and played as usual. All the symptoms then increased; and on the 19th there was constant vomiting. The abdomen was not distended; but a tumor was felt in the iliac fossa. Nothing felt within the rectum. On the 21st, at 3 A. M., the child had a natural dej.; and in the afternoon some bloody serum was passed. On the 22d an enema was given, and rejected with a good deal of force; and the intestine was then seen as well as felt, at the anus. On the 23d it was carried to the hospital (133, 225), where it died about eight hours after admission.

The large intestine was completely doubled upon itself; so that, in the preparation, the orifice of the appendix cæci is seen at the very extremity of the protruding mass, and just above it the opening from the ileum, — the opening of the appendix being marked in the preparation by whalebone, and that of the ileum by a glass rod. (*Med. Jour.*, Aug. 6th, 1868.) 1868.

Dr. R. M. Hodges.

2250. Strangulation of the intestine, by the appendix cæci.

From a woman, æt. forty years, and a patient of Dr. H. M. Lincoln, of Westminster. Two months before her death she was thrown from a vehicle, and injured so as to be confined to her bed for four or five weeks. About six weeks after the accident, and when still quite feeble, she rode two or three miles over a rough road, and in a wagon of which the body rested directly upon the axletree. After this she took to her bed, and never again left it.

Her symptoms were those of peritonitis, with some colicky pain, but no more vomiting than would have been caused by the active cathartics she took; the effect of these last being very partial.

The appendix cæci adheres strongly to the mesentery by a fibrous band that arises from its extremity, and that is not larger than a knitting-needle. The very lower extremity of the ileum, to the extent of 4 or 5 in., is the portion strangulated; but the strangulation was by no means tight, even in the recent state. The intestine was, as usual, much distended above, and contracted below the strangulation. Peritonitis considerable in amount; and it was a very unusual complication, so far as has been observed here. (Amer. Jour. of Med. Sc., July, 1853.) 1854.

Mr. J. L. White, med. student.

2251. A portion of small intestine, showing an unusual development of the solitary glands, and also of Peyer's patches.

From a child, five years old, who, having previously been well, came home sick, and vomited a large quantity of grapes. Vomiting and purging continued until the next morning, when it was found collapsed; and in a few hours it died. The glands were enlarged throughout the small intestine. 1859.

Dr. C. Ellis.

2252. A portion of the large intestine of a sheep. Great numbers of the mucous follicles in this, and some in the small intestine, are enlarged to a diameter of $\frac{1}{4}$ in. or more; and, on section, were found distended by a thick, curdy substance. Some have an opening at the summit, through which the contents are seen; but over the rest the mucous membrane is continuous. 1867.

Dr. H. O. Marcy, of Cambridgeport.

2253. Follicular enteritis.

The patient was a little girl, three years old, who was taken with vomiting after eating heartily of pigs' feet for her breakfast, on the morning of Dec. 10th; the vomiting continuing until she died, on the 15th, at 3 A. M. Toward the last it was very urgent, and partially digested blood was thrown up. On the first day she took a cathar-

tic without effect; but after enemata she had dark and slimy discharges, and afterwards several that were greenish. And these were all the discharges that she had during her sickness, though cathartics and enemata were given. Pain in the abdomen, and of a colicky character, was a nearly constant symptom throughout, with tenderness. There was some pain in the epigastrium, and some tenderness over the abdomen, but otherwise this last was natural. On the evening of the 14th she was in a state of collapse, constantly restless, and crying out, with her hand on the epigastrium; the abdomen not tympanitic, but full and hard about the cæcum; laudanum was ordered p. r. n., and two enemata were given, containing ol. terebinth, but without effect.

The disease was almost continuous throughout the upper half of the large intestine, so that its follicular character would not have been suspected; the surface being rough, of an opaque whitish color, and abraded, with very considerable thickening. Healthy patches of mucous membrane, however, soon began to appear, and these gradually increased until the disease had for the most part disappeared; but as low down as the rectum, the surface was everywhere more or less scattered with follicles, about the size of mustard seed, singly or in small groups, and evidently the commencement of the more advanced disease. In the lower part of the small intestine, also, were numerous isolated follicles, similar to the above, and, like them, not ulcerated nor abraded upon the surface. Peyer's patches in the lower part of the intestine were much raised, rough upon the surface, and opaque as if thinly coated, and even infiltrated with lymph. Blood and some bile were found in the stomach and upper part of the small intestine; and the intestines otherwise were healthy. 1869.

Dr. Samuel G. Webber.

2254. Thibert's model. A portion of small intestine, showing hemorrhage into the mucous membrane, in scattered patches. 1849.

Dr. J. Ware.

2255. Inflammation of the intestine, from a woman, æt. thirty-five years, who died of gangrene of the lung, and had had

some diarrhœa for a short time before death, but no pain. (Hospital, 208, 242.)

There was an effusion of lymph upon the mucous membrane, throughout the large intestine, and the last two feet of the ileum, and increasing from above downward. At first it was in patches; then in transverse lines, giving a rugous appearance to the inner surface, and between them this surface was quite healthy. 1857. *Dr. C. Ellis.*

2256. A portion of lymph in a tubular form, and removed after death from the intestines. In the preparation a portion of intestine has been drawn through it, and then distended with spirit.

From a man, æt. thirty-four years, who died under the care of Dr. Folts, of E. Boston, and after a few days' sickness, of meningitis. His bowels having previously been costive, he had a thin, black, fetid dej., followed by several others of the same character; and in the first two were two or three portions of lymph, that altogether measured about a foot in length. These last were opaque, of a dirty white color, stained by the fæces, about a line in thickness, and, microscopically, appeared to consist of a granular and fibroid substance, with epithelium.

The mucous membrane of the last two or three feet of the ileum was much inflamed, in strongly marked transverse folds, and covered by a slight deposit of lymph. The large intestine was also highly inflamed, with thin patches of lymph upon the surface, from 1 to 2 in. in diameter. 1853. *Dr. C. Ellis.*

2257. A portion of large intestine, from a case of acute dysentery. The surface is covered with lymph. 1861.

Dr. J. B. S. Jackson.

2258. A portion of small intestine, showing finely the appearances usually seen in typhoid fever. 1861.

Dr. C. Ellis.

Five Thibert's models. Cases of fever. 1849.

Dr. J. Ware.

2259. Small intestine near the cæcal valve. Peyer's patches swollen and inflamed, not ulcerated.

2260. Ulcers defined; and more numerous toward valve.

2261. Extensive ulceration, with thickening of Peyer's patches near the valve; and considerable swelling of the mucous membrane.

2262. Ulcers of Peyer's patches, cicatrized.

2263. Mucous membrane of the large intestine, near the cæcal valve, studded with very large, inflamed follicles, that look like pustules, ulcerated at the summit, and surrounded by a circle of inflammation. Just above the cæcal valve the intestine is inflamed and ulcerated.

2264. Deep and extensive ulceration of the lower portion of the ileum, with much discoloration. Some ulceration of large intestine, and mesenteric glands much enlarged. Thibert's model. 1847. *Dr. J. C. Warren.*

2265. A portion of the ileum, showing ulceration of Peyer's patches just above the valve, and a small slough hanging from one of them. Blood was found in the intestine, below the slough, but none above.

From a man, æt. thirty years, who died of fever, of two and a half weeks' duration. At 6½ A.M. there were symptoms of internal hemorrhage; and he died before eight o'clock; having had a profuse discharge of blood not long before. (Hospital, 212, 243; and Med. Jour. Vol. LVII. p. 160.) 1858. *Dr. C. Ellis.*

2266. Lower portion of the ileum, in which the Peyer's patches and solitary glands are very prominent, but not ulcerated. Redness, in the recent state, near the cæcum. (For the mesenteric glands see No. 1840.)

From a young man, æt. nineteen, who died of fever of four and a half weeks' duration, and who had two or three dej. daily. During the first three weeks he continued at his work. (Hospital, 227, 14.) 1860. *Dr. C. Ellis.*

2267. Ulceration of Peyer's patches; with a perforation not larger than a pin-hole, 3 in. above the valve.

From a man, æt. twenty-six years, who died of fever at the end of five weeks. On the morning of the 14th he was attacked with severe pain in the abdomen, and on the 16th, at 11 P.M., he died. Acute peritonitis was found, with ʒxij. of pus in the cavity. (Hospital, 204, 71.) 1856.

Dr. C. Ellis.

2268. A portion of intestine, showing a perforation about an inch in diameter, and about 2 in. above the cæcal valve; the whole base of an ulcer seeming to have sloughed through. There were only one or two very small ulcers near it, and none of the other patches were distinct. The peritoneum was generally reddened, and there was lymph to the extent of an inch around the large ulcer.

From a healthy young man, who had had well-marked symptoms of typhoid fever for about two weeks. Perforation occurred forty-eight hours before death, but the pain and other symptoms were by no means urgent. (*Med. Jour.* Vol. LIX. p. 522.) 1859. *Dr. C. G. Putnam.*

Five Thibert's models. 1849. *Dr. J. Ware.*

2269. A very large perforation of the ileum, from ulceration of Peyer's patches; the others having healed.

2270. Small intestine, seen externally; and showing peritonitis, the result of perforation.

2271. Inflammation of the small intestine.

2272. Numerous ulcerations of the small intestine, giving the appearance of lace-work; with considerable swelling of the tissues.

2273. Long and narrow ulcerations, transverse to the course of the small intestine, with swelling of the mucous membrane, thickening of the parietes, etc.; the result of chronic inflammation. Mesenteric glands swollen, red, etc.

2274. The appendix cæci, from a case of typhlo-enteritis.

The patient was a lady, æt. thirty-seven years, who, having been indisposed for a few days, was attacked suddenly and violently with pain in the abdomen, and died on the ninth day. There was more or less pain throughout; some vomiting; no free dej.; pulse nearly imperceptible from the first.

On dissection, there was found extensive peritonitis. The first half inch of the appendix was quite healthy; but the rest was inflamed upon the inner surface, and tending to gangrene. In the cavity were very numerous masses of fæcal matter; and one much larger than the rest, protruded from an opening through the parietes of the appendix, and

near its origin; the opening being two and one-half lines in diameter, and the edges quite sloughy. 1849.

Dr. C. G. Putnam.

2275. A second specimen. From a gentleman, about thirty-five years of age, who sank gradually, and died in eleven days; a patient of Dr. Bowditch. Great pain and tenderness, with fulness over affected part. Vomited freely eight or nine times the day before death. Bowels generally loose, or kept so. A large cavity was found in the cellular tissue, behind the ascending colon, and containing a blackish and very offensive fluid; a very similar fluid being found in the colon.

The preparation shows a small portion of the ileum and large intestine; the inner surface of the cavity; the appendix cæci cut off abruptly 2 in. from its origin, and opening directly into the cavity; but otherwise healthy; and direct openings into the cavity from the cæcum. The neighboring muscles were to some extent dark green, and contained thick pus. The pleura was also inflamed at the base of each lung. In the cavity was a calculus, that probably escaped from the appendix, and was the source of the whole trouble. 1858.

Dr. C. Ellis.

2276. A third specimen, from a patient of Dr. D. H. Storer; a man who had had great pain in the back and right hip, extending down the thigh; with tenderness in the groin, and afterward fulness there as from suppuration; the fulness subsequently disappearing. The whole duration of the disease was short.

An extensive abscess was found in and about the right iliac region, and it communicated freely with the cæcum and the appendix cæci; the opening into the cæcum being evidently from without inward, and explaining the subsidence of the fulness observed during life. No foreign body was found; but there may have been one that escaped into the cæcum. Some of the bones were denuded. (*Med. Jour.* Vol. LXV. p. 61.) 1861.

Dr. C. Ellis.

2277. A fourth specimen. The appendix cæci is sloughy, and perforated at its extremity.

From a college student, æt. twenty-one, who had been ill

for two weeks. During the first half of his sickness he was confined to his room for three or four days, but without any marked symptoms. Then there came on a severe rigor, followed by colic pain, and relieved by a discharge from the bowels. The case was particularly characterized by a recurrence of such paroxysms once or twice every twenty-four hours; the chill lasting about twenty minutes, and being followed by heat, and an active pulse; the pain lasting for three or four hours; and each attack being relieved by a copious dej. During the intervals he kept his bed, but was quite comfortable, and with a pulse of 65. On the day before his death he was particularly comfortable, and asked for steak; but, at 4 P.M. a very severe rigor came on, followed by prostration, and he died the next day, at 10 A.M.

On examination, a general peritonitis was found, especially in the right iliac fossa; and in the appendix three or four masses of old fæcal matter, with some mixture of the triple phosphate.

The case, which occurred in the practice of Dr. Ezra Palmer, was further remarkable for the absence of nausea, vomiting, and constipation. (See No. 2331.) 1867.

Dr. J. Homans.

Three Thibert's models. 1849.

Dr. J. Ware.

2278. Gangrene, with ulceration of the colon and rectum.
2279. Gangrene of the rectum, from a child three months old.
2280. Chronic inflammation, with gangrene, of the small intestine. Parietes thickened and indurated; with several defined and deep ulcerations. Mesenteric glands swollen, red and indurated.
2281. Chronic ulcer of the duodenum, $\frac{1}{2}$ in. by $\frac{1}{3}$ in. in extent, and $\frac{1}{2}$ in. from the pylorus. Perforation through the base, quite circular and defined, and two lines in diameter. The surrounding mucous surface is quite healthy.

From a healthy-looking negro, twenty-five years of age, but formerly supposed to have had disease of the liver. Just after carrying a hod of coal upstairs, violent pain in

- the abdomen came on, and in twenty-two hours he died with acute peritonitis. 1849. *Dr. Wm. E. Coale.*
2282. Two ulcers in the duodenum, adjoining the pylorus. One is circular, quite deep, and $\frac{1}{2}$ in. or more in diameter. The other is smaller, less regular, and has perforated the peritoneal cavity. 1857. *Dr. A. A. Gould.*
2283. Two chronic ulcers in the duodenum, not far from the pylorus. One is about two-thirds of an inch in length; the base is formed by the pancreas, and at one point it approaches very near to the peritoneum. The other is less deep, and smaller.
 From a child, five years of age, that had acute pleurisy; and at the end of a week died with symptoms of internal hemorrhage, after three hours' continuance. — A large amount of blood was found in the stomach, and throughout the intestines; and on moving the body after death, blood escaped from the mouth and anus. (*Med. Jour. Vol. LVII. p. 450.*) 1858. *Dr. F. H. Gray.*
- Ulcer in a large serpent, just below the pylorus; about one-third of an inch in extent, and with a parasite hanging from it. (See No. 285.)
2284. Thibert's model. Very extensive ulceration of the mucous membrane of the small intestine; engorgement, but without induration, etc. 1849. *Dr. J. Ware.*
2285. Ulceration of the small intestine. The ulcers extended throughout this intestine; and were shown, microscopically, not to be formed directly in the old tissues, but in a new material that was first formed in them; this last being "composed of fibroid tissue, some fibro-plastic elements, and many small nuclei with small nucleoli." Perforation took place six or seven feet from the pylorus. From the same case as No. 2197. (*Med. Jour. Vol. LXXI. p. 241.*) 1864. *Dr. C. Ellis.*
2286. Ulceration of the small intestine, from the same patient as No. 2185. The ulcers were scattered throughout the whole of the small and large intestine, and resembled those in the stomach; largest and deepest in the jejunum, where some of them were perhaps two-thirds of an inch in diameter; dark gray and cicatrizing in the large intestine. The

other organs were healthy. (Med. Jour. Vol. LXIV. p. 549.)
1861. *Dr. C. Ellis.*

2287. Thibert's model. Numerous, large, and chronic ulcerations of the colon; chiefly between the folds of the mucous membrane. Parietes thickened and indurated. 1849.
Dr. J. Ware.

2288. Ulceration of the large intestine. About midway the mucous membrane was almost entirely destroyed to the extent of 6 in.; and throughout the whole of this intestine there was more or less ulceration; the base of the largest, and many of the smaller, ulcers being covered with large, grayish granulations.

From a very corpulent woman, æt. sixty-eight years, who had had diarrhœa for six weeks and a half, but yielding readily to treatment, so that on two or three occasions her physician, Dr. Salter, discontinued his attendance; character of the disease dysenteric at first, with constitutional symptoms. Death at last rather sudden.

There was some valvular disease of the heart, diseased liver, gall-stones, and fibrous tumors of the womb; there having been some corresponding symptoms, though her general health had been good. (Med. Jour. Vol. LIV. p. 57.) 1856.
Dr. C. Ellis.

2289. Thibert's model. Chronic ulceration of the rectum. 1849.
Dr. J. Ware.

2290. The lower part of the rectum, most extensively ulcerated;
• and, apparently, rather an acute affection. Superiorly very defined, and burrowing; the muscular coat below this looking as if clearly dissected. For the last inch and a half it is not so much an ulceration as an irregular abscess, burrowing between the rectum and the vagina. Above the seat of disease the mucous membrane was quite healthy, excepting a fistulous opening into a portion of the large intestine, that adhered to the rectum, as seen in the preparation. 1861.
Dr. J. B. S. Jackson.

2291. Continuous ulceration of the rectum; with chronic abscesses between this and the sacrum, and opening freely into the intestine. The ulceration began in the arch of the

colon, and increased downward. The other organs were healthy.

From a woman, æt. forty-four years, who had had dysentery for six months, with pain and tenesmus. (Hospital, 198, 203.) 1855. *Dr. J. B. S. Jackson.*

2292. Abscess between the rectum and bladder, and opening into each.

From a gentleman, æt. sixty years, who had had urinary symptoms for two years, with intensely acute symptoms the last two weeks; half a pint of pus having been discharged from the rectum the day before death. 1861.

Dr. J. B. S. Jackson.

2293. Sinuses about the rectum; opening externally, and extending upward nearly 5 in. 1847.

Dr. J. C. Warren.

2294. Cast, in plaster, of two portions of small intestine, and showing well-marked tubercular ulceration. Colored by Mr. C. J. Blake.

From a man, æt. twenty-four years, who died of phthisis. (Hospital, 213, 118.) 1858. *Museum Fund.*

2295. A second cast, colored by Mr. Blake, and showing two long and narrow ulcers, running transversely, and entirely across the small intestine. There were numerous others of the same character; and they were all more or less tubercular.

From a man, who died of phthisis, and without diarrhœa. (Hospital, 239, 172.) 1861. *Museum Fund.*

2296. A portion of intestine, inverted; with a diverticulum. This last is $2\frac{1}{2}$ in. in length, was situated five feet and a half from the cæcal valve, and shows upon its inner surface three large tubercular ulcers. — From a case of phthisis. (Hospital, 217, 242.) 1859. *Dr. C. Ellis.*

2297. Thibert's model. A portion of the colon, showing ulcers of various size; from a case of phthisis and chronic diarrhœa. 1849. *Dr. J. Ware.*

2298. Perforation of a large ulcer, in the ileum, and 7 in. from the cæcal valve. There were other large ulcers below, but none above this; of a bluish color, and without any tubercular appearance.

From a man whose lungs were extensively tubercular.

This case, which was observed in the dissecting-room, may possibly have been one of typhoid fever, supervening on phthisis. 1855. *Dr. R. M. Hodges.*

2299. Polypi of the large intestine. There were two in the cæcum, and four or five others in the ascending colon. All had pedicles; and the largest was of the size of an English walnut.

From a woman, about sixty years of age, who died of pneumonia. (Med. Jour. Vol. LXIV. p. 211.) 1861.

Dr. D. W. Cheever.

2300. A second specimen. From a hospital patient, who died of cardiac disease very soon after entrance.

“Attached to the posterior wall of the rectum, at a point 7 in. from the anus, by a pedicle upward of half an inch in diameter, was a soft, highly vascular, lobulated and villous, cauliflower-like excrescence, about 2 in. in diameter, rising from half an inch to an inch above the surrounding surface. It apparently involved the mucous coat alone.

“Microscopically, it was composed of much elongated, granular, nucleated cells, some of which resembled long columnar epithelium, and were arranged, like the last, in close juxtaposition. Others, though elongated in the same manner, had more irregular outlines, and resembled cells found in a variety of morbid growths.” 1857.

Dr. C. Ellis.

2301. A portion of the large intestine; distended and dried, and showing a stricture 15 in. from the lower extremity.

It was strictly annular, and looked almost as if girt by a string; firm, but not of scirrhus density, and not adherent externally. The large intestine above the stricture was, throughout, greatly distended, and contained an immense quantity of soft fæces; the small intestine was also very much distended by thin fæces and gas. Below the stricture, the intestine was of about the usual size. The parts having been removed and washed out, a portion of the intestine above the stricture was filled with water, but not a drop passed through; it was then inflated, under water, but it was not until several trials had been made, and with

considerable force, that a little air could be made to pass through; nor was this last result obtained subsequently. The intestine having been inverted, there was found, at or just above the stricture, a well-defined, somewhat deep ulcer, not more than one-fourth of an inch in width, and not at all remarkable in its character, but involving the entire circumference of the intestine. Otherwise the dilated intestine was quite healthy, though the muscular coat was much hypertrophied. The other organs were also healthy, excepting the uterus, which contained two fibrous tumors, that were felt during life through the vagina.

From a woman, *æt.* thirty-four years, previously healthy, and who died on the 22d of November. In April she had an attack of obstinate constipation, pain in the abdomen, and vomiting; relieved by cathartics. In June a similar attack. During the last week of July a still more severe attack, and from that time she was never relieved. Hardened scybalæ were occasionally brought away by active cathartics and enemata; but for some weeks before death these last only were used, and for the last seventeen days nothing whatever passed the bowels. The abdomen was very greatly distended, and generally very tense; portions of the intestine sometimes feeling like solid tumors, and in a few moments relaxing under the hand, as the muscular spasm yielded. Vomiting was an urgent symptom. 1857.

Dr. J. B. S. Jackson.

The above case was published in the *Med. Jour.* (Vol. LV. p. 448), with a brief analysis of five other and similar cases that I have met with.

2302. A portion of the ileum, about 3 feet above the valve, very greatly contracted, and to the extent of about 2 in. Inner surface for the most part superficially ulcerated; but without thickening of the parietes, or any appearance of malignant disease. The intestine above was much dilated, and somewhat ulcerated; but otherwise healthy, as it was below the seat of disease. Three or four feet higher up, also, the intestine was contracted; and again in the duodenum, 2 in. below the pylorus.

From a patient of Dr. Stone, Jr., of Walpole; *æt.* fifty-

seven years, and had had diarrhœa, with constant pain in the abdomen for two years. 1861. *Dr. C. Ellis.*

2303. A portion of small intestine, thickened by encephaloid infiltration. Many portions of this intestine were similarly affected; and particularly the duodenum at its origin. Also the cæcum.

From a woman, æt. twenty-three years, who had occasionally had difficulty of digestion for some years; and constantly the last six or seven months. Pain, with sense of fulness in epigastrium, constant. No vomiting until quite late in the disease. (*Med. Jour. Vol. LXVI. p. 233.*) 1862. *Dr. C. Ellis.*

2304. Disorganization of the cæcum, commencing at the valve, and affecting the whole circumference, to the extent of 2 in. It had a foul and very malignant look, though there were none of the usual appearances of cancer.

From a lady, about fifty years of age, and who had been sick about eight months. A silver-coated, and unmistakably assafœtida pill that had been taken about six weeks before, was found at the seat of the disease. 1850.

Dr. J. B. S. Jackson.

2305. A portion of the arch of the colon, and of the sigmoid flexure, firmly adherent by encephaloid disease, and communicating freely with each other. There was, also, the same disease in the liver.

From a gentleman, æt. sixty-seven years, who was attacked about a year before his death with pain in the abdomen, followed by vomiting and emaciation; and a tumor in the left iliac region. He improved afterward so as to attend to his duties in the Legislature; but died at last exhausted by his disease. (*Med. Jour. Vol. LXV. p. 271.*) 1861. *Dr. C. Ellis.*

2306. Cancer of the large intestine. At the junction of the sigmoid flexure and the rectum the canal was closely constricted by a circular growth, which involves from 1 to 2 in. of the wall, the thickness of which is increased to a quarter of an inch. The mucous surface is red, but apparently smooth. The submucous cellular coat was thickened, firm, and of a whitish color. Muscular coat thickened and striated for

the most part, but in the centre the coats are all blended in the morbid tissue. On microscopic examination of intestine, there were seen some large but indistinct nuclei, like those belonging to malignant formations; but the fatty degeneration was so extensive as to make it impossible to pronounce with accuracy upon the exact character of the elements. — The liver weighed nearly nine pounds, and contained very numerous cancerous masses.

From a woman, who had been for a long time constipated, oppressed after her food for about a year, with more or less nausea, pain, and fulness in the abdomen. About ten days before death she took an active cathartic, but she had no discharge from the bowels from that time. There was vomiting, with much pain and oppression, and she gradually sank. Her mother died of cancer of the womb, and her grandmother of the same disease in the breast. (Med. Jour. Vol. LXIII. p. 343.) 1860.

Dr. C. Ellis.

2307. Colloid disease of the whole rectum; with an opening at the upper part into the bladder, which last was greatly contracted and coated with a phosphatic deposit.

From a gentleman, seventy years of age, who had been perfectly healthy until within a few years of his death. His principal trouble was an almost constant desire to evacuate the bowels, with discharges of a highly fœtid substance. Gradually sank under his disease, but never had a moment of what could be called pain. For the last week or two there was a discharge from the rectum through the urethra. (Med. Jour. Vol. LIX. p. 283.) 1858.

Dr. J. M. Warren.

2308. A second specimen. — Just above the anus is a very narrow strip of healthy intestine, though at the orifice is a considerable mass of the disease, that seemed to be seated in the hemorrhoids, that occasionally protruded during life. The principal disease is nearly 3 in. in extent, and involves nearly the whole circumference of the intestine; perfectly well marked, and not complicated with any other form of disease.

From a woman, about fifty years of age, and who had

been suffering from the disease for three years ; her chief symptoms being an intense, paroxysmal, and increasing pain, passing up through the rectum, and as high as the top of the sacrum. Very little hemorrhage ; and no vesical nor uterine symptoms. (Med. Jour. Vol. XLVI. p. 86.) 1862. *Mr. Albert Wood, med. student.*

2309. Scirrhus of the rectum, from a lad about seventeen years of age. The disease was of eleven months' duration, and came on with pain in the umbilical region, followed by vomiting, indigestion, and constipation. Eight months afterward, and when first seen by Dr. H., there was emaciation, with much pain, and especially on defecation. The pain, however, was never referred to the rectum, but always to the region of the transverse colon. On examination, the intestine felt very irregular, and as hard as a scirrhus breast. A month before the lad's death, the obstruction gave way, and he had free dejections, but the pain continued.

On dissection, the disease was found to commence an inch or less from the anus, and to extend upward about 3 in. ; involving the whole circumference of the intestine, and being deeply ulcerated almost throughout. The intestine was very closely adherent to the walls of the pelvis. The bladder was involved ; the ureters nearly obliterated, and higher up greatly distended ; and there were very slight traces of disease upon the peritoneum.

The age of the subject in the above case was very remarkable. 1861.

Dr. Anson Hooker, of E. Cambridge.

2310. Cast, in plaster, of a cancerous rectum ; colored.

From a farmer, sixty-eight years of age, and of robust health. He had been treated for piles for about a year, when, about ten months before death, he came under Dr. T.'s care. The sensation in the rectum he described as of weight, fulness, or distention ; and there was frequently a slight discharge of mucus or blood, but without much actual pain until about a month before death, when both the pain and the discharges were considerably increased, with an almost total loss of control of the sphincter. The discharges had been constantly offensive, and toward the

last were more so. Tenesmus was frequent, but never very distressing. Throughout the disease, the bowels acted pretty regularly, but always with pain; this last being severe during the last week, but it was apparently rather from tympanitic distention than from the disease itself, and was readily relieved by small doses of opium and conium. The appetite, which was always sufficient, was sometimes craving, and his food seemed to be well digested. He gave up work about a year before his death, but frequently rode short distances without pain or inconvenience, though walking caused an aching pain so long as he was under Dr. T.'s care; during the last three months he kept his bed. The pallid, straw-colored complexion of cancer was well marked; but the emaciation was less marked than would have been expected.

The disease commenced about 2 in. from the verge of the anus, and extended upwards 4 in. The whole circumference of the intestine was involved, the limits of the disease were perfectly defined, and the general appearance showed unequivocally its malignant character, though there was nowhere any encephaloid, scirrhus or colloid deposit to be seen. No trace of the original tissue of the intestine could be distinguished upon the cut surface, but the whole had a soft, opaque, thickened, and perfectly disorganized look; the structure was loose or coarse, and infiltrated with fluid, with many quite small, superficial sloughs upon the surface. In one place the diseased structure was destroyed to the extent nearly of an inch, and at the bottom of the cavity was a large slough. The intestine immediately above the seat of the disease was healthy, excepting a number of quite small and superficial ulcerations; there being very little if any thickening or dilatation. Dr. T. found the diseased portion of the intestine so adherent to the sacrum that it was removed with some difficulty. The other organs he found healthy.

Microscopically, it was regarded by Dr. Ellis as a malignant disease, though it did not show the usual elements of cancer, — as the gross appearances did not to the naked eye. (Med. Jour. Vol. LXXIV. p. 503.) 1866.

Dr. George G. Tucker, of Westfield.

IV. FOREIGN BODIES, ETC.

2311. Stones passed from the bowels at one discharge, by a half-witted boy, twelve years of age, who had been complaining somewhat for a few days. They are ninety-three in number, weigh $9\frac{1}{2}$ oz., and are such as may have been picked up in the street; some of them being as large as the last joint of the finger. 1863.

Dr. J. W. Graves, of Chelsea.

2312. False teeth, swallowed by a woman, and passed from the bowels in five days; with very little suffering from the accident. Three incisors upon a silver plate; there having originally been four. 1863.

Dr. Geo. Fabyan.

2313. A brass padlock, swallowed by a child two and a half years old, and passed from the bowels in about sixty-two hours, with very little trouble to the patient. It is, however, a padlock of the smallest size; measuring, with the hasp shut down, $1\frac{1}{8}$ in. in length, and $\frac{3}{4}$ in. in width. 1863.

Dr. Wm. G. Wheeler, of Chelsea.

I have been told by a gentleman of this city that when a boy he swallowed a small padlock, but never knew that it passed from his bowels; nor did he suffer from the accident.

2314. A hair-ball from the stomach of an ox; form rounded; greatest diameter $2\frac{1}{2}$ in.; color, black; surface glazed. 1854.

Dr. Samuel Kneeland, Jr.

2315. A second specimen; quite round, and $5\frac{3}{4}$ in. in diameter. Sawed through to show its structure.

Dr. H. brought the specimen from Texas, and stated that the animal from which it was taken was in every respect perfectly healthy. He further stated that these formations are not at all rare in T.; and that, having been sawed through, they are, sometimes, as he was informed, used to scrub the floors of the houses. 1857.

Dr. J. F. Head, Surgeon U. S. A.

2316. Two hair-balls, from the second cavity of the stomach of a calf, six weeks old. Mr. M. states that an intelligent man, who took them out, was quite sure that they were in that particular cavity. The animal was quite healthy.

One of the balls is of a compressed, spherical form, $2\frac{3}{4}$ in. in diameter, and $1\frac{3}{4}$ in. thick. The other is $1\frac{3}{4}$ in. long, and of rather an oval form. The structure, upon the surface at least, is loose, and not glazed as it usually is in older animals. 1868.

Mr. S. L. Moore, med. student.

2317. Hair-ball, from the stomach of a hog. A portion of it seems to have been sliced off; but, otherwise, it would be of a regular form, 5 in. in length, and $3\frac{1}{2}$ in. in diameter. The mass consists of bristles, with very little else; and it is very compact. Internally they are irregularly matted together; but externally they are very regularly arranged, — being parted to the right and left, as the hair often is upon the back of the head.

Mr. L. was told that the animal was one of a drove of ten, that ate well, but continued lean; and, on being slaughtered, a hair-ball was found in the stomach of each; the specimen here shown being the largest of them. 1857.

Mr. Thos. W. Leach, med. student.

2318. The gizzard of a pigeon transfixed by a pin, and without anything to show that it had troubled the bird. (See No. 2175.) 1857.

Dr. O. W. Holmes.

See biliary calculi.

2319. A small portion of very pure ambergris. The lot, from which this was selected, weighed about 50 lbs., and was taken from the intestine of a sperm whale; the animal being in sufficiently good condition. The quality of the mass varied as to purity; there being many teeth of the squid mixed with it, and one of them is here shown. 1865.

Mr. Heman Smith, merchant.

2320. Fat, discharged from the bowels of a man, æt. forty-five, who had "choleric" in England twenty years ago, and had been passing ever since, and several times daily, a greenish-yellow, oily, and very offensive fluid, that after a while became hard, like tallow. He was pale, but had a fair amount of flesh and strength, and a good appetite. Legs œdematous, but without albumen in the urine. Alkalies tried for a week or two, but without effect. 1868.

Dr. Henry K. Oliver.

2321-3. Calculi, from the intestine of a horse. The largest is about $3\frac{1}{2}$ in. in diameter, and weighs 2 lbs. $3\frac{1}{2}$ oz.; form very regular; rounded, with some flattening, and with one marked façette. The smallest is between 2 and 3 in. in diameter, weighs $9\frac{1}{2}$ oz., is not rounded, and has very marked façettes; having been sawed, the concentrically laminated structure is strongly marked, and for a nucleus there is seen a piece of iron, a few lines in diameter, as it appears upon the cut surface. The third specimen weighs $18\frac{1}{2}$ oz., and is intermediate between the two others in regard to size and façettes; on section, it resembles the second in structure, and in having a piece of iron for its nucleus. In all of the three the color is a pale brownish, with a mixture of gray; the structure of the two that have been sawed is rather coarse than otherwise; and the laminated structure of the largest is perfectly well marked externally.

Dr. James C. White found them to consist mostly of the triple phosphate of ammonia and magnesia; a little phosphate of lime, and a trace of carbonate of lime. There was a considerable amount of silica also mixed mechanically with it, and some little animal matter. (Med. Jour. Vol. LXIII. p. 361.) 1860.

Mr. Robert T. Edes, med. student.

2324. A bezoar, of a spherical form, and highly polished upon the surface. Diameter $2\frac{3}{4}$ in. A stone seems to form the nucleus; and around this the layers of diphosphate of lime are arranged in concentric laminae, and with the radiated structure that is peculiar to these concretions. 1847.

Dr. J. C. Warren.

The last, and four next specimens were analyzed by Dr. J. C. White.

2325. A second specimen. Cylindrical, with hemispherical terminations. Length, $\frac{7}{12}$ in. Surface partly covered with a black polish. Nucleus formed of vegetable fibre. Composed of the diphosphate of lime; as are the next three.

This and the next three specimens were presented to the college many years ago by Dr. J. Nichols, of London. (See urinary calculi, page 533.)

2326. A third specimen; resembles the last, but is more spherical, and the layers are more concentric. Structure radiating and crystalline. Length, $\frac{3}{4}$ in.
2327. A fourth specimen. This consists of two separate concretions, united, and between them is a deep groove, that is partly filled up with woody tissue. Form oval, and surface polished. Diameters, 3 in. by 2 in. Outer layers composed of long radiating crystals.
2328. Fragment of a fifth. Very compact; and surface polished.
2329. A body from the appendix cæci, of a brownish color and elongated form; length, $\frac{1}{2}$ in.

From a woman, æt. twenty-two years, who died of typhlo-enteritis after about a week's sickness; the symptoms being much less marked than usual. The appendix was adherent, extensively gangrenous, and largely perforated near its extremity; with acute and universal peritonitis. 1864. *Dr. C. Ellis.*

2330. A smooth, compact, pale-brownish mass, from the appendix cæci, of an irregular form, and about as large as the tip of the little finger. A smaller one that was also removed, consisted, according to Dr. Bacon, of fæcal matter and vegetable fibre, with phosphate of lime one-fifth.

From a healthy young man, twenty-one years of age. Duration of disease one week. Pain in pyloric region, vomiting and constipation for the first two days; and afterwards a more severe pain toward the right iliac fossa; with vomiting, tympanites, and tenderness until death. On dissection, extensive peritonitis was found, with a sloughing of the appendix near the foreign bodies. 1860.

Dr. E. B. Hammond, of Nashua, N. H.

2331. Hardened fæces, from the appendix cæci. (See No. 2277.) 1868. *Dr. J. Homans.*

SERIES XXXI.—PERITONEUM AND THE
SUBJACENT TISSUE.

2332. Thibert's model. A portion of small intestine laid open, and showing the serous surface highly injected, and in several places deeply ulcerated. 1849.

Dr. J. Ware.

2333. A portion of intestine, with the mesentery, from a "white whale" (*beluga borealis*), showing a large quantity of lymph upon the serous surface. The whole membrane was similarly affected; and there was a small amount of serum in the cavity. The animal was taken in the St. Lawrence River; and was exhibited, alive, for several months, in this city. (See Dr. W.'s anatomical description, with figures, in the Jour. of the Boston Soc. of Nat. History, Vol. vii. p. 603.) 1863. *Dr. J. Wyman:*

2334. A portion of the lower part of the large intestine, showing a direct, circular opening, about one and one-half lines in diameter, and that communicated with a large, circumscribed peritoneal abscess.

From a young woman, who died about three and a half months after criminal abortion had been produced. During the last six weeks there had been diarrhœa, vomiting, soreness about the right hip, and great prostration; the dejections, for some time, being purulent. 1869.

Dr. C. C. Tower, of S. Weymouth.

2335. Numerous small distinct granulations upon the serous surface of the intestine. The mesenteric glands (No. 1845) were tubercular. 1860.

2336. Thibert's model. Small intestine and mesentery; serous membrane reddened, with very numerous tubercular granulations. 1849.

Dr. J. Ware.

Ascarides, from the peritoneal cavity of a horse. (See No. 3079.)

2337. A dense, fleshy body that was found free in the peritoneal cavity. It is of a somewhat flattened, heart-shaped form, 1 in. in length, and smooth upon the external sur-

face. Internally there are some small, cretaceous grains, and it is not distinctly fibrous. 1869.

Dr. J. B. S. Jackson.

2338. A portion of small intestine from a hog, inflated and dried, with the mesentery, and showing a sub-peritoneal emphysema that was quite extensive. The specimen was sent to Dr. B., who referred to Mr. Paget's description of the affection, under the head of "Gaseous cysts" (Surg. Path. p. 309); to Mr. Hunter's figure of a similar case; to the remark of Mr. H. that hogs are subject to ulceration of the alimentary canal; and to that of the butchers that this appearance of air-cells is not of rare occurrence.

In connection with these last statements, Dr. B. further referred to the same form of emphysema that he had seen in a case of ulcer at the pylorus; and I have seen the same in a case of perforation of an ulcer of the duodenum. Dr. B. supposed, in his case, that the air was forced into the cellular tissue from the stomach, and through the ulcer. In the present case the stomach was not sent with the intestine; but the animal was said to be healthy, excepting the emphysema. 1854.

Dr. H. J. Bigelow.

2339. A second and similar specimen, from a hog; dried.

The air vesicles were especially at the junction of the intestine and mesentery, and extended throughout a large portion of its length; varying in size; some agglomerated, and others solitary; some imbedded in fat, and others exceedingly delicate, and hanging from the peritoneal surface by a slender pedicle of some length. There was no ulcer in the stomach or duodenum. 1855.

Dr. H. J. Bigelow.

2340. A portion of intestine from the last case; in spirit, and showing well the pedunculated vesicles. 1855.

Dr. H. J. Bigelow.

2341. A portion of intestine showing the appendices epiploicæ very largely developed and loaded with fat. Several of them, smaller than the rest, were firm to the feel, as from an absorption of the fat, of a dull reddish color, and attached to the intestine by a short but firm fibrous pedicle; looking as if they might readily have been detached; and,

excepting the color, resembling the masses that are sometimes found free in the peritoneal cavity, though nothing of the kind was found in the present case.

From a very fat female subject. 1860.

Dr. R. M. Hodges.

2342. Melanotic masses upon the mesentery; of a pale brownish color, and varying from the size of a pea to that of an English walnut. (See No. 1744.) 1849.

Dr. J. B. S. Jackson.

2343. Fundus of the uterus with one of the ovaries, from the same patient as the last, and showing blackish melanotic masses upon the serous surface. 1859.

Dr. J. B. S. Jackson.

2344. A portion of the abdominal parietes, showing a protrusion and adhesion of the omentum.

From a little girl who was transfixed by a hay-hook. (No. 3116.) 1857. *Dr. J. P. Maynard, of Dedham.*

Mesenteric glands, cretaceous. (See No. 1851-2.)

2345. A very fine specimen of colloid disease of the omentum, the whole of which was most extensively affected; with more or less deposit upon different parts of the peritoneal surface. The organs were not involved. From an old woman. 1868.

Dr. Chas. B. Porter, Jr.

2346. A second specimen.—From a man, æt. sixty-three years, and of robust health. In Dec., 1862, he was very much jarred and bruised by a fall upon the ice; and, besides general pain and soreness, he had great pain and tenderness across the abdomen, just below the umbilicus. On account of this last, he was often obliged to lie down, and finally to give up his business. His general health also failed; and he soon noticed a fulness of the abdomen, that went on increasing. On the seventh of February, when Dr. R. first saw him, he was quite feeble, with an anxious countenance and difficult respiration, but without the look of a very sick man. The abdomen was full and tense, and felt below the umbilicus as if it would burst. The diagnosis was ascites, with peritonitis, as the result of the fall. April 13th, about six quarts of an oily-looking sub-

stance, with a great quantity of fibrous matter, were drawn off; and showing, microscopically, innumerable cells, mostly degenerated by fatty metamorphosis. It was thought after this that there must be a cyst. In May and June he was tapped five times, and after the 20th of June the canula was left in; the fluid varying more or less at the different operations. Sinking was gradual, with great emaciation, great pain, and tenderness of the abdomen, œdema of the lower extremities, vomiting at last, and death on the 8th of July.

On dissection, the parietes of the abdomen, the omentum, and the interior of the abdomen generally contained a great amount of colloid deposit, in which the microscope showed an abundance of fat; the organs being healthy. There was also an extensive and recent peritonitis. 1866.

Dr. W. Read.

2347. A peculiar and probably malignant disease of the omentum.

The following account of the case was from Dr. Asa Millet, of Abington, with whom Dr. J. saw the patient. She was thirty-nine years of age; had been sick nine weeks when Dr. M. first saw her, and had been treated for ascites. Health previously good. Dr. M. found some ascites, with a tumor, three or four inches in diameter, near the left iliac region; and he felt tumors by the vagina and rectum. She was much emaciated, and complained chiefly of exhaustion, but not much of pain. The tumor and the ascites increased; and she died three weeks afterwards.

The omentum, which was sent to Dr. J., was very greatly thickened, with rounded edges, smooth upon the surface, and dense to the feel. On incision, it was uniformly white, and quite tough, as if composed of a fine and compact fibro-cellular tissue. The uterus, which was also sent, was completely invested with the same material, and its substance was more or less infiltrated by it; the inner surface being nearly white. Dr. M. found similar formations along the large intestine and the edge of the liver, but none upon the abdominal parietes, nor in the organs. There were also six quarts of fluid in the peritoneal cavity. 1857.

Dr. John Jeffries.

The above disease very much resembled that of two children, whom I examined several years ago, except that the structure was more compact. (No. 507 in the Cabinet of the Society for Medical Improvement.) There were nowhere any of the usual appearances of carcinoma. A case not very unlike the above has also very recently (1870) occurred in this vicinity.

2348. Scirrhus omentum; thick, whitish, hard, irregular, and coarsely granulated. 1847. *Dr. J. C. Warren.*
2349. A portion of a cancerous omentum, the whole of which formed a large, thick, dense, and coarsely granulated mass. The mesenteric glands, pancreas, and uterus were also cancerous; and there were numerous subcutaneous tumors over the abdomen.

From a woman, æt. forty, who had had cancer of the labia pudendi for two years. No hereditary tendency to cancer could be traced. 1861.

SERIES XXXII.—HERNIA.

2350. An inguinal hernia upon the left side, so large as to have contained nearly the whole of the intestine. It extended to the knees, and was supported by a cloth that was slung over the shoulders. There is also a small hernia upon the other side. The parts having been removed, *en masse*, with a small piece of the pelvis, the vessels were injected, the intestine was inflated, they were fitted into a new pelvis, and the preparation was dried. (See the Life of Dr. J. C. Warren, Vol. II. p. 418.) 1847.
Dr. J. C. Warren.
2351. Sac of an inguinal hernia distended and dried. 1847.
Dr. J. C. Warren.
- 2352-3. Thibert's models. Strangulated inguinal hernia and operation.
Dr. G. Hayward.
2354. Photograph of an adult negro, with a large scrotal hernia of four years' duration. 1868.
Dr. Elliott Cones, Ass't Surgeon U. S. A.

2355. A scrotal hernia; laid open; intestinal and omental.
 • 1847. *Dr. J. C. Warren.*

2356. Firm adhesion of the small intestine at the internal ring, from which it had almost escaped; with perfect strangulation in the recent state.

From a man, æt. sixty-five. On the 18th of May, strangulation of an old hernia came on, without any violent symptoms, and on the third and fourth day the tumor disappeared. He, however, gradually got worse, with great uneasiness and occasional retching, and on the 26th he was seen by Dr. C. He was then in a collapsed state, and vomited at long intervals a thin "stercoraceous" fluid; abdomen tympanitic, and he had had no free dej. since the attack. On the 28th he died.

Dr. C. thought the case remarkable from the fact of the continuance of the strangulation after the apparent reduction and from its slow progress. 1859.

Dr. H. G. Clark.

2357-8. Thibert's models. Strangulated crural hernia and operation. The patient was a female, aged thirty, and the parts had been inflamed for three days.

Dr. G. Hayward.

2359. A large crural and intestinal hernia. The testicle is just below the great mass; and portions of the inguinal artery and vein are also shown. The pubes has been sawed out, and helps to preserve the relation of the parts. In spirit. 1847.

Dr. J. C. Warren.

2360. A portion of the ileum, from a man who had been successfully operated on for artificial anus.

The patient was fifty-one years of age, of intemperate habits, and had been ruptured since the year 1844. In Sept., 1853, strangulation occurred, followed by sloughing; and from that time the fæces were discharged altogether at the groin. In June, 1854, Dr. J. commenced a series of operations upon him, the result of which was an improvement, and finally an entire closure of the opening in the intestine, though there was an occasional discharge of pus until the last; a small cavity being found, on dissection, in the integument.

The hernia was inguinal, and involved the intestine

about 20 in. from the cæcum. The ileum extended about $1\frac{1}{2}$ in. below Poupart's ligament, and then doubled sharply upon itself. The canal seemed quite free, though it contained a few grape-seeds; and neither upon the external nor upon the internal surface was there the slightest appearance of a cicatrix. Toward the cul-de-sac, however, a band traversed a portion of the calibre of the intestine, two or three lines in width midway, but broader at each end, and covered by mucous membrane. The upper portion of the intestine is larger than the lower; and just above the junction of the two, the upper sends off something like a diverticulum about $\frac{3}{4}$ in. in length, closely adherent to the intestine, and of a white opaque color externally, though without thickening or induration. Whether this was a true diverticulum, that may have had something to do with the descent of the intestine, is uncertain. 1867.

Dr. J. S. Jones.

2361. A portion of small intestine, showing, to the extent of about 2 in., the effect of strangulation. 1847.

Dr. J. C. Warren.

2362. An umbilical, omental hernia, from a fleshy old woman, who died of other disease. The tumor is nearly 2 in. in diameter. 1856.

Dr. H. J. Bigelow.

2363. A second specimen. Protrusion quite small. 1847.

Dr. J. C. Warren.

2364. A portion of omentum, $4\frac{3}{4}$ in. in length, removed by incision in a case of large crural hernia; the strangulation having lasted seven days. The operation was done in 1805, and was one of the first that was ever performed in this city. The patient recovered, and lived many years afterwards. (See Life of Dr. J. C. Warren, Vol. II. p. 90.) 1847.

Dr. J. C. Warren.

2365. A preparation, that shows strongly the conservative powers of nature.

A man, æt. forty-four, had an old, partially adherent, intestinal, scrotal hernia; and, as if to prevent any further descent of it, there was stretched across the cavity of the pelvis a strong, defined band, $3\frac{1}{2}$ in. in length and one and one-half lines in diameter; one end of it being attached to the large intestine just where it enters the pelvis, and the

other to the mesentery of the ileum about where it entered the hernial sac. And this was the only peritoneal adhesion that existed. The very means, however, used to oppose the hernia, caused, at last, the patient's death, by producing an internal strangulation of the intestine; several similar attacks having previously occurred, as so often happens where a permanent cause exists.

In the preparation the band only has been preserved, with a small portion of intestine at one end and of mesentery at the other. 1863. *Dr. J. B. S. Jackson.*

2366. Photograph of an old man who was the subject of a large ventral hernia. Eight or ten years before his death he had extensive suppuration in the front of the abdomen, and it continued for several years. For the last three or four years the contents of the abdomen had been protruding, until the mass became "larger than a ham," occupying nearly the whole space from the pubes to the costal cartilages, "wagging up and down during respiration," and covered so thinly that the motion of the intestines was plainly seen. (Med. Jour. Feb. 6th, 1868.) 1868.

Dr. Norton Folsom, Assistant Superintendent of the Lunatic Asylum at Taunton.

2367. Diaphragmatic hernia in a raccoon; omental. The edges of the opening are smooth, and the parts appear quite healthy.

The term hernia is not properly applicable to these cases, as there is no sac. 1852.

Mr. A. H. Ogden, Taxidermist.

SERIES XXXIII.—THE LIVER AND DUCTS.

I. LIVER.

2368. Cast in plaster, colored, showing a very extensive laceration of the organ.

The patient, æt. fifty-five, who was said to have been run over by a railroad car, was carried to the hospital (608, 53), and died in one and one-half hours. The liver

was large and fatty, and there was a pint of thin blood in the peritoneal cavity. Other injuries were also found. 1864. *Museum Fund.*

2369. An abscess in the right lobe of the liver, about three inches in diameter; filled, in the recent state, with a dirty brown, and very offensive liquid, coated with a dirty-white lymph, and at one point threatening to burst into the peritoneal cavity. The organ was generally of a dull red color, but blackish about the cavity. No gall-bladder was seen; but the hepatic duct contained a very large calculus (No. 2403), and in the ducts within the liver were some minute ones.

From a hard-working man, æt. forty-eight, who had been always subject to attacks of bilious vomiting, but otherwise healthy. Being unwell at the time, in consequence of a local injury, he was attacked with feverish symptoms, and sharp pain, with tenderness about the liver, followed by a pain in the right shoulder, chills, and heat, diminished appetite, and occasional nausea, skin dry and hot, or bathed in perspiration. After the nineteenth day, the skin, etc., were colored by bile; and during the last two days there was a very marked failure, with dullness on percussion and absence of respiration over the lower back part of the right lung. To explain this last, there was found more than a quart of offensive purulent serum in the pleural cavity, with lymph. The whole duration of the acute symptoms was thirty days, and they led Dr. A. to a correct diagnosis of the case. (*Med. Jour. Vol. LIII. p. 232.*) 1855. *Dr. Zabdiel B. Adams.*

2370. An abscess in the substance of the organ, about 2 in. in diameter. The disease was supposed to be of about six weeks' duration, and for some time there had been an external opening just below the sternum, but without jaundice.

From a sailor, who had been on the coast of Africa. There was a profuse discharge of offensive pus; and he finally died from an opening into the peritoneal cavity. 1868. *Dr. J. W. Graves, of Chelsea.*

2371. A portion of liver from a case of pyemia. (See No. 1199.)

The organ weighed 5 lbs. 10 oz., and contained great numbers of recent abscesses, from the size of a pea to that of a peach-stone, and giving it, in some parts, quite a honey-comb appearance. The spleen weighed 2 lbs. 3 oz., and in it were large gangrenous abscesses. There were also acute peritonitis and sloughing of the stump. 1868.

Dr. H. J. Bigelow.

2372. The greater part of the liver, showing a cavity that held, by estimate, four pints of thick pus; the interior being thinly coated with opaque lymph.

From a man, *æt.* forty-eight, who came from England in Sept., 1867; went directly to Chicago, and eight days afterward was taken sick. His symptoms were diarrhœa, and constant pain in the epigastrium, with chilliness and general pains at first, and a considerable loss of flesh and strength. Entered the hospital Dec. 5th (276, 52), having recently arrived from the West, and kept his bed, most of the time until his death, which occurred on the 26th of January. There were tenderness, very severe pain, and extensive dulness on percussion in the region of the liver; and fulness in the right half of the epigastric region; but there was no fever nor yellowness of the surface.

Anteriorly the abscess had approached very near to the surface of the liver; and, superiorly, the diaphragm formed the parietes to the extent of two or three inches, and bulged into the pericardial sac. This last was coated with fibrine, and contained about two pints of fluid; and in the right pleural cavity was a pint of serum. Otherwise, the liver was healthy, except a commencing abscess about one and one-half inches in diameter, and not far from the large one. (*Med. Jour.*, May 14th, 1868.) 1868.

Dr. C. Ellis.

2373. A simple cyst, about the size of a large nutmeg, just below the surface of the liver, and lined, in the recent state, by a thin, bluish membrane.

From a man, *æt.* forty-five, who died after a fracture. (*Hospital*, 99, 120.) 1863.

Dr. C. Ellis.

2374. A defined, rounded cyst, of the same size as the last, lined by a well-marked opaque membrane, and filled, when

- recent, with serum. No evidence, microscopically, of parasitic origin. The liver, otherwise, was quite healthy. From a case of Addison's disease. 1861. *Dr. C. Ellis.*
2375. Thibert's model. Fatty liver. 1849. *Dr. J. Ware.*
2376. A portion of fatty liver, in an empty jar. The fat has exuded spontaneously; and, at an average summer temperature, resembled clear olive-oil; but for the last few years it has not liquefied even in the summer season. 1857. *Dr. J. B. S. Jackson.*
2377. Thibert's model. "Cirrhosis," but not well represented. 1849. *Dr. J. Ware.*
2378. Portion of a granulated liver. This would seem to be a much more proper term than "cirrhosis," as this last has reference (as Cruveilhier remarks, — *κίρροσ*, yellow) to the color, that is, generally, though by no means always observed; the organ being sometimes red and occasionally green; whereas, it is always granulated when the disease exists in any marked degree. 1847. *Dr. J. C. Warren.*
2379. A section of the liver from a sheep, and showing a peculiar structural change. It resembles three specimens (Nos. 1459-61) that were examined at the Fort Pitt Museum, near London, in 1851, as perfectly as if it were from the same subject. In the catalogue of that Museum, the liver is described as having a peculiar cribriform or honeycombed appearance, from small cavities in its substance; the cavities not lined by a membrane, and contained no fluid; structure soft and homogeneous, and had, in the recent state, a bluish or leaden hue; disease of the liver not suspected during life. — From Mr. John Arthur, of the University of Edinburgh. 1852.

Dr. J. B. S. Jackson.

2380. Peculiar disease of the liver, from a little boy, æt. six years, who had had ascites, drowsiness, etc., for some months. (Hospital, 237, 128.)

The organ weighed two pounds ten ounces. "Of an olive-brown color, through which ran irregular white lines of fibrous tissue. Very firm, and required considerable force to make an incision. Externally studded with small granulations, which were less marked on cut surface; but, on pressure, the latter was seen to be studded with minute

granulations, evidently resulting from the pressure of the fibrous material upon the soft hepatic substance." The spleen was much enlarged. 1863. *Dr. C. Ellis.*

2381. Syphilitic disease of the liver. Several opaque, yellowish-white compact masses were found in the substance of the organ, perfectly defined, uniform in appearance, and from half an inch in diameter to the size of a hen's egg. The liver was rather large and quite firm; acini remarkably distinct; and upon the anterior surface were several depressed cicatrices about four or five lines in diameter and in depth. There was also disease of the dura mater, brain, and kidneys, which Dr. T. supposed to be of a syphilitic character.

From a man, æt. forty-nine, who had syphilis twenty-six years before his death, and subsequently various secondary manifestations of the disease. Intermittent fever thirteen years before death, and occasional attacks ever afterwards. During the last year dyspepsia, diarrhœa, pulmonary symptoms, and headache. Death at last sudden. His children look, and have always been, unhealthy. (See *Med. Jour.*, July 15th, 1869, for details, and quotations from authors in regard to the disease.) 1869. *Dr. J. B. Treadwell.*

2382. Colored cast, showing the external appearances in a typical case of encephaloid disease of the liver. There were throughout numerous rounded, defined masses, and generally about 2 inches in diameter; many projected above the surface, and the central depression was very marked in three or four of them. In structure they were whitish, opaque, very generally soft, and in the centre completely broken down. Some yellow, xanthoid material, and some effused blood. Intervening substance healthy. Weight of the organ 3 pounds $6\frac{1}{4}$ ounces. The stomach was also very extensively cancerous.

The patient, a man æt. sixty-nine years, had had diarrhœa for nearly two years, had done no work for nine months, and failed rapidly the last few weeks. There had been frequent nausea, occasional vomiting, and toward the last with much distress. In October he was seen casually by Dr. J. F. Wakefield, of South Malden, and by whom the organs were presented; there being then great

uneasiness at the epigastrium, with œdema of the lower extremities. Dec. 23d, Dr. W. was called to him professionally, and found sufficient evidence of malignant disease. The liver was very distinctly felt, and had a stony hardness, with dulness on percussion. There was nausea, such that scarcely a teaspoonful of water could be retained; great pain on pressure over the epigastrium; some jaundice, with great œdema and dyspnœa; and he died on the 27th. The dyspnœa may have been connected with a large effusion of serum that was found in the pericardium. 1869.

Museum Fund.

Three Thibert's models. 1849.

Dr. J. Ware.

2383. Encephaloid disease of the liver.

2384. Disease less advanced. The parts directly about the diseased portions are highly injected with blood. Internal view.

2385. External view of the last specimen.

2386. Defined, black melanotic masses in the liver. (See No. 1744.) 1849.

Dr. J. B. S. Jackson.

2387. A portion of the liver, containing echinococci. — From a man, æt. twenty-four years, who died at the hospital, of pthisis (202, 211).

“Upon the convex surface of the organ, near the right edge, was a low, yellow, fluctuating protuberance, more than an inch in diameter, and surrounded by a zone of delicate, pink blood-vessels. On incision, there escaped a slightly opaque fluid, which had filled a syst about $1\frac{1}{2}$ in. in diameter. On further examination, there was found, closely attached to the healthy substance of the liver, a thin, bluish-white membrane, within which was a second, nearly white, quite brittle, about half a line in thickness, and which fell away from the first, and lay in wrinkles at the bottom of the cavity. Upon its inner surface were an extremely thin layer of brown, pulpy matter, and many small prominences. No secondary cysts were seen.”

“With the microscope, numerous hooklets of the echinococci were detached in the fluid above mentioned; and in the pulpy layer the animals themselves were found in large numbers, mingled with scattered hooklets and fat-

globules. The white, brittle membrane presented a finely striated appearance, as if made up of concentric layers. Near the cyst, and in the substance of the liver, was a small effusion of blood."

In the preparation the thick opaque cyst that contained the hooklets is shown, and to some extent the thin outer membrane.

In connection with this case Dr. E. described minutely another. (Med. Jour. Vol. LIV. p. 344.) 1856.

Dr. C. Ellis.

2388. A portion of the liver of a hog, that contained large numbers of acephalocysts. The parasites have been removed (No. 3073), but the interior of several of the cysts that surrounded them is shown.

The liver itself was healthy; as was the animal, which was slaughtered for the market. 1854.

Dr. H. J. Bigelow.

2389. A similar specimen, apparently. 1847.

Dr. J. C. Warren.

II. GALL-BLADDER AND DUCTS.

2390. A defined, chronic ulcer at the fundus of the gall-bladder, and about $1\frac{1}{2}$ in. in diameter; perforation being prevented by external adhesions. The organ was small, and contained some thin, puriform fluid, besides a quantity of calculi. (No. 2428.)

From a lady, about forty-five years of age, who died of phthisis. 1850.

Dr. J. B. S. Jackson.

2391. A thickened, opaque, inelastic gall-bladder, that was contracted about a calculus. (No. 2416.) 1847.

Dr. J. C. Warren.

2392. A gall-bladder, filled with calculi, and dried. 1847.

Dr. J. C. Warren.

2393. A second specimen. From a woman, æt. seventy-three, who had for six months gastric symptoms, with a jaundiced hue, and general decline of the health. 1867.

Dr. C. C. Tower, of S, Weymouth.

2394. A round, biliary calculus, about $1\frac{1}{4}$ in. in diameter, and closely impacted in the cystic duct, near its origin from

the gall-bladder; a wet preparation. Duct greatly dilated toward this last, but of about the usual size, and pervious beyond the calculus. Other calculi (No. 2434) were found in the gall-bladder.

From an elderly lady, who died of disease of the heart, etc. 1856. *Dr. J. B. S. Jackson.*

2395. An oval, biliary calculus, about $1\frac{1}{2}$ in. by $\frac{7}{8}$ in., contained within and closely invested by the fundus of the gall-bladder.

From a lady, about seventy years of age. Gall-stone not suspected. 1862. *Dr. C. Ellis.*

2396. A calculus, about the size of a pigeon's egg, tightly embraced by, and adherent to, the fundus of the gall-bladder.

From a woman, æt. sixty-eight years, who died of disease of the heart, and without any report of biliary symptoms. (Hospital, 239, 104.) 1862. *Dr. C. Ellis.*

2397. Gall-bladder, contracted about two calculi; about as large as the top of the finger. Cut through, laid open, and dried.

From a woman, æt. seventy. All of the bile-ducts were dilated. (Hospital, 163, 104.) 1850.

2398. A firm calculus, of a very regular ovoid form, about 2 in. in length, and 1 in. in diameter. It is closely invested by the gall-bladder, and the calculus has been sawed through. A dried specimen.

From a lady, seventy-six years of age, who had been under the care of Dr. Fletcher, of Pepperell, for disease of the heart; and there had also been some derangement of the digestive functions. 1870.

Dr. Amos B. Bancroft, of Chelsea.

2399. Gall-bladder, with the ducts, and a portion of the intestine; in spirit.

The parietes of the first are diseased. The cystic duct, in the recent state, when cut open, measured at the largest part, $1\frac{1}{2}$ in. transversely; the hepatic $1\frac{3}{4}$ in.; and the common duct 2 in.; but this last contracted gradually to its natural size, before it opened into the intestine. Upon the inner surface of the intestine, and commencing $\frac{1}{4}$ in. from

the pylorus, is a defined and recent ulcer, $1\frac{1}{4}$ by $\frac{3}{4}$ in. in extent, and corresponding to an adhesion that existed between the intestine and the dilated hepatic duct. In the gall-bladder and ducts were about a dessert-spoonful of small, round, smooth calculi.

The patient was a large, fine-looking man, forty-nine years of age, who had been subject to colic. Five weeks before death he had an attack of pain across the upper part of the abdomen, followed by jaundice; kept his bed for a few days, but was soon about his business. Nine days before his death he was attacked in the street with violent abdominal pain, nausea, and vomiting. The nausea soon subsided, but he had pain in paroxysms, with tenderness till the last. During the last five days he had hemorrhage from the bowels, and under this he sank. The small intestine contained blood; and from the ulcer in the duodenum there hung off a large coagulum. (See Amer. Jour. of Med. Sc., July, 1852.) 1852.

Dr. John Homans, Sen.

The ulceration of the duodenum, in the above case, when there was none upon the inner surface of the hepatic duct, is interesting in connection with a case of aneurism of the arch of the aorta in the Med. Soc.'s Cabinet (No. 373), and in which the inner surface of the œsophagus is ulcerated, but that of the sac is not; and with an aneurism of the arch of the aorta, that is figured by Cruveilhier (liv. 3, pl. 4) that burst into the œsophagus, and in which the inner surface of the trachea is ulcerated, but the corresponding part of the sac is not. The ulceration does not go on continuously from the diseased surface, or commence upon the inner surface of the cavity that contains something that is to be got rid of, but it commences, independently, upon the healthy inner surface of the canal, into which an opening is to take place.

2400. Opening between the gall-bladder and duodenum, sufficiently large to admit the fore-finger; besides a smaller one. The two organs are firmly adherent, and the gall-bladder is much contracted and thickened. The opening had recently given issue to a large gall-stone (No. 2405) that was found in the ileum, one foot above the cæcum;

several ineffectual attempts at a passage having previously been made.

From a woman, æt. forty-three years. In 1856 she complained frequently of distress at the epigastrium. Jan. 17th, 1857, she had violent colic, with much retching and vomiting, but was relieved in a few hours. On the 26th of Jan., the 5th of March, and the 29th of April, she had similar attacks, and each was more severe than the preceding. On the 2d of May the pain was relieved by etherization; five copious, thin, yellow discharges followed, with much prostration, and she died the next morning. There was no jaundice. (Med. Jour. Vol. LVI. p. 367.) 1858. *Dr. C. Ellis.*

2401. Gall-bladder opening into the duodenum, 3 in. from the pylorus. The organ, which was firmly adherent to the intestine and to the colon, was contracted, thickened, looked upon the inner surface like an old tuberculous cavity, and was distended with blood, the source of which last was not found. The opening into the intestine was about midway between the fundus and the neck, and was perhaps two lines in diameter. In the cavity of the organ was a large gall-stone (No. 2402); and the cystic duct seemed to have been obliterated.

From a woman, æt. sixty-five years, who had been well until the 1st of March, when she had an attack of bilious vomiting; followed by deep jaundice, which continued until her death on the 9th of July. There was also pain in the hypochoñdria; nausea, thirst, a burning sensation in the epigastrium, and an irregular, knobby feel to the edge of the liver. (Hospital, 197, 206; and Med. Jour. Vol. LII. p. 498.) 1855. *Dr. C. Ellis.*

III. BILIARY CALCULI.

Many of these specimens have faded, more or less, since they were collected, from exposure to the light, so that their color will not often be referred to.

2402. A calculus, $1\frac{1}{2}$ in. long, oval, and finely granulated upon surface. (See No. 2401.) 1855. *Dr. C. Ellis.*

2403. A calculus, from the hepatic duct, 2 in. in length, and 8 or 10 lines in diameter. (See No. 2369.) 1855.

Dr. Z. B. Adams.

2404. A calculus, about $\frac{1}{2}$ in. in diameter, and with marked facettes, that was taken from the duct just within its opening into the intestine. The ducts generally were dilated, and the gall-bladder nearly obliterated.

The patient was a woman, forty-three years of age, who had been under the care of Dr. D. D. Thayer, and subject for about twenty years to attacks of pain, that were relieved by vomiting; these attacks being perhaps owing to the passage of calculi, as the present specimen was the only one found, and its form showed that there must have been others. The orifice of the duct also readily allowed the passage of a common blow-pipe. In Nov., 1866, she was taken more sick, and never again did any work, though not confined entirely to the house. Through the winter she had frequent chills and heat. Pain in the epigastrium, and extending to the region of the gall-bladder, was from the first, and so long as she lived, a constant and often severe symptom. In January, 1867, she became jaundiced, and remained so ever afterward, and sometimes very deeply so. In Feb., 1868, she had epistaxis for three weeks, that threatened her life; and in Nov., 1868, another severe attack that proved fatal about the fifth day. No trace of coagulum was found on dissection; but the blood was very thin and pale, and a portion of it that was removed in a phial showed on the following day a yellow serum only, with a small amount of red sediment.

The tendency to hemorrhage has been shown in many other cases of jaundice that have occurred here, and in not a few has been the cause of death.

In regard to the calculus, it was thought that it may have passed down into the common duct in Nov., 1866, as there was never after that time any one great change in the course of the biliary symptoms. 1868.

Dr. J. B. S. Jackson.

2405. A dark-brown and nodular calculus, more than an inch in diameter. It passed into the intestine, and caused fatal obstruction. (See No. 2400.) 1858. *Dr. C. Ellis.*

2406. A gall-stone from the ileum, about a foot from the caecal valve. It is of a dark-brown color, about $1\frac{1}{2}$ in. in length, an inch in diameter, and worn, as by attrition, at one extremity.

In Oct., 1866, Dr. Buckingham saw the patient, with pain in the epigastrium, tenderness along the lower edge of the liver, nausea, and diarrhoea; and, a week before, there had been excessive pain in the same region, with yellowness of the skin. Twenty years before he had had an attack that was thought to be connected with a biliary calculus. April 24th, 1867, the spermatic vein was tied for varicocele by another physician; and on the 27th he died.

A few inches from the gall-stone there was a diverticulum; and opposite to this last, upon the inner surface of the intestine, an irregular ulcer. The gall-bladder was destroyed; and, corresponding to it, an irregular, discolored opening from the duodenum, about $\frac{1}{3}$ in. in diameter. In connection with the recent operation, there was found recent, though not extensive, peritonitis. 1868.

Dr. C. W. Swan.

2407. A calculus, that is broken upon one side, but was originally of a cylindrical form, about $\frac{3}{4}$ in. by from $\frac{5}{8}$ in. to 1 in.; very-marked facette upon each end.

From a woman, æt. sixty-six years, who discharged the calculus from the bowels, after an attack of severe colic, vomiting, great constipation, and collapse. This was the only attack she ever had; and fourteen years afterward she was in excellent health. 1860.

Dr. E. H. Clapp, of Wrentham.

2408. A barrel-shaped calculus, $1\frac{1}{2}$ in. by $1\frac{1}{8}$ in.; light-colored, remarkably compact, and smooth upon the surface. — From a lady, over eighty-two years old, who was suddenly attacked with severe pain in the epigastric region, followed by nausea and vomiting. The symptoms continued for six days, but gradually diminished; and on the 7th the calculus was passed from the bowels, with two or three smaller ones, and with very severe pain. Convalescence rapid. (Med. Jour. Vol. LXVI. p. 452.) 1862.

Dr. Francis Collamore, of Pembroke.

2409. A mass nearly as large as the last joint of the thumb, and consisting, apparently, of a fusion of several calculi.

It was passed from the bowels by a patient, who was seen by Dr. S. in consultation with Dr. David S. Fogg, of Dedham; an elderly woman, long subject to hepatic symptoms, who had never before passed calculi, and was quite relieved after the discharge. 1858.

Dr. D. H. Storer.

2410. Deposit upon a watch-crystal, in the course of an examination by Dr. B., of the last specimen, and described by him as a modification of cholesterine. 1858.

Dr. J. Bacon.

2411. Cast of a biliary calculus, that was discharged from the bowels of a female. It is about one inch in diameter, and quite angular. 1869.

Museum Fund.

2412. Two calculi, as large as the last joint of the thumb, smooth upon the surface, and one of them of a decidedly reddish color.

From a woman, over seventy years of age, who walked out a few days before her death, and was supposed to have died of old age. The liver, however, was much enlarged, and contained a great amount of encephaloid disease; neither this nor the gall-stones having been suspected. 1869.

Dr. J. R. Little, of Jamaica Plain.

2413. Forty-two calculi; generally about three lines in diameter; color, grayish.

From a woman who committed suicide. In the right hypochondrium was a well-defined tumor, of about the size of the fist, but not particularly tender. Gall-bladder filled with inspissated bile. (Med. Jour. Vol. LXX. p. 192.) 1864.

Dr. H. R. Storer.

2414. A calculus, nearly an inch long, and resembling No. 2402. The gall-bladder was ulcerated, and ruptured into the peritoneal cavity. — From a lady, æt. forty, and recently confined. 1860.

Dr. E. H. Clarke.

2415. A calculus, 1 in. in length, ovoid, compact, rough upon the surface, and almost perfectly white, but with a degree

of translucency, so that it resembles some kinds of confectionery. Found by Dr. J. C. White to consist wholly of cholesterine, but that it required a little more oxygen to produce crystallization.

From a lady, æt. fifty, who died of apoplexy, and had had symptoms of the passage of a gall-stone four or five years before, with an occasional bilious attack afterward. 1862. *Dr. Geo. W. Pierce, of Leominster.*

2416. Section of an ovoid calculus, $1\frac{1}{2}$ in. in length; highly crystalline, and must consist mainly of cholesterine. (See No. 2391.) 1847. *Dr. J. C. Warren.*

2417. A very unusual form of calculus. "Composed," according to Dr. White, "mostly of cholesterine, with some fatty acids, and a trace of inorganic matter. Colored between crystalline plates by inspissated bile." It is of a rounded form, and nearly half an inch in diameter. On section, it is somewhat radiated in structure; and the contrast between the brownish-red portion, and the white and brilliantly crystalline plates is very striking. The exterior is everywhere irregular, and curiously reticulated by the plates, which are quite prominent above the surface; the intervening and depressed portions being of a brown color, and the whole dull in appearance as compared with the brilliant interior. 1869. *Dr. J. S. Jones.*

2418. A compact, light-colored calculus, of a somewhat cylindrical form, smooth upon the surface, or coarsely granulated, and measuring $1\frac{7}{8}$ in. by 1 in. It filled the gall-bladder, and no other disease was found.

From a lady, æt. sixty-two, who had been dyspeptic for many years, with much uneasiness in the region of the gall-bladder, and occasional yellowness of the surface. When Dr. S. saw her, two years before death, there was a tumor in the region of the gall-bladder, with tenderness there; and he diagnosticated a disease of that organ. Became at last extremely emaciated, feeble, and sallow. 1864. *Dr. D. H. Storer.*

2419. A very dark, pear-shaped calculus, $1\frac{2}{3}$ in. in length, and 1 in. in diameter at its large extremity. Surface crumbling, and quite soft when recent; so that it has shrunk

considerably since it dried. With it were six others, small, hard, angular, and bronze-colored.

From a painter, æt. sixty-five years. Quite intemperate for very many years, and health poor. Died of scirrhus of the stomach. 1861.

Mr. S. G. Minassian, med. student.

2420. A calculus, of a regular, oval form; and, sawed longitudinally, it measures on the cut surface, $1\frac{1}{2}$ in. by $\frac{7}{8}$ in. Color, brownish. A marked nucleus, $\frac{7}{8}$ in. by $\frac{5}{8}$ in., seems to consist mainly of cholesterine. 1860.

Dr. G. C. Shattuck.

2421. A rounded, blackish, crumbling calculus, $1\frac{1}{2}$ in. in diameter; and with this were quite a number of small ones.

From a gentleman, æt. fifty-three years, who had disease of the liver. 1857.

Dr. C. Ellis.

2422. Four rounded, smooth, compact calculi, with very marked facettes; each about two-thirds as large as the last joint of the thumb.

From a gentleman, æt. fifty-four years, of sedentary habits, and who died of disease of the heart and kidneys. No hepatic symptoms reported. 1859.

Dr. C. Ellis.

2423. A rounded calculus, finely granulated upon the surface, rather more than an inch in diameter, and of a peculiar grayish color. 1859.

Dr. J. B. S. Jackson.

2424. A calculus, exceedingly rough upon the surface, and nearly $\frac{3}{4}$ in. in diameter. — From a man, æt. seventy years, who died from an accident. (Hospital, 80, 172.) 1859.

Dr. C. Ellis.

2425. Two calculi, of a flattened spherical form, and nearly $\frac{3}{4}$ in. in diameter. — From a man, æt. sixty, who died of cancer of the liver and lungs. (Hospital, 225, 26.) 1859.

Dr. C. Ellis.

2426. A very dark calculus, somewhat crumbling, and about as large as a robin's egg. — From a woman, æt. sixty-two, who died of disease of the liver. (Hospital, 157, 164.) 1849.

Dr. Waldo J. Burnett.

2427. Two yellowish calculi, about as large as the end of the finger. — From a woman, æt. seventy-three. Disease of the heart; and the liver healthy. 1850.

Dr. C. D. Homans.

2428. About a dessert-spoonful of whitish calculi, $\frac{1}{16}$ to $\frac{5}{16}$ in. in diameter. The gall-bladder (No. 2390) was diseased. 1850. *Dr. J. B. S. Jackson.*
2429. Thirty-one calculi, about 3 or 4 lines in diameter, white, very compact, and with very marked facets. 1850.
2430. Five, rounded calculi, about as large as the top of the finger, and many small ones; from Dr. S., who died of rupture of the heart, at the age of sixty-one years, and who had had during the last twenty years several severe attacks of pain in the region of the liver, with vomiting. 1867.
2431. Four calculi, about $\frac{2}{3}$ in. in diameter, and somewhat angular. — From a woman, æt. sixty, who died of a spinal affection. The gall-bladder was considerably enlarged, and filled with a perfectly clear, but rather thick fluid; one of the calculi being impacted at the exit of the duct. The common duct was large enough to easily admit the finger, but at the opening into the intestine would not admit a probe. 1867. *Dr. A. C. Webber, of Cambridgeport.*
2432. One hundred and twenty-eight calculi, $\frac{1}{8}$ to $\frac{1}{2}$ in. in diameter; angles and facets very marked; a very thin, black pellicle upon the surface, scaling off, and showing a pinkish color beneath. 1847. *Dr. J. C. Warren.*
2433. Two calculi, $\frac{1}{2}$ in. in diameter. One cut open, and shows the crystalline structure very finely; from the same patient as No. 2288. 1856. *Dr. C. Ellis.*
2434. Four calculi, from the same patient as No. 2394, of a rounded form, and granulated upon the surface. 1856. *Dr. J. B. S. Jackson.*
2435. One hundred and twenty-five dark, angular calculi, about $1\frac{1}{2}$ to 8 lines in diameter. — From the same patient as No. 1975. 1858. *Dr. R. M. Hodges.*
2436. Two hundred and two calculi, $\frac{1}{8}$ to $\frac{1}{2}$ in. in diameter; quite compact, and having a whitish, pearly lustre; facets quite marked. — From a lady, æt. fifty-three, who died of cancer of the liver. 1859. *Dr. W. E. Coale.*
2437. Ten calculi, nearly as large as pepper-corns, compact, quite granular, of an intensely black color, and apparently

formed from inspissated bile. — From a woman, æt. seventy-two, who died of disease of the pancreas; the pressure upon the hepatic duct from this last causing a great distention of the duct, generally. (Med. Jour. Vol. Lxi. p. 89.) 1859. *Dr. C. Ellis.*

2438. Granular calculi, of a dull black color, from the size of small mustard seed to nearly that of a pea, and in bulk about $\frac{3}{4}$ ij; probably inspissated bile. — From an intemperate man, æt. forty-six, who had granulated liver, with ascites. (Hospital, 254, 214.) 1865. *Dr. C. Ellis.*
2439. A collection of calculi, nearly $\frac{3}{4}$ iss in amount, of a reddish brown color, and very compact; generally about $\frac{1}{4}$ in. in diameter, and with strongly marked façettes; three are $\frac{2}{3}$ in., and more rounded. — From a very fleshy woman, æt. thirty-seven. 1859. *Dr. C. Ellis.*
2440. Sixty-eight calculi; 1 to 8 lines in diameter; quite compact; and originally of an ochre-yellow color; façettes more or less marked. — From a man, æt. thirty-one, who died of acute disease. No symptoms referable to the calculi in this nor in the last case. (Hospital, 236, 122.) 1861. *Dr. J. B. S. Jackson.*
2441. One hundred and sixty-seven calculi; six measuring 6 to 8 lines, and the rest from 1 to 3. — From a man, æt. about forty-five years. 1861. *Dr. D. W. Cheever.*
2442. Fourteen calculi; originally of a pale greenish, but now of a grayish color; with marked façettes, and averaging more than $\frac{1}{4}$ in. in diameter. — From a woman, æt. eighty. 1862. *Dr. C. Ellis.*
2443. Four calculi; one about the size of a pea, and the others as large or larger than the last joint of the finger. — From a woman, about sixty-five years of age, who died of cancer of the œsophagus. (Med. Jour. Vol. Lxv. p. 411.) 1862. *Dr. C. Ellis.*
2444. Two rounded, compact calculi, about 8 to 9 lines in diameter, and ten smaller ones; façettes very strongly marked. — From a lady, æt. forty-two, who died of chronic peritonitis. The gall-bladder was diseased. (Med. Jour. Vol. Lxv. p. 474.) 1862. *Dr. C. Ellis.*
2445. Fifty-four calculi; five about as large as the top of the

finger, of an irregular form, and almost without façettes ; the rest very much smaller and angular. — From an elderly woman. 1863.

Mr. George W. Masters, med. student.

2446. Eight large calculi, and mostly quite angular ; with several small ones. — From a woman, about fifty years of age, who died of phthisis. 1868. *Dr. C. B. Porter.*

2447. Four hundred and fifty-four smooth, compact, dark-brown calculi, from $\frac{1}{8}$ to nearly $\frac{1}{2}$ in. in diameter, and with well-marked façettes. — From a large, plethoric, and exceedingly gross woman, æt. fifty-five years. The gall-bladder was filled with the calculi, and contained nothing else excepting a white mucus. 1864.

Dr. G. J. Arnold, of Roxbury.

The number of cases in which biliary calculi have been found in females, rather than males, and particularly in fleshy subjects, has been quite remarkable. Their latency, also, has been very frequently observed here, as elsewhere.

2448. A very large collection of biliary calculi, pretty uniformly about 1 to 3 lines in diameter, and measuring altogether $\frac{3}{4}$ in. — From a female, æt. eighty-two, who had disease of the heart. The gall-bladder was 6 in. in length, the same in circumference, and contained much bile, besides the calculi, some of which last were just within the cystic duct. There had been nausea and vomiting the last two weeks, but no cardiac symptoms. 1869.

Dr. John Homans.

2449. Calculi, discharged from the umbilicus.

The patient was a woman, eighty years of age, and had had a burning sensation in the right side for six or seven years, with thick and very fetid urine ; but her general health was good. In Dec., 1868, a severe pain came on over the liver, and continued about three weeks. About two weeks afterward, a tumor of some size appeared over the gall-bladder, without pain ; and about the 1st of March it opened at the umbilicus, and discharged a calculus. From that time one or two calculi were discharged every two or three days, until the 23d of October, when, after

severe pain for three days, eight calculi were discharged at once; and none have been seen since, though the opening remains. The calculi were about the size of a common pea, and generally angular. The friends think that the number altogether may have been a hundred. Since the spring, when Dr. D. first saw her, her general condition has been comfortable, but failing. Stomach and bowels well, except for about two or three weeks in Sept., when her appetite failed, and the dej. were clay-colored. Burning sensation in right side relieved since the discharge of the calculi. As has been observed in similar cases, there was no discharge of bile with the calculi.— (See *Med. Jour.*, Jan. 6th, 1870.) 1870.

Dr. Geo. W. Doane, of Hyannis.

2450. Calculi from different subjects. Two are rounded, and about an inch in diameter. The rest are remarkably angular; one about $\frac{2}{3}$ in., and nine about $\frac{1}{4}$ in. in diameter. 1855. *Dr. W. D. Buck, of Manchester, N. H.*

SERIES XXXIV. — URINARY ORGANS.

I. KIDNEYS.

2451. Laceration across the organ, to the depth of $\frac{1}{8}$ to $\frac{1}{3}$ in. There was a large effusion of blood about it, but none in the bladder.

From a man who jumped from a railroad car, when it was in motion, and lived about forty-eight hours after the accident. (*Hospital*, 65, 96.) 1855. *Dr. C. Ellis.*

2452. Encysted disease of the kidney. Both organs were much enlarged, so as to be very conspicuous when the abdomen was first opened, and had a coarsely granular, colorless, and almost gelatiniform appearance. The organ has been cut open, and there is seen to be no trace of the cortical or tubular portions.

The cysts are generally one or two lines in diameter, but some would have held from one to four fluid ounces; the

fluid was generally clear, but in some of the larger cysts rather dark and turbid. Pelvis and infundibula rather small, and did not communicate with any of the cysts. Cysts were also found in the liver. The other kidney is in the Cabinet of the Society for Medical Improvement, — No. 589.

From a young man, nineteen years of age, who always had great thirst, and passed large quantities of urine, so that the disease of the kidneys, it was thought, might have been congenital. (See No. 2455.) During the last month the respiration was hurried and panting; and two weeks before his death, when he was first seen by his physician (Dr. John Ware), dyspnœa was the most prominent symptom. His countenance was then pale, and had sometimes a deathly aspect. There were also pains in the limbs, palpitation, cough, and at last cerebral symptoms. The urine was copious, clear, frothy, of a light-straw color, and moderately coagulable.

Dr. Ware attributed the peculiar respiration to the deterioration of the blood, and this last to the disturbed function of the kidneys. 1847. *Dr. J. C. Warren.*

2453. A second specimen, entire. Weight, when recent, 26 oz., and length, 12 in. It seemed to be a complete transformation; the cysts varying in size, and the thin fluid within them being more or less colored. The other organ, which was about as large, having been cut through, showed, besides the cysts, several large cavities which were nearly filled with a white substance, like soft putty, and much resembling the material occasionally found in the kidneys and other parts, as the result of "tubercular" disease. This substance was found by Dr. Bacon to contain pus globules, epithelium cells, much fatty matter, and, he thought, tubercular corpuscles. The ureter of this second kidney was obliterated near its origin. The urine, taken from the bladder after death, Dr. B. found to be turbid and faintly acid; density, 1.018. Proportion of urea very small; and as the urine had not become ammoniacal by standing, but little urea could have been destroyed by decomposition. Albumen in moderately large amount.

From a man who had suffered for some months, and as it

was thought, from an affection of the liver; the kidneys not having been suspected. (Amcr. Jour. of Med. Sc. April, 1854.) 1854. *Dr. E. Leigh, of Townsend.*

2454. A kidney, consisting of a collection of cysts, from $\frac{1}{4}$ in. to more than an inch in diameter. It is between 4 and 5 in. in length, very irregular in its outline, much shrunken; and, though not cut open, feels as if there might be a great deal of tough fibrous tissue with the cysts. The parietes of a number of the cysts in the recent state were quite stiff, like parchment, and some portions were completely ossified; of a bluish color externally, and contained, apparently, a thin serous fluid.

From a little girl, *æt.* twelve years, who had always been sickly, but without any urinary symptoms. — For the other kidney see No. 2476. (Med. Jour. Vol. LIV. p. 402.) 1856. *Dr. C. D. Homans.*

Cruveilhier has figured a very similar specimen (Anat. Path. liv. 6, pl. 4.), and regarded the disease as congenital.

2455. An encysted kidney, from a monstrosity (No. 846); preserved entire, and perfectly resembled, externally, the other, which was fully examined. This last weighed 6 oz., was deeply lobulated upon the surface, though no investing membrane could be detached, and contained throughout immense numbers of cysts, about one-half of a line in diameter. The ureter consisted of a whitish, condensed, impervious cord, not a line in diameter; and the pelvis was merely an enlargement of the same tissue. Internally no trace of the natural structure of the organ was visible to the naked eye. The following microscopical examination was made by Dr. Jeffries Wyman: — “There were only traces of the natural structure of the kidney. A few uriniferous tubes, with their epithelial linings, were seen, but no unequivocal Malpighian bodies, though there were some rounded masses covered by a capsule that might have been such. No connection was traced between the cysts and the uriniferous tubes. The contents of the cysts consisted of a transparent fluid, in which were floating numerous rounded cells, with a central nucleus similar to those

figured in Jones and Sieveking's Pathological Anatomy (Am. Ed. 1854), p. 555, fig. 254, a. In one of the cysts an octohedral crystal, probably of oxalate of lime, was found." The bladder was tolerably developed. 1862.

Dr. T. E. Francis, of Brookline.

For a remarkably similar case to the above, that also occurred in the practice of Dr. F., see No. 848, and for two other cases of encysted kidney in monstrosities see Nos. 820 and 788 in the Cabinet of the Society for Med. Improvement. As this condition of the organs may occur in a monstrosity, so may it in a subject otherwise well formed, as suggested in a previous case (No. 2452).

2456. A cyst, about half as large again as the fist, in the upper extremity of the kidney, and cut open. It is quite thin, and was filled with a thin fluid when recent. The organs seemed to be affected with Bright's disease, and two or three other small cysts were found upon the surface.

From a gentleman, æt. sixty-three. 1852.

Dr. J. B. S. Jackson.

2457. A specimen, similar to the last. Cyst entire, and $1\frac{1}{2}$ to 2 in. in diameter. Organ otherwise healthy, externally, excepting two or three other quite small cysts. 1857.

Dr. C. Ellis.

2458. Hydronephrosis. The kidney is of about the usual size, but no trace of renal substance is visible to the naked eye, though some slight irregularities are seen upon the inner surface. No cause ascertained for the dilatation; the ureter arising rather abruptly from the sac, and being rather small, though pervious throughout. The contained fluid resembled urine, and amounted to about $\frac{3}{4}$ ij. The other kidney was about three times the usual size. — From a healthy woman, æt. sixty-six, who died of strang. hernia. 1867.

Dr. J. C. Neilson, of Charlestown.

2459. Kidney and ureter, injected by Dr. Hodges, and dried. The kidney is very small, lobulated in correspondence with the infundibula, and extremely thin. The ureter is $2\frac{1}{2}$ in. in diameter at its upper portion, about as large as the finger toward the bladder, and much smaller midway. 1854.

Dr. J. B. S. Jackson.

2460. A similar specimen, and similarly prepared by Dr. H. The upper portion of the ureter is greatly dilated. 1859.

Dr. J. B. S. Jackson.

2461. A third specimen; entire, and preserved in spirit, so that it can be inflated through the ureter. 1861.

Dr. J. B. S. Jackson.

2462. A fourth specimen. The right kidney is immensely enlarged, and very thin; and though the mucous surface had formed a great quantity of pus, it is in every respect almost perfectly healthy in appearance.

The patient was a milkman, æt. thirty-three years, and had considered himself as well until ten weeks before his death, when he gave up his work. On the fourth day Dr. H. was called, and found him with typhoidal symptoms, pain in the right hypochondrium, and a hard tumor that filled the whole right side of the abdomen, and extended 3 in. beyond the median line, so that he was as large as a woman in the seventh month of pregnancy. The tumor was not tender, and the patient knew nothing of its existence. In two weeks there appeared to be pneumonia upon the right side, but during the fifth week he seemed fairly convalescent. Severe rigors then came on, with loss of strength; the tumor began to soften; and this went on until the beginning of the seventh week, when fluctuation was fairly established. It was then punctured, and two quarts of pus were drawn off; one pint being discharged daily for about two weeks, when it materially lessened. With this discharge there was neither pain nor soreness. In a few days he began to expectorate from ʒij. to iv. of pus daily; and, in three weeks after the opening of the tumor, he died.

An opening through the diaphragm allowed the pus to pass from the kidney into the right pleural cavity; the quantity of fluid in the chest and abdomen amounting altogether to six quarts. There was also extensive and recent peritonitis. The right lung was compressed, but the other organs were healthy. (*Med. Jour. Vol. LXII. p. 124.*)

Dr. Jacob Hayes, of Charlestown.

2463. Infundibula of the kidney dilated into cavities about 2 in.

in diameter. Two of these contain calculi; and the surface of one of these last is for the most part covered with a fibrinous substance that may have resulted from a former effusion of blood. In the pelvis, which is not dilated, is a third calculus, about $2\frac{1}{2}$ in. in length, $\frac{1}{2}$ in. in diameter, and sending branches into the infundibula. Each of these calculi adhered closely to the mucous surface, though to a small extent, and so caused a dilatation of the organ, by preventing the flow of the urine.

From a large, fleshy man, æt. fifty-eight years, who died of apoplexy. Intemperate in regard to eating and drinking. Disease of the kidneys had not been suspected; but, after his death, his wife reported that he had long been subject to pain in the loins, and some incontinence of urine.

A portion of one of the calculi was found by Dr. Bacon to be composed of the oxide of lime, phosphate of lime, phosphate of magnesia, and organic coloring matter; no uric acid nor urates. 1852. *Dr. J. B. S. Jackson.*

2464. Calculi in the bladder, kidneys, and ureters.

The patient was a man, aged thirty-seven years, who had had urinary symptoms for twelve years, and underwent lithotomy in 1862. In June, 1868, he entered the hospital (138, 48), greatly reduced, and died in a few days. Pain severe; and the urine, which was passed every ten or fifteen minutes, was loaded with pus. The right kidney was greatly enlarged, and the left sacculated. In the pelvis of each was a calculus, about 3 in. in length, and $\frac{3}{4}$ in. or more in diameter; also in the right ten, and in the left five calculi, about $\frac{1}{4}$ to $\frac{3}{4}$ in. in diameter. One small calculus was also found in the left ureter, and two in the right. The calculus in the bladder was oblong, flat, and smooth, $2\frac{1}{2}$ in. in length, and $1\frac{3}{4}$ in. in width. They are all of a yellowish color, and consist, according to Dr. White's analysis, of about equal parts of oxalate, and phosphate of lime, with a little carb. of lime.

In the preparation the organs have been dried, and the calculi are shown in situ. 1868.

Dr. R. M. Hodges.

2465. A kidney, ulcerated, but rather less extensively than No. 2467; and containing, within it, an irregular white calculus. 1847. *Dr. J. C. Warren.*

2466. The left kidney, reduced to a dense mass of fibrous and adipose tissue, so that its outlines are only faintly traceable. In the remains of its cavity is a compact, yellowish white calculus, an inch or more in length, and about $\frac{1}{3}$ in. in diameter; and, connected with this, undoubtedly, though the connection was not fully traced, is a fistula that opened upon the surface of the body.

From a woman, æt. forty-five years, who fell down stairs thirteen years before her death, and had pain in her side from that time. Three years before death the pain increased; an abscess formed between the last rib and the ilium, was opened, and a fistula ever afterward remained. There was much pain, and it was thought that dead bone was felt; but no bone was found either dead or denuded, and it was probably the calculus that was felt. (Hospital, 78, 242.) 1859. *Dr. C. Ellis.*

2467. Kidney very extensively destroyed by chronic ulceration. 1847. *Dr. J. C. Warren.*

2468. A kidney, from a gentleman who had suffered severely from urinary symptoms. It is thin, sacculated, and was filled, when recent, with a putty-like substance. 1856. *Dr. C. Ellis.*

Four Thibert's models. 1849. *Dr. J. Ware.*

2469. Kidney hypertrophied and granulated.

2470. A yellowish, mottled appearance, and degeneration throughout the organ.

2471. Another form of this granular disease of the kidney.

2472. Atrophy, with structural disease.

2473. Bright's disease. There was an albuminous-looking deposit throughout the cortical substance, that is still well marked.

From a woman, æt. forty years, who had had cardiac symptoms for sixteen months, and dropsy for several months. Urine sometimes very strongly coagulable, and sometimes not at all so. The heart was much diseased;

and there was a bright yellow mass in the spleen, of which there is a colored drawing in the Med. Soc.'s Cabinet. 1852. *Dr. J. B. S. Jackson.*

2474. One-half of one of the kidneys, both of which were large and white, and resembled perfectly the fourth figure in Dr. Bright's Hospital Reports.

From an Irish girl, æt. twenty-three years, who died at the "Channing Hospital," Jan. 27th, 1861. She had had phthisis for two years; progress slow till March 6th, when she had scarlatina, and then it was much more rapid. Very anæmic and anasarcaous toward the last; and, after death, two quarts of serum were found in the peritoneal cavity. 1861. *Dr. J. Nelson Borland.*

2475. A remarkably irregular appearance over the whole external surface of the kidney; as if cicatrized. From a man, æt. fifty-six, who had died of cancer of the tongue. 1855.

Dr. J. B. S. Jackson.

2476. Atrophy of the left kidney. In the recent state, it was between two and three inches in length, of a uniform, yellowish-white color, and the normal structure was hardly if all perceptible. (See No. 2454.) 1856.

Dr. C. D. Homans.

2477. A small kidney, reduced for the most part to a thin layer of renal substance, and replaced by a great increase of the fat that is usually found in the hilus. The pelvis is very much encroached upon, but communicates with the ureter. The tissue of the organ is diseased; and the tubuli of the other organ were filled with fat globules.—From a man, æt. forty-nine years, who died of apoplexy. (Hospital, 237, 202.) 1863. *Dr. C. Ellis.*

2478. A kidney, not more than $1\frac{1}{2}$ in. in length, and consisting of but one cone, with a portion of another, and the corresponding cortical substance. These, however, appeared healthy; and there was nothing to show that the rest of the organ had been destroyed by disease. The pelvis was quite large; and the other kidney weighed eight ounces. From a young man, æt. nineteen, who died of Bright's disease. (Hospital, 242, 12.) 1864. *Dr. C. Ellis.*

2479. Very great atrophy of the kidneys. One of them measured $1\frac{3}{4}$ in. by $1\frac{5}{8}$, and weighs 310 grains; the other $1\frac{1}{2}$ in.

by $\frac{1}{4}$ in., and weighs 75 grains; a portion of the ureter being attached to each. The smallest was granular externally, and the cut surface is seen to have a diseased look.

From a little girl, æt. nine years, who complained of fatigue, palpitation, and distress in the region of the heart in the summer of 1867, and until the month of September, when she had an attack of vomiting, with nausea ever afterward in the morning. Pupil of right eye dilated from that time, and contracted imperfectly. Convulsions during the latter part of October and in December. Ascites began early in January, and the abdomen became enormously distended. Urine highly albuminous, and twice it was bloody. Impulse of heart strong, with marked dullness. Symptoms of croup the last two days. The left ventricle of the heart was found immensely hypertrophied and dilated, but without valvular disease. 1868.

Dr. C. Ellis.

2480. One-half of a cancerous kidney; the other half being in the Cabinet of the Soc. for Med. Improvement (No. 593). In the recent state it weighed 18 oz., and was nearly 7 in. in length. The upper portion contained well-marked encephaloid, effused blood, and one or two cysts. In the lower portion, which was completely disorganized and quite firm, there was a coarse areolar tissue, a semi-translucent deposit, and some of the opaque, tuberculoid substance that is so often found in degenerated cancer. There were diseased masses in the brain and lungs; but the other kidney was healthy.

From a gentleman, æt. forty-nine years, who had cerebral symptoms, but none referable to the kidneys. 1847.

Dr. J. C. Warren.

Parasites from the kidney. (See No. 3082.)

2481. Ureters dilated; inflated and dried. From a case of cancer of the womb (No. 2787); in which disease they are often found thus affected. 1852.

Dr. J. B. S. Jackson.

II. BLADDER.

Calculi in the ureters. (See No. 2464.)

2482. The bladder of a child that was transfixed by a hayhook. (See No. 3116.) 1857.

Dr. J. P. Maynard, of Dedham.

2483. Thibert's model. Inflammation at the neck of the bladder, which, by the swelling that has taken place, prevented the proper entrance of an instrument. Three bougies have entered the cavity by false passages; and two have passed quite through the parietes of the organ, and are seen behind it. A dilatation of the lacunæ in the prostatic portion of the urethra also helped much to the formation of the false passages. 1847. *Dr. G. Hayward.*

2484. A large part of the mucous membrane entirely destroyed, though there is nowhere any deep ulceration; surface quite rough, and appeared flocculent under water. Membrane otherwise healthy, and with well-defined limits. Prostate enlarged; with a marked transverse ridge across the neck of the bladder. The patient was about eighty years of age, and had frequent and painful micturition for six or seven years; the urine being turbid, very slow to start, passed every half hour in the night toward the last, and the call to pass it being often very sudden and urgent, so that he died worn out by the disease. 1867.

Dr. H. J. Bigelow.

2485. Immense distention of the bladder.

From a woman, æt. forty-five years, and of robust health. About five years before her death she was examined for a tumor of a few months' duration, and that was supposed to be an encysted ovary. For three or four years she had occasionally had slight dysuria, but no further symptoms until two weeks before death, when, after a retention for twenty-four or thirty-six hours, the catheter was passed with much difficulty, and about half a pint of quite healthy urine was drawn off. From that time her distress was very great and constant. The urine was passed only in the lithotomy position, and with great pain and straining; for the last three days it was strongly ammoniacal, but it never contained mucus, pus, nor blood.

The bladder, which was the "tumor" felt during life, rose to about two inches above the umbilicus, pushing the peritoneum before it, and contained more than four quarts of dark-brown and intensely ammoniacal urine. The parietes were dense, but not thickened, and the inner surface a little roughened, but without any trace of inflam-

matory product; a very striking appearance being a pretty uniform brownish and greenish discoloration of the mucous surface, as occasionally seen in the intestines. The muscular fasciculi were not visibly enlarged; and the ureters were not dilated. In the substance of the fundus and body of the uterus and on the left side, is a defined, fibrous tumor, about four or five inches in diameter; and in the left side of the neck a second, of an oval form, about a third as large; the uterus being apparently pushed towards the right side. The smallest of these tumors, which is preserved with the bladder, is quite dense, and possibly may have occasioned the distention of the bladder. (*Med. Jour.* Vol. LXIV. p. 251). 1861.

Dr. C. H. Walker, of Chelsea.

2486. Mould in plaster of the interior of the bladder, and of two hernial protrusions of the mucous membrane. The largest diameter of one of these last is about $3\frac{1}{2}$ inches, and the orifice or neck about one inch. The other is very much smaller. 1859.

Dr. J. B. S. Jackson.

2487. Sacculated bladder. — From a gentleman, æt. sixty-three years, who, for the last twenty years, had had frequent and difficult micturition, with pain and uneasiness in the lower part of the abdomen. Symptoms much increased toward the last, but he finally died of typhoid fever.

The organ filled the whole pelvis, extended as high as the umbilicus, and contained about $2\frac{1}{2}$ quarts of urine. The proper bladder was very much enlarged, thickened, and the muscular fibres strongly developed. At the fundus and toward the left side was an orifice about $1\frac{1}{2}$ in. in diameter, and leading to a sac that was considerably larger than the bladder itself. This sac, which contained the greater part of the urine, was quite thick, and the muscular coat well marked, showing that it was not a mere hernia of the mucuous membrane. The prostate gland was much enlarged, chiefly in the centre, with a band from side to side, as usually seen. The ureters and pelvis were dilated, but the kidneys were healthy. (*Med. Jour.* Vol. LVI. p. 343.) 1857.

Dr. C. D. Homans.

2488. A second specimen. — The organ is about as large as the foetal head, the walls half an inch thick, and the muscular

coat quite developed. Mucous surface nowhere smooth, and in many parts covered with shreds, and rough elevations from the thickening of the submucous coat. The sac is, perhaps, half as large again as the bladder itself; and the opening between the two is from two to three inches in diameter. The left ureter opens into the sac, half an inch from the bladder, and is considerably dilated, as is also the pelvis of the kidney, which contains a dark, irregular calculus.

From a hostler, æt. thirty-five years, who had had dysuria for a month or more before he applied for medical advice. Pain in the region of the kidneys was severe, with tenderness over the bladder, and occasional retching and vomiting; and he died not long afterward of peritonitis. 1867.

Dr. R. M. Hodges.

Calculus in the bladder in situ. (See No. 2464.)

2489. A tumor projecting into the cavity, and from the fundus the bladder, is perfectly defined, of a circular form, about 4 in. in diameter and 2 in. in elevation; the mucous membrane stopping abruptly around the base. It had a dead-white color, a fibrinous consistence, and considerable friability, so that it had been broken into in some places by handling. The external surface was rough, but the general form rounded. In structure it was uniform, nowhere at all vascular, and showed nowhere any of the usual appearances of cancer. Under the microscope, Dr. Ellis found no cancer cells, nor, indeed, any definite appearances. Not very far from the tumor was a white deposit in or beneath the mucous membrane, and about a line in diameter; and otherwise the bladder appeared quite healthy, being neither fasciculated nor remarkable as to its size. Upon the peritoneal surface, corresponding to the tumor, there was no appearance of morbid deposit.

The patient was a shoemaker, of good general health, and fifty years of age. When first seen by Dr. C., about two years before his death, he had had frequent and irresistible calls to urinate for about eight years, and until the last two years this had been the only symptom; but, afterward he had had considerable pain during micturition, with constant uneasiness, and sometimes a smarting, cut-

ting pain along the urethra and in the glans. The urine, then, and so long as he lived, averaged about two quarts daily, was often bloody, and sometimes offensive. The blood was often in clots, and during the last few months he lost a great deal, with much straining and distress; a pound or more being sometimes passed daily and for several days. The urine always contained blood, albumen, pus, large quantities of mucus and of epithelial scales, casts of tubes, and sometimes oxalate of lime. The passage of a sound caused very acute pain along the urethra, and especially at the prostate. When first seen there was some constitutional affection; and for about a year before his death there was a decided failure of his health, though he worked at his trade until the last seven months. (Med. Jour. Vol. LX. p. 203.) 1859.

Dr. Benj. Cox, Jr., Salem.

2490. Cancer of the bladder.

In the recent state the organ was contracted, and a well-marked encephaloid growth arose from its inner surface, posteriorly, in the form of soft, luxuriant, polypiform vegetations; the disease was between 2 and 3 in. in extent, pretty well defined, and rose above the surrounding surface about one-half or two-thirds of an inch. Otherwise the bladder was healthy, excepting a discoloration of the inner surface, and a slight deposit, apparently from the urine. The ureters and pelves were dilated, and there was some acute inflammation of one of the kidneys; but there was no cancer in any other part of the body. In the head nothing was found but a little serous effusion.

From a woman, æt. sixty-two years, who entered the hospital, Dec. 23d, 1856 (210, 32), and reported, as follows: Two and a half years previously she had ridden two hundred miles in the cars, in the course of nine hours, and within a few hours, if not immediately on her arrival, had hæmaturia; this symptom continued for three weeks. Ardor urinæ was quite severe at first, but had not been present for the last three months. There had been also soreness, and a sense of weakness of late about the hypogastrium; but very little if any marked pain ever in the bladder. There had been slight pain in the region of the

kidneys for the last few days; also, incontinence of urine, complete during the night and nearly so in the day, for the last two months. The urine had been pale and offensive for the last three months. The patient gave up work when the disease commenced, but was not confined to the house. She retained considerable flesh and strength, but was pale; and, her complexion being naturally dark, she had the hue that is so often observed in cases of cancer.

On examination, the bladder was found to bulge into the vagina, and to have a thickened, fleshy, but not firm feel, as from a mass of soft vegetations, in its cavity. The urine was sufficient in quantity, but was very pale, exceedingly offensive, contained a great deal of pus, and had the density only of 1.011; a catheter that was passed became at once very deeply discolored.

Jan. 6th. — The patient became dull; and from the following day until the 10th, when she died, she was almost entirely unconscious, — breathing about eight times in a minute, but without convulsion of any sign of distress.

Some of the interesting points in this case are, — the long journey, as an exciting cause of the disease, — the occurrence of hemorrhage as the first symptom, as it sometimes is in phthisis, — the very mild character of the symptoms, considering the usual irritability of the bladder, — the feel of the bladder, — and the mode of death, as in Bright's disease, and in connection with which the low specific gravity of the urine is to be remembered. (Med. Jour. Vol. LV. p. 526.) 1857.

The "peculiar hue of cancer" is often wanting in this disease, as it is often enough met with in other cases; and it may not unfrequently be explained as the effect of palor upon a naturally dark complexion.

Dr. J. B. S. Jackson.

2491. The posterior portion of the bladder, showing an opening through into the vagina or uterus, and large enough to admit the last joint of the fore-finger. — From a case of cancer of the womb. 1855. *Dr. J. B. S. Jackson.*

2492. Villous cancer. — In the recent state, the bladder was 4 in. in diameter; its walls being half an inch in thickness, and the fibres of the muscular coat much hypertrophied. Upon

many parts of the inner surface were small, dirty-white patches of lymph, some of them roughened by a deposit of salts from the urine. Rising from one-fourth to one-half of an inch above the surface, just within and a little to the right of the meatus, was a soft, highly vascular villous growth, 3 in. long, and from an inch and a half to 2 in. wide. The vessels were parallel to the villi, which were very distinct, and in water presented very much the same appearance as the villosities of the chorion. The disease was confined to the surface, and resembled soft encephaloid.

The microscopic characters were those of villous cancer; namely, villi and large cells of various shapes and sizes, — some of them containing large nuclei and nucleoli. The left kidney and ureter were inflamed, and both ureters were dilated.

From a healthy farmer, æt. forty-five years. For ten years he had complained of his back, and for four years of an occasional burning and throbbing in the urethra after micturition. During the last five months he had passed blood with his urine. Occasionally, during micturition, there was such a pressure downward as to cause involuntary discharges from the bowels; there being a difficulty both of passing, and of retaining the urine. Between two and three months before death, he passed from the urethra white bodies, of the size of a common bean. When first seen, seven weeks before his death, he complained chiefly of his back, and the burning in the urethra, but his general appearance was healthy. Ten days afterward Dr. Bacon found the urine turbid, colored by blood, alkaline from carbonate of ammonia; density, 1.013. There was a large deposit, composed chiefly of whitish ropy mucus, with blood corpuscles and phosphates, and a few pus globules, granular exudation corpuscles, and epithelial cells. The mucus was probably in part a result of the decomposition of pus by the alkaline urine. Considerable albumen was found, which was due to the blood and pus present. Failure gradual, with vomiting and irritability of the bowels the last week. (Med. Jour. Vol. LV. p. 311.) 1857.

Dr. C. Ellis.

2493. Extensive cancerous disease of the bladder, and of a peculiar form. There projects from the lower half of the posterior wall a fungous, lobulated growth, about the size of an English walnut. In the recent state the cavity of the organ was not more than 3 in. in diameter, and empty. The verumontanum, with the prostate gland and neighboring tissues are also affected. The rectum was involved; the pelvis was mostly filled with a morbid growth; the lumbar glands were most extensively diseased, and there was disease of one of the lower ribs. The growths everywhere were of considerable consistence; of a dull or yellowish white color; here and there vascular or ecchymosed, and contained much milky fluid.

On microscopic examination, there were seen many granular nuclei of the size of, or smaller than, blood globules. Some contained large nucleoli, but most were without them. A few nuclei, with large, well-marked nucleoli, were here and there seen; but, with these exceptions, there was nothing which could by any one be considered as characteristic of cancer.

From a literary gentleman, sixty-six years of age. In May, 1856, he asked advice for difficulty of defecation; and, on examination, a tumor in the region of the prostate was found pressing in upon the rectum. A tumor was also felt, extending 2 in. above the pubes. For the first two months there was much pain, but afterward none at all. Micturition throughout very frequent. Became extremely emaciated, and died Dec. 29th; having had no dej. for two weeks, and having passed no urine for three days. (Med. Jour. Vol. LV. p. 512.) 1857. *Dr. C. Ellis.*

III. FOREIGN BODIES FROM THE BLADDER.

2494. A smooth stone, $\frac{3}{4}$ in. by about $\frac{1}{3}$ in., removed from the bladder, by the forceps, and found by Dr. Bacon to be a "rolled pebble of argillaceous rock;" four or five others having been removed within a few weeks.

From a respectable married woman, about thirty-five years of age, and whose propensities, otherwise, were in no way remarkable, so far as was known. She had been practising

the deception for one or two years ; with very severe pain, and a constant desire to urinate ; much blood and mucopurulent matter being mixed with the urine, which was very offensive. She indignantly denied the charge of having introduced the stones, as usual ; but at last acknowledged the fact, and assigned as a reason, an intention of suicide. (Med. Jour. Vol. LX. p. 78.) 1859.

2495. A lead pencil, removed from the bladder of an unmarried woman, thirty years of age. The two halves were separated in the bladder, and separately removed. 1869.

Dr. J. S. Jones.

2496. A stiletto, removed from the bladder by a lithontriptic instrument. It is 3 in. in length, made of bone, and such as is used by seamstresses.

The patient was an unmarried woman, about thirty-eight years of age, and professed to have used it to relieve herself of dysuria. It was in the bladder about twelve hours, and caused no great irritation. 1863.

Dr. R. M. Hodges.

2497. Two pieces of gutta-percha bougies, removed from the urethra by perineal section.

The patient was forty-five years of age, and had been in the habit of passing bougies of his own manufacture. One of the pieces had been broken off four months, and the other two days, before he entered the hospital (118, 203). On the eleventh day no urine escaped from the wound ; and in two weeks he was discharged. One of the pieces is coated with phosphatic deposits. The bougie, from which a piece had been recently broken, is shown with this last. 1865.

Dr. R. M. Hodges.

2498. A portion of gum-elastic catheter, 9 in. in length, removed from the bladder. — The patient was a laborer, æt. forty, who was injured by a bank of earth falling upon him, and for sixteen days was obliged to have the catheter used daily. The instrument was at last broken off, but nothing was done about it, as he was told that it would melt and come away. The urine was passed every few minutes, and in very small quantities ; and when he entered the hospital (131, 60) there was scalding along the

urethra, pain and tenderness over the hypogastrium, a slight mucous sediment in the urine, and afterward a strong ammoniacal odor. About six weeks after the original injury, the bladder was injected with warm water, and the catheter removed by means of a lithotrite, there being a considerable deposit of the salts of the urine upon it. 1868.

Dr. H. G. Clark.

IV. CALCULI.

One hundred and twenty-three of the following specimens were sent to Harvard University, from England, in the year 1800, by Dr. John Nichols; and, as the Medical School then existed, and they were undoubtedly intended for its use, they will be entered as a donation to the Museum. Not many years ago they were removed from Cambridge to the Medical College. In 1856 they were examined by Dr. James C. White; and the results were given in a tabular form, with some remarks, in the *Med. Jour.* (Vol. LIV. p. 459). Since then one of the specimens has unfortunately been lost.

Forty-eight other specimens were already in the Museum when it was presented to the College by Dr. J. C. Warren; and these were analyzed by Dr. White, in 1858, and the results published in the *Med. Jour.* (Vol. LIX. p. 329), in tabular form, and with extended remarks upon the formation of calculi. In both cases Dr. W. used the microscope, as being much more exact than the test tube. In the Nichols collection he says: "In each case the entire surface of a section through the centre has been carefully and equally scraped; by which means we not only obtain all the constituent parts, but their relative proportions also." In the Warren collection he says: "In every instance the nucleus and each layer have been separately examined," etc. In his second article Dr. White gives the following tables, — the four first in reference to Dr. Warren's collection, and the two last to show the result of the analysis of both collections: —

TABLE I.

Nucleus consisting of uric acid	1
“ “ and urate of ammonia	16
“ “ “ and urate of lime	9
“ “ mixed urates, and oxalate of lime	10
“ “ “ “ and phosphate of lime	5
“ oxalate of lime	3
“ phosphate of lime, and triple phosphate of ammonia and magnesia	1
“ a concretion of organic material	1
“ a piece of coke	1
“ a bullet	1
Total	48

TABLE II.

Calculi composed of uric acid	1
“ “ and urates	11
“ “ “ and oxalate of lime	11
“ “ “ “ and phosphates	6
“ “ “ “ and phosphates and carbonate of lime	4
“ “ urates and phosphates	1
“ urates and oxalate of lime	1
“ “ and phosphates	5
“ “ “ and carbon. of lime	1
“ “ “	2
“ oxalate of lime	3
“ phosphates	1
“ “ and carbonate of lime	1
Total	48

TABLE III.

Calculi containing uric acid	35
“ urate of ammonia	39
“ “ lime	20
“ “ soda	5
“ “ magnesia	2
“ oxalate of lime	30
“ phosphate of lime	20
“ carbonate of lime	7
“ triple phosphate of ammonia and magnesia	13

TABLE IV.

Layers of uric acid and urates followed by oxalate of lime	8 times
“ following “	5 “
“ “ phosphates	3 “
Oxalate of lime followed by “	11 “

TABLE V.

Calculi composed of uric acid	11
“ “ and urates	47
“ “ “ and oxalate of lime	30
“ “ “ “ and phos- phates	18
“ “ “ “ and phos- phates and carb. of lime	4
“ “ “ and phosphates	13
“ “ and oxalate of lime	7
“ urates and “	1
“ “ “ and phosphates	10
“ “ “ “ and carbonate of lime	1
“ “ phosphates	8
“ oxalate of lime	5
“ “ and phosphates	3
“ phosphates	1
“ “ and carbonate of lime	12
Total	171

TABLE VI.

Calculi containing uric acid	132
“ urate of ammonia	114
“ “ lime	32
“ “ soda	32
“ “ magnesia	15
“ “ potash	9
“ oxalate of lime	79
“ phosphate of lime	58
“ carbonate of lime	20
“ triple phosphate of ammonia and magnesia	34

2499. Pure uric acid; numerous millet-seed calculi. 1847.

Dr. J. C. Warren.

2500. Uric acid calculi, about the size of mustard-seed; passed from the urethra, with many others at different times, and by a gentleman, who was otherwise sufficiently well. 1869.

Dr. H. G. Clark.

The following ten specimens were given, in 1800, by
Dr. John Nichols.

2501. Uric acid. 6''' by 7''' (''' lines, and '' inches). Irregular concretion.
2502. Uric acid. 7''' by 4'''. External surface dark red.
2503. Uric acid. 8''' by 6'''. Compressed, oval. External surface granular.
2504. Uric acid. 8''' by 5'''. Shape, peculiar. Originally oval, but changed subsequently by formation of a broad groove, which is deeper at one end. Centre made up by agglomeration of particles.
- Dr. White remarks upon the eroded appearance in several of the specimens from the two collections that he examined, and that is, "without doubt, owing to chemical action, induced by injections within the bladder."
2505. Uric acid. 7''' by 6'''. Pale, globular, and resembling dried putty, externally.
2506. Irregularly loose compact mass of uric acid, and formed about an oblong, darker nucleus of the same. No regular stratification. 1'' 3''' by 11'''.
2507. Uric acid. 1'' 3''' by 1''. Smooth; oval; light-fawn color; concentric layers.
2508. Uric acid wholly. 1'' 9''' by 1'' 2'''. Oblong. Concentric;—much cracked, and probably after formation of external layers. Exterior, pale brown; worn, granular appearance. Original length above given.
2509. Uric acid. 1'' 2''' by 1''. Two halves preserved. Smooth; finely laminated; globular form, with two cotyloid cavities, caused probably by the presence of other calculi in the bladder, and giving the surface a fan-shaped form.
2510. Uric acid. 2'' by 1'' 5'''. Long; oval. Nucleus dark pink; exterior layers pale fawn color.
2511. A smooth, compact calculus, $1\frac{2}{3}$ in. in length, $1\frac{1}{8}$ in. in diameter, and having the peculiar form of two blunt cones, united by their base. On long. section, it has the characteristic reddish color and concentric arrangement throughout; and, on examination by Dr. White, is found to consist of uric acid, with a little urate of ammonia.

Removed from the bladder after death. The patient was an old man, seventy-eight years of age, who had been under the care of Dr. J. Homans, Sen., and who had great dysuria for a short time, six years before his death. After this subsided he had as good health as most persons of his age, until the last eight months, when the disease returned, so that he was confined to his house; the urine being small in amount, and the character unnatural. The pain, however, was only moderate in amount; and he died at last from a slight cause. The bladder was thickened and contracted about the calculus. 1867.

Dr. J. Homans, Jr.

The next eleven specimens were given, in 1847, by

Dr. J. C. Warren.

2512. A finely marked oval calculus. $2'' 2\frac{1}{2}'''$ by $1'' 8\frac{1}{2}'''$. Nucleus, yellow; uric ac. mostly; with the urates of ammonia and lime. Then a well-defined layer of the same, but different in color; and next a deposit of ur. ac., with very little ur. of ammonia. The outer portion consists of pure uric acid; and the surface presents a very unusual appearance, as if it had been studded with numerous tubercles, and there had been a deposit about these in concentric layers.
2513. Uric acid, and urate of ammonia. $1'' 2'''$ by $1'' 1'''$. Of a spherical form; and the layers are regularly concentric. Both halves are shown.
2514. Specimen identical in every respect with the two last.
2515. Uric acid and urate of ammonia. $1'' 7'''$ by $1'' 1'''$. Oval; nucleus irregular.
2516. Uric acid, and urate of ammonia; less of the urate in outer layers. Original size, $1'' 4'''$ by $1'' 2'''$. Irregularly oval. External surface polished.
2517. Mixed uric acid, and slight amount of urate of ammonia. $2'' 8'''$ by $2'' 1'''$. Ovoid; exterior, irregular; interior about nucleus corroded and loosely deposited.
2518. Small, irregularly shaped stone. Ur. ac., urates of ammonia and lime. $8'''$ by $10'''$.
2519. Compressed, spheroidal concretion of ur. ac., with a little ur. of ammonia and lime. $1'' 5'''$ by $10'''$.

2520. Large, oval, and regular calculus. Ur. ac., with slight mixtures of urates of ammonia and lime. 2" 8''' by 2" 1'''.
2521. Very large, irregularly ovoid calculus. Urates of ammonia and lime, and ur. ac. Human? Structure not compact; outer surface somewhat tuberculated. Length, 3" 1''; and greatest width, 2" 4'''.
2522. Large, oblong stone, showing a constriction at one extremity, as if worn away. Uric acid, with a little urate of lime. Centre cracked and shrunken. 3" 1'' by 1" 2'''.

The next thirty-five specimens were given, in 1800, by
Dr. J. Nichols.

2523. Uric acid, with a little urate of ammonia. 1" 10''' by 1" 5'''. Smooth, compressed, oval, pale.
2524. Uric acid and urate of ammonia. 1" 7''' by 1" 5'''. Broad; oval. Layers diminish in depth of color from within outward. Exterior shows appearances of probable erosion while within the bladder.
2525. Uric acid and urate of ammonia. 1" 4''' by 1" 1'''. Shallow cavity in one side, caused by attrition. Nucleus of dark shade; slightly pink. Exterior, pale.
2526. Uric acid and urate of ammonia. 2" 4''' by 1" 6'''. Flattened; oblong; pale and coarsely granular exteriorly.
2527. Uric acid and ur. of ammonia. 1" 11''' by 1" 7'''. Flattened; ovoid. Centre pale yellow, resembling agate in structure. Exterior grayish, and pinkish-white, and rough as from loss of matter.
2528. Uric acid and ur. of ammonia. 1" 10''' by 1" 3'''. Shattered half of an oblong oval stone. Structure about nucleus friable. Exterior smoothly granular.
2529. Uric acid and urate of ammonia. 2" 2''' by 1" 10'''. Broad, oval stone. Regular, concentric layers. Yellowish-fawn, or reddish. Exterior worn in line of longest axis, and smoothly granular.
2530. Uric acid and urate of ammonia. 2" 2''' by 1" 6'''. Very fine specimen. Oblong, oval. Reddish-fawn color. Formed

by deposition of laminæ about two large nuclei. Exterior smoothly tubercular.

2531. Uric acid and urate of ammonia. 2" 2''' by 1" 8'''. Part of thick cortex of large stone. Structure, porous. Pale brown. Exterior tuberculated and grooved.

In the next eleven specimens the urate of ammonia is in larger proportion than in the last nine.

2532. Ur. ac. and urate of ammonia, Length, 2" 4'''. Irregular clump of a large, dark, reddish-brown stone. Fractured surface shows finely the fan-like radiation of its coarsely crystalline structure. Exterior tuberculated, and indented.

2533. Uric acid and urate of ammonia. 1" 7''' by 1" 3'''. Pale; pinkish-white; friable; mortar-like; oval.

2534. Ur. ac. and ur. of ammonia. 1" 3''' by 1". Compressed; ovoid. Centre of a reddish-ochre color. Outer portion, yellowish-fawn. Exterior smoothly granular. Both halves preserved.

2535. Uric acid and ur. of ammonia. 1" 7''' by 1" 2'''. Irregular, ovoid. Porous. Exterior tuberculated.

2536. Uric acid and urate of ammonia. 1" 3''' by 8'''. Compressed, irregular, spheroid, with one surface deeply concave. Nucleus very porous. Cortex pale fawn, and smooth.

2537. Ur. ac. and ur. of ammonia. 10'''. Compressed spheroid. Resembles much a nutmeg in color and structure. Exterior polished.

2538. Ur. ac. and ur. of ammonia. 8''' by 9'''. Compressed spheroid. Nucleus, grayish-white. Outer portion, yellowish-fawn color; and covered with flattened tubercles.

2539. Ur. ac. and ur. of ammonia. 9''' by 7'''. Oblong, ovoid, and much resembling the last specimen.

2540. Ur. ac. and ur. of ammonia. 1" by 10'''. Compressed, oval. Pale fawn color. Between the centre and cortex is seen a lamina presenting the nacreous lustre peculiar to this form of calculus.

2541. Ur. ac. and ur. of ammonia. 10''' by 9'''. Spherical. Exterior friable, and mottled with faint pink.

2542. Twenty-three calculi, or fragments of calculi. Largest surface, 10^{'''}. Ur. ac. and ur. of ammonia. Spherical in shape, and worn by attrition on their surfaces. Outer portion loosely attached to a firmer nucleus, so that the broken-masses leave this prominent. Color, grayish-pink.
2543. Fine, compressed, oval calculus of ur. ac., and urates of ammonia and soda. On the flattened surfaces two grooves are seen tending toward the hour-glass constriction. 2^{''} by 1^{''} 7^{'''}.
2544. Portion of a long stone, consisting of ur. ac. and urate of ammonia and soda. About the centre a reddish-brown passes into an orange-colored deposit. The exterior is smoothly tuberculated, and the interior is porous in parts. 2^{''} 2^{'''} by 1^{''} 9^{'''}.
2545. Oblong, oval calculus of loose structure. Ur. ac., ur. of ammonia, and soda. Exterior porous, and coarsely granular. 2^{''} by 1^{''} 7^{'''}.
2546. Loose, porous, pale fawn-colored calculus of ur. ac., and urates of ammonia and soda. Exterior tuberculated. 1^{''} 2^{'''} by 1^{''} 4^{'''}.
2547. Oblong, oval, with shallow concavity on external surface. Ur. ac., urates of ammonia, and soda. Centre, pale yellow. Cortex of a deep fawn color. Exterior somewhat tuberculated; the projections serving as centres of concentric layers. 1^{''} 6^{'''} by 1^{''} 1^{'''}.
2548. Irregularly ovoid. Ur. ac., and urates of ammonia and soda. Exterior smoothly granulated. 1^{''} 2^{'''} by 1^{''}.
2549. Portions of a very irregularly shaped renal calculus. Ur. ac., urates of ammonia and soda. Layers very loosely arranged. Exterior yellowish-pink, and has a sanded appearance. Light and porous. Several spinous processes. Length, 1^{''} 2^{'''}.
2550. Fragments of a calculus, resembling much No. 2542. Ur. of ammonia and soda, and ur. ac.
2551. Compressed, oval calculus. Ur. ac., urates of ammonia, and soda. Exterior granulated; and has a peculiar, purplish-brown color. 1^{''} 2^{'''} by 10^{'''}.
2552. Oblong oval stone. Nucleus wanting. Structure light

and porous. Ur. ac., with urates of ammonia and potash. Exterior, pale fawn color, and tuberculated. 1" 10''' by 1" 5'''.

2553. Ur. ac., urates of ammonia and potash. 7''' by 6''' . Irregular shape. Exterior granulated.

2554. Uric acid, and urates of ammonia and potash; 2" 1''' by 1" 6''' . Oblong oval. Centre very porous. Exterior laminae pale and firmer. Exterior, grayish-white and scaly.

2555. Ovoid. Porous and light-colored for the most part. Nucleus oval, of a purplish-brown color, and compact. Exterior covered with flat tubercles; and marked by two symmetrical, longitudinal depressions upon each surface, with a blunt ridge between them. Both halves preserved.

2556. Ur. ac. and ur. of soda. 8''' by 7''' . Spheroidal. Nucleus bright red, interspersed with yellow layers. Exterior layers strongly radiated. External surface granulated, and covered in spots with warty excrescences.

2557. Uric acid, and urates of soda and potash; 1" 6''' by 1" 2''' . Oval. Centre reddish. External surface has a very corroded appearance.

2558. A collection of small calculi from the kidney of a little girl (No. 1576), and would about fill a drachm measure. Form rounded, with some small granulations on surface; from a very minute size to that of a duck shot, or larger; ash-colored. On attempting to rub one down, it is found to be mainly quite hard, with a crumbling, concentric structure externally. Ex'd by Dr. White: "resemble in shape globular masses of ur. of soda. Ur. ac., and a small proportion of ur. of potassa." 1859.

Dr. C. D. Homans.

2559. A compact, reddish calculus, of a flattened and somewhat ovoid form, and about $\frac{3}{8}$ in. in diameter; probably uric acid and urates, according to Dr. White.—From the kidney of a child, two years old, who died at the hospital of croup (139, 283). Both kidneys were healthy, and disease had not been suspected. 1869.

Dr. R. M. Hodges.

2560. A material that looks not unlike the fragments of a calculus, that had been broken up by a lithotrite, and in bulk about four fluid-drachms.

From a gentleman who was first seen by Dr. G. about a year and a half ago. Two and a half years previously he passed about a teaspoonful of fine red sand after considerable pain. After this he was relieved for a time; but in a few weeks he began to have discomfort in passing the urine, and for the next two years this went on, gradually increasing. When Dr. G. saw him, he was passing his urine every hour, or oftener, during the night, and perhaps every fifteen minutes during the day; and always with great pain. Just before this time, a catheter having been passed, it was found almost impossible to withdraw it. The obstruction was without doubt owing to the calculi; and, when it was at last withdrawn, the pain was excruciating. There was some loss of flesh, and of the appetite, but the patient's general appearance was sufficiently well. The urine had generally been fetid, and had a dirty look; and once or twice some blood had been passed. On passing an instrument there was felt something like the remains of a disintegrated calculus, or as if it were passing into a sandy beach. A series of operations was then commenced for the removal of the fragments. A very large and perfectly straight catheter, that was made for the purpose, and with a very large eye, was passed two or three times a week for several weeks. The bladder was always first injected with tepid water; the instrument was then passed; and, on withdrawing the stopper, more or less of the fragments were forcibly discharged. Since the last of them were got rid of, the relief has been complete, though a catheter has always been required.

The fragments that have been preserved, are not quite one-half of the whole amount that was passed. Most of them are very irregular, like bits of dried mortar, and on an average smaller than a dried pea. Many were smooth, rounded, and sometimes hollow; and many were surrounded by a secondary deposit. When recent, they were generally lemon-colored, and several of them still have a yellowish

or buff tint, but otherwise they are grayish or clay-colored, from having been in a bottle containing an alkali.

Analyzed by Dr. D. H. Hayden, and found to consist of the ur. of ammonia, with a trace of triple phosphate. 1870.

Dr. G. H. Gay.

2561. A calculus, with fragments, removed by Dr. Clark.

From a young man, eighteen years old, from Providence, R. I., and who entered the hospital March 2d, 1868 (135, 76). "Bladder always weak," but had suffered severely for the last five months. Urinated every hour or two, with a scalding pain afterwards from the neck of the bladder to the end of the penis. The stream would sometimes stop abruptly, and then commence again. Great pain in the bladder on active exercise; less when up than in bed, and most when on the back or right side. On examination of the urine, it was found ammoniacal, alkaline, with a small amount of albumen, a very abundant, white, ropy sediment, and an immense number of pus corpuscles, and crystals of triple phosphate.

On the 7th the operation was performed; and, the stone being large, it was necessary to break it up somewhat, and to cut the prostate, right and left. The bladder felt quite hard and contracted. On the 13th, fragments continued to come away, on syringing the wound. On the 24th, urine passed through the urethra for the first time. April 10th he was up and walking about; and on the 3d of July he left the hospital, with a fistulous opening not quite closed, and occasionally a slight discharge of urine from the wound.

The stone is of a flattened, oval form, and measures upon the cut surface about $1\frac{1}{4}$ by $1\frac{1}{8}$ in. Structure, compact. A small nucleus of uric acid is surrounded by layers of ox. of lime; followed by a layer of triple phosph., about $\frac{1}{10}$ in. broad, and this by layers of the ox. of lime, with a small quantity of uric acid; this last portion constituting the largest portion of the calculus. Surface covered with a highly laminated deposit of phosphate of lime, and the fragments consist of the same, with some coloring matter. The surface of the stone, exposed to a considerable extent, is of a pinkish color, and finely granulated.

Weight of the stone and fragments, when first removed, 13 dr. 2 sc. and 4 gr., Troy. — The analysis was made by Dr. D. H. Hayden. 1870. *Dr. H. G. Clark.*

The next thirty specimens were given in 1800, by
Dr. J. Nichols.

2562. Uric acid, urate of ammonia, and ox. of lime in slight proportion; 1" 8''' by 1" 4'''. Ovoid. Exterior slightly tuberculated, and upon each surface two longitudinal depressions separated by a ridge. Cortex porous and light. Nucleus of a purplish-brown color, and compact. Both halves.
2563. Nucleus of ur. ac. and ur. of ammonia. Outer layers of oxalate of lime; regular, well-marked, compact. 1" by 7'''. Shape, irregular; surface, smooth; color, pale.
2564. Nucleus of ur. of ammonia; ur. ac. slight. Outer layers, ox. of lime. Large tubercles on exterior. Deep fawn color. Shape, irregular. Size, 10'''.
2565. Very rough, spherical, mulberry calculus. Nucleus irregular in shape; ur. of ammonia, and a little ur. ac., succeeded by ox. of lime. Interstices between the ray-like laminae filled with the urate. 1" 3''' by 1" 1'''.
2566. Dark, round, mulberry stone. Nucleus, ur. ac. and ur. of ammonia. Exterior, ox. of lime. Much organic matter, consisting of dried blood, epithelium, etc., between nucleus and the oxalate. 1" 2''' in diameter.
2567. Irregularly shaped, botryoidal calculus. Nucleus ur., ac. and ur. of ammonia; and the same is interspersed amidst the very irregularly deposited layers of oxalate of lime, which form nearly the whole of the exterior. 1" 6''' by 1" 4'''.
2568. Spherical calculus, made up of alternate layers of ox. of lime and ur. ac., with ur. of ammonia. Nucleus composed of the last two substances. Exterior covered with a distinct coating of large crystalline concretions of ox. of lime, coral-like in aspect. 1" 3''' in diameter.
2569. Large, pale calculus, of a long oval shape. Nucleus; ur. ac., much ur. of lime, and a little ur. of ammonia. Outer part made up of ur. ac., much ur. of lime, and a little ur.

of ammonia and oxalate of lime. 2'' 10''' by 1'' 8'''.
Human?

2570. Ox. of lime, mixed with ur. of ammonia and ur. ac. Spherical. 9''' by 8'''.
2571. Fragment of stone; ox. of lime, ur. of ammonia, and a little ur. ac. Cavity in centre, filled with much organic matter, as epithelium, etc. Size originally 1'' 2''' by 1''.
2572. Spherical, tubercular calculus, showing beautiful changes of color and arrangement. The inner portion consists of ur. ac., ur. of ammonia, and ur. and ox. of lime. This is followed by a remarkably compact and colored deposition of ox. of lime, of a stellated form, which is succeeded by a more regular layer of ox. lime, ur. ac. and ur. of lime. Diameter 2'' 1'''.
2573. An irregular, tetrahedral and coarsely lobulated calculus. Centre very dark, and composed of ox. of lime, ur. ac. and urates of ammonia and lime. Contains many cavities filled with coagula and epithelium. Outer portion formed by ox. of lime, uric acid and ur. of lime. 1'' 7''' by 1'' 3'''. Both halves preserved.
2574. Large, irregular, gourd-shaped calculus, composed of regularly concentric layers of ur. ac., ur. of ammonia, and ox. of lime. Its constricted form is owing to attrition or erosion; it having been originally spherical in shape. Exterior also shows signs of erosion. 2'' 10''' by 1'' 10'''.
2575. Peculiar calculus approaching the pyriform in shape externally. The body is composed of ur. ac. and ur. of ammonia; the dense cortex of ox. of lime. Exterior polished at one extremity, and of a greenish-brown hue; the other eroded apparently and of a paler color. 1'' 9''' by 1'' 3'''.
2576. Broad, oval calculus, made up of loosely adherent, concentric laminae of ur. ac. and ur. of ammonia, with a little ox. of lime. Centre, yellowish red. The exterior, like many others in this collection, shows marks of the action of solvents within the bladder. 1'' 6''' by 1'' 3'''.
2577. Broad, flattened, ovoid; resembling in color, structure of

- section, and roughly granulated exterior surface, a macaroon. Scarcely a trace of laminae. Ur. ac., ur. of ammonia, and ox. of lime. 1" 10'" by 1" 7'".
2578. Uric acid and urate of ammonia; ends composed of ox. of lime. 2" 3'" by 1" 6'" . Oblong. Exterior surface coarsely granulated, and sparsely studded with broad tubercles.
2579. Oxalate of lime, uric acid, and urate of ammonia. 1" 5'" by 1" 2'" . Oval. Centre spongy though hard, but surface has a pinkish-ash color. Exterior covered with fine tubercles.
2580. Broad, flattened, ovoid calculus of ox. of lime, interspersed with ur. ac. and ur. of ammonia. Very compact. Exterior thickly coated with groups of crystals of oxalate of lime, and studded with a row of tubercles. 1" 3'" by 1" 1'" .
2581. Ox. of lime, with ur. ac. and ur. of ammonia. Length 1" . Irregular, lobulated concretion. Very compact. Exterior smooth, white, and resembles flint in appearance; coated thinly with organic matter.
2582. Smooth, compressed, oval calculus; composed mostly of ur. ac. with ur. of ammonia and ox. of lime. Color yellowish-fawn. 1" 9'" by 1" 4'" .
2583. Flattened oval stone of ur. ac., with ox. of lime in slight proportion and ur. of ammonia. Exterior indented deeply, grooved by erosion, and surrounded with a belt of rounded tubercles. 2" 2'" by 1" 8'" .
2584. Ox. of lime, with a nucleus of ur. ac. and ur. of ammonia. Exterior covered with high tuberculated excrescences. 1" 6'" by 1" 3'" .
2585. Irregular oval calculus. Nucleus consists of ur. ac.; then a dark-colored portion of ox. of lime. Cortex composed of ur. ac., urates of ammonia and soda, and ox. of lime. Exterior nodulated and tuberculated. 2" 2'" by 1" 10'" .
2586. Mulberry calculus. Ox. of lime, ur. ac., urates of ammonia and soda. Tuberculated nodules. 1" 4'" by 1" 2'" .

2587. Compressed, irregularly ovoid concretion. Ur. ac., ox. of lime, and urates of ammonia and soda. No regular laminae. Very porous. Exterior covered with flattened tubercles. 2" 2''' by 1" 6'''.
2588. Flattened, oval, handsomely marked. Ur. ac., ur. of potassa, and ox. of lime; the latter forming the dark-colored border. 1" 3''' by 11'''.
2589. Oblong, porous. Ur. ac. almost wholly; some ur. of soda and ox. of lime. Exterior shows marks of erosion, and the "hour-glass constriction" very finely; the groove is narrow and deep. 2" 7''' by 1" 7'''.
2590. Oblong, oval. Ur. ac., ur. of soda, and ox. of lime; the latter forming the smooth, polished, pale, olive exterior. Cut surface, yellowish-fawn. 2" 2''' by 10'''.
2591. Mulberry, oval calculus. Nucleus composed of ur. ac., and ur. of soda. Mostly composed of ox. of lime. Exterior covered with small tubercles of uniform size and dark color, interspersed with minute, light-colored, spherical concretions of the same composition. 1" 4''' by 1''.

The next seven specimens were given in 1847, by

Dr. J. C. Warren.

2592. A calculus, botryoidal, and polished upon the surface. Nucleus, ur. of ammonia and ur. ac. Next portion consists of loosely deposited ur. of ammonia, ox. of lime, and triple phosphate mixed. Outer part is made up of very compact layers; ox. of lime, with a very little phosphate of lime. 1" 4''' by 1" 2'''.
2593. Large, irregularly cylindrical stone. Nucleus, ur. ac., and ur. of ammonia. Second layer consists of ur. ac., ur. of ammonia and lime, and ox. of lime, forming an oval calculus, on the two long surfaces of which were deposited masses of ur. of ammonia, triple phosph. and phosph. of lime mixed. 1" 5''' by 1" 2'''.
2594. Thin, oblong calculus. The dark, broad lamina consists of ur. ac. and ur. of ammonia; inside of which and exteriorly are formed layers of the same, alternating with phosphate and oxalate of lime, and triple phosphate. 1" 2''' by 11'''.
2595. Oval calculus. Nucleus is made up of ur. ac. and ur. of ammonia, and succeeded by a broad portion of ur. ac.

and ur. of ammonia, phosph., and ox. of lime. The outer surface of this layer was composed of sharp spiculæ of this latter salt, on which the external laminae of phosph. of lime with a little oxalate were deposited. 1" 7''' by 1" 4'''. 1847.

2596. Irregularly oval. Nucleus, urates of ammonia and lime. Mass made up of ox. of lime, phosph. of lime, and a little triple phosph., irregularly mixed. 1" 3''' by 11'''.
2597. Rough, irregularly ovoid. The central dark portion is composed of ur. of ammonia and lime, and a little ur. ac., mixed with ox. and phosph. of lime. The well-defined layer (marked 2) consists of ox. of lime and a little phosph. of lime; on either side of which is a mixture of urate of ammonia and phosphate of lime. 1" 9''' by 1" 2''.
2598. Irregular, cylindrical. Nucleus, urates of ammonia and lime, and ox. and phosph. of lime; the oxalate shooting out in rays, and forming separate centres of crystallization. The filling in and exterior are composed of phosph. and ox. of lime and triple phosph., with urates of soda and ammonia, and ur. ac. 1" 5''' by 1''.

The nine following specimens were given in 1800, by
Dr. J. Nichols.

2599. Irregular shape. Ur. acid, ox. of lime, triple phosph., phosph. of lime, and urates of ammonia and soda. 1" by 10'''.
2600. Compressed, oval. Ur. ac., ox. of lime, and urates of ammonia and soda. Triple phosph. in crevices between centre and cortex. Exterior shows signs of deep erosion, probably chemical. 1" 9''' by 1" 4'''. 1847.
2601. Nucleus, ox. of lime, ur. ac., and urates of ammonia and lime. White portion consists of phosph. of lime and triple phosphate. Exterior granular and friable. 2" 3''' by 11'''.
2602. Originally ovoid, but changed in shape by deposition of phosph. of lime and triple phosph. on one surface. Body consists of ox. of lime, ur. ac., and urates of ammonia, lime, and soda. 1" 8''' by 1" 1''.
2603. Irregular, nodular mass. Nucleus, ox. of lime, ur. ac.

and urates of ammonia, lime, and magnesia. Exterior portion, phosph. of lime and triple phosphate. Friable. 11''' by 9'''.

2604. Spheroidal. Skeleton made up of ox. of lime, and there are found interspersed ur. ac. and ur. of lime, and phosph. of lime, with triple phosph. The latter two form the soft exterior. Original length, 1'' 6''', and breadth 1'' 2'''.

2605. Oblong, oval, rugged stone. Composed of alternate layers of ur. ac., urates of ammonia, lime, and soda, and ox. of lime. Phosph. of lime also intermixed. Exterior shows signs of deep chemical erosion. 2'' by 1'' 4'''.

2606. Oval, compact. Pinkish tinge in places. Ox. of lime, and ur. ac., and urates of ammonia and lime. Between the loosely joined laminae is phosph. of lime. Exterior quite dark, in part of an olive tint and scaling. 1'' 8''' by 1'' 3'''.

2607. Oblong; very irregular. Central portion, ox. of lime, ur. ac. and ur. of ammonia. About this is a deposit of phosphate of lime and triple phosphate. 2'' 3''' by 1'' 3'''.

2608. Section of a large calculus from the human subject. No history of the case. Analysis and description by Dr. J. C. White: "Large, irregularly pyriform; originally oval, but changed in shape by the subsequent deposition near one end of an amorphous mass, which finally was covered in by the general layers. Nucleus and body composed of a mixture of ur. of ammonia, ox. of lime, triple phosph. of ammonia and magnesia, and carb. and phosph. of lime. A narrow ring of ox. of lime separates the large unstratified nucleus from the outer layers. Externally, except a portion of the smaller end, the surface is covered by a deposit of large, white, rounded, prismatic crystals, resembling somewhat those of ox. of lime occasionally found in the same situation, but softer and efflorescent. Color of exposed and cut surfaces, pale, brownish-yellow. Stratification not very compact." Length of section, 2'' 9'''; breadth, 2''. 1860.

Dr. T. H. Gibby, of Nashua, N. H.

2609. Calculus removed by operation. From a little boy, eight years old, who had had the usual symptoms for three years. Lithotomy was performed June 1st, 1869; on the 8th the urine passed mostly through the penis, and on the 16th he was able to leave the hospital (141, 118).

Form of the stone somewhat cylindrical; diameter $1\frac{3}{8}$ in. by 1 in. Surface whitish and granulated. Structure rather coarsely laminated, with a defined, compact nucleus $\frac{1}{2}$ in. in length, of a pale-brownish color, and contrasting with the whitish color around. Composed, according to Dr. White, of the phosph. and carb. of lime, a little of the triple phosphate, and urate of ammonia; nucleus mostly ox. of lime. 1869.

Dr. R. M. Hodges.

2610. Two calculi, removed by operation. The patient, a puny little boy, four years old, had had occasional dysuria for two years, and of late excruciating pain, with incontinence of urine. Lithotomy was performed January 23d, 1868, and he left the hospital well, March 7th (107, 4).

The external appearance of the calculi was very nearly the same; about $1\frac{1}{4}$ by 1 in.; form somewhat triangular, flattened, and with the angles quite rounded; surface smooth, and of a yellowish color; one, on section, is for the most part dark, very irregular in structure, and with something like a central cavity; cortex, $\frac{1}{8}$ to $\frac{1}{4}$ in. thick, is white and compact. Composed, according to Dr. White, largely of ur. acid and urates; ox. of lime very small; carb. and phosph. of lime, and triple phosphate. 1869.

Dr. H. J. Bigelow.

2611. A calculus, the form of which suggests the idea of a decoy duck. Body $2\frac{1}{4}$ in. in length, and of an ovoid form; with a projection, near one extremity, about the size of the last joint of the finger; one of these portions having probably formed in some sac connected with the bladder. Brownish externally, and internally yellowish. Laminated. External layers in part broken, and show a coarse structure; and beneath this is partially seen the characteristic tuberculated surface of a ur. ac. calculus. Analysis by Dr. W.: "Ur. ac., mixed urates, phosph. of lime, triple phosph. of ammonia and magnesia, and a little ox. of lime." 1867.

Dr. J. C. White.

The next five specimens were given in 1847, by

Dr. J. C. Warren.

2612. Oval. A large gap occurs, which must have been formed in the bladder. Nucleus, ox. of lime, ur. ac., and the urates of lime and ammonia; a black lamina of coagula may have rendered the fracture less difficult. Its exterior and the crack are coated with a deposit of phosph. and carb. of lime, and triple phosph. of ammonia and magnesia. 2" by 1" 8".
2613. Spherical. Nucleus, ox. of lime, with a little ur. ac., and urates of soda and ammonia. This is followed by a less compact deposition of ox. of lime, and urates of ammonia and soda. Exteriorly is a layer of phosph. and carb. of lime. 1" 9" by 1" 7".
2614. Irregular, ovoid. Nucleus compound, and composed of ox. and ur. of lime, ur. of ammonia and ur. ac. About this are deposited, at first regularly and afterward eccentrically, ur. of ammonia, ox., carb., and phosph. of lime; the yellow streaks being composed of the ox. and ur. 2" 6" by 1" 9".
2615. Irregular ovoid, and constricted towards one extremity. Nucleus, ur. ac., urates of ammonia and lime, and ox. of lime. About this is a regular deposit of phosph. and carb. of lime; then a layer of ur. ac., urates of ammonia, and lime; and then a large amount of carb. and phosph. of lime, and triple phosphate. Human? 3" 5" by 2" 7".
2616. Oval. Ur. ac., ur. of ammonia, phosph. of lime and triple phosph. The ends are wanting in ur. acid. 1" 10" by 1" 4".
2617. A calculus $1\frac{1}{2}$ in. by $1\frac{3}{8}$ in., and of a somewhat rounded form. Hard, laminated, and, for the most part, of a reddish-brown color; this portion consisting, according to Dr. White, mainly of uric acid, with a little ur. of ammonia, and a considerable amount of ox. of lime where it borders the external shell. This last consists of the phosph. of lime, and triple ph. of ammonia and magnesia, is $\frac{1}{4}$ in. thick at one part, but varies much, and in some places the reddish portion is exposed; surface broadly grooved.

Removed by lithotomy from a man seventy-six years

old, who had always resided in this vicinity, and who had had symptoms of calculus for five years. Never sounded until the day before the operation. He had a very large prostate, and passed water about forty times a day. Greatly exhausted by want of sleep, and pain, and was exceedingly feeble at the time of the operation, which he survived twenty-four hours. He rallied thoroughly from the operation, passed a comfortable night, took nourishment and stimulants with relish and in large quantities, and died at last quite suddenly. 1869.

Dr. R. M. Hodges.

2618. A calculus that distended the pelvis of the left kidney, and extended into the infundibula and calices; so that its irregular form suggests the idea of some kinds of coral. Weight 1 oz., and diameters about $2\frac{1}{2}$ by $1\frac{1}{2}$ in. Extremities of some of the branches cup-shaped, so as to receive other calculi or the papillæ of the pyramids. Surface rough, and fawn-colored. In the other kidney were several small calculi. Of these last, of which the largest are shown, one or two are about as large as the tip of the finger; one is irregularly covered over with large, sharp crystals, and another partially with the same. Around the calculi there was a puriform fluid, and the renal substance was gangrenous. The same fluid was found in the ureters and bladder; and the mucous membrane of this last was diseased. The third lobe of the prostate also was enlarged; the membranous portion of the urethra showed the results of old inflammation, with contraction of the canal and fistulæ, of which one opened externally. — Dr. White found the large calculus to consist of urate of ammonia in large amount, uric acid in small amount, carb. of lime, phosph. of lime, and triple phosph. of ammonia and magnesia. The large and peculiar crystals upon the surface of a portion of the large calculus, and that seem to entirely compose two of the small calculi, are ox. of lime.

The patient, who had been under the care of Dr. J. S. Green, of Dorchester, was a carpenter, sixty-six years of age, who had had dysuria, with failure of the health, for six years. A year before his death perineal abscesses formed, and two months afterward the urine began to pass

through them. Gradually sank under the disease. (Med. Jour. Vol. LXXVII. p. 330.) 1867. *Dr. J. Homans.*

2619. Calculus, removed by the lateral operation. The patient was a little boy, six and a half years old, who had always resided in Boston, and had had symptoms of stone for four years. The operation was performed April 20th, 1857. The urine did not pass wholly through the urethra until the 9th of May, at which time the wound was fairly cicatrized. On the 26th, without assignable cause, the wound opened, and urine began to pass through a fistulous orifice, which, by report, was preceded by a little boil. There was no surrounding inflammation. Although the urine passed freely by the urethra, and only by drops through the fistula, it was not until June 9th that this last was obliterated by repeated applications of nitrate of silver. The stone was oval, flattened, $\frac{7}{8}$ in. in length, and weighed eighty-two grains.

The following is the result of Dr. Bacon's analysis; the powder removed in sawing the calculus, and a few crystals from the outside being examined: "The constituents are, — oxalate of lime, phosphate of lime, triple phosphate and carbonate of lime; with small proportions of urate of ammonia, urate of soda and uric acid. Comparing the analysis with the appearance of the section, it is evident that the nucleus and several surrounding layers consist of oxalate of lime chiefly. The outer layers are mostly composed of earthy phosphates. Small crystals of oxalate of lime cover the exterior. This deposition of oxalate of lime upon earthy phosphates is an interesting point in the structure of the calculus." 1858.

Dr. R. M. Hodges.

The next nineteen specimens were given in 1800, by

Dr. J. Nichols.

2620. Oblong calculus, with a curved, irregularly shaped concretion, deposited on one extremity. Centre consists of ox. of lime and ur. ac.; remainder of the same, with phosphate of lime, triple phosph., carb. of lime, and urates of ammonia, potash, and magnesia. Length, 2". Renal?
2621. Oblong. Friable. Centre consists of ox. of lime, ur. ac., and urates of ammonia and magnesia. Outer portion

- a mixture of triple phosph., carb. and phosph. of lime. 1" 10''' by 1" 1'''.
2622. Ovoid. Centre lost. Outer portion; ur. ac., urates of potassa and lime, phosph. of lime and triple phosph. 1" 8''' by 1" 3'''.
2623. Flattened; ovoid. Ur. ac., urates of ammonia and potash; very little triple phosph. present. Exterior, granular. 1" 5''' by 1" 2'''.
2624. Broad oval. Centre, ur. ac., and urates of ammonia and magnesia. Outer part is a mixture of phosph. of lime and triple phosphate. 1" 7''' by 1" 2'''.
2625. Thin, oval. Nucleus, ur. ac. and ur. of ammonia. Outer layers, phosph. of lime, triple phosph., and a little ur. of ammonia. 1" 9''' by 1" 2'''.
2626. Fragment of a cylindrical calculus, showing by course of laminae that two nuclei were once present, and at a long distance apart; a very interesting specimen. The fawn-colored striæ are ur. of ammonia and ur. ac. The remainder consists of phosph. of lime and triple phosphate.
2627. Irregular mass; mixture of phosphate of lime, triple phosph., ur. ac. and ur. of ammonia and soda. 10''' by 8'''.
2628. Cylindrical. Friable. Phosph. of lime, triple phosph., intermixed with ur. of ammonia, and a little ur. acid. 1" 8''' by 10'''.
2629. Conical, oblong. Ur. of ammonia and ur. ac. The white parts are composed of the phosph. of lime and triple phosph. 2" by 1".
2630. Rough, and irregularly laminated. Ur. ac., ur. of ammonia, carb. of lime, and triple phosph. 10''' by 7'''.
2631. Ovoid. Nucleus, ur. ac. and ox. of lime. Outer portion ox. of lime. External surface thickly studded with prominent rugged tubercles. 1" 1''' by 9'''.
2632. Ox. of lime and uric acid. Original length, 1" 5''' by 1". Exterior shows marks of erosion. Oblong, oval.
2633. Ox. of lime and ur. acid. 1" by 10'''. Firm mulberry calculus; exterior studded with warty tubercles.
2634. Ox. of lime and ur. acid. 10''' by 7'''. Exterior distinctly granular and sanded.
2635. Ox. of lime and ur. acid. 10''' by 7'''. Oblong, oval. Exterior tuberculated and rough.

2636. Ox. of lime and ur. acid. Surface, 4^{'''}. Irregularly shaped concretion.
2637. Ox. of lime and ur. acid. Diameter, 4^{'''}. Pyriform. Exterior covered with beautiful transparent, tabular crystals of ox. of lime.
2638. Small, compressed, oval, mulberry calculus. Ox. of lime, with a little ur. ac. and phosph. of lime. 9^{'''} by 7^{'''}.
2639. A calculus, removed from the bladder by the finger.

The patient was a married woman, æt. thirty-four years, and had had frequent and painful micturition for about four months; she was constantly getting worse, and the urine was toward the lastropy and offensive. About a year before, a small calculus had been passed. The forefinger was passed without much force through the urethra; and, with the aid of the other hand in the vagina, the calculus was removed. It is of an irregularly triangular form, about 1 $\frac{1}{2}$ in. by $\frac{3}{4}$ in. in its largest diameters, and consists of the triple phosphate of ammonia and magnesia, carb. of lime, and ur. of ammonia. With it was a second calculus, about the size of a pea, and of a flattened form; and, the bladder having been fully explored by the finger, no others were found. Relief from the operation complete. (Hospital, 124, 151.) 1867.

Dr. R. M. Hodges.

2640. Nodulated, reniform calculus of ox. of lime, with a little ur. of the same; presenting the appearance of numerous distinct nuclei. 4^{'''} by 3^{'''}. 1847. *Dr. J. C. Warren.*
2641. Oval. Centre, ox. of lime. Body composed of urates of ammonia and lime, forming a soft, porous compound. Exterior sanded. 1^{''} 7^{'''} by 1^{''} 2^{'''}. 1800.

Dr. J. Nichols.

2642. External layers of an oblong flattened stone. Urates of ammonia, soda and magnesia, and ox. of lime. Centre lost. 2^{''} 6^{'''} by 1^{''} 7^{'''}. 1800. *Dr. J. Nichols.*

2643. Oblong, spheroid. Darker portion inside is composed of ox. of lime, with a little urate of the same. Outer part made up of ox. and phosph. of lime, ur. of lime in considerable amount, and urates of soda and ammonia. 2^{''} 5^{'''} by 2^{''} 1^{'''}.

Dr. J. C. Warren.

2644. Compact, triangular, prismatic stone. Ox. of lime, in-

termixed with a little ur. of ammonia and phosph. of lime. Length of the largest surface. 1" 2". 1847.

Dr. J. C. Warren.

2645. Hard oval. Mostly ox. of lime, with which are mixed the urates of ammonia, soda, and magnesia, with phosph. of lime and triple phosph. Exterior shows marks of violence or erosion. 1" 6" by 1" 2". 1800.

Dr. J. Nichols.

2646. One-fourth of a chalky, friable calculus. Centre, ur. of ammonia and ox. of lime; remainder consists of phosphate of lime and triple phosphate. Original size, 1" 10" by 1" 2". 1800.

Dr. J. Nichols.

2647. Form elongated and peculiarly curved; the nucleus being at one end, and composed of organic matter, epithelium, tubuli, etc., with a little ur. of ammonia. The remainder consists of carb., phosph., and ox. of lime, and triple phosph. The coarse, granular mass is formed of large crystals of phosph. of lime and organic matter. 3" by 1" 4". 1847.

Dr. J. C. Warren.

2648. Oblong, oval. Centre, ox. of lime and ur. of ammonia. Body made up of loose, friable laminæ of phosph. and carbonate of lime, with triple phosph. 1" 6" by 11". 1800.

Dr. J. Nichols.

2649. Oblong. Urates of ammonia, soda and magnesia, with phosph. of lime and triple phosph. 9" by 6". 1847.

Dr. J. C. Warren.

2650. Oval. Porous. Urates of ammonia, soda, magnesia, and lime; and phosphate and carb. of lime. 1" 7" by 1" 1". 1847.

Dr. J. C. Warren.

2651. Calculus removed by the operation of lithotomy.

The patient was seventy years of age, belonged in this State, had had urinary symptoms for about ten years, and for a little more than two years had been troubled with the stone. His father had had a stone removed fifty years before, weighing 3 oz. Aug. 7th lithotripsy was tried, but not much came away; on the 9th a second operation; on the 11th a third, when the instrument broke in the bladder. On the 13th the stone was removed, and with it the

broken instrument; and on the 28th of Sept. he left the hospital well (132, 142).

The stone is oblong, tuberculated externally, and on the cut surface measures $1\frac{3}{4}$ in. by $1\frac{1}{2}$ in. Weight, 14 drachms when removed; with 24 grs. of fragments. Analysis by Dr. White; ur. ac. and ox. of lime; and concentric, with alternating laminae of characteristic color.

Dr. R. M. Hodges.

The following seven specimens were given in 1800, by

Dr. J. Nichols.

2652. Soft. Oblong. Urates of ammonia, soda and magnesia, phosph. of lime, and triple phosph. $1'' 2'''$ by $8'''$.
2653. Fragments of an irregularly-shaped, friable concretion. Ur. of ammonia, with a little triple phosph. Color, dirty gray; pinkish tinge externally.
2654. Outer layers of a calculus, composed of urates of ammonia and soda, with a little phosph. of lime externally. Centre either absorbed or lost. Inner layer easily enucleated: $1'' 9'''$ by $1'' 2'''$.
2655. Ovoid. Very porous. Phosph. of lime, triple phosph., and urates of ammonia and lime. $1'' 4'''$ by $1'' 1'''$.
2656. Boat-shaped. Nucleus eccentric; urates of ammonia and magnesia. Body, phosph. of lime and triple phosphate. $1'' 7'''$ by $10'''$.
2657. Spherical. Porous. Phosph. and carb. of lime, and triple phosph., with a little ur. of ammonia. $11'''$.
2658. Irregular, ovoid. Composed of loose layers of phosph. and carb. of lime, with a slight amount of triple phosph. and ur. of ammonia. Deposited on a bent piece of woody fibre. $1'' 7'''$ by $1'' 4'''$.
2659. Calculus removed by the lateral operation.

The patient was a merchant, æt. twenty-six, from the State of Maine, and had had symptoms of stone for three years. He was very much emaciated, but gained twenty-five pounds in the course of six weeks after the operation. (Hospital, 77, 116.) The calculus is of a flattened, ovoid form, $2\frac{3}{4}$ in., and the diameters are $2\frac{1}{2}$ in., and $1\frac{3}{4}$ in.

Color, whitish ; and structure, as seen on cut surface, rather coarse. Weight, 4 oz. 2 sc.

The powder obtained in sawing the calculus was found by Dr. Bacon to consist of phosph. of lime, a considerable amount of the triple phosph., and small proportions of carb. of lime, ox. of lime, and animal matter. For a report of the case, with a figure of the calculus, see *Med. Jour.*, Vol. 58. p. 13. 1858. *Dr. H. J. Bigelow.*

2660. Fragments of a calculus, that were removed through a vesico-vaginal fistula. (*Hospital*, 79, 94 ; and *Med. Jour.* Vol. LVIII. p. 362.) — The patient was thirty-two years of age, and from the western part of this State.

“For five weeks preceding her last confinement, two years and seven months before entrance, she had painful micturition for the first time in her life. Her labor lasted seven days, and the physicians in attendance attributed the delay to the presence of a stone in the bladder. The child was delivered without instruments. In ten days she was up and about the house, and for five weeks had no trouble. She then began to have offensive and thick purulent urine ; and, finally, at the end of seven weeks, took to her bed from inability to walk about or sit down. She was confined to it for eleven months, and during this period passed calculi from the bladder, sometimes as many as four at a time, and varying from the size of a pea to that of a walnut. She had passed none for a year. A catheter detected the existence of a calculus, and, on examination per vaginam, a large vesico-vaginal fistula was found, admitting the finger, which came in immediate contact with the calculus. The vagina and inside of the bladder felt rough to the finger, like sand-paper, from the deposit of phosphates. A pair of lithotomy forceps, introduced through this aperture, crushed a very soft stone, and five drachms of fragments were removed. Great relief followed the operation.”

The calculus was found by Dr. White to consist of the triple phosph., phosph. of lime, and ur. of ammonia. “The laminae are arranged in an irregular, concentric manner, and are mostly made up of large, loosely arranged crystals of triple phosphate, undoubtedly a hasty and secondary

formation, depending upon inflammation produced by the fistula." 1858. *Dr. R. M. Hodges.*

2661. Calculus removed by the lateral operation; of a flattened, oval form; $\frac{5}{8}$ in. by $\frac{3}{8}$ in.; earthy appearance; surface rough, with some small, shining crystals. Consists chiefly, according to Dr. Bacon, of the triple phosph. and phosph. of lime, with some ur. ac. and urates. The crystals upon the exterior are the triple phosph.

From a mechanic, of this city, æt. fifty-one, who had severe urinary symptoms, and had had them, more or less, as long as he could remember. In 1858 a large calculus was removed. Oct. 25th, 1859, another stone was felt by Dr. B., and on the 25th of Feb. the operation was performed. The calculus broke, and the specimen here shown formed the nucleus; about a teaspoonful of fragments being also scooped out. The patient finally did well. (Hospital, 87, 6.) 1860. *Dr. H. J. Bigelow.*

2662. A dark, compact, urethral calculus, about $\frac{1}{2}$ in. long and $\frac{1}{8}$ in. in diameter; transverse section highly polished. Examined by Dr. White; ox. of lime, with urate of soda, and a trace of uric acid.—From a little boy, five years old, who had had retention of urine for about twenty-four hours, and some trouble for two or three days. Removed by incision in front of the scrotum, and the child did well. 1860. *Dr. J. Homans.*

2663. A calculus, that was passed from the urethra. It is about $\frac{1}{2}$ in. long, $\frac{1}{4}$ in. in diameter, crystalline upon the surface, and consists, probably, of ox. of lime.—From a man, about fifty-two years of age, and who had had urinary symptoms for some years. The calculus protruded from the urethra, and was easily removed. 1857. *Dr. J. Ware.*

2664. Urethral calculus, $\frac{3}{8}$ in. by $\frac{1}{4}$ in., irregular, granulated, and composed apparently of the ox. of lime.—From a man, æt. twenty-seven, who had suffered for two months from pretty severe symptoms, that had been attributed to inflammation of the bladder. The calculus was felt about $\frac{3}{4}$ in. from the orifice of the urethra, and was easily removed. (Hospital, 140, 202.) 1869. *Dr. R. M. Hodges.*

2665. A rough, dark-brown calculus, $2\frac{1}{2}$ lines or more, in diam., and passed from the urethra.

From a man, about thirty-two years of age, who had "bilious fever" in Aug. and Sept., 1866, and that lasted for five weeks. This was followed by attacks of pain in the stomach, umbilicus, pubic or right iliac regions, with retraction of the scrotum, but not of the testicle; sometimes preceded by pain in the lower part of the spine; occasionally with priapism; and always followed by a sense of constriction to the right of the pubes, extending down the right side of the penis, and into the thigh. In March, 1867, he went abroad, and had no trouble except an occasional sense of constriction about the pubes. About the first of July, after his return, and whilst feeling perfectly well, the uneasiness in the pubic region returned, with frequent desire to urinate, and very slight hematuria, and in the night the calculus was passed. Examined by Dr. J. C. White, and found to consist of the ox. of lime. 1867.

Dr. C. Ellis.

2666. Urethral calculus, about 3 by 5 lines; dark, very hard, and somewhat irregular. Probably ox. of lime. — From a gentleman, who, in the spring of 1868, began to have attacks of very severe and sharp pain in the right side of the abdomen, with a drawing up of the testicle; microscopically, a few blood globules and crystals of the ox. of lime were occasionally seen. In Dec., 1869, he felt by the pricking pain that the calculus had entered the urethra; considerable force was required to expel the urine, and occasionally it stopped; and about the third day the calculus was expelled. 1870.

Dr. C. Ellis.

2667. Ox. of lime. Form very peculiar; originally an ovoid, from which three equidistant processes shoot out, forming a triangular prism on section. Largest diameter, 6". 1847.

Dr. J. C. Warren.

2668. A calculus that was voided by a mare, after considerable straining. Of a regular, oval form; $2\frac{1}{8}$ in. by $\frac{5}{8}$ in., and quite heavy; surface quite coarsely and uniformly granulated, and of a dark ash-color, externally. On section, it is indistinctly radiated from the centre, and the color is

rather lighter. Composed nearly of pure ox. of lime, with a little carb. of lime, according to Dr. White. 1869.

Dr. H. J. Bigelow.

2669. A collection of calculi, from the size of a mustard-seed to that of a pea, and amounting to about a teaspoonful and a half; fawn-colored, smooth, highly polished, and with some appearance of façettes.

From a man, about seventy-five years of age, who had had perineal fistula for some weeks, and, when Dr. C. first saw him, an infiltration of urine. Incisions were made; and in the course of four or five operations, subsequently, the calculi here shown, with many more, were removed from somewhere, as it seemed, anterior to the bladder. The fistula then closed, and the patient did well.

Dr. D. H. Hayden analyzed the calculi, and found them to consist of the ox. of lime. 1870.

Dr. H. G. Clark.

2670. Spherical. Ox. of lime; 5'' in diameter. 1847.

Dr. J. C. Warren.

2671. Ovoid. Exterior presents a coralline appearance, formed by crystals of ox. of lime. Length, 7'''. 1847.

Dr. J. C. Warren.

The next five specimens were given by

Dr. J. Nichols.

2672. Ox. of lime. Spherical. Exterior covered with very prominent globular clusters of tubercles. 1'' 4''.

2673. Compressed, spherical, brown calculus, composed entirely of ox. of lime, and highly characteristic. Exterior covered with nodular masses of tubercles and minute granules. 1'' 4''.

2674. Very compact. Oblong ox. of lime, with a little phosph. of lime. Exterior covered with a thick coating of crystals of ox. of lime; large, flattened octahedra. 1'' by 7''.

2675. Large, cylindrical, friable mass of triple phosph. and phosph. and carb. lime; deposited upon an irregular stellate nucleus of ox. of lime. Diameter, 1'' 6''.

2676. Very large, irregular, white oval. Nucleus eccentric; substance very compact and dense. Phosph., carb. and

ox. of lime, and triple phosph. Exterior smooth. — From a horse probably. 4" 2'" by 2" 7'''.

2677. A renal calculus, of immense size, with six small ones.

The case was published in the Boston Med. Intelligencer, March 2d, 1824, by Dr. J. Lummus, of Lynn. — For two years the patient had had pain in each side, and particularly in the left; but, until a few weeks before her death, nursed a young infant, and attended to her domestic duties. Ten days before death Dr. L. found her prostrated, greatly emaciated, and with a distinct, hard, unyielding tumor in the seat of the pain. "All the viscera seemed healthy, except the kidneys. The left ureter was impervious; the right I was prevented from examining. I removed the tumor on the left side, weighing 4 lbs.; containing the kidney, thickened peritoneum, and a calculus weighing 19 oz., avoirdupois; an end of it broken, and presented a smooth fracture; another calculus weighing $\frac{1}{2}$ oz., and six others, weighing together $\frac{1}{2}$ oz. The calculus in the right side I felt through the thickened peritoneum; and I judged it was but little smaller than that of the left; I was not allowed to remove it."

The body of the large calculus is of an ovoid form, and upon one side regular in its outline. From the other side there project five masses, more or less pedunculated, as usually seen in renal calculi, and varying from the bulk of a chestnut to that of a pullet's egg. The color is whitish, and the surface rough. Weight, 1 lb., $1\frac{1}{4}$ oz. Diameters of the body of the calculus, $5\frac{2}{3}$ in., $2\frac{1}{3}$ in., and $2\frac{5}{16}$ in. The small calculi weigh $1\frac{1}{3}$ oz.; vary much in form, and in size, from about $\frac{1}{8}$ in. to $1\frac{1}{4}$ in. in diameter.

In 1858 the specimen was examined by Dr. J. Bacon: "The portion analyzed was from one of the external nodules, which presented, on section, numerous concentric layers, mostly of a yellowish-white color. A friable nucleus, composed of ox. of lime, with a very little phosph. of lime, occupied the centre. Around this was a series of hard layers, consisting of phosph. of lime, chiefly; with a little ox. of lime, triple phosph. and carb. of lime. The outer layers, of a nearly white color, and rather friable, were composed of phosph. of lime, with considerable triple

phosph. and a little carb. of lime. The calculus contained, in addition to the mineral substances, a larger proportion than usual of epithelial debris, and other indeterminate animal matter." 1847. *Dr. J. C. Warren.*

2678. Calculi, passed from the urethra. The patient was a single woman, *æt.* fifty-five years, and severely troubled by rheumatism for about sixteen years. For about a year she had had uneasiness in the region of the bladder, with increased turbidity of the urine; there having been a mucous deposit for some time before. These symptoms increased, and about the last of July the calculi were passed at once, and without pain. For a few weeks previously she had kept her bed, but her health afterward improved, and the urine became nearly free from mucus. Dr. White found the calculi to consist, principally, of phosphate of lime, with the ox. and carb. 1868.

Dr. James S. Greene, of Milton.

2679. Fragments of a calculus, with fine débris, from a case of lithotrixy; and amounting altogether, in bulk, to about ʒvi .

The patient, a man *æt.* thirty-eight years, entered the hospital July 26th, 1869 (140, 218); had had symptoms of disease for four years, and was constantly getting worse. Pain in the bladder, and especially after micturition. Urine passed frequently; and with a sudden stoppage of the flow, when he strained violently. On admission, there was a dull pain in the bladder most of the time; very severe pain in the end of the penis after micturition; and an occasional mucous sediment. A stone was felt, and on the 28th it was crushed by Dr. H.; the operation being followed by chills. Aug. 9th, a second operation; but nothing of any amount came away. A severe chill followed, and the man died on the 12th; a fine sand having been passing more or less every day from the time of the first operation.

The bladder was contracted into a firm ball, of a dark ash color, upon the inner surface, and contained fragments of the calculus; but these last were mostly in a pouch, that was anterior to the prostate gland, and ulcerated upon the inner surface.

Composition of the calculus, according to Dr. White: phosph. of lime chiefly, with some ox. of lime, and a trace of triple phosph. of ammonia and magnesia. 1869.

Dr. R. M. Hodges.

2680. A large ovoid calculus, and another much smaller; removed from a sac in front of the bladder.

The patient, a laborer, thirty-three years of age, had stricture nine years before, and that was relieved by dilatation; but from that time he had been in the habit of passing, occasionally, an elastic catheter (about No. 5). Nov. 5th there was difficulty of micturition, and a small swelling appeared in the perineum. On the 7th, after a cold ride, the swelling became painful, and from that time increased.

On the 14th he was seen by Dr. J. Spalding, of Lowell. The swelling was then larger than the fist, and the whole scrotum and penis were infiltrated with urine. On the right side there was a urinary fistula, that had existed for nine years, and upon the left side the cicatrix of one that had healed. The bladder was not distended; and every hour or two the man drew off a considerable quantity of urine by the catheter; the flow being quite free when the instrument was passed down to near the membranous portion of the urethra, and it being evident that it did not enter the bladder. The strength and pulse were fair. An incision along the raphé, and just below the scrotum, was followed by a gush of about ξ ij. of urine; and the cellular tissue was found extensively gangrenous. The calculus was then felt firmly imbedded in fibrous tissue; and, the anterior wall of the sac in which it lay being incised, it was with considerable difficulty separated from the walls and withdrawn. At least a pint of urine immediately escaped. A *façette*, showing that there was a second calculus, this last was felt and easily removed. The largest calculus measured $5\frac{3}{16}$ in. in its largest, and $4\frac{1}{2}$ in. in its smallest circumference; diameters of cut surface, $1\frac{3}{4}$ in. by $1\frac{3}{8}$ in. Weight, 740 grs., Troy. Structure compact; and of a light-yellowish color. Distinctly, though not strongly, laminated upon the cut surface; the laminæ being darker than the rest, and quite hard. External surface

generally granulated; but at one extremity there is a smooth, highly polished, and concave surface, being the *façette* above referred to, and at the other a smooth but convex surface, which was explained by the frequent passage of the catheter. The smaller calculus, of which one-half only is preserved, measures $1\frac{3}{8}$ in. in length upon the cut surface, and must have been somewhat pyriform in shape. The nucleus was ox. of lime; color the same as the largest, and the external surface was granulated. The larger calculus consisted mainly of the phosph. and carb. of lime (bone earth), with a considerable mixture of ox. of lime, as shown in the *laminæ*. Analyzed by Dr. D. H. Hayden.

In a note, dated Feb. 7th, 1870, Dr. G. says that after the operation, all of the gangrenous tissue came away, and the wound granulated rapidly; elastic catheters being kept in the bladder for some weeks. About a month ago a small stone was felt in the situation of the former one; very friable; and the fragments, that were removed, not equalling in size a cherry-stone. The man is now in better health than for several years, and able to work. A small fistula remains in the perineum, through which all of the urine passes; but he can retain it for five hours; the stream is of full size, and he only suffers during its evacuation from this mode of passing it. There is still, however, another stone that can be felt by passing a probe into the fistula 4 or 5 in., and that is to be removed by operation.

February 22d, Dr. G. presented the fragments of this last, which were removed on the 20th. They were contained in an irregular sacculated cavity, and weigh, now that they are dry, one hundred and twenty grains. 1870.

Dr. J. Orne Green.

2681. A renal calculus, $2\frac{1}{8}$ in. by about $1\frac{3}{4}$ in. on cut surface; of a dull brownish color; rough and somewhat tuberculated externally; and coarsely laminated internally, with a small, compact nucleus. Analyzed by Dr. White; ox. and phosph. of lime.

From an elderly woman, who for several years had had slight attacks, that increased in frequency and severity

toward the last. There was pain in the loins; and the urine was either very copious, or very scanty in amount. During the last three or four months that Dr. P. attended her she kept her bed; and the urine always contained pus. Over one of the kidneys there was a tumor that would occasionally become much enlarged, and then subside upon the discharge of pus. Death finally from exhaustion. 1869. *Dr. G. W. Pierce, of Leominster.*

2682. A flattened, ovoid calculus, $1\frac{3}{4}$ in. by $1\frac{1}{2}$ in. on cut surface, and having rather a chalky-white look. Concentric structure distinct, but not strongly marked. Externally fawn-colored, and somewhat rough. Consists, according to Dr. White, of ox. of lime, phosph. and carb. of lime, triple phosph. in small amount, and ur. of soda. Central nucleus of lithic acid, of a pale-brownish color, about $\frac{1}{2}$ in. by nearly $\frac{3}{4}$ in.

The patient was a boy, ten years of age, who entered the hospital March 14th, 1862 (101, 120). Occasional attacks of pain in left side, and chiefly about 2 in. above the ant. sup. spinous process of the ilium, with micturition about every thirty minutes, and great pain then in the glans. These pains came on suddenly and violently about four years before; and previously he had been quite healthy. Was able to attend school during a part of the time. General appearance thin and pale.

Removed by incision on the 22d; and on the 30th of April the boy was discharged well. 1869.

Dr. H. J. Bigelow.

2683. Irregular, lenticular, chalky-looking concretion. Phosph. of lime and triple phosph. $1'' 8'''$ by $9'''$. 1847.

Dr. J. C. Warren.

The next four specimens were given in 1800, by

Dr. J. Nichols.

2684. Flattened spherical concretion of phosph. of lime and triple phosph. $1'' 10'''$ in diameter.

2685. Compressed, spherical. Triple phosph. and phosph. of lime. Section shows laminae finely marked, interrupted by crevices apparently. No organic matter present to explain this coloration. $1'' 8'''$ in diameter.

2686. Another flattened, disc-like stone. Triple phosph. and phosph. of lime. Concentric markings like the last. 1" 4'''.
2687. Chalky, oblong concretion. Phosph. of lime and triple phosph. Outer portion arranged in laminae. 1" 4''' by 10'''.
2688. Urethral calculus, from a case of abscess of the prostate, etc. (No. 2876). Form somewhat irregularly ovoid; and measures $1\frac{5}{8}$ in. by $1\frac{2}{8}$ in. Surface fawn-colored, smooth, and toward the large extremity polished to some extent. There is also shown another small stone, that was removed at the same time; $2\frac{1}{2}$ by $1\frac{1}{2}$ lines, flattened, and having both surfaces quite polished, as if by attrition against the large one. The large calculus is evidently phosphate upon the surface; but it has not been analyzed, as, on account of its size, it was desirable to preserve it entire. 1868. *Dr. H. J. Bigelow.*
2689. A calculus from the bladder of a child, who was transfixed by a hay-hook (No. 3116). Examined by Dr. Bacon, who remarked that it was evidently of rapid formation. Length nearly $\frac{3}{4}$ in., and thickness $\frac{3}{8}$ in. Exterior rough, with small tubercular projections. On section, it is seen to be hollow. The shell is about a line in thickness, and is composed of triple phosphate and phosphate of lime, with considerable animal matter. The large cavity within contains only a thin, shrivelled membrane, loosely adherent to the walls, and probably the remains of a slough. 1857. *Dr. J. P. Maynard, of Dedham.*
2690. A few, minute, rounded, compact, white calculi, that were passed from the urethra; the largest about the size of a duck-shot. Surface not rough nor crystalline. "Phosph. of lime, with a little triple phosph.," according to Dr. Bacon. — No. 1339 in the Med. Soc.'s Cabinet were from the same subject; a gentleman, æt. about twenty-five, who was subject to acidity of the stomach, and had often passed such calculi as are here shown, but was otherwise healthy. 1859. *Dr. S. D. Townsend.*
2691. Nucleus is a piece of coal or coke, coated with carb. and phosph. of lime and triple phosphate. 9''' by 6''' . 1847. *Dr. J. C. Warren.*

2692. A calculus from the bladder of a sperm whale. It is perfectly white, of a fine, compact structure, very distinctly laminated; of a tetrahedral form, with well-marked façettes, and about $1\frac{1}{2}$ in. in diameter. A large number of calculi, and very nearly resembling this specimen, were removed from the bladder, and weighed altogether 86 lbs.; one of them was about as large as the two fists. The whale was a very large old male, and so much emaciated as to furnish but very little oil. One of the calculi was analyzed by Dr. C. T. Jackson, and found to consist of the phosph. of magnesia and ammonia, with some phosph. of lime. (See Catalogue of the Med. Soc.'s Cabinet, No. 635.)

One of these specimens was sent to the Hunterian Museum, and is represented in the Catalogue, Plate 17, fig. 6. 1868. *Soc. for Med. Improvement.*

2693. Elongated concretion, 1 in. in length, and about $\frac{3}{4}$ in. on cut surface. Phosph. and carb. of lime. Renal. Nucleus eccentric. 1800. *Dr. J. Nichols.*

2694. An irregular calculus, and renal without doubt. Phosph. and carb. of lime, and triple phosph. 2'' by 1''. 1800. *Dr. J. Nichols.*

2695. Renal calculus; very irregular. Phosph. of lime, carb. of lime, and triple phosph. of ammonia and magnesia. 1800. *Dr. J. Nichols.*

2696. Fragments of a calculus, removed from the bladder after death. (Hospital, 67, 184.) The patient, a man, æt. thirty years, had had very urgent symptoms, and more or less for eighteen years. Lithotrity was performed by Dr. B., Oct. 13th and 18th, Nov. 10th and 24th, and Dec. 15th. At the first operation the calculus was reported as large. Death occurred on the 11th of March. Bladder and kidneys much inflamed. The fragments are from the size of a small bean to that of a pigeon's egg, and irregular in shape; the rough surfaces being smoothed by attrition, and partly by phosphatic deposit. One of the calculi examined by Dr. Bacon, and found to consist essentially of triple phosph., with phosph. of lime, carb. of lime, and a considerable amount of organic matter. 1857.

Dr. H. J. Bigelow.

2697. Urethral calculus, $\frac{3}{8}$ in. in diameter, and rather more than $\frac{1}{2}$ in. long; of a whitish color; an irregularly flattened form, and granulated upon the surface. Composition, probably, according to Dr. White, phosph. and carb. of lime. No urates. 1869. *Dr. H. J. Bigelow.*

2698. Fragments of a large stone that were discharged within twenty-four hours, and after a single operation. None of them are large, and much of the material is a mere white powder. Composed, according to Dr. White, of carb. of lime, phosph. of lime, and a little phosph. of ammonia and magnesia. It contained also a large amount of oil and animal matter. The patient was entirely relieved. 1869. *Dr. H. J. Bigelow.*

2699. A calculus removed by the lateral operation. A considerable portion has been broken away; and the remainder, excepting a coarse powder, consists of a hemispherical, whitish mass, nearly 2 in. in diameter, and 1 in. thick; smooth, but somewhat porous on its convexity, and quite rough on the broken surface; structure coarse and crumbling. Dr. Bacon's analysis: phosph. of lime and triple phosph., carb. of lime, carb. of magnesia and animal matter: The stem of a plant forms the nucleus.

From a man, æt. twenty-one years, and a resident of this State. Entered the hospital Feb. 7th, 1861 (93, 226). Nine years previously he fell astride of a rail fence, but did not seem to have hurt himself much. Four years before entrance, an abscess formed near the anus. This never healed, and during the last six months others had formed in the perineum. This last became fistulous, and after a while urine passed through the opening. His general health became much reduced, with great suffering, and the presence of calculus was ascertained. Feb. 9th the operation was performed; the stone being much broken up; and on the 15th of Aug. he was discharged, much improved; though some urine still passed by the wound. 1861.

Dr. H. J. Bigelow.

2700. An irregularly ovoid calculus, whitish, compact, and granulated over most of its surface; weight, $3\frac{1}{2}$ oz.; diameters about $2\frac{3}{4}$ in., $1\frac{5}{8}$ in., and $1\frac{7}{8}$ in. Also a second, about

as large as the top of the thumb; a marked concavity corresponding to a convexity upon the first.

From a woman, *æt.* twenty-eight years, who had had symptoms of disease for thirteen years, and urinary fistula in the groin for the last two. Dr. J. S. Ross, of Great Falls, N. H., who sent the specimen, with a full history of the case, to Dr. Bigelow, was consulted, and found her in a most distressing and loathsome condition; greatly reduced in flesh and strength, and confined to the bed, which was saturated with urine. On pressure over the bladder, a stream of urine, with mucus, could be forced upward 6 in. from the fistula in the groin. Vagina, and external surface for some distance much inflamed, and very sensitive. The calculus was perfectly immovable, under the arch of the pubes, and seemed to occupy the greater part of the pelvic cavity. Feb. 25th, 1861, an attempt was made, under ether, to remove it, when it broke, and the large mass was easily extracted. The small calculus was then felt in the bladder; and, the finger being passed through the dilated urethra, it was removed; there being no other opening between the bladder and the vagina. After the operation the inflammation very soon subsided, the fistula had closed on the ninth day, and on the twenty-third day she walked three-fourths of a mile without inconvenience; and the following November she was quite fleshy, in perfect health, and entirely relieved of her former troubles.

Dr. Bacon's analysis of the calculus: triple phosph., with traces of phosph. and carb. of lime, and the usual organic matters; but no ur. ac., urates, nor ox. of lime. 1861.

Dr. H. J. Bigelow.

2701. Two small, oval, flattened calculi, about $\frac{1}{2}$ in. in length, and that were passed from the bladder, in a case of fracture of the spine, with several others at different times. Composed, according to Dr. White, of the phosph. and carb. of lime, with triple phosphate of ammonia and magnesia. 1869.

Dr. J. S. Jones.

2702. A calculus, from a case of complete prolapse of the uterus. (No. 2736.) It is of a regular, oval form, $1\frac{1}{8}$ in. by $1\frac{1}{16}$ in., light-colored, soft, not at all laminated, and

consists, according to Dr. Hayden's analysis, of the earthy phosphates. Also a second and probably similar calculus, 6 by 3 lines. 1870. *Dr. H. H. A. Beach.*

2703. Over six hundred very small, cream-colored calculi, from the bladder of an ox. Examination by Dr. Bacon. "The largest measures about a line in diameter. Nearly all are regularly spherical, with a smooth surface. They are sufficiently hard to scratch flint glass. Some exhibit indistinct concentric layers, but no crystalline structure occurs in any. On chemical analysis, by Dr. Bacon, they are composed of silicic acid chiefly; with a little animal matter, partly fat; a little chloride of potassium, and traces of other potash and soda salts. Boiling nitric acid slowly penetrates the calculi, and dissolves out the organic and saline matters, rendering them translucent. After this treatment, they retain the original form and hardness; and when washed and dried are quite white, and consist of pure amorphous silex. The specimens in the tube-vial exhibited have been thus treated. — Traces of silex occur in the normal urine of the ox and various other animals, and have also been found in that of man; but genuine siliceous calculi are of exceedingly rare occurrence." 1857.

Dr. J. B. S. Jackson.

2704. A calculus from the urethra of an ox, that caused retention of urine, and finally rupture of the bladder. Examination by Dr. Bacon: "The calculus weighs $8\frac{1}{2}$ grs., and measures 7 lines by 3, being of an irregular shape. It is slightly tuberculated, and is mostly covered by a thin, smooth crust, like a glaze. This has a peculiar semi-metallic or iridescent lustre, and is made up of several very thin laminae. The interior, so far as exposed, is composed of thicker layers, of a whitish color.

"Portions from the shining crust, and from layers near the surface, were analyzed. They consist of carbonate of lime chiefly, with silicic acid, phosphate of lime, and organic matter. The silica forms the principal constituent of some of the laminae, and is not found in others." 1860.

Dr. J. H. Blake, of N. Auburn, Me.

In the *Med. Jour.* Vol. LXIII. p. 40, another perfectly

similar case, in regard to its history, is referred to, and that was observed by Dr. O. Martin, of Worcester; and in the Catalogue of the Med. Soc.'s Cabinet (No. 1396) a third is reported.

In the same Journal (Vol. LXIV. p. 417) is an article on siliceous urinary calculi, by Dr. John Bacon, in which he refers to the presence of silicic acid, as a normal condition in man, and the lower animals, quoting several cases from authors, besides two (Nos. 645 and 1396) from the Med. Soc.'s Catalogue, and finally concludes that "siliceous calculi are not so extremely rare as has been hitherto supposed."

Renal calculi, Nos. 2463-6, 2558-9, 2618, 2620 (?), 2677, 2681, 2693-5.

Urethral, Nos. 2662-6, 2688, 2690, 2697, 2701.

Removed by lithotomy, Nos. 2561, 2609-10, 2617, 2619, 2651, 2659, 2661-2, 2679, 2682, 2699; and by other operations, Nos. 2560, 2639, 2660, 2669, 2679-80, 2698, 2700.

From animals, Nos. 2569 (?), 2615 (?), 2668, 2692, 2703-4.

SERIES XXXV. — FEMALE ORGANS OF GENERATION.

I. OVARIES.

2705. A defined abscess in the ovary, that contained an ounce of thick pus; cut open, and shows the inner surface thinly coated with lymph. Near it is a second cavity, about as large as the top of the little finger, that did not contain pus nor blood, though red inside, and having a free and ragged opening into the peritoneal cavity. This last contained eight or ten quarts of sero-purulent fluid, with lymph; the inflammation being marked about the ovary, and attributed to the rupture of the small cavity.

From a young woman, who had had derangement of the menstruation for several months; looked pale and hag-

gard, had swelling of the abdomen, and who was suspected to have had some operation done, or taken some medicine, with a view to abortion; there being nothing, however, on dissection, to show pregnancy. The latency of the peritonitis was most remarkable; the girl having driven out frequently, and even, as Dr. R. thinks, danced through the evening at a party, a week before her death, and walked half a mile on the last day. At 9 P.M. she went to bed as usual, was restless and very thirsty in the night, and complained of feeling sick. In the morning she was found unconscious, and soon died. 1868.

Dr. J. M. Rice, of Worcester.

2706. One, large, unilocular cyst; and without a trace of a second. — From a woman, æt. thirty-five years; married about eight years. Abdomen enlarged much before that time; and with much increase the last two months. One child. Kept about until a week before death.

The sac contained nearly two and a half pailfuls, of a thin fluid, deeply colored with blood; and with a great quantity of soft, old lymph. Parietes generally thick and dense. Inner surface opaque, rugous, and had almost a cutaneous look, though no true skin was seen. Extensive old, peritoneal adhesions. Left ovary well. 1861.

Dr. J. B. S. Jackson.

2707. An ovary about the size of a small hen's egg, and much resembling a figure in Mr. Paget's work on tumors. There are three cysts in juxtaposition, and two of them are just beginning to show the proliferous tendency. Smaller cysts are also seen in other parts of the organ. 1861.

Dr. J. B. S. Jackson.

2708. Multilocular cyst, about the size of a goose-egg. The other ovary was similarly diseased, except that one of the cysts was as large or larger than the fist.

From a woman, æt. sixty-nine years, who was attended eighteen years ago by Dr. Wm. J. Walker, for ovarian disease. She had had a tumor from that time; and, during the attendance of Dr. S., it was about the size of an orange. The arrest of the growth of the tumor is an interesting practical fact. 1862. *Dr. D. H. Storer.*

Encysted disease of both ovaries. (See No. 2772.)

2709. An ovarian cyst, about 2 in. in diameter, cuticular upon the inner surface, and with hair growing from it. The cavity was filled with hair; and with fat, which seems always to be found with it.—From a healthy, single woman, æt. forty-five years. (Hospital, 228, 88.) 1860.

Dr. C. Ellis.

2710. Hair from the above cyst. 1860.

Dr. C. Ellis.

2711–12. An ovarian cyst, containing bone, teeth, etc.

From a middle-aged, dissecting-room subject. It was about two-thirds as large as the fist, and was filled with a soft, yellowish, fatty substance, with which was mixed a large quantity of loose hair. Upon the inner surface there was to some extent a pretty well-marked coarse cutis, with some remains of cuticle, but only a single hair was found attached. Near the skin, and just beneath the inner surface of the cyst, was a piece of bone, $1\frac{1}{2}$ in. long, in connection with which were two teeth. Two or three quite small cysts were connected with the larger one. The other ovary, upon the left side, was about half as large as the above, and consisted of a number of cysts, all of which contained fat, and in one of which there was hair, with traces of skin, but nothing further.

Dr. D. W. Cheever.

Hair from the above cyst. 1861.

Dr. D. W. Cheever.

2713. A very irregular piece of bone, and four smaller pieces from an ovarian sac; dried. Two of these last contain the crowns of one or two molar teeth; and five other crowns are shown that were separated in preparing the specimen. 1868.

2714. Two pieces of bone, that were attached, near to each other, by a small but firm fibrous band, to the interior of an ovarian sac, and that contain numerous teeth. One is 3 in. in length, and about 1 in. in diameter. The other is about 2 in. by $\frac{1}{2}$ in.; but the form of both is quite irregular. The teeth are nearly all of them firmly implanted in the bones, and consist of molars and incisors, with some that cannot very well be named. The largest bone contains seventeen teeth, and the smallest thirteen; and they are arranged in each in two compact groups.

The sac, which has been distended and dried, shows an extensive cretaceous deposit in the parietes. In the recent state it weighed 2 lbs., and contained 20 lbs. of a dark, thick, chocolate-colored liquid. There was mainly one cyst, but with some divisions.

The patient was a single woman, thirty-one years of age; had known of the disease for about ten years, and had been as large as at the ninth month of pregnancy for a year or two. She was generally healthy, had never been tapped, and bore the disease well. May 31st the cyst, which was not adherent, was removed by Dr. K., and the patient died about the fifth day from peritonitis. 1869.

Dr. Gilman Kimball, of Lowell.

2715. The cyst, from the above case; dried. 1869.

Dr. Kimball.

2716. A quantity of hair that was very positively stated to have been taken from the urinary bladder; lying in it quite free, and the organ itself being perfectly healthy. When received it was in a liquid that was removed with it, and that resembled a thick mucilage, with a mixture of a substance, that resembled, but was shown by Dr. Bacon not to be fat.

The patient, an unmarried woman, sixty-two years of age; died of a chronic peritoneal disease, of ten months' duration, and the bladder had never been suspected. "The uterus and its appendages were apparently in a healthy condition."

In the Cabinet of the Soc. for Med. Improvement there is an ovarian sac containing a very large mass of hair adherent to its interior. The case was published as one of development of hair in the urinary bladder; and there can be no reasonable doubt that a similar mistake was made in the above case; and, still further, these are probably not solitary instances. 1869.

2717. Both ovaries encysted and acutely inflamed.

From a woman, *æt.* forty, and previously healthy. On the morning after her marriage she had symptoms of severe inflammation; and in three weeks (Nov. 19th) entered the hospital (99, 416) with a firm, painful, tender, fluctuating tumor, that almost filled the left side of the abdomen.

The whole of the right side was tender and tympanitic. Constitutional symptoms grave. One pint of fetid pus was drawn off from the left ovary on the 22d; three and a half pints from the right on the 24th; and on the evening of that day she died.

Pus, with recent lymph, was found in both cysts. 1862.

Dr. H. J. Bigelow.

2718. An ovarian cyst, that was supposed to have ruptured several times, and at last filled the peritoneal cavity with a secretion from its inner surface.

The patient was unmarried, fifty-four years of age, and had always been quite healthy, though of very sedentary habits. About five years before death the catamenia ceased, and she very soon afterward had the first of several attacks which were thought to warrant the above diagnosis. A rounded, hard, smooth tumor would appear in the region of the left ovary, without tenderness or pain, but with a general feeling of indisposition. In the course of a week or two the tumor would suddenly disappear; a soft, diffused swelling across the hypogastric region would follow; and she would almost at once be seized with universal cramp-like pains and retching. The pains were so severe, that she would sometimes fall upon the floor when the attack came on, but in the course of three or four hours they would subside. The retching would continue for about the same time, but with little or no vomiting, and the hypogastric swelling would gradually subside; the whole attack lasting from about two to four weeks. At first the tumor was about the size of a small apple, but it enlarged somewhat with each attack.

About three years before death, having altogether had six or seven attacks, the character of which was very similar, she had the last, and this was by far the most severe. The tumor enlarged to the size of a pint bowl, and it did not burst for two or three months, but the exact time at which the rupture took place was most satisfactorily indicated. She was awakened from her sleep by a sensation as if she had been slapped with the hand upon the tumor, and at once this last disappeared. She then awoke her sister, told her the circumstances, and said that she felt as

well as she ever did. In a few minutes, however, she was attacked with the usual symptoms, which, as above stated, were more severe than ever before, — the swelling of the abdomen continuing for some weeks.

In the autumn of 1857, enlargement of the abdomen commenced without the precursor of an attack, and from that time it went on increasing; but it was only during the last few months that it would have been noticed when she walked abroad. She lost flesh and a great deal of strength; but she was able to do some work as a tailoress, was never confined to her bed, and walked out within three or four weeks of her death, which occurred in Dec., 1858. There never was any return of the general pains, and over the abdomen her only complaint was of a sense of weight. The appetite was good, to the last, except during the attacks; bowels generally well; urine scanty and turbid. Œdema of feet for the last two months. An hour or two only before her death she said that she felt very sick, but made no especial complaint, and had then only just left her sitting-room. She was never tapped.

On dissection, the peritoneal cavity contained, by estimate, six or seven gallons of a very viscid substance, that was compared, at the time, to soft soap. A stout, muscular man, who was in the habit of lifting heavy weights, undertook to remove the tub that contained this substance, but found it too heavy; and on setting it down, said that he should estimate the weight at 200 lbs. In the place of the left ovary, was a mass of disease that appeared very satisfactorily to consist of a cyst about as large as the two fists. This cyst had been lacerated throughout the greater part of its extent; the edges of the laceration apparently cicatrized, and being quite distinct. Its interior was made up of cysts, generally from 2 to 4 lines in diameter; and from it there hung off a secretion which was somewhat clear, but altogether too viscid to be removed without great difficulty. The serous surface of the cyst had, in some parts, a dark-brown discoloration; and, in others, a brilliantly glistening and silvery appearance, which Dr. Ellis found to be owing to cholesterine. The spleen was quite small, and the investing membrane thickened and opaque, with

much of the silvery appearance just referred to. Otherwise the organs were healthy, so far as observed. 1859.

Dr. J. B. S. Jackson.

2719. Fundus of the uterus, from a seven months' fœtus, with the ovary, and showing a small cyst in this last. 1869.

Dr. J. B. S. Jackson.

2720. A multilocular ovarian cyst, removed during life; result fatal.

The patient was nineteen years of age; the abdomen had been enlarging for two years, and she had been tapped seven times. An exploratory incision was made on the 20th of June, and the tumor was removed by Dr. B. on the 4th of July. An incision was made from the ensiform cartilage to the pubes; some adhesions were found, and eighteen pints of fluid were removed from the sacs that were punctured. Death on the evening of the 24th; and, on dissection, about 3x. of blood were found in the peritoneal cavity, but no inflammation. (Med. Jour. Vol. LXI. p. 19.) 1859.

Dr. Chas. E. Buckingham.

2721. A multilocular cyst, successfully removed. The tumor was of about two years' duration, so far as was known, and weighed, with the contents, 34 lbs. The patient recovered rapidly, and without a bad symptom. (Med. Jour. Vol. LXVI. p. 445.) 1862.

Dr. Wm: G. Breck, of Springfield.

2722. Ovarian tumor, removed during life; recovery from the operation.

The patient was a healthy married woman, æt. fifty-nine years. In Feb., 1863, there was a slight fulness of the abdomen, with a reddish discharge from the vagina, that recurred at regular monthly periods for six months; menstruation having ceased nine years before. In June the abdomen was greatly distended, and the legs œdematous. In August several gallons of fluid were drawn off, and the tumor was then felt. Dec. 17th a second tapping. Jan. 3d, 1864, the tumor was removed by Dr. C.; an incision being made from the umbilicus to the pubes; and the ascitic fluid being first removed. The peritoneum was very much thickened, reddened, and granulated. Feb. 4th the wound had healed, and the patient was about her room.

The tumor weighed $2\frac{1}{2}$ lbs.; but, with the fluid that was removed from it, it was estimated at 8 lbs. It consisted mainly of two or three large cysts, the inner surface of which was everywhere covered with a soft fibrinous substance, mixed with a thick puriform fluid. The appearances were suspicious, but "nothing decidedly cancerous" was found microscopically. (See *Med. Jour.* Vol. LXX. p. 89.)

For more than a year the patient was quite well, and gained 40 lbs. of flesh, with disappearance of the ascites and œdema. In the spring of 1865 she was much chilled by exposure to a cold rain, sickened from that time, and died in Jan. 1866. The ascites returned, and she was tapped four times; for the first time in July, after which a tumor was felt, that proved, on dissection, to be a large and well-marked cancerous development of the right ovary, which was healthy at the time of the operation. The uterus and other organs were healthy; and the peritoneum much more healthy than at the time of the operation. 1866.

Dr. H. G. Clark.

2723. Fibrous disease of the ovary. It forms a pretty regularly oval mass, about 4 in. in length, 3 in. in width, and 2 in. in thickness; has a fine fibro-cellular structure, and is as dense as if scirrhus. Microscopically, nothing was found but fibrous tissue.

From an old woman, of whom very little was known. The other organs were healthy. In the *Med. Soc.'s Cabinet* (No. 682) is an ovary, very similar in appearance, and as large as a small muskmelon; from a cancerous subject. 1861.

Dr. Sydney H. Carney.

2724. Both ovaries, removed during life. They are of an oval form; one being 8 in., and the other $5\frac{1}{2}$ in. in length. Structure fibrous. Firm to the feel in the recent state, though everywhere infiltrated with serum. Many firm granulations were seen upon the surface, and a number of reddish nodules, from a quarter to half an inch in diameter; a cyst, about $\frac{1}{2}$ in. in diameter in one, and a little pus in the other.

The patient, a married woman, æt. thirty-six years, was quite well until April, 1859, when the catamenia ceased,

the abdomen enlarged, with nausea, and she was thought to be pregnant; the enlargement increasing so as to cause great dyspnœa. Sept. 25th Dr. S. saw her, and found her in bed, much emaciated, with an anxious countenance, and two distinct, firm, and movable tumors in the lower part of the abdomen, one upon each side of the median line. There was also ascites. As ballottement was very distinct, he regarded it as a case of pregnancy; and, having decided upon premature delivery, a sound was passed, and the uterus found empty. The diagnosis was then uncertain; but, upon the presumption of extra-uterine gestation, and with the full sanction of Dr. J. M. Warren, the tumors were removed on the 3d of October by abdominal incision. The operation was done with great ease, and scarcely an ounce of blood was lost. For thirty-six hours the patient did well; but peritonitis then came on, and she died on the third day. (Case published in full, with remarks, in the *Med. Jour.* Vol. LXi. p. 325.) 1860. *Dr. D. H. Storer.*

2725. An osteoid tumor, connected with, but apparently not of the ovary; hard and compact for the most part, but not true bone, microscopically. One-half of the tumor is here shown; and it seems to have been of a regular, ovoid form, and about 2 in. in length. In the ovary was a cyst that contained about $\frac{3}{4}$ of serum, and the other ovary was somewhat diseased. — From an Irishwoman, about thirty-five years of age, who died in a drunken affray. 1867.

Dr. J. G. Park, of Worcester.

II. FALLOPIAN TUBES.

2726. Spontaneous rupture.

From a woman, æt. nineteen years, of loose habits, and who died with symptoms of internal hemorrhage after eight or nine hours' sickness. The peritoneal cavity contained about two quarts of blood. In the upper posterior part of the left tube, midway, is a laceration through its entire thickness, about $\frac{1}{4}$ in. in length, and from which, in the recent state, there hung a coagulum. The tube is not enlarged, and neither was the uterus; nothing like an ovum being anywhere found. A large spurious corpus luteum was found in the left ovary, and a smaller one in the right;

menstruation being daily expected at the time of death. (Med. Jour. Vol. LXIV. p. 249.) 1861.

Dr. Lincoln R. Stone, of Salem.

2726½. Dropsy of the Fallopian tubes. The fluid having been removed, the tubes were inflated and dried, with the uterus, and they are now about 5 in. in diameter. The fluid was examined by Dr. Bacon, and found to be feebly alkaline, moderately albuminous, and of a spec. grav. of 1.011. 1867.

Dr. J. B. S. Jackson.

2727. Tube enlarged by tubercular deposit upon the inner surface. 1855.

2728. A cyst, about the size of a hen's egg, connected with the tube. 1847.

Dr. J. C. Warren.

2729. The uterus of a strumpet, showing the obliteration of the ends of the tubes, and the old adhesions about the ovaries that are so common in these persons. 1864.

Dr. J. B. S. Jackson.

III. UTERUS.

2730. Elongation by the growth of a large ovarian tumor; and particularly drawn upon about the origin of the right Fallopian tube; this being the side upon which the disease was developed. Its length was 5 in.; and the os uteri so nearly effaced that the cavity of the womb and that of the vagina seemed almost continuous. (Hospital, 70, 250; and Med. Jour. Vol. LV. p. 407.) 1858.

Dr. C. Ellis.

The elongation of the organ, as shown by the uterine sound, is often regarded as one of the diagnostic marks of fibrous tumor; but it is not by any means always found; whereas, it not very unfrequently is found in ovarian disease.

2731. Anteversion. The organ is completely doubled upon itself; a thread having been passed through to keep it in the position in which it was originally found. Not at all enlarged.

From an unmarried woman, æt. twenty-eight, who died of disease of the stomach (No. 2200) in 1863, and who had had amenorrhœa for some time, but without any other uterine symptoms, so far as known. (Hospital, 250, 216.) 1863.

Dr. J. B. S. Jackson.

2732. Excision of a large portion of the uterus, for inversion.

The patient was married at the age of nineteen, had one child within the year, and about two or three months afterward discovered a protrusion of the organ through the vulva. Menstruation gradually became very profuse, and, in the course of three years, she became so reduced that Dr. S. did the operation as a means of saving her life. For the first year her health decidedly improved; but after a while it began to fail, with symptoms of suppression of the catamenia, and she died five years after the operation, of tubercular disease.

Dr. Wm. H. Thayer, of Keene, N. H., examined the body, and published the result, with a general history of the case, in the Berkshire Med. Jour. (Mass.), Sept., 1861. A portion of the cervix remained; and the Fallopian tubes, that arose from a single point, were entirely obliterated to the extent of a few lines from their origin. The ovaries were quite natural, and contained several corpora lutea. In the preparation, the organ has been cut through, and shows the peritoneal surface to some extent. 1856.

Dr. D. H. Storer.

2733. A large portion of the uterus, removed by the écraseur, for inversion. Length about $2\frac{1}{2}$ in., and thickness of the fundus about $1\frac{1}{2}$ in. An incision, along one side, exposes the serous surface, with a portion of the Fallopian tubes and broad ligaments, and shows the absence of adhesions.

The patient, æt. forty-three years, had had three children, and the last five years ago. The catamenia had been frequent and profuse during lactation, and for the last two years constant. When first seen, two days before the operation, she was perfectly blanched and very weak; and the globular, inverted organ was felt in the vagina. No blood was lost during the operation; but a few hours afterward the patient complained of pain and tenderness of the abdomen, soon became pulseless, and died in twenty-four hours after the removal of the organ. Autopsy by Dr. E. 1864.

Dr. C. Ellis.

2734. Hypertrophied os and cervix uteri excised; and weighing between 5 and 6 ounces after being steeped in alcohol.

The patient, a negress, had her first child in 1835; her second in 1838, and two months afterward the tumor protruded from the vagina. In 1845 a miscarriage at the fifth month. In 1846 a child was born at the full term, though the tumor was external during the entire term of pregnancy and parturition. In 1848 a miscarriage at five months; and the next year two in the third month.

In 1860 she came under Dr. M.'s care, with severe and increasing dysmenorrhœa; the tumor being about three-fourths as large as at the time of operation. After trying various expedients, a linen bag was found to be the most serviceable, and this she ever afterward wore; any attempt to return the tumor within the vagina causing great distress. During about a third part of each year she was obliged to give up work, keep her bed, and use opiates, etc. Dr. M. intended to remove the protruding mass when menstruation should cease, but it was found impossible to delay the operation, and it was therefore done on the 29th of May, 1861. The protrusion then was from $4\frac{1}{2}$ to 5 in. beyond the labia, and the diameter of the mass about $3\frac{3}{4}$ in.; a catheter passing in $8\frac{1}{4}$ in. Around the os were five large ulcers. The *écraseur* and the knife were both used, and the mass was removed about $2\frac{3}{4}$ in. from its extremity. The hemorrhage was not great; and after the operation the cut surface, within the vagina, resembled a hollow cone. The patient did quite well, and was soon up and about. Three months after the operation, however, she had a very severe attack, owing to a closure of the uterine canal, and a retention of the catamenia. An opening was made; and twice afterward it was necessary to repeat the operation. At the date of Dr. M.'s report of the case (Oct. 26th, 1862) the length of the uterine cavity was $4\frac{1}{2}$ in., and the patient was quite comfortable. Menstruation regular; and ceased about the year 1867, at the age of 60 years.

The large size of the os uteri shows how impregnation must have been effected. — *Med. Jour.* Vol. LXVII. p. 349. 1862.

Dr. Henry A. Martin.

2735. Cast of the above protruding mass, taken just before the operation. (See last case.) 1862.

Dr. H. A. Martin.

2736-7. Casts of a case of complete prolapse of the uterus; the organ projecting about 5 in. beyond the labia; and the Fallopian tubes are drawn down between the rectum and bladder, as in a case figured by Cruveilhier (*Anat. Path. Liv. xvi*). The ovaries are still about in place. External and pelvic view. The bladder contained a calculus (No. 2702).—From a dissecting-room subject. See No. 3677. 1870. *Museum Fund.*

2738. An abscess in the broad ligament, opening into the uterus, and causing death three weeks after labor. This last was natural; but there was hemorrhage before the head descended, and several times subsequently, and under the loss of blood she sank. During the first few days she had pain in the right iliac region, and after the 12th a tumor there; but the indications of disease were very little marked; and it was thought possible that the disease may have existed before labor. Dr. Cheever, who attended the patient, and sent the specimen to Dr. B., found the abscess upon the right side, and with an opening that would admit the finger half an inch inside of the os uteri. The cavity contained much pus, fresh blood, and was 3 or 4 in. in extent, with other, circumscribed sinuses in the broad ligament, and an infiltration of dense lymph in the surrounding cellular tissue. Peritoneum ecchymosed, but not inflamed. Uterus sufficiently well. 1858.

Dr. H. I. Bowditch.

2739. A defined abscess in the substance of the posterior walls of the cervix uteri, capable of holding two or three drachms, and filled, when recent, with thick pus. The surrounding parts are healthy.

From a woman, *æt.* twenty-five years, who had always had dysmenorrhœa, and died a few weeks after confinement. The vagina had been extremely sensitive, the os uteri normal, and the cervix enlarged, tender, soft, and obscurely fluctuating. (Case, with remarks, in the *Med. Jour.* Vol. LXX. p. 69.) 1864. *Dr. H. R. Storer.*

2740. A large circumscribed, peritoneal abscess between the bladder and uterus.

The patient was a slender woman, *æt.* thirty-seven. In March, 1861, her husband was sick, and she nursed him

constantly for eight weeks. Menstruation at this period ceased on the second or third day; and immediately afterward a tumor appeared quite suddenly above the pubes, with very little local or constitutional disturbance. April 25th Dr. P. saw her, in consultation with Dr. C. D. Cleveland. The tumor was then of a globular form, about the size of a small foetal head, slightly elastic, and not hard, nor tender on pressure. A soft tumor was felt in the upper part of the vagina, and upon the back of it the os uteri appeared as a semilunar slit. The appetite was good, and she did not look sick. July 13th there was more local and constitutional disturbance; the vaginal tumor was about 6 in. in diameter, and more prominent; and, being opened, discharged about ξ viii. of thick, yellow, inodorous pus. Aug. 29th the tumor above the pubes "felt like a foot-ball." Opened per vag., and discharged four quarts of pus, of rather disagreeable odor; the parietes of the abscess collapsing so as nearly to efface the cavity. From this date the discharge of pus was constant until her death in Nov. 1862; menstruation being regular during nearly the whole time.

The abscess was very defined and regular; and, though empty, was capable of holding from one to two pints; parietes dense; inner surface quite dark and knobbed, and looked as if an adventitious mucous membrane were forming; a minute opening, from the puncture, is seen in front of the uterus, which is considerably enlarged. (See *Med. Jour.* Vol. LXIX. p. 59.) 1863. *Dr. C. G. Putnam.*

2741. A large multilocular cyst, developed in the parietes of the fundus of the uterus.

The patient was an unmarried, light-mulatto woman, æt. thirty-three years, and resided in the West Indies. In 1856 she had "typhoid fever" twice. During convalescence from the second attack she was very much frightened by a lunatic, had excessive uterine hemorrhage, and the abdominal tumor was then discovered. From that time she was confined mostly to her bed or a couch, and became greatly reduced in flesh and strength, with nausea and vomiting. Catamenia suppressed at first, but throughout her sickness she had an irregularly recurring menorrhagia,

with a continuous, excessive, and peculiarly offensive discharge. In 1858 she was tapped as for ovarian dropsy. In July, 1860, she arrived in this country, much exhausted. Jan. 15th, 1861, she became suddenly worse; on the 17th she was tapped — the distention being enormous; and on the 19th she died.

The cavity of the abdomen contained about sixty pints of fluid. The tumor, which rose as high as the umbilicus, and adhered to the anterior parietes, was made up of exceedingly delicate cysts, from the size generally of a walnut to that of a foetal head, and filled with a gelatinous or thin serous fluid. The uterus is about 4 in. in length, and the tumor arises directly from the fundus; the parietes between its cavity and that of the cysts being as healthy as in any other part, though diminished by one-half in thickness. To a considerable extent the parietes are continued over and gradually lost upon the surface of the cysts; and in some places small cysts are developed in this expanded portion of the uterus. There is no appearance of cancerous disease, nor any fibrous tumors in the womb. Ovaries large, but otherwise not remarkable. (*Med. Jour.* Vol. LXIV. p. 305.) 1861.

Dr. A. W. Thompson, of Northampton.

2742. Thibert's model. A pedunculated polypus, arising from the fundus of the womb, and enclosed in the neck. Also a small fibrous tumor in the parietes of the fundus; and an encysted disease of the left ovary. 1847.

Dr. G. Hayward.

2743. The uterus is cut open, and shows a polypus arising from the fundus, by a long and slender peduncle, and bulging to about the size of the end of the thumb, at the os tincae. The organ itself is considerably enlarged.

The case occurred in the practice of Dr. J. M. Warren, from whom the following history was obtained. — The patient was a woman, fifty years of age. Catamenia irregular for some years before it ceased. Occasional uterine hemorrhage for about a year before her death, and once or twice to a great amount; the discharge being at times very offensive. Always more or less pain, and sometimes very severe. About six months before death a tumor was

found, completely filling the cavity of the vagina, but this afterward entirely disappeared. She sank at last under an abscess in the right iliac fossa. 1847.

Dr. J. C. Warren.

2744. A tumor, about as large as the top of the finger, of a flattened form, and attached broadly to the fundus and upper part of the body. Organ well. 1864.

2745. A smooth, firm, and pedunculated tumor arises from just above the cervix; and the lower extremity, which bulges to the size of the end of the finger, just appears through the os uteri. Organ well, excepting one or two small fibrous tumors at the fundus.

The patient was about forty-nine years of age, and had had a polypus removed about twenty years before her death. For several years she had lived in the family of a physician, but he had never heard of any uterine trouble. 1860.

Dr. F. S. Ainsworth.

2746. A tumor, nearly the size of two fists, arises extensively from the cervix, hangs into the vagina, which is much distended, and is intimately adherent to the os tinæ, excepting an opening of 3 or 4 lines; the outline of the os, however, being sufficiently marked. Form rounded, and structure indistinctly fibrous.

From a woman, æt. thirty-six years, who had had five miscarriages, with considerable hemorrhage; and two children at the full period. The last labor, which occurred in 1850, was preceded by dangerous hemorrhage, as the placenta was over the mouth of the womb. From this she recovered well, but some months afterward hemorrhage came on, and continued more or less at intervals until her death in 1854. During the last fifteen months she was under the care of Dr. G., perfectly blanched, and mostly confined to her bed. Examinations always caused hemorrhage; but the tumor was never painful nor tender, and caused no sense of bearing-down, nor dysuria, so that the patient was hardly conscious of its presence. The catamenia were regular, and entirely without pain, though sometimes attended with hemorrhage; the most severe hemorrhages generally occurring a week or two after the flow had ceased. 1857.

Dr. Samuel Gregg.

2747. A uterus, showing two polypi arising from the centre of the fundus, close together, and remarkably symmetrical. In the recent state they were nearly an inch in length, about $\frac{1}{3}$ in. in diameter, and of a deep red color. — From a woman, æt. fifty-five, who had had occasional flowing for five years, and died at last from cancerous disease of the ovaries. 1869. *Dr. Benjamin Cushing.*

2748. A regular and somewhat oval tumor, 12 in. in circumference, and $2\frac{1}{2}$ in. where it was attached to the inner edge of the os uteri. The surface is smooth, the structure tough, uniform, fibro-cellular, and, in the recent state, it was distinctly vascular.

The patient was thirty-five years of age, had had a bearing-down sensation, with dysuria for three or four years, and of late an occasional slight hemorrhage. The tumor, which filled the entire pelvis, was removed by the écraseur, and less than an ounce of blood was lost. In ten days the patient was about her house, and she soon recovered. 1863. *Dr. D. H. Storer.*

2749. A polypiform tumor, removed by the écraseur; of a globular form, smooth upon the external surface, and weighing 4 oz. Structure shown on incision.

The patient had had profuse menorrhagia for years; became perfectly anæmic, and was thought by her physician to be dying when the operation was done by Dr. S., who saw her in consultation. Recovery complete. 1866.

Dr. H. R. Storer.

2750. A uterine polypus, tough in consistence, and that much resembled a common fibrous tumor. Form that of a regular, flattened sphere, $1\frac{1}{2}$ in. in diameter, and $\frac{3}{4}$ in. in thickness; with large blood-vessels upon the cut surface.

From a married woman, æt. thirty-three years, who was anæmic from the constant and often severe hemorrhages to which she had been subject. Duration of the disease four years. The tumor was in the vagina, and was removed with Simpson's polypome; not more than ζ i. or ij. of blood having been lost. The pedicle was surrounded by the os uteri, and receded, after the operation, so as not to be felt. Menstruation became regular; and the patient before long

recovered her health so far as to go out to service as a domestic. 1860. *Dr. S. L. Abbot.*

2751. A tumor from a married woman, who had had hemorrhage, at intervals, for four years. Suddenly, and after a long walk, a dense, heart-shaped, pediculated mass was forced down, so as to protrude externally. A ligature was applied, and on the fourth day it came away; the weight being $2\frac{1}{2}$ lbs. The apex was marked by a smooth circle, and probably due to the pressure of the os uteri. No hemorrhage followed the operation; and, though there was prolapsus of the organ, the patient's health was greatly improved. The mass looks and feels not unlike the common fibrous tumor of the womb. 1859.

Dr. James Ayer.

2752. A tumor, from a woman, æt. thirty, who was in labor with her first child, at the full period, and had had no symptoms of the disease. Dr. C. found the tumor below the child's head, and it descended with it. After the delivery it remained external to the vulva, and seemed to arise from the whole anterior lip of the uterus. A double ligature was at once passed about it, and it was then cut away; but, as it bled considerably, a second ligature was used, and the patient then did well. The tumor was about twice as large as a hen's egg, and resembles a very dense fibroid tumor of the womb. 1856. *Dr. B. Cushing.*

2753. A tumor, about $1\frac{1}{2}$ in. in diameter, of a rounded form, and mostly smooth over the surface, but in part torn, and showing the mass to be made up of small, fibrous tumors.

From a woman, æt. forty-six years. The tumor had been pressing down for thirteen years; and she had had, meanwhile, two children and two or three miscarriages. There had been hemorrhage for a week before Dr. S. saw her, but never before; nor had there been any return when he reported the case three months after the operation. The tumor was twisted off at the os with the fingers. 1859.

Dr. D. H. Storer.

2754. A tumor, larger than the last; of a rounded, and somewhat flattened form, and smooth upon the surface; the

peduncle being $\frac{3}{4}$ in. in diameter, and of a coarse fibrous structure.

From a woman, æt. forty-one years, who had had one miscarriage and six children. There had been constant pain in the back since the last in 1847, with increased catamenial flow from that time, and frequent hemorrhages from 1857 till 1859, when the polypus was removed, and, as in the last case, from within the os. The case, however, was complicated with a tumor in another portion of the organ, and the hemorrhage continued. 1859.

Dr. D. H. Storer.

2755. A tumor, 5 in. in length, 10 in. in circumference, and with a pedicle half an inch in diameter. Structure fibrous.

From a woman, æt. forty-one years, who had had one child, twenty-one years before. Flowing for the last nine years; chiefly at the menstrual periods, but at other times on exertion; one quite unusual symptom being an accumulation of the coagula between the tumor and the walls of the vagina. Latterly she had been much reduced by the loss of blood, and was confined to her chamber. Dr. Channing passed a ligature by means of Gooch's canula, and the tumor came off on the fifth day. 1856.

Dr. C. G. Putnam.

2756. A polypus, 2 in. in length, $1\frac{1}{4}$ in. across its free extremity, and $1\frac{1}{2}$ in. at the pedicle. Form not unlike that of a pear. The most remarkable peculiarity, and that which constitutes it as belonging to a very rare variety, is the existence of three or four cavities, opening largely upon the free extremity, as in the case of some small sponges, and of which two communicate, though the others are separate; these cavities resulting from the formation of the polypus, and not from disease. In the recent state it was as large as a goose-egg, of a very deep and rich purple or crimson color, soft to the feel, and thickly covered with very viscid mucus.

From a widow, æt. forty-four years, who had had several children; and who, for three years, had had a constant discharge of mucus and blood, with pain in the back, and a sense of bearing-down. She had become quite anæmic,

and had been treated by various physicians for prolapsus; the tumor was at the orifice of the vulva, and the largest cavity felt not unlike the os uteri. Dr. M. at once removed the tumor from the upper part of the cervix, with complete relief; and a year and a half having now elapsed, the patient's health is quite robust.

Dr. M. refers to Scanzoni as having met with and described a single case of this form of polypus. Dr. Oldham also describes and figures two specimens, and calls it the channelled polypus. (Guy's Hospital Reports for 1844, p. 115. — Med. and Surg. Jour., June 11th, 1868.) 1868.

Dr. H. A. Martin.

2757. A uterus, from which a polypus had been recently removed. A circular depression is seen upon the inner surface, just above the cervix, quite defined, and about $\frac{1}{2}$ in. in diameter. The lower part of the cervix is considerably dilated, and the organ, otherwise, is sufficiently well.

From a woman, æt. forty years, who entered the hospital April 23d, 1853 (184, 268). She was quite anæmic; having had menorrhagia for about twenty years, following two miscarriages, and frequent hemorrhages for the last two years. A large, soft tumor filled the upper part of the vagina, and a ligature was applied by Dr. J. M. Warren, on the 10th of June. On the 20th it came away; being 2 in. in length, $1\frac{1}{2}$ in. at the broadest part, and having a long pedicle. The patient died with inflammatory symptoms on the 2d of July; and, on dissection, the case was found to be complicated with a large ovarian cyst. 1854.

Dr. J. B. S. Jackson.

2758. A firm mass upon the inner surface of the fundus of the uterus; $1\frac{1}{2}$ in. in diameter, and forming the remains of the pedicle of a polypus, that was removed six months before death. The organ was tubercular, as were the peritoneum, lungs, etc. (Med. Jour. Vol. LXV. p. 474.) 1862.

Dr. F. Minot.

2759. Three or four fibrous tumors, about as large as the fist, besides several small ones. The large ones project into the peritoneal cavity, and one of them is to some extent

entirely broken down in structure. Cavity of organ not enlarged, and cervix not involved. 1847.

Dr. J. C. Warren.

2760. Several large, dense, pedunculated tumors hang off into the peritoneal cavity; and two or three of them, of the size of the fist, are ossified. Cervix and os small. The whole mass weighs $7\frac{3}{4}$ lbs. 1847.

Dr. J. C. Warren.

2761. A fibroid tumor, attached to the external surface of the organ by a few fibres only, though there were firm old adhesions to the neighboring parts. It is about as large as the two fists, of a regularly ovoid form, and strongly marked fibrous structure, and is shown to have been of long duration, by its opacity, and a certain amount of ossification upon the surface.

From a woman, æt. fifty-nine years, who died of cancer. The existence of the tumor was known for twenty years before her death, but it seemed to have given her but little if any trouble. (Med. Jour. Vol. LXI. p. 242.) 1859.

Dr. C. D. Homans.

2762. A single tumor, $2\frac{1}{2}$ in. in diameter, and projecting into the cavity of the womb, which is considerably enlarged; structure flaccid, and imperfectly fibrous. Uterine parietes flaccid, and quite thin over the tumor. Neck not involved. The specimen resembles very strikingly one of Dr. Baillie's figures. (Pl. III. fig. 2.) 1854.

Dr. Charles Gordon.

2763. A tumor, about as large as a marble, and projecting into the uterine cavity from the fundus. Incision through both.

From a negress, æt. forty-five years, who was estimated to weigh 350 lbs. She had had three children, and ten miscarriages; the last time about two years before her death, when, as she said, "she nearly flowed to death." 1855.

Dr. Wm. E. Townsend.

2764. Forty-two tumors, from about $\frac{1}{2}$ in. to 2 in. in diameter. There were also two large tumors that were ossified throughout. (Nos. 1308-9 in the Med. Soc.'s Cabinet.)

From a negress, æt. fifty-nine years; a feeble-minded

woman, who had had incontinence of urine, but no other marked symptoms. 1857.

Dr. G. L. Collins, of Providence, R. I.

2765. The uterus perfectly buried in tumors, which vary in size generally from 1 to 3 in. One of the largest is in the cervix, and seems to have originally formed in this unusual situation. Another of the largest hung freely into the peritoneal cavity; and a third, 2 in. or more in diameter, projects into the cavity of the fundus, with a small pedicle. The uterine cavity is much dilated, but the parietes of the organ are comparatively thin; and the blood-vessels are enlarged as usual. The whole mass weighs 3 lbs.

From a widow, æt. forty-six years, who had had profuse menstruation for years, but without much pain; and no other pelvic symptoms. 1861. *Dr. C. G. Putnam.*

2766. Several small tumors in the womb, which last is much atrophied; the most interesting point being the formation of a fibrous tumor, about half as large as an English walnut, in or rather below the broad ligament, and quite beyond the limits of the uterus. 1861.

Dr. J. B. S. Jackson.

2767. A large uterine tumor, that was spontaneously discharged.

The patient was forty-one years of age; and being then in her ninth pregnancy, had in May, 1855, a considerable hemorrhage. Sept. 24th Dr. S. was called, and found that she had been flowing for a month. A very firm tumor was felt in the right iliac region, but he was not allowed to make an examination. Dec. 23d the child was born, presenting by the breech, with the head exceedingly compressed upon one side, as by the tumor, and weighing 6 lbs. The placenta, to some extent, was strongly adherent; and, on separating it, the tumor was distinctly felt. During the following night and day she had severe after-pains; and forty-eight hours after delivery, the tumor, weighing 2 lbs., was thrown off. Recovery rapid.

In May, 1857, she was again delivered of a large, healthy child; but she recovered slowly, and died the following January from a large intra-thoracic tumor. In the

body of the uterus was a fibrous tumor, of the size of a pea, but upon the inner surface nothing peculiar was noticed. 1856. *Dr. D. H. Storer.*

2768. The fundus and body of the womb, considerably enlarged, and very much elongated by fibrous tumors. Cervix not affected. 1861. *Dr. R. M. Hodges.*

2769. Portion of a tumor, to show the change of structure that may take place after a long while.

The patient was eighty-four years of age, and had had swelling of the abdomen for more than thirty years. There is no appearance of fibrous structure to the naked eye, though it is marked enough microscopically; but it is perfectly white, very flaccid, though tough, moist in appearance, and irregular rather than smooth upon the cut surface. Altogether it formed a semi-spherical mass, 6 in. in diameter, and 3 in. in thickness; and the convexity was surrounded by a thick, cretaceous covering (No. 2773) — there being no ossification of the substance of the mass. 1852. *Dr. Daniel Huntington, of Rochester, Vt.*

2770. A single tumor, developed in the fundus of the organ, very defined, of a regular, rounded form, and measuring on the cut surface about 5 in. in diameter. Structure quite dense, for the most part, but with great numbers of small cavities, in which is a cellular tissue, and which last is very soft and relaxed, and, when recent, so infiltrated as to give a gelatiniform appearance. The uterus is quite small; and the expansion over the tumor is well shown.

From a woman, æt. forty-five years, who had known of the tumor for at least five years. During the last year she was as large as at the sixth month of pregnancy; and died at last worn out by pains. 1861.

Dr. J. B. S. Jackson.

2771. A tumor in the anterior parietes; single, perfectly globular in form, nearly as large as the fist, very dense, and partially ossified. Uterus elongated, very much as in No. 2768. The subject was about seventy years of age. 1857.

Dr. R. M. Hodges.

2772. A tumor, $1\frac{3}{4}$ in. in diameter, quite defined, surrounded by a cretaceous shell, and has throughout a dead, opaque,

dryish, yellowish-white appearance, with some brownish discoloration. It is quite as dense as any fibroid tumor, though the peculiar structure is less marked than usual. As in No. 2769, the tumor had ceased to grow, had degenerated, and the patient may have lived for many years without any further trouble from it.

The ovaries are shown with the uterus. The left has been transformed into a thin, serous cyst, nearly $2\frac{1}{2}$ in. in diameter. The other consists mainly of a collection of cysts, nearly twice the size of an English walnut, and upon which the remains of the atrophied ovary are spread out.

From a woman, æt. forty-five years, who died of pulmonary disease, and had no uterine symptoms. Her last labor occurred six years before her death, and she then had twins. Menstruation was said to have been regular until the last; occasionally very scanty, and, when this was the case, she had hæmoptisis. 1852.

Dr. Charles H. Stedman.

2773. Ossific envelope, from the surface of a fibrous tumor. (No. 2769.) 1852. *Dr. D. Huntington.*

2774. A tumor cut open and dried; and showing cretaceous matter scattered throughout. It was about $\frac{3}{4}$ in. in diameter, and hung off from the fundus into the peritoneal cavity by a slender pedicle. In the substance of the body of the organ was a second, smaller tumor, not at all ossified. — From an octogenarian. 1855. *Dr. C. Ellis.*

2775. Tumor, ossified throughout. A dried section. $1\frac{7}{8}$ in. by $1\frac{1}{4}$ in. 1862. *Dr. C. Ellis.*

2776. Three irregular, cretaceous masses, and altogether about twice the size of the fist. From a tumor that arose from the posterior portion of the cervix, and weighed 14 lbs. The soft parts, which have been dissected away, had a lax, coarse, fibrous structure.

From a lady, æt. sixty-five years. The abdomen had been gradually enlarging for about forty years, until the cavity was filled. 1866.

Dr. F. F. Tursait, of Weymouth.

2777. A tumor, hanging by a very marked pedicle from the

fundus of the uterus, and into the peritoneal cavity. About the size of a hen's egg; and, having been cut open, it shows a complete breaking-down of the substance for the most part, but with the intervening fibrous structure unchanged. The uterus, otherwise, is healthy. 1847.

Dr. J. C. Warren.

2778. A tumor, 5 in. in diameter, and attached to the fundus of the organ. In its substance is a large, and irregular, but perfectly defined cavity, containing portions of the mass, that have been detached apparently by the process of sloughing; these free portions being deeply discolored when recent, though still very dense. Several folds of the ileum adhered to the tumor, and one of them opened into its cavity; and it must have been a rupture of this cavity into that of the peritoneum that caused death.

The patient, æt. thirty years, was about as usual, when symptoms of perforation came on, and she died considerably within twenty-four hours; about two quarts of a thick fluid, and having a strong fæcal odor being found in the peritoneal cavity. (Med. Jour. Vol. LXXIV. p. 425.) 1867.

Dr. Wm. Reed.

2779. Uterus, in the posterior parietes of which a large tumor had become separated from the surrounding substance of the organ, by a process of sloughing, so that it lay there as free as a polypus that had been detached by a ligature. The tumor itself is in the Med. Soc.'s Cabinet. (No. 970.) The uterine cavity is cut open, and is seen to be healthy, though much elongated; and in the parietes of the organ are other fibrous tumors. 1861.

Dr. J. B. S. Jackson.

2780. The uterus cut open, and showing a fibrous tumor in the substance of the fundus, about the size of an English walnut. This last formed a tumor in the hypogastrium as large as the fist; but, under the use of the bromide of potassium, it diminished so that in two months it could not be felt. Three years afterward the patient died of fever. 1866.

Dr. H. R. Storer.

2781. A large tumor, mistaken for an encysted ovary, and removed during life. (Hospital, 32, 164.)

The patient was a healthy, unmarried woman, æt. twenty-seven years. Duration of disease about one year; and growth of tumor rapid the last six months. It extended to the epigastrium, was not painful, seemed to be distinctly lobulated, and had an elastic feel as if encysted. With the full sanction of the surgeons of the hospital, and determination of the patient, Dr. P. removed the tumor, after applying ligatures about what seemed to be the pedicle. A few ounces only of blood were lost; and the patient was quite comfortable until the evening, when she suddenly fell off, and twelve hours after the operation died; nearly a quart of blood being found in the peritoneal cavity.

The tumor weighed nearly 9 lbs.; and, even after removal, the sense of fluctuation was such that it was impossible to realize, until it had been cut through in different directions, that it was not encysted. This feeling was owing to the structure, which, instead of being dense, as in most cases, was soft and compressible, with large meshes, and a very considerable amount of serous infiltration. There was also in the centre of the mass a considerable amount of effused lymph. It arose from the fundus of the womb, and was invested by a thin layer of uterine tissue. The uterus is preserved with the tumor, and is seen to have been cut through near the fundus. (*Amer. Jour. of Med. Sc.*, April, 1848.) 1848. *Dr. Samuel Parkman.*

2782. The uterus, greatly enlarged by fibrous tumors, and removed, successfully, during life; the weight of the mass being 8 lbs. Both of the ovaries are seen; and the cavity of the uterus is exposed by incision.

The patient was forty-seven years of age, and had known of the existence of a tumor for five years. Convalescence was uninterrupted; and on the thirty-seventh day she returned home, a distance of about four miles. Before the uterus itself was removed, a tumor that was attached to the broad ligament was removed, and that weighed 16 lbs., after thirteen pints of fluid had been drawn from it.

This case has been published in the *Amer. Jour. of Med. Sc.*, Jan., 1866, with numerous quotations, and a full dis-

cussion of the subject of the removal of the organ.
1866.

Dr. Horatio R. Storer.

2783. The greater part of the uterus, with a large fibrous tumor connected with the fundus; removed during life.

The patient was a widow, fifty-two years of age, who had suffered from the disease, more or less, for nine years, and particularly for the last two. The chief symptom was pain in the pelvis and lower extremities, as from pressure upon the sacral nerves; with partial loss of power and sensibility toward the last. Bowels much constipated, and feces flattened; but dysuria not urgent. General health impaired, and for the last two or three months she had scarcely been up.

The case was diagnosticated by Dr. C. as one of fibrous tumor of the womb; and the operation was performed by him in May, 1867, at the earnest solicitation of the patient, and with a full understanding as to the probable result. The mass, here shown, was removed with the *écraseur*, and afterwards the other ovary with the same. Seven silver wire ligatures were applied to the vessels, and the actual cautery was also used; $\bar{3}j.$ or more, only, of blood being lost during the operation, which lasted about five hours. The patient lived twenty-three hours after the operation, and until the last three or four hours looked as if she might recover. On dissection, no inflammation was found, nor effused blood.

The uterus has a rounded, knobbed appearance, and is about the size of the fist; containing numerous fibrous tumors, and almost entirely in the anterior parietes. From the fundus there hangs off, and by a long pedicle, a very dense tumor, of which the diameters are $6\frac{1}{2}$, $5\frac{1}{2}$, and 4 inches. The whole mass weighs now 3 lbs. $12\frac{1}{4}$ oz. 1869.

Dr. Charles M. Carleton, of Norwich, Conn.

2784. A membrane that was expelled from the uterus, and has the appearance of a decidua, excepting its unaccountable length. One surface is throughout quite smooth, and the other rough; and in one place at least the characteristic punctated appearance is quite marked. To the extent of about 3 in. it is tubular, and probably large enough to

admit the finger. The width varies at different parts ; and the length is 15 in.

From an unmarried woman, thirty-eight years of age, who discovered a tumor, about five years ago, upon the right side, half way between the umbilicus and pubes, and about the size of an egg. During the menstrual periods there has always been great flowing, but without pain, — and, since the tumor was first known, with three exceptions, a membranous discharge at each period ; the length of the membrane varying from 6 to 24 in. The woman has the appearance of full health, and the tumor, which is in the right side of the abdomen, and extends rather beyond the median line, is of a rounded form, dense to the feel, and apparently about 6 in. in diameter.

Microscopically, Dr. J. Collins Warren found the membrane transparent, filled with spindle-shaped cells, and perforated with holes ; with villi thickly attached to the rough surface. 1870. *Dr. C. E. Buckingham.*

2785. Tubercular disease of the inner surface of the body and fundus of the womb ; cervix, as usual, not affected.

From a woman, æt. twenty-nine years, who was extensively tubercular. 1855. *Dr. J. B. S. Jackson.*

2786. Scirrhus of the womb. The os and cervix are destroyed, with the whole upper part of the vagina ; ulcerated surface dense. No cancerous disease elsewhere.

The patient was thirty-nine years of age, had had the disease for a year or more, and the case was remarkable for the entire absence of pain. (Med. Jour. Vol. XLV. p. 394.) 1852. *Dr. J. B. S. Jackson.*

2787. Encephaloid disease. — Organ cut open, and shows a destruction of the os, cervix, and great part of the body ; with some superficial ulceration of the vagina, resulting from the irritating discharge, and a threatening of rupture into the peritoneal cavity. An encephaloid mass, about the size of a nutmeg, is also seen to project into the bladder, which, though small, is otherwise healthy. The appendages of the uterus are adherent ; and the ureters (No. 2481) were dilated. As usual in cancer of the womb, the other organs were not affected.

From a married woman, æt. thirty-two years, who entered the hospital April 14th, 1851, and died Nov. 28th (169, 154). Duration of the disease uncertain, as she had been out of health for three or four years. Leucorrhœa for some years; with a constant and offensive discharge whilst she was in the hospital. The "catamenia," which had previously been regular, was very profuse, and present during more than half the time, for about ten months preceding Feb. 1851, but afterward became scanty. Much pain; and especially during defecation, though no dysuria. Became very pallid, and much reduced, with universal anasarca for some months before death. (Amer. Jour. of Med. Sc., April, 1852.) 1852. *Dr. J. B. S. Jackson.*

2788. Thibert's model. Encephaloid disease of the neck of the womb, successfully removed by M. Paul Dubois. The os uteri is shown. 1847. *Dr. G. Hayward.*

IV. EXTERNAL ORGANS.

2789. A potato, 4 in. in length, and $6\frac{1}{2}$ in. in circumference, that was thrust into his wife's vagina by a man who was on the verge of delirium tremens. After several ineffectual attempts with forceps, etc., Dr. T. removed it with a corkscrew, as he would a cork from a bottle. It had been in the vagina for about an hour, and no inflammation resulted. 1852. *Dr. Wm. E. Townsend.*

2790. Wound of the vagina by a hay-hook (No. 3116). The bladder and intestine were also wounded; and, the perforations not having closed, a glass rod has been passed through, and indicates the course of the hook. 1857. *Dr. J. P. Maynard, of Dedham.*

2791. A superficial, lacerated wound of the nymphæ, that, in the recent state, was $1\frac{1}{2}$ or 2 in. in length, with some extravasation of blood into the surrounding tissues. The vagina was perhaps also lacerated near the meatus; but it was thought that the parts may have been cut during their removal.

From a healthy woman, in the seventh month of pregnancy, who was found by Dr. A. lying upon the floor, in a

pool of blood, and immediately after falling from a bed upon which she had been standing; there being no certain evidence that she struck anything as she fell, though the post of a crib was suspected. All efforts to arrest the bleeding were of no avail, and she died in about three-quarters of an hour.

The above is only one of several cases that have been reported to the Soc. for Med. Improvement, of violent hemorrhage in case of wounds of the external genital organs during pregnancy. 1851.

Dr. Z. B. Adams, of Framingham.

2792. A large and continuous portion of "epithelium," discharged from the vagina. The patient, who had been under the care of Dr. J. T. G. Nichols, of Cambridge, was a servant girl, æt. twenty-six years, who had had a moderate leucorrhœal discharge for some time; and profuse menstruation, though regular, and with very little pain. The membrane was thrown off toward the close of a menstrual period; and there had been similar discharges previously. 1867.

Dr. J. Wyman.

2793. Bodies discharged from the vagina, and that look very much, in regard to form, as if they might be casts of the cavity of the fundus and body of an enlarged uterus. They are about $2\frac{1}{2}$ to 3 in. in length, $1\frac{1}{2}$ in. in width, and from $\frac{1}{4}$ to $\frac{1}{2}$ in. in thickness. One extremity is smoothly and regularly rounded, and the other is ragged. The surfaces also are nearly regular, and to the feel they are fleshy. In structure they are foliated like packages of thin membranes, closely compressed; this being well shown on section of one of the specimens. Microscopically, Dr. B. S. Shaw found them "composed of epithelium, such as is found lining the vagina, namely, large nucleated scales."

The patient was a pallid, fleshy, bloated-looking woman, about forty-four years of age, and subject to a great variety of distressing complaints. Married a few years, but had never had sexual connexion on account of a contracted state of the vagina. Some time after her marriage she was treated by an empiric for about eighteen months; used

occasionally strong vaginal injections, and during this time mainly the epithelial bodies were discharged. For the first three months they came away regularly once a month; but afterward more frequently; and at last several were passed in a week; the number altogether being ninety-six. The specimens here shown are opaque, and of a reddish color, from the injections that had been used, as the patient thought; the appearance generally being pearly and semi-transparent, according to her report. Menstruation began at the age of nineteen, was generally irregular, and had ceased about two years before the discharge of these bodies commenced. Much dysuria for many years, with bearing-down pain, but not much leucorrhœa. 1857. *Mr. T. H. Gibby, med. student.*

2794. A cyst removed from the vulva, and about the size of a large filbert. It has been turned inside out, stuffed, and dried; and, there having been two ducts, these are marked by bristles. Prepared by Dr. B., who regarded it as a distended Cowper's gland. 1869. *Dr. H. J. Bigelow.*
2795. Two cysts beneath the mucous membrane of the vagina, from $\frac{1}{2}$ in. to 1 in. in diameter, and filled apparently with serum. One is just below the os uteri, and the other near the vulva. From the same patient as No. 2791. 1857. *Dr. C. Ellis.*
2796. A soft and extremely flaccid tumor, that arose from the internal labium by quite a small pedicle, and hung down 11 in. between the thighs when the patient stood erect. Cuticular covering very delicate, and healthy in appearance. The patient was about twenty years of age; and the growth had been forming about three years. 1856. *Dr. D. H. Storer.*
2797. A slender, but firm little polypoid excrescence, about an inch in length, and removed from the internal labium of a married woman. It had existed for a year, and kept up a constant vaginitis, which was relieved after the excision. 1856. *Dr. D. H. Storer.*
2798. A fibrous tumor removed from the right labium of an unmarried woman, æt. thirty-five years. It was of fifteen

years' duration, larger than a hen's egg, hard, movable, painless, increasing slowly, and troubling her chiefly by its size. The patient did well. 1861.

Dr. J. M. Warren.

2799. Elephantiasis of the external and internal labia, removed by Dr. J. M. Warren from a girl æt. eighteen years. The disease had existed for two years, began in the ext. labia, and formed a rather large tumor; inflamed and painful, with considerable discharge from the surface, though there was no ulceration. Its erectile tendency was shown at the menstrual periods. Clitoris not involved. Hemorrhage not great at the time of removal; and the parts healed well without much contraction. The patient was married afterward, but was soon divorced upon the suit of her husband. Dr. W., being then again applied to, found the hymen thickened, and very tough; and, having divided it, the flaps were removed, and the passage was then quite free. She was afterward married again, bore a child in the course of a year, and died in twenty-four hours; labor not extremely difficult. 1847.

Dr. J. C. Warren.

2800. Enlargement and thickening of the internal labia, with almost a warty appearance upon the surface. 1847.

Dr. J. C. Warren.

2801. A small, but highly characteristic specimen of elephantiasis of the labia; lobulated, warty, dense, and discolored. A tumor, weighing $1\frac{1}{4}$ lbs., and of fifteen years' duration, had been removed (No. 672 in the Med. Soc.'s Cabinet), but returned in a year and a half; and when the woman died, about twelve years afterward, there was a mass upon each side of the vulva as large as a sausage. 1852.

Dr. J. B. S. Jackson.

2802. An enlarged copy by Mr. B., of a photograph of a Japanese woman, who had a tumor of immense size hanging down between her thighs, and that resembled, so far as a poor photograph shows, a case of elephantiasis of the labia. There is no appearance, however, of the vulva; and, though it may have been an elephantiasis that originated from and chiefly affected the clitoris, it may perhaps have formed about the pubes, and descended as it enlarged.

The woman was about forty years of age, and the tumor, that had been forming gradually for several years, became at last too heavy for her to carry about, and it was cut off. Weight after removal about 50 lbs. The operation was done in Japan; and the woman was said to be doing well some months afterward. The photograph, with these few facts in the case, was sent to Dr. S. Cabot. 1870.

Mr. W. P. Bolles, med. student.

2803. Model in wax, by Guy, of Paris, showing a most exuberant growth of syphilitic vegetations along each external labium. 1847. *Dr. J. C. Warren.*

2804. Melanosis of the clitoris; about as large as the end of the little finger. The prepuce is comparatively unaffected; and traces of the crura are seen. Excised with one of the internal labia, of which the upper part was diseased. From a healthy woman, æt. forty-two years. Duration of the disease nine months. 1857.

Dr. H. J. Bigelow.

V. BREAST.

The following seven models, by Thibert, were given in 1847, by *Dr. G. Hayward.*

2805. Inflammation of the nipple, with slight erosions.
2806. Inflammation, with cracks about the nipple.
2807. Commencing inflammation of the breast, from lactation.
2808. Acute inflammation.
2809. Abscess formed, but not open.
2810. Extensive abscess; opened.
2811. Abscesses, with two openings.
2812. A portion of the udder of a Durham and Jersey heifer, showing a very marked epithelial disease. It is in the form of superficial nodules, distinct or coalescing; and these consist of an involution of the cutis, and the formation of defined, more or less irregular, and not very deep cavities. These last seemed to be filled with epidermis, which is crumbling upon the surface, but more resisting and adherent beneath; the cutis that formed the cavities

being thickened and dense, but nowhere ulcerated. The animal was expected to calve in a few weeks; and, though the disease was very extensive, and a portion of it was left, when the mass was removed, the animal did well. Dr. B. S. Shaw found the nodules to be "composed of large epithelial scales, such as are found in epithelial disease of the human lip." 1867.

Dr. C. C. Tower, of S. Weymouth.

2813. A large, unilocular, simple cyst, removed from the breast of a lady sixty-two years of age. It began three years before as a small, painless tumor, and at the end of two years was as large as a goose-egg. From that time it increased more rapidly; and particularly the last three weeks, when the summit became discolored. It appeared as a large, globular, fluctuating tumor, and occupied the whole breast; the skin upon the summit thin, tense, shining, and of a greenish color; the nipple pushed to the outer side, and the whole mass perfectly free. It was exceedingly troublesome by its bulk and weight; and the patient did quite well after the removal.

The whole mass weighed $3\frac{1}{2}$ lbs.; and the cyst contained $1\frac{1}{2}$ pints of a thin, bloody fluid, with shreds of dirty, soft coagula. There were also, apparently, some adherent, firm coagula; and some looser, tuft-like masses, from which floated loose shreds of tissue. Otherwise the inner surface of the cysts was smooth and shining.

Dr. G. explained the rapid growth toward the last, and the discoloration by hemorrhage into the cyst. 1863.

Dr. T. H. Gage, of Worcester.

2814. A tumor, of an oval form, about the size of a fist, and quite defined, though no proper cyst is generally to be seen. The cut surface, which is very remarkable in appearance, might perhaps be described as coarsely and loosely foliated, and as suggesting the idea of a section of the central portion of a cabbage. There seem, also, to be two small tumors, beside the large one. Near the nipple the milk-tubes are seen, somewhat distended. 1847.

Dr. J. C. Warren.

2815. Glandular hypertrophy. — From a healthy married lady,

æt. sixty-two years. (Hospital, 71, 125; and Med. Jour. Vol. LV. p. 39, with remarks by Dr. Bigelow and others.) Disease of twenty-eight years' duration, and was at first a small, hard, painless lump. Soon afterward she nursed a child, and from that time it increased gradually until the last year, when the growth was very rapid. The breast was at least three times its natural size, and weighed, after its removal, $2\frac{1}{4}$ lbs.; axillary glands not affected. The mass consists of lobes and lobules of various sizes, and very loosely connected; with a round cretaceous mass in the centre, about $1\frac{1}{2}$ in. in diameter, and not unlike an ossified fibrous tumor of the womb. Microscopically, Dr. Ellis gave the following as the result of his examination:—

“Fragment of tumor contained much fibrous tissue, and many lobules, which looked like masses of small nuclei. In the latter no nucleoli could be distinguished. Numerous small, round, or oval free nuclei were, however, seen, containing one or two small nucleoli. Tubuli, lined with epithelium, also were noticed. The disease was evidently glandular hypertrophy.”

He adds, “I examined it also with reference to the existence of cysts. On puncturing many parts of the external surface, there exuded a somewhat milky fluid, which had been contained in fissures or flattened cavities of no great extent. The fluid contained numerous cells and free nuclei of an epithelial character. Projecting into the fissures, from various parts of their walls, were warty vegetations, some of which had a linear or laminated arrangement. One of the largest of these cavities contained a yellowish fluid, somewhat resembling olive oil. In this, in addition to the epithelium, were found many fat globules, and large spherical corpuscles, apparently formed by the aggregations of the same.” 1856. *Dr. H. G. Clark.*

2816. A coarse, irregular, cretaceous mass, about $2\frac{1}{2}$ in. in diameter, and removed from the interior of an encysted breast; dried.

From a woman, forty-eight years of age. Eighteen years before her entrance into the hospital (136, 106), the breast became “caked” after labor, and remained so from

that time, with abscesses twice. During the last three months it had been enlarging rapidly, with severe pain, but without tenderness, and on admission it was about as large as the patient's head. After the removal, which was attended with much hemorrhage, it was found to be about 6 or 8 in. in diameter, and to consist of a mass of cysts, varying from the size of a pea to that of an orange, and containing a coffee-colored fluid. The patient did well, and left the hospital in about a month. 1869.

Dr. R. M. Hodges.

2817. An ovoid tumor, about 3 in. in diameter, quite defined, and with some appearance of a cyst about it. The structure is white, compact, tough, somewhat lobed and lobulated, and having a coarsely granulated look upon the cut surface. Glandular hypertrophy, without doubt. 1847.

Dr. J. C. Warren.

2818. Another tumor, apparently of the same kind, though not cut through. Size of a hen's egg; of a rounded and rather irregular form, and with a marked cyst about it in part. 1847.

Dr. J. C. Warren.

2819. The same. Nearly the size of two fists; of a rounded and somewhat flattened form. No cyst about it, though very defined. Quite lobed upon the surface, and somewhat so within; cut surface smooth; but, on handling, it appears reticulated, like fine sponge. 1847.

Dr. J. C. Warren.

2820. The same. The tumor, which is cut through midway, is of a rounded form, nearly 5 in. in diameter, knobbed upon the surface, and with a fibro-cellular investment about it. The structure is firm; the cut surface uneven or coarsely granular, with some appearance of lobes, and generally an intervening dense fibrous tissue. Just below the surface, at one part, is a very marked cyst, into which there projects a tumor larger than an English walnut.

The patient, æt. twenty-eight years, had a phthisical look, and died five days after the removal of the mass; tubercular disease being found in various organs. (Hospital, 89, 32.) The tumor was of two years' duration, and increasing; with considerable pain, movable, and uniformly

hard, except at one part, where it was as hard as scirrhus.
1861. *Dr. C. Ellis.*

2821. The same. A colored lithograph of a small tumor, and section of the same. Another figure in the same plate shows a minute lobe picked to pieces, and of the natural size. Another shows this same lobe magnified 30 linear, and the irregularly enlarged lobules, of which it is composed, forming a botryoidal mass. In another figure the edges of these lobules are seen, magnified 300 linear, with hypertrophy of the fibrous element and sparse cells. 1858.

Dr. H. J. Bigelow.

2822. A defined cyst, about 3 in. in diameter, and into which there projects a regular, round tumor, filling the greater part of it, remarkably concentric in structure, and which, in its nature, is apparently malignant. Outside of the cyst is a considerable mass of disease, but from which a portion has evidently been cut away; smooth on the cut surface, and less opaque than the tumor within the cyst. — Removed from a lady about fifty years of age; no decided pain. 1861.

Dr. H. J. Bigelow.

The following six models by Thibert, were given in 1847, by

Dr. G. Hayward.

2823-4. Scirrhus, and section.

2825. Cancer, with disease of skin.

2826. Encephaloid disease.

2827. A large, deep, and very defined cavity, with disease of the glands, — the result of cancer.

2828. Extensive ulceration, and half cicatrized; the result of cancerous destruction of the gland.

2829. Section of a scirrhous breast. 1847.

Dr. J. C. Warren.

2830. A regular, defined, smooth, ulcerated mass, projecting from the surface of the breast; about 2 in. in diameter, and $\frac{1}{2}$ in. thick. Subjacent parts probably not much affected. 1847.

Dr. J. C. Warren.

2831. Encephaloid; the disease has extended just below the surface, though the skin is not yet broken. 1847.

Dr. J. C. Warren.

2832. Cast of a very large and purely encephaloid breast, about 6 in. by 3 in. in diameter.

The patient was a single, middle-aged, healthy-looking Irishwoman, and the duration of the disease was two years. The structure was moderately firm, whitish, and semitranslucent; section flat; some xanthoid; no striæ, fibres, nor milk-tubes. About four years afterward the mass was again removed by Dr. Gay, and was then about two-thirds as large as before. 1861.

Dr. H. J. Bigelow.

SERIES XXXVI.—GENITAL ORGANS OF THE MALE.

I. SCROTUM.

Four Thibert's models, given in 1847, by

Dr. G. Hayward.

2833. Effusion of blood into substance.

2834. Urinary abscess, with fistulæ.

2835. Inflammation, with commencing gangrene.

2836. Gangrene more advanced; extended to the prepuce and integuments in the hypogastrium.

2837. A perfectly defined, rounded abscess, of the size of a nutmeg, and situated in a thick, dense, fibrous tissue, that closely invests the testicle, and is from $\frac{1}{2}$ in. to 1 in. in thickness. It is thickly lined with recent lymph, and was filled, when recent, with thick, greenish pus. The testicle is healthy.

The patient was twenty-one years of age, and had suffered greatly from pain, and a sense of weight for about two years. About a pint of serum was drawn off; and a few weeks afterward, upon the presumption that the testicle was diseased, the organ was removed. Sent to Dr. S. from the country. 1854.

Dr. B. S. Shaw.

Follicular disease of the scrotum. (See No. 1989.)

II. TESTICLE.

2838. Thibert's model. Hydrocele. 1847.
Dr. G. Hayward.
2839. — — Cavity shown, extending to the groin. 1847.
Dr. G. Hayward.
2840. Old hydrocele, about the size of an orange. Not cut open. 1847.
Dr. J. C. Warren.
2841. The same, about as large as the last. Cut open to show the testis, and great thickening of the sac. 1847.
Dr. J. C. Warren.
2842. A third specimen. — The tunica vaginalis is nearly $\frac{1}{4}$ in. thick, and in the cavity was a pint of a dirty-colored fluid; the fluid of the hydrocele being probably mixed with effused blood. The inner surface was lined in part with lymph. The disease was of nineteen years' duration, and the mass was removed as being an enlarged testicle. It was as large as a cocoa-nut, firm, and without fluctuation, but showing an inflamed spot upon its anterior face. The testicle is seen upon the back part of the sac, apparently atrophied and adherent. The other testicle had been enlarged during the last year, but without hydrocele. The patient did well. 1849.
Dr. J. M. Warren.
2843. Old adhesions of the tunica vaginalis. Testicle not enlarged. 1847.
Dr. J. C. Warren.
2844. A round, fleshy body, about as large as a garden pea, and that was attached to the testicle by a small pedicle. Fibroid in structure. Removed in the course of an operation for hydrocele; the tunica vaginalis being somewhat thickened. 1862.
Dr. H. J. Bigelow.
2845. A body that was found free in the cavity of the tunica vaginalis; about the size of an apple-seed, smooth upon the surface, and about as firm as cartilage. The tunica vaginalis was healthy.
Dr. H. has met with several similar cases. 1861.
Dr. R. M. Hodges.
2846. The genital organs of a man who must have been castrated before puberty. — The penis is not far from an inch in length; and beneath it was a scar upon each side.

The vasa deferentia ended abruptly at the groins. Vesiculæ seminales and prostate extremely small. Bladder thickened.

From a dissecting-room subject, about forty years of age, with the general contour of a woman, and an absence of beard. 1858. *Dr. R. M. Hodges.*

(For varicocele, etc., see Disease of the Veins.)

2847. Effusion of blood into the substance of the testicle. Organ cut open, and looks otherwise healthy. 1847.

Dr. J. C. Warren.

2848. Encysted disease of the organ.—A thin slice having been taken off after it had been hardened in spirit, the cysts are finely shown.

From a healthy man, about thirty-five years of age; and the disease was of three or four years' duration. Gradual enlargement; sense of weight, but no pain; fluctuation very distinct. The organ was of an elongated, oval form, and in contact with the external ring. About two and one-half years after the removal, Dr. B. heard from the patient, and he was then well. 1854.

Dr. H. J. Bigelow.

A similar testicle was removed by Dr. Gay not very long afterward.

2849. Organ much enlarged, and consists of an opaque, yellowish-white curdy mass, with commencing cavities. 1847.

Dr. J. C. Warren.

The following thirteen models by Thibert were given in 1847, by

Dr. G. Hayward.

2850. Case of tubercular disease of the testicle. Surface of the scrotum irregular; and abscesses opening externally.

2851-2. Scirrhus. External appearances before the operation; and section after removal.

2853-4. Encephaloid. External appearances after removal; and section.

2855. Encephaloid, with ulceration of the scrotum, and slough; before the operation.

2856. Section of the last, after removal.

2857. Encephaloid, after removal. From a child, two years old, that died of convulsions two days after the operation.
2858. Section of the last.
2859. Cancer, with great enlargement before the operation; and section.
2860. Section of a cancerous testicle; of a mixed encephaloid, scirrhus, tuberculoid, and fungous character. Fibrous coat thickened and scirrhus.
2861. The testicle after removal. Character of disease uncertain.
2862. The same. One-half of the investing membrane removed.
2863. Organ greatly enlarged and apparently encephaloid, but with numerous cysts. 1847. *Dr. J. C. Warren.*
2864. Vesicula seminalis much enlarged, and solidified by opaque tubercular matter, with some softening. The vas deferens, where cut across near its termination, very much resembles a tubercular Fallopian tube; but just beyond this it is healthy. The other ves. sem. was healthy. Some tubercular deposit, however, is seen in the prostate, and there was the same in the brain and throughout the lungs. From a middle-aged man. 1856.

Dr. J. B. S. Jackson.

III. PROSTATE GLAND.

2865. Lateral lobes greatly enlarged, and the left most so, as, it has been said, is generally the case; the course of the urethra being strongly inclined toward one side. The third lobe, so called, is not at all enlarged; but a marked transverse ridge connects the lateral lobes, and behind it is quite a cavity. Bladder sacculated. 1849.
- Dr. J. B. S. Jackson.*
2866. Lateral lobes greatly enlarged; and from the left there stands off a large additional mass. Structure rather irregular. No third lobe, but in place of it a thick, transverse ridge. Lacunæ about verumontanum rather large, with some appearance of laceration; and upon one side is a false passage about 2 in. in extent. Bladder much

thickened and sacculated, and in the recent state contained a number of small calculi. (Med. Soc.'s Museum, No. 1557.) Upon the outside are one or two phlebolites.

From a gentleman, æt. eighty-six years; a large, fleshy man, and a high liver. Duration of the disease twelve or fifteen years. About five days before his death an attack came on, similar to those that he had often had, but more severe than usual; bladder distended to above the umbilicus; several attempts at catheterism, but blood only came away. 1852. *Dr. J. B. S. Jackson.*

2867. Lateral lobes about equally enlarged, and form a regular, rounded mass, about two-thirds as large as the fist. Canal not cut through, but evidently not enlarged. 1847.

Dr. J. C. Warren.

2868. Lateral lobes uniformly enlarged to more than half the size of the fist, with a transverse ridge, but no third lobe; the passage being quite free. Bladder dilated, thickened, and remarkably sacculated. Between this last and the rectum was an abscess that contained about two ounces of thick yellow pus, with infiltration of the cellular tissue.

From a professional gentleman, æt. seventy-five years, who was in the hospital in February, 1854, for about two weeks (64, 8). Within ten years he had had three attacks of retention of urine, and that were relieved by the catheter; and for the last two years there had been great dysuria. In Nov., 1853, he had an attack of fever, with great pain at the neck of the bladder, and severe dysuria; and, on admission into the hospital, the fæces could not be retained when the urine was discharged. During his stay there, he was very irritable, but did not suffer greatly from the prostatic disease; and, as bearing upon the abscess, there was no pain in the perineum, so far as was known. A few days before leaving the hospital, however, there was inflammation of one epididymis, with discharge of pus from the urethra. After leaving he gradually failed, and died on the 4th of the following month. 1857.

Dr. Edward B. Peirson, of Salem.

2869. Lateral lobes enlarged, with some enlargement of the middle lobe, and altogether, about four times the usual

size. Tumors developed in the substance of the gland, as often seen, and suggest strongly the idea of the uterine fibroid tumors. Before it was cut through, the canal readily allowed the passage of the forefinger from the bladder, so that the tip could be felt upon the other side; though between the bladder and the canal of the urethra there is a high transverse barrier that seemed to completely separate the two. The bladder rose to the umbilicus, and carried the peritoneum with it three-fourths of the distance from the pubes; organ much thickened and remarkably fasciculated and sacculated; the cysts that rose from the fundus being so thin as to resemble the intestine. The ureters and pelves also were considerably dilated.

From a gentleman, æt. seventy-eight years, who had retention of urine for the first time five years before death, and used the catheter for two or three months. From that time he strained very much when urinating, his health was much impaired, and he finally died three weeks after a fracture of the neck of the femur. 1855.

Dr. J. B. S. Jackson.

2870. A general enlargement of the organ; and the third lobe, also, stands out prominently, of the size of a large marble, and about as round.

From a man who died of pleural disease of about five weeks' duration. Slight dysuria for about a year and a half. Considerable hematuria for four days after the pleural attack; and some dysuria, with a tickling sensation, from that time. Passed urine six times in twenty-four hours, but stream never suddenly stopped. Much given to sexual indulgence. 1852.

Dr. J. B. S. Jackson.

2871. Third lobe enlarged; and the bladder somewhat thickened and sacculated. 1847.

Dr. J. C. Warren.

2872. The third lobe is about as large as a marble, and stands directly up against the orifice of the urethra; the lateral lobes being not much enlarged. The bladder rose nearly to the umbilicus, and contained xxv . or xx . of clear urine; muscular coat much thickened and fasciculated; also three or four herniæ of the mucous membrane, near the opening of the ureters, and about as large as the top of the finger.

One of the most striking points is a very defined, smooth, thick band, of a somewhat crescentic form, about an inch behind the prostate and near the extremities of which the ureters open. In front of this band the surface is perfectly smooth, but immediately behind it there is quite a sac, reticulated upon the surface, and in which a calculus might form and lie undetected. Ureters and pelves much dilated. The kidneys were small and dense, and one is shown in the preparation. Several phlebolites about the ves. seminales; the connection with the veins being very marked.

The patient was eighty years of age, and had been failing for about a year and a half, with involuntary urine in the night until six weeks before death. No pain, and no suffering from retention. He had had, however, a "tumor" in the lower part of the abdomen, that became smaller after urination, but never disappeared, and of which the nature was never suspected. 1852.

Dr. J. B. S. Jackson.

2873. A very marked and regular enlargement of the middle lobe; the lateral lobes being somewhat enlarged.

From an old man who had been subject to retention of urine. About ten days before Dr. B. saw him, a catheter had been used, and from that time the urine dribbled away. The bladder was felt as a soft tumor, and of moderate size, above the pubes. Several instruments were tried without success; and, as the obstruction in the region of the prostate was abrupt, and there was no deviation of the catheters to one side or the other, Dr. B. made an attempt to transfix by force the projecting lobe of the prostate. The patient, however, was already exhausted, and died within an hour. The preparation shows the puncture made by the instrument, and that very nearly reached the bladder. 1859.

Dr. H. J. Bigelow.

2874. A moderate, but quite irregular enlargement of the gland; three or four pyriform masses or lobes being formed upon the right side, with the blunt extremities toward the bladder.

From a gentleman, æt. sixty-six years, who had had pain along the urethra, and frequent micturition for two

years, with occasionally an involuntary discharge of urine and fæces in the night, toward the last. Nineteen days before his death he was exposed to intense cold, and kept his bed from that time, with paroxysms like those of fever and ague, and a great aggravation of the urinary symptoms. Pain in the bladder, but not in the back; and with pus in the urine.

On dissection, there was found suppuration in the cellular tissue about one kidney, and pyelitis in both organs. The bladder, which is shown, was contracted, red upon the inner surface, and contained some pus, besides three small calculi. Phlebolites in abundance, and they are seen in the preparation. 1849. *Dr. J. B. S. Jackson.*

Within a week or two of the above case I examined another, in which there was extensive sub-peritoneal inflammation, with pus; connected evidently with an enlarged prostate, and immediately excited by exposure to intense cold.

2875. The prostatic portion of the urethra distended by a rounded tumor, that projects into it from the gland; this last being itself otherwise healthy and not enlarged. Cut open. 1859. *Dr. J. B. S. Jackson.*

2876. Abscesses in the prostate gland.

From a man, æt. forty-six years, who entered the hospital Dec. 9, 1867 (134,122). Gonorrhœa thirteen years before, and followed by stricture, but not much troubled by it. Two weeks before admission he found that he could not pass his urine, though it did afterward pass in drops, or in a very small stream; the scrotum and penis becoming swollen and painful. On admission, the scrotum was enormously swollen, inflamed, and sloughy; with phymosis, and great œdema of the prepuce. This last was at once divided by Dr. B.; and on passing a catheter, a large calculus (No. 2688) was found in the urethra, and removed by external incision; an extensive incision was then made through the scrotum, the cavity was well washed out, and a catheter was passed into the bladder and retained. Death on the fifth day.

On dissection, an abscess was found in each lobe of the prostate, about $\frac{2}{3}$ in. in diameter, and upon the left side it

opened freely into the urethra. In the cavities were found several prostatic calculi, and others were felt in the substance of the gland. The urethra was sloughy near its origin, and at that part the urine had escaped; but this is not shown in the preparation. 1868.

Dr. H. J. Bigelow.

2877. Prostatic calculi, from the above case. 1868.

Dr. H. J. Bigelow.

2878. A second specimen. The ducts of the gland were much dilated and crowded with them. (No. 699 in the Soc.'s Cabinet.) From a gentleman, æt. sixty-five years. 1863.

Dr. J. B. S. Jackson.

IV. PENIS.

2879. A portion of the prepuce removed from a boy eight or nine years of age, and who had had phymosis from birth; the orifice being only about large enough to admit a probe. 1860.

Dr. H. J. Bigelow.

2880. A slough from the urethra of a soldier, who entered a hospital in New Orleans under the care of Dr. H. — On admission, Feb. 20th, he reported a discharge for three weeks after impure connection, and for which he had used an injection of two grains of chloride of zinc to an ounce of water. This caused considerable, but not severe pain; and he had continued it for five days, when the mass suddenly began to protrude. By gentle traction $7\frac{1}{2}$ in. of the slough were drawn out, and it then broke off. It was of a grayish color, tough though flaccid, tubular in form to some extent, smooth and shining upon the inner surface, with longitudinal folds, and upon the outer surface rough. On the 1st of April he was discharged well, and, so far as was known, without any contraction of the canal.

The specimen was examined by Dr. Ellis, who thought "it was probably a real slough." It was afterward sent on to Washington to Dr. J. J. Woodward; and Dr. Curtis having "made a number of sections," both he and Dr. W. were "of the opinion that the specimen is a true slough of the mucous membrane (a part of which is pseudomembrane). The sections showed blood-vessels with their coats,

and contained blood, connective tissue cells in various stages of multiplication, etc., etc." 1865.

Dr. John Homans.

2881. Urethra cut open and showing an enlargement of the lacunæ. 1847.

Dr. J. C. Warren.

Six Thibert's models, given in 1847, by

Dr. G. Hayward.

2882. A large, defined, and sloughy abscess about the bulbous portion of the urethra.

2883. Stricture, with apparently extensive sloughing.

2884. Stricture, with an opening just behind it, upon the under surface of the penis. Also, a large, defined, circular ulcer about the membranous portion of the urethra.

2885. Stricture, with very extensive gangrene.

2886. Stricture, rupture of the urethra, infiltration of urine, abscess in the substance of the penis, and gangrene of the scrotum. Bladder thickened and sacculated.

2887. Ulceration of the membranous portion of the urethra, leading to infiltration of urine and the formation of a large abscess along the canal. The bladder is thickened and sacculated.

The following eight specimens were given, in 1847, by

Dr. J. C. Warren.

2888. Stricture near the membranous portion of the urethra ;
 . an old cavity in the prostate of the size of a nutmeg ;
 chronic disease of the bladder, and perfect disorganization
 of the kidney.

2889. Penis and bladder laid open, and showing toward the
 . membranous portion of the urethra a false passage about
 two inches in length, apparently the result of stricture.
 Bladder thick and very much dilated.

2890. Urethra laid open, and showing a false passage, but no
 appearance of stricture. Bladder very much contracted.

2891. A very close stricture, about two inches from the glans,
 and two or three lines in extent. The integument beneath
 the penis has been very extensively destroyed, but was
 beginning to cicatrize. There are also irregular, shreddy

cavities, and the same are seen in the parietes of the bladder.

2892. A close stricture, about $\frac{1}{3}$ in. in extent, and about 3 in. from the glans. A false passage commences just in front of the stricture, and extends to where the penis has been cut off near the bladder.
2893. Sloughing about the membranous portion of the urethra, but with no appearance of stricture. Bladder thickened, and rectum prolapsed.
2894. The urethra laid open, and shows a defined ulcer at the bulbous portion. It extends through the mucous membrane, and is $\frac{1}{2}$ in. in extent and $1\frac{1}{4}$ in. transversely.
2895. The prepuce almost entirely detached, and standing off from the organ at a right angle; the glans being completely uncovered and shrunken. Urethra laid open, and shows the lacunæ enlarged, but no stricture.—From a gentleman of very dissipated habits, and who died perhaps thirty years ago.
2896. The inside of the prepuce covered by venereal warts. There being a complete phymosis, the prepuce was slit up, and then cut off. A few detached warts in the bottom of the jar were from the glans.—The patient had had gonorrhœa about a year before. 1857.

Dr. H. J. Bigelow.

2897. Penis amputated for extensive epithelial cancer.

The patient, æt. fifty years, had had dysuria for sixteen weeks, and an external sore for four. Upon the body of the organ was an elevated, ragged, and partially ulcerated growth, from 2 to $2\frac{1}{2}$ in. in width; the organ being bent upon itself, so that the glans was directed upward. Urine passed frequently, and with scalding; and altogether through an opening in the prepuce for the last two weeks. Patient kept awake by pain, but looked pretty well. (Hospital 77, 194.) 1859.

Dr. H. J. Bigelow.

- 2898-9. Thibert's model. Cancer of the glans and section. 1847.

Dr. G. Hayward.

2900. The whole glans more or less diseased; and toward the corona extensively destroyed by malignant-looking ulcera-

ation; the corresponding portion of the prepuce being entirely destroyed. 1847. *Dr. J. C. Warren.*

2901. Glans greatly enlarged, rough, irregularly ulcerated upon the surface, and labelled by Dr. W., "Cancer." Prepuce cut through anteriorly, and looks healthy. 1847.

Dr. J. C. Warren.

2902. Cancer of the glans.

The patient was fifty years of age, otherwise healthy, and entered the hospital June 7th (38, 234). In Feb. the glans was slightly enlarged and indurated; and the orifice of the urethra was somewhat obstructed. As the disease increased, the prepuce became œdematous, with phymosis; and toward the last of April ulceration began. On admission, the whole glans was hard, irregular, nodulated, superficially ulcerated, and about one-third larger than natural; myriads of minute vessels running over the surface, from the dorsum of the penis, and bleeding on the slightest pressure. The prepuce was drawn back with difficulty, and the urine was still discharged in a very fine and twisted stream, and with much effort. — After the removal of the organ, the glans was found to consist of a uniform, pearly white, dense, coarse structure, with some encroachment upon the corpora cavernosa; the fibrous envelope of these last being much thickened, and quite dense so far as the disease extended. Microscopically malignant. — Patient recovered well from the operation, but showed himself at the hospital the following winter with a return of the disease. 1849. *Dr. S. D. Townsend.*

2903. Epithelial cancer of the glans.

From a man forty-four years of age. (Hospital, 79, 50.) Disease, which was of three years' duration, began at the base of the glans, and was followed by paraphymosis. On admission, a foul, deep ulcer encircled the penis from the base of the glans toward the pubes, for more than an inch in extent, and with a ragged collar of exuberant granulations along the upper edge. Great pain. No marked enlargement of inguinal glands. — After removal, on the 17th of April, the structure appeared of a dull white color, and the epithelial character was well marked, microscopically.

Corpora cavernosa involved. — May 20th, there was an infiltration of urine, followed by erysipelas and sloughing. He recovered, however, well from this attack, and left the hospital on the 2d of August, but with a nodule in the groin about twice the size of a hen's egg. 1858.

Dr. H. G. Clark.

2904. Disease of the prepuce, regarded by Dr. W. as cancerous. The patient was twenty-five years of age, of robust health, and had had complete phymosis for a long while. About six months before Dr. W. saw him, it became ulcerated upon the inner surface, and gradually swollen, hard, and somewhat painful. After removal, it appeared as a uniformly white and firm stricture. 1850.

Dr. J. C. Warren.

V. BREAST.

2905. Non-malignant disease.

From a physician, æt. thirty-eight years, who first felt in Sept., 1856, and without known cause, an itching, burning, and stinging sensation in the nipple; with a lancinating pain in the base of the same, and for about two inches around it. Early in the disease he scratched off a scab, but this never formed again, and the nipple was otherwise healthy. In the course of the first month a tumor was felt, and this, with the pain, etc., gradually increased. In Feb. it was removed, and, after the operation, appeared as a defined, somewhat oval mass, $1\frac{3}{4}$ in. by $2\frac{1}{2}$ in., and about $\frac{1}{2}$ an in. thick in the centre; surfaces convex and edges thin. It was closely connected with the nipple, but quite free from the skin,—both of which were healthy. In structure it was fleshy to the feel, and consisted of a whitish, fibro-cellular tissue, with numerous minute, transparent, firm granulations within a line and a half of the external surface. Microscopically, Dr. Ellis found fibrous tissue mainly, and no appearance of carcinoma.

In 1869 the patient was in robust health, and reported that he had had no further trouble with the breast. He served, however, during the Civil War, and while at the South had swelling with considerable irritation of the other breast, but this, after a time, entirely subsided. 1857.

Dr. J. B. S. Jackson.

2906. Scirrhus. 1847.

Dr. C. J. Warren.

2907. The same; a typical specimen, microscopically, and to the naked eye.

From a gentleman, æt. sixty-nine years. Disease of four or five years' duration. The tumor had doubled its size during the last year; and, at the time of removal, was half as large as a horse-chestnut.

Dr. B. reports this as the third or fourth case that he has met with. 1864.

Dr. H. J. Bigelow.

2908. The same. From a man, æt. forty-nine years. (Hospital, 91, 174.) Disease began three years before, with a hard tumor in the breast, of the size of a pea. This increased slowly; and in a year and a half pain began, and became very severe, piercing and shooting toward the axilla. When seen, the tumor was $1\frac{1}{2}$ in. in extent, scirrhous to the feel, with the nipple in the centre, and adherent to the skin. During the removal the pleural cavity was accidentally punctured, but no bad consequences followed. 1861.

Dr. G. H. Gay.

SERIES XXXVII. — UTERO-GESTATION.

I. PARTS CONCERNING THE MOTHER.

2909. Tubal pregnancy.

The uterus measures $3\frac{3}{4}$ in. by $2\frac{3}{4}$ in., and in thickness $\frac{3}{4}$ in. Decidua strongly marked. The ovum is in the right tube, measured 2 in. by $1\frac{1}{4}$ in., and the fœtus is plainly seen, about as large as at two and a half to three months. The tube is extensively lacerated, but the fimbriated extremity, through which the membranes protrude, is not involved. Both ovaries were very carefully examined, but no corpus luteum was found. The peritoneal cavity was, as usual, filled with blood.

The case occurred at the State Almshouse at Monson. An Irishwoman, æt. twenty-five years, had passed two menstrual periods, and on the 1st of Feb. complained of constipation and pain through the pelvis during defecation.

This she had had for four or five weeks, but was otherwise quite well. On the morning of the 13th she had a very severe attack of pain, after a dejection, and this continued; but at 2 P. M., having got relief, she arose, dressed herself, and went down stairs. There she became faint and vomited, and the pain returned with increased severity, and symptoms of collapse. She rested quietly, however, through the night, but the next morning fainted on going to stool, and died at 10 A. M. 1857.

Dr. S. D. Brooks, Sup. of the Almshouse at M.

2910. A second specimen. The uterus is seen cut open, with the tube, and the corpus luteum.

The woman was twenty-seven years of age, and about ten weeks' pregnant. Four or five weeks before death a discharge came on, supposed to be catamenial; this ceased after continuing for three weeks, but reappeared a day or two before death. Attacked in the morning with agonizing pain, and she died in six hours, with the symptoms of internal hemorrhage; the nature of the case having being recognized by Dr. S.

On examination, three pints of blood were found in the peritoneal cavity. The ovum was in the outer half of the right tube, $1\frac{1}{2}$ in. in length, and no part of it had escaped from the tube; the rent in this last being irregular, and $\frac{1}{2}$ in. in length. Uterus $3\frac{1}{2}$ in. in length, and without a trace of decidua. Corpus luteum in the right ovary, and finely marked. 1860.

Dr. H. R. Storer.

For a collection, by Dr. G. H. Lyman, of eleven cases of tubal pregnancy that have occurred in this State, and mostly in this city, including the above, see *Med. Jour.*, Vol. LXI. p. 464.

2911. Oviduct of a fowl, greatly distended by yolks. 1861.

Dr. J. B. S. Jackson.

A similar specimen to the above is in the Med. Soc.'s Cabinet, No. 712.

2912. Interstitial pregnancy.

From an unmarried girl, twenty years of age. Pain in abdomen came on at 6 A. M., followed by faintness and great distress, and she died at $5\frac{1}{2}$ P. M. The cavity of the

abdomen contained three quarts of fluid blood, besides a large coagulum, in which last was an ovum. The uterus is about twice its usual size, and lined by decidua. In its substance a cavity is seen that, in the recent state, was about as large as a small hen's egg, and into which the right Fall. tube opened, though the cavity did not open into the general cavity of the organ. The rupture of the cavity that contained the ovum into that of the peritoneum was about an inch in length. (See No. 2921.) 1855.

Dr. C. H. Stedman.

2913. Wax model, from Paris, showing the uterus, with its appendages, and in or near each ovary a cyst containing a fœtus of two and a half to three months. 1847.

Dr. J. C. Warren.

2914. A fœtus, of which the bones are fully exposed, and only held together by the adipocere into which the soft parts are changed; the whole being very compactly doubled upon itself.

From a woman, æt. forty, who had had six healthy children. She died insane, and nothing was known of an extra-uterine gestation.

The sac (No. 2915) that contained the fœtus was in the lower part of the abdomen, upon the left side, with strong external adhesions in part, varying in thickness, but compact in structure, cretaceous to a small extent, and without any appearance of a placenta. The fœtus lay free in the cavity; and from its weight (4 lbs.), and the size of the bones, had probably reached the full term. A few loose bones, and some fœcal matter were also found in the sac, which communicates with the rectum by two small openings; and one or two small bones were found in the intestine. The ovaries and Fall. tubes are normal. 1865.

Mr. Robert L. Dryer, med. student.

2915. Sac from the above case. 1865. *Mr. Dryer.*

2916. The greater part of the bones of a fœtus, that was not far from the full term; discharged from the rectum, and displayed by Dr. R. M. Hodges upon a black-board.

The patient, about thirty years of age, consulted Dr. S. in Sept., 1861, for a pain that she had had in the lower part

of the abdomen for several months, and that was sometimes very severe. There was a slight fulness upon the right side of the abdomen, and, after a vaginal examination, she was thought to be pregnant. Twenty days afterward she had for twelve hours violent pains, like those of labor; and these she had occasionally afterward in a less degree. Early in November she had diarrhœa for ten days, and the discharges were exceedingly offensive; there being, also, a dark, sanious, vaginal discharge, with vomiting. For several weeks her situation was exceedingly alarming; and during this period of prostration the bones began to be discharged. The discharge continued until the following July, and the assistance of Dr. S. was often required. From July, 1862, she gradually improved, and in the autumn took charge of a large boarding-house. 1865.

Dr. D. H. Storer.

2917. A collection of foetal bones, which were found "imbedded in the fat below the kidneys" of a sow. Some of them are loose, but they are otherwise intimately fused into a mass about three-fourths as large as the fist. Upon the surface are seen very distinctly a scapula, humerus, several ribs, and an upper jaw with four teeth protruding from it. Dr. M. having sawed the mass before he sent it, there is seen a large cavity, that appears to be that of the cranium, and within it a basilar bone, a portion of a vertebra, and of a pelvis, the crowns of teeth, and a quantity of hair. Between this cavity and the external surface of the mass is an irregular and much smaller cavity, in which are seen portions of long bones; and, upon the surface of what appears to be a cranium, there is hair, and some appearance as of a scalp. Over a large part or the whole of the external surface of the mass, also, there seems to have been a thin membrane, with short hairs upon a portion of it. 1869. *Dr. W. H. McDonald, of Antigonish, Nova Scotia.*

2918. The vagina of a sheep, that had been greatly distended by foetal bones. 1854. *Dr. W. Read.*

Deformed pelvis. (See Nos. 1567-74.)

2919. Rupture of the posterior portion of the uterus and vagina,
• about 3 in. in length, and nearly longitudinal.

From an Irishwoman, about thirty-five years of age, and who had had six children previously. Attended by a midwife; and had been in labor ten or twelve hours when Dr. S. saw her. The fœtus, which had escaped into the abdominal cavity, was turned, and delivered by the feet without much difficulty; there being a cessation of pains, and some collapse. Peritonitis came on in one or two days; and the patient died on the eighth day. — On examination, a thin layer of lymph was found; but no other effusion, and no blood. The uterus had contracted, so as to close the opening. 1857. *Dr. D. H. Storer.*

2920. Contraction of the vagina, with obliteration of the uterus.

The patient had a difficult labor in the winter of 1845–6, followed by inflammation of the vagina, and, as the patient thought, by a total closure of the canal; there being complete amenorrhœa, but without swelling of the abdomen. In Oct., 1850, she died of phthisis.

The contraction was an inch within the vulva, and during life would only have admitted a large goose-quill; but, when the specimen was received by Dr. B., it readily admitted, before being cut open, the handle of a scalpel. Cicatrization commences just behind the orifice of the urethra, and the surface is indurated and somewhat irregular. The whole circumference is affected, but the extent is quite limited; and the vagina, above, is sufficiently large, and quite healthy. The uterus is small, and the cavity completely obliterated, except perhaps to a small extent in the cervix. 1850. *Dr. H. I. Bowditch.*

II. PRODUCT OF CONCEPTION.

2921. Fœtus, with the membranes, from a case of interstitial pregnancy. (No. 2912.) The entire length of the fœtus is $1\frac{1}{2}$ in. 1855. *Dr. C. H. Stedman.*

2922. A fœtus, from a case of extra-uterine gestation.

The patient, æt. twenty-four years, was first seen by Dr. Willis, of Waltham, on the 4th of Jan., with intense pain in the abdomen; the uterus being slightly depressed, and very tender. She kept in bed mostly for four or five

weeks, but was at last able to sit up for several hours. On the 12th of March symptoms of internal hemorrhage came on, and she died in eleven hours, — in the fourth month of pregnancy.

On examination, a large effusion of blood was found in the peritoneal cavity; and in that of the pelvis an entire ovum, that appeared to lie between the Fallopian tube and ovary, but the exact connection of which, with the surrounding surface, was not ascertained. The foetus is well-formed, and $6\frac{1}{2}$ in. in length. The uterus was 4 in. in length, changed as usual in pregnancy, and lined by a decidua. 1863.

Dr. C. Ellis.

2923. A foetus that was sent from the country to Dr. S., as having been carried twenty-two months beyond the full period of gestation, but which was without any reasonable doubt a case of extra-uterine gestation.

The patient, æt. forty-two years, had had several children and miscarriages, and had good reason to suppose that she had reached the full period of pregnancy in April, 1858. Labor pains then came on, but not very actively, and they soon subsided. Menstruation had occurred two or three times before April, and continued to afterward so long as she lived, though irregularly and scantily. A tumor remained in the hypogastrium; but the woman enjoyed good health until Oct., 1859, when she fell down stairs. This was followed by great pain in the abdomen, nausea and vomiting, and four weeks after the accident by copious, loose, and very offensive discharges from the bowels. In Feb., 1860, she died.

On dissection, the fundus of the uterus was found very extensively adherent to the small intestine, and also to the sigmoid flexure of the colon. In the cavity that contained the foetus there was no trace of a placenta, but about a pint of thick yellow fluid, with feculent matter, which last was explained by an opening from the cavity into the colon, and through which the left hand and fore-arm of the foetus had passed. — The foetus now weighs (1868) 2 lbs. 13 oz.; and the length of the spine is nearly 7 in. Cranial bones, and the ends of many of the long bones de-

nuded, perhaps by the putrefactive process, though the flesh is generally sound. (Med. Jour. Vol. LXII. p. 400.) 1860.

Dr. D. H. Storer.

2924. Cystic disease of the ovum, from a woman who had been flowing at intervals for several months, and who thought herself pregnant.

The mass was about three times as large as the fist. Cysts generally quite large, and connected by portions of the foetal membranes; the cavity of the amnion being quite distinct, with traces of a decidua, though there was no trace of an embryo. 1863.

Dr. Wm. Mason, of Charlestown.

2925. A second specimen. — The foetus, which is quite plump and healthy in appearance, weighs $1\frac{1}{2}$ oz., and measures $4\frac{1}{2}$ in. in length. The cord, amniotic cavity, and a considerable portion of the chorion, are also quite healthy; but with these are seen numerous cysts, of variable size, and there were discharged with the ovum about two quarts of them.

The patient was thirty years of age, had had two children, and the diseased ovum came away at the end of the third month. There had been more or less, and sometimes considerable, flowing during the last six weeks; and vomiting was an urgent symptom during the whole period of pregnancy. 1863.

Dr. G. H. Gay.

2926. A third specimen. — The whole mass was about half a pint in amount; the cysts varying from a pin's head to half an inch in diameter. Decidua distinct, but no trace of a foetus.

For the first three months after menstruation ceased, there was pain in the back, with bearing-down, leucorrhœa, etc. At the end of the second month the uterus was enlarged, but it had subsided at the end of the third. Hemorrhage occurred at the middle of the fourth month, and increased, with pain, for a week or more, and the "hydroids" then came away. The woman had had one child, or more, and did not think herself pregnant.

Dr. Waldo J. Burnett examined some of the cysts, microscopically, and "found the parietes to consist of a

simple aggregation of minute granules, such as constitute the primary cell membranes, but neither fibrillæ, fibres nor vessels; the structure being quite different from that of cysts in general. The liquid contents were hyaline; and, in the larger ones, the granules were suspended for precipitation upon the internal surface; the action of acids showed the presence of albumen." 1850.

Dr. Chas. G. Putnam.

2927. A blighted ovum, about 2 in. in diameter, with a large portion of the decidua vera, but not a trace of an embryo. 1861.

Dr. Anson Hooker, of E. Cambridge.

2928. A second specimen.— The foetus is about as large as at the sixth week; the membranes forming a thick, fleshy, opaque mass, knobbed upon the inner surface, and about $3\frac{1}{2}$ in. in diameter. Menstruation ceased on the 15th of June, and was followed by symptoms of pregnancy. About the 1st of August, the patient lost a child very suddenly; and from that time the morning sickness ceased, the breasts became flaccid, and after one or two hemorrhages, pains came on, and the ovum was expelled on the 21st of October. 1849.

Dr. M. S. Perry.

2929. A third specimen.— The ovum, which was retained for thirteen months, is of an oval form, about 4 in. in length, and consisted of a whitish, opaque, ill-defined tissue, with traces of chorion, the remains of effused blood, and numerous little cysts. There were also numerous little cavities, from 1 to 4 lines in diameter, and that had a serous-looking surface within, though they were unlike the other cysts; and in some of them were small, granular, cretaceous bodies.

From a woman, æt. forty-two years, who had had prolapsus uteri for three years. In Dec., 1850, menstruation ceased, and in February there were symptoms of pregnancy. In May the swelling of the breasts subsided. Some fulness in hypogastrium; but there was no increase after the fourth month, and about the sixth it subsided. During the first six months there were more or less bearing down pains; in June, September, October, and November, slight, dark, and quite thick discharges from the uterus, which

was enlarged and tender. During the latter half of December two very considerable hemorrhages. About the 1st of Jan. severe and increasing pains came on, and on the 22d the ovum was expelled. 1852.

Dr. E. Leigh. of Townsend.

2930. A fourth specimen. — The membranes are about $1\frac{1}{2}$ in. in diameter, and have the usual opaque look, and stiffened feel, without any appearance of villosities. The foetus and cord are, each, $\frac{3}{8}$ in. in length; and the umbilical vesicle appeared, as usual in abortions at the sixth week, like a yellowish, opaque, compressed, albuminous mass, about a line in diameter.

The woman had had a child four years before, followed by ulceration of the os uteri, and, meanwhile, four miscarriages. Toward the end of May she became pregnant. About the middle of July flowing came on, and continued until after the middle of November, when the ovum was expelled. 1861.

Dr. D. H. Storer.

2931. A fifth specimen, rather smaller than the last, but the same in regard to structure, and the umb. vesicle. Inner surface botryoidal, as it so generally is. Foetus rather shorter than the last, and very nearly ovoid in form. Cord $\frac{5}{8}$ in., and constricted midway.

The woman, having had the usual signs, etc., of pregnancy, had a slight discharge of blood at the end of the third month. At the end of the fifth, the abdomen had ceased to enlarge, and she had various nervous and other symptoms. At the end of the seventh month, and having been quite well for the last few weeks, she made a sudden effort, and the ovum came away. 1861.

Dr. D. H. Storer.

2932. A sixth specimen. — A thick, condensed, pyriform, diseased ovum, that was sent to Dr. S. as a polypus that had been expelled. The cavity is distinct, but there is no trace of embryo nor cord. 1862. *Dr. D. H. Storer.*

Cases of blighted ova are sufficiently common here, and show that we ought not always to persist in an attempt to prevent miscarriage. The ovum is diseased, and ought to come away, as a worm-eaten apple drops from the tree. In regard to the diagnostic marks of a blighted and re-

tained ovum, there are often occasional, slight hemorrhagies, as in some of the above cases, and pregnancy, that had been supposed to exist, comes to be questioned; and so the case may go on for months.

2933. A blighted fœtus, $7\frac{3}{4}$ in. long, and weighing $3\frac{1}{2}$ oz. The surface was tattered, and it had the usual flattened and macerated look; the vessels in the cord being no larger than the smallest sewing thread, and looking as if no blood had passed through them for a long time; and yet, as usual in such cases, there was no sign of decomposition. The inner surface of the amnion was roughened by a pasty or crumbling deposit.

From a case of twins, — the other child weighing 12 lbs. When the mother was four and a half months pregnant, she had a diarrhœa for twenty days, but was well from that time. 1861.

Dr. D. H. Storer.

2934. A fœtus, $3\frac{1}{2}$ in. in length, and having the flattened, bloodless look above referred to. The different parts are sufficiently distinct, but confused by a very delicate membrane, that partly and immediately invests the surface. The whole is quite soft; and, the surface being broken near the umbilicus, there was seen a trace of the deep-yellow discoloration that is so common in blighted fœtuses (kirronosis, of Lobstein). One child was born at the full period; and, after the placenta came away, the second fœtus was found in the vagina, and enclosed in its membranes. These last were collapsed; and the placenta was thin, compact, granulated, and bloodless. 1852.

Dr. E. D. G. Palmer.

2935. A fœtus, about $\frac{5}{8}$ in. long, and about as much developed as at the seventh or eighth week. The last menstrual period ended Jan. 23d; symptoms of pregnancy followed, and abortion took place on the 20th of April, 1863.

Dr. J. G. Blake.

2936. A fœtus, about as large as at the fifth or sixth week, and apparently blighted. 1847.

Dr. J. C. Warren.

2937. A fœtus, quite plump, but less than $1\frac{1}{2}$ in. in length. At the fourth month, as was supposed, the breasts became

flaccid, with a sense of coldness of the abdomen, etc.; and at about the ninth month the ovum was discharged. 1854.

Dr. D. H. Storer.

For a blighted anencephalous fœtus, see No. 835.

2938. The umbilical cord, passed twice round the neck of a fœtus, of four and one-half months. There is, also, disease of the placenta. 1859.

Dr. D. H. Storer.

2939. A knot in the umbilical cord. 1857.

Dr. D. H. Storer.

2940. Two knots in the cord, about 4 in. apart, and one of them is in the form of the figure 8. The cord was 36 in. in length. 1858.

Dr. Edward Coale.

2941. A placenta, dried, with a cretaceous deposit upon the maternal surface. Labor natural. 1858.

Dr. C. G. Putnam.

SERIES XXXVIII.—TUMORS.

2942. A very thin cyst, $2\frac{3}{4}$ in. in length, and nearly 2 in. in diameter. "From the neck." 1847.

Dr. J. C. Warren.

2943. A very thin cyst, 5 by 3 in. in diameter, and referred to by Dr. W. in his work on Tumors, p. 543. It occupied the whole side of the neck, and involved all of the deep-seated and important parts.

From a man, thirty years of age. Tumor of several years' duration, and had of late much increased. No fluctuation, but felt as if composed of solid and fluid parts. No pain except from distension. Internal jugular vein divided, and tied in the course of the operation; and the sac, when cut, discharged a quantity of glairy fluid and flocculi. The wound healed by the first intention. 1847.

Dr. J. C. Warren.

2944. Daguerreotype of a case of hydrocele of the neck; a large ovoid tumor upon the right side, and of several years' duration.

From a man, æt. twenty-two years. The sac contained a turbid, purulent fluid; and it was mostly extirpated, though there was, as usual, a deep and narrow prolongation backward, that could not be removed. No recurrence. 1858. *Dr. H. J. Bigelow.*

2945. A second daguerreotype, and of a similar case.

The patient was forty-four years of age, in delicate health, and the disease had existed for about one year. It appeared first above the clavicle, and of the size of a shag-bark; in six months it was of the size of a hen's egg; and when the woman entered the hospital (55, 194), it was larger than the fist, translucent, fluctuating, painless, and extending under the trapezius muscle. Most of the sac was removed; and the portion that extended under the muscle and clavicle was tied; ʒvj. of fluid being discharged, of the color of coffee and milk, with cholesterine and inflammatory products. — The patient was discharged on the tenth day, doing well, though the wound was still discharging. 1858. *Dr. H. J. Bigelow.*

Cyst in posterior nares. (See No. 2068.)

2946. Daguerreotype of a case of hydrocele of the neck.

The subject was an infant, six months old. The tumor, which was congenital, was soft and fluctuating, extended from the angle of the lower jaw, beneath the clavicle, to the third rib, and disappeared on strong pressure. Nov. 7th, 1863, Dr. B. punctured it, and removed ʒvj. of serum. A sound was then passed down within the cyst, and to a point just below the axilla; a second puncture was made at this point; a thread was carried through, and the ends tied. On the 17th this last was removed; the tumor gradually disappeared; and Dec. 15th the child left the hospital well (111, 98). 1868. *Dr. H. J. Bigelow.*

2947-8. Daguerreotype of a case of oil cyst, below the ear.

The patient was a man, forty-five years of age, and the tumor that had been forming from the age of three years, was first noticed after the healing of an abscess in the ear; this gradually enlarged until the last two years, and then more rapidly. At the time of the operation it was of the

size of a hen's egg, immovable and painless; the integuments being healthy. Adhesions everywhere intimate, and even to the styloid process. It was, however, dissected out entire, except at one point, where at the summit of the cyst was a hole, large enough to admit a probe, passing through the cartilage of the ear, and appearing beneath the skin, within the concha, and near the meatus; and from this, as a point of departure, Dr. B. thought that the whole cyst had expanded. The inner surface of the cyst was mostly red and shining; but, microscopically, an imperfect epithelium was seen, and particularly toward and within the perforation. The contents were very remarkable; ξ ij. of a limpid yellowish oil, perfectly resembling common lamp-oil, and congealing soon after its discharge, at a temperature of 65° ; followed by about a dessert-spoonful of what appeared to be a ceruminous and epithelial substance, in the form of whitish, opaque, flocculent masses. A small seton was passed through the perforation in the cartilage; and the patient did well. 1858.

Dr. H. J. Bigelow.

2949. A meliceric cyst, removed from beneath the chin of a healthy lad, fifteen years of age. (Hospital, 79, 52.) The tumor began seven years before, on the median line, increased slowly, and only troubled the boy mechanically. Extended to the left angle of the jaw, and looked like a double chin; fluctuation perfect.

The sac contained ξ ij. or iv. of thick, gray, meliceric matter, and was lined apparently by skin. At the end of three weeks the patient was discharged, with the wound nearly healed. 1858.

Dr. H. J. Bigelow.

2950. Contents of the above cyst; composed of large pavement epithelium, fatty matter, and cholesterine. 1858.

Dr. H. J. Bigelow.

2951. Thibert's model. An atheromatous tumor beneath the scalp, about 2 in. in diameter. 1847.

Dr. Geo. Hayward.

2952. A thin cyst beneath the scalp, and filled with fluid; about 2 in. in diameter. 1847.

Dr. G. Hayward.

2953. Cast of an encysted tumor from the scalp; of a flattened

form, 1 in. in diameter, and $\frac{3}{8}$ in. thick. At the operation, it was found to be almost wholly contained in a cavity that it had formed for itself in the substance of the parietal bone; the edges of the cavity being sharp, and the depth more than $\frac{1}{2}$ in. The aperture allowed but a small portion of the tumor to project above the surface of the surrounding bone; and this portion alone was felt before the operation. The bottom of the cavity was formed by the internal table of the parietal bone, and was so thin as to spring under pressure.

The patient was a young man, æt. twenty-six, and reported the tumor as of three months' duration; but Dr. H. thought it in all probability congenital, and that the depression in the parietal bone was analogous to the depression that is sometimes seen in congenital, circumorbital, encysted tumors. (Hospital, 122, 58.) 1865.

Dr. R. M. Hodges.

2954. A cast, to show the depression in the parietal bone in the above case. 1865.

Dr. R. M. Hodges.

2955. A cyst, from the head, about as large as a hen's egg; inverted and stuffed. Inner surface generally quite smooth; but at one part there is skin, with black hairs growing from it. 1847.

Dr. J. C. Warren.

2956. Balls of fatty matter, from a cyst upon the top of the head (Hospital, 51, 188); of a yellowish-white color, soft, cheesy consistence, and averaging 2 or 3 lines in diameter. For a daguerreotype of the patient, cast of the tumor and cyst itself, see Nos. 1240, etc., in the Med. Soc.'s Museum. 1852.

Dr. Samuel Parkman.

2957. A cyst, removed from over the sternum, and perhaps congenital.

From a man, forty-five years of age. The inner surface is cuticular, with hairs growing from it; and the cavity was filled, when recent, with balls of fat, 3 or 4 lines in diameter, intermixed with epithelial scales and loose hairs; the resemblance to the last case being very striking. 1852.

Dr. S. D. Townsend.

2958. Hair from the above cyst. 1852.

Dr. S. D. Townsend.

2959. A congenital cyst from the upper and outer part of the orbit of a child, four years old; of an oval form, about the size of a small filbert, and filled with fatty matter and hair. 1852. *Dr. Robert W. Hooper.*

Cyst containing hair, from the testis. (See No. 907.)

2960. A cyst from over the first, but near the second phalanx of the thumb; between the skin and the flexor tendon. It is about half an inch in diameter, not very thick, but has a dense, fibrous, pearly look, and was filled, when recent, with a substance of an atheromatous consistence. — From a man who entered the hospital for fracture (75, 16). 1857.

Dr. H. J. Bigelow.

2961. A material, removed from a cyst, and that resembled thick, coarse, Indian-meal gruel; the greater part consisting of opaque yellow flakes, to the naked eye, and of epithelial scales, microscopically. About $\frac{3}{4}$ v. or $\frac{1}{2}$ v. altogether, were removed; and the appearances are well preserved.

From a woman, forty-nine years of age, who had had the tumor over the upper part of the scapula for more than thirty years. Occasionally it inflamed, but generally it only troubled her mechanically. The parietes of the cyst were thick; and its interior was lined by a thick, rough, irregular, foliated cuticle, with many raised, crater-like points, as from follicular origin. Dr. B. has, in his collection, a fine colored drawing of this case. 1856.

Dr. H. J. Bigelow.

2962. An encysted tumor from beneath the skin, in the gluteal region.

It weighed $4\frac{1}{2}$ oz., and consisted of epithelial scales, concrete sebaceous matter, and carb. and phosph. of lime; no cholesterine. It was nearly round; laminated in structure, and so hard that it had to be sawed for examination. The inner surface of the sac was lined with soft epithelium. — From a clergyman, about forty years of age. Tumor of twenty years' duration; always hard and painless, but mechanically troublesome. Sent to Dr. D. by Dr. H. C. Perkins, of Newburyport. — One-half of the tumor is shown; dried. 1854. *Dr. S. Durkee.*

2963. A cyst from under the tongue.

The patient, æt. nineteen years, entered the hospital (81, 111) with a prominent, fluctuating, deep-seated, painless tumor, filling the space between the symphysis, and the angle of the jaw upon the left side, and protruding into the mouth; and it was as large, she thought, when first noticed eight months before. Integument not affected. Discharged about ʒij. of a yellowish, cheesy material. The cyst, inverted and stuffed, shows the epidermal character. 1859. *Dr. H. J. Bigelow.*

2964. A cast, showing a cyst about the middle of the sole of the foot.

The patient was a boy, twelve years old, and his parents thought that the disease was congenital. It was increasing in size, but there was no pain nor other trouble from it, unless he wore a tight boot. On admission into the hospital, under the care of Dr. H. (125, 140), it was apparently about as large as an English walnut, — about one-half projecting above the surface, smooth and elastic, or imperfectly fluctuating. Skin adherent but not discolored. No pain on pressure. It was situated between the fascia and the muscles; and was easily removed; with a copious discharge of white, cheesy material, consisting of epithelial scales, fat, and cholesterine. Considerable inflammation followed the operation, but in rather over two weeks the wound had quite healed. — The cast was taken by Mr. C. Pratt, house-pupil. 1866.

Dr. R. M. Hodges.

2965. A cyst from the palm of the hand.

The patient was a middle-aged woman, and had had a tumor for ten or twelve years near the anterior extremity of the second or third metacarpal bone, but with scarcely any trouble from it until the last two or three months, when inflammation appeared upon the corresponding part of the back of the hand. The cyst, which had a fluctuating feel, having been opened by Dr. B., discharged about ʒss. of pus and pultaceous matter; and it was then dissected out; not connected with the tendon. The parietes are quite thick, firm, laminated, and capable of holding

from a sixth to one-fourth of a drachm. An abscess seemed to be forming in connection with the cyst, and toward the back of the hand. The patient did well. Cast taken by Mr. R. P. Lincoln, one of the house-pupils. 1867.
Dr. H. J. Bigelow.

2966. A tumor from the groin, that before removal was nearly or quite as large as a hen's egg; hard, defined, not discolored, and with an opening at the summit; adherent closely to the skin and surrounding parts. It consisted of an opaque, crumbling substance, with an appearance of cholesterine, but had mostly undergone a calcareous degeneration, and was surrounded by a cyst of condensed cellular tissue.

The patient was seventy years of age, and first noticed the swelling in 1827. In 1837 it suppurated, and remained open from that time. In Nov., 1868, the mass was removed, and the man did well, though the operation was followed by an enlargement and suppuration of the inguinal glands. (Hospital, 139, 97.)

In regard to the nature of the disease, Dr. B. could not say whether it was originally glandular or encysted. 1869.

Dr. H. J. Bigelow.

2967. A congenital tumor, and probably an epithelial cyst, that had become cretaceous from the effects of inflammation.

Removed from over the tuberosity of the ischium, of a man thirty years old. About two years before the operation, it became tender, opened, discharged a chalky matter, and then healed; but it enlarged from that time. When seen by Dr. B., it formed a projecting tumor, of the size of a filbert, and rested upon a distinct, flattened base, about an inch in diameter. This last, as well as the tumor, proved to consist of a number of lobulated, cretaceous masses; the material being in some parts hard and brittle, like chalk; and in others pasty. 1859.

Dr. H. J. Bigelow.

2968. A very unusual growth, removed from just below the eyelid. Before the operation the tumor was about the

size of a walnut, rather soft, though not fluctuating, and not discolored nor adherent.

The patient was a healthy boy, sixteen years of age, and the disease was of about a year's duration, though it had been stationary the last six months. Never tender until the last month, when the skin ulcerated, and a gush of blood followed.

After removal, the mass appeared light-colored, dryish, friable, and curiously granular; particles rolling off beneath the finger, and feeling calcareous. No calcareous matter, however, was found microscopically, but partially developed epithelial cells distributed uniformly throughout the mass. This last was perfectly homogeneous on section, though in certain directions it could be torn in non-concentric laminae. There was no marked cyst about it, and the surrounding tissues were healthy. (Hospital, 138, 203.) 1869.

Dr. H. J. Bigelow.

Encysted disease of bone. (No. 1483.)

Dentigerous cyst. (No. 2091.)

Horny growths, from cutis. (Page 397.)

2969. A fatty tumor, from the deltoid region. Weight, 5 lbs. 12 oz., and deeply lobulated. The skin was thin over it; and the veins much dilated.

From a woman, about fifty-five years of age. Duration about fifteen years. 1847.

Dr. S. D. Townsend.

The next four specimens were given, in 1847, by

Dr. J. C. Warren.

2970. A second specimen, about 4 in. in diameter, and with a peduncle of about $1\frac{3}{4}$ in. Skin at one part abraded or superficially ulcerated.

2971. A third; two-thirds as large as the head, and mostly covered by integument. This last is destroyed at one part, and very definitely, to the extent of about an inch; and a slough hangs off from within.

2972. A fourth; of the size of two fists, with a portion of skin attached, and deeply lobulated.

2973. A fifth; $2\frac{3}{4}$ in. in diameter, and not at all lobulated. Form plano-convex.

2974. A sixth; from a man, æt. forty-five years, who entered the hospital Feb. 3d, 1866 (125, 124). About twenty years before, he scratched off a "mole" from over the rectus muscle, and just above the patella. Four or five years afterward the tumor appeared; and for the last ten years there had been regular, periodic pains in it, but the motions of the part were not interfered with. The tumor was rather smaller than a hen's egg; and upon the surface, and near the centre, was a small and faintly brownish mole. The excision was followed by extensive inflammation, suppuration, and gangrene, but the man finally recovered. 1866. *Dr. R. M. Hodges.*

2975. Thibert's model. External view of a fatty tumor in the lumbar region. 1847. *Dr. G. Hayward.*

2976. The same. — Tumor beneath the scalp; about an inch in diameter. External view. 1847. *Dr. G. Hayward.*

2977. A ninth specimen. Cast, in plaster, to show the external appearances in a case in which the humerus was almost entirely surrounded by a fatty tumor. This last weighed 1 lb. 4½ oz. Troy. It was situated beneath the fascia, muscles, artery, and nerves; and passed through an opening in the triceps. Removed by two straight incisions; and no ligatures required.

The patient was a lad, fifteen years of age; and the tumor had existed for seven years. 1856.

Dr. H. J. Bigelow.

2978. A tenth; tumor removed from the external labium.

The patient was an Irish girl, twenty years of age, and the tumor had existed for two years. Form regular; length, 7 in.; and, being pedunculated, it hung down between the thighs like a bull's scrotum. It had recently ulcerated upon the surface, and that led her to speak of its existence, which she had kept entirely to herself until the day before the operation. Previously she had been troubled only by its weight, which, after removal, was found to be 2¾ lbs. 1855.

Dr. S. D. Townsend.

2979. Eleventh specimen. The tumor weighed about 2 lbs.; and was removed from the scrotum by Dr. Kimball, of Lowell.

The patient, an Irishman, æt. twenty-three years, had had occasional and sometimes severe pain in the testicles for about five years, with occasional dysuria. About a year after the pain began, the tumor was felt in the lower part of the scrotum, and the man was pretty sure that it had not descended from above. (See Med. Jour. Vol. LXV. p. 222.) 1861.

Mr. S. G. Minassian, med. student.

Large and congenital development of fat in the fore-arm. (See No. 924.)

2980. Cast of an abdominal tumor, that weighed 80 lbs. Its general form is that of a flattened mass, about 22 in. in its two largest diameters, and 6 to 8 in. in thickness. It was composed of many lobes, some of which were quite firm, and others so soft that they fluctuated. Two irregular masses of bone were also found, of which one was larger than an English walnut, and the other about as large as the top of the finger; situated in a dense fibrous tissue, and containing laminae and true bone corpuscles. Portions of the surface were quite vascular; but the prevailing color was white or yellowish-white. In structure, some of the lobes had a fibroid appearance, though a large portion of the tumor showed an intermixture of adipose substance. The fat in some parts was of a whitish color, but contained, like the yellow portions, the usual adipose cells. The soft, fluctuating lobes were composed of a delicate, moist, fibrous tissue. In the centre of one of the largest lobes was an irregular cavity, surrounded by brownish tissue, and evidently softening.

The patient, who had been under the care of Dr. Geo. C. Lincoln, of S. Malden, was a sailor, twenty-five years of age, and rather slightly built, though healthy until Nov., 1859, when he first noticed an enlargement of the abdomen. He did not give up his work, however, until he arrived home toward the last of December. For the next two months he kept about, but was considerably troubled by his increased bulk. In March he entered the hospital (230, 8), and was there for a short time; the abdomen being enormously swollen, tense, and inelastic, like stiff leather, imperfectly fluctuating, and very slightly tender at

some points. There was then a considerable amount of ascites, and afterward some œdema of the lower extremities. In April, 1861, the abdomen measured 52 in. in circumference, and was smooth and symmetrical. In May general convulsions came on, and in two days he died.

On dissection, the peritoneum contained a little serum, but was quite healthy. The diaphragm was pushed up to the fourth rib; the arch of the colon lay above the tumor, and was firmly adherent to it; and the ascending portion, with the whole of the small intestine, lay behind the tumor, and in the right lumbar region. The origin of the tumor, which was extensively adherent, seemed to have been from the sub-serous cellular tissue upon the left side.—The spleen, and a portion of the arch of the colon are shown in the cast, to indicate the different parts of the tumor. 1861.

Museum Fund.

2981. Portions of bone from the above tumor. 1861.

Dr. C. Ellis.

2982. An enlarged and admirable drawing, in India ink, of a woman in whom there was formed a tumor that was perhaps as large as any that has ever been recorded. The estimated weight of the tumor, alone, at the time of her death, was not far from 275 lbs.; and the weight of the patient, without it, was probably not 100 lbs. The sketch was copied by Mr. Bolles from a daguerreotype, which is also shown.

A history of the case, with a wood-cut, was published in the Ohio State Medical Society's Transactions, in 1851, by the late Dr. Phillip J. Buckner, of Cincinnati, who went two hundred and twenty miles to see the patient, and who took with him a daguerreotypist, in order that he might have a drawing to accompany his report of the case. The patient having died in 1854, the late Prof. John Delamater, of Cleveland, who had seen the patient during life, published in the Cleveland Medical Gazette, Aug. 1st, 1859, a full history of the case, with a wood-cut similar to Dr. B.'s; and, in his report, he incorporated portions of Dr. B.'s, with the written statements of Drs. C. H. Beach and D. I. Johns, who were the principal attendants upon the patient, and of Dr. J. W. Smith, who had charge of her

during the last years of her life. The following is a summary of Prof. D.'s report: —

The age of the patient, at the time of her death in 1854, was thirty-six years. In 1838, and being then in the sixth month of her first pregnancy, she was kicked in the right iliac region by a cow; and to this accident she always referred her troubles. She, however, went her full time, and was confined in June; suffering afterward habitually from soreness of the side, and weakness in the loins.

In Sept., 1840, a second child was born. Six weeks before labor she lifted a heavy kettle, swooned, and, on recovery, found a small tumor protruding from the vagina. Health delicate for the next eleven months.

In 1841 she aborted at the third month, after a fright. Three days afterward she took cold, and had tenderness and fulness of the abdomen; the right side becoming so sensitive that the bedclothes were oppressive.

In 1843 a dead child was born at the full period, and after a severe labor. The vaginal tumor at this time projected 3 or 4 in. beyond the labia, was $1\frac{1}{2}$ to 2 in. in diameter, and its attachment was beyond the reach of the finger. Subsequently to this labor the whole tumor sloughed off. Difficulty of passing the urine also followed, and the catheter was used for some months. During this attack a soft, immovable tumor was felt, a little to the right of the linea alba, and almost filling the right side of the abdomen; and from that time the abdomen enlarged pretty rapidly for a year.

About four years after the tumor appeared in the abdomen, another showed itself in the right labium, extending to the nates. This last was soft and elastic, and for a year or two it could be returned within the pelvis or abdomen; but, subsequently, it enlarged *pari passu* with the abdominal tumor, and both fluctuated so distinctly that the case was thought to be one of dropsy. The tumors were tapped or incised eight times, but no fluid was discharged. The abdominal tumor had produced the most distressing dyspnœa, so that she could scarcely breathe except when on her hands and knees. As the tumor of the hip enlarged, however, the dyspnœa was relieved, as well as

the general anasarca, and a numbness of the lower extremities that she had suffered much from. At the urgent solicitation of the patient, the tumor upon the hip was opened, and the finger passed in, but a soft tissue only was felt, and very much like the omentum.

After the relief above referred to, the patient's health improved, she again became pregnant, and in 1848 was delivered at the full period; artificial means being required, and the child dying during the labor. When this was over she returned to her former condition.

Before this last pregnancy, when she was in a sitting posture, which she sometimes attempted, the abdominal tumor rested upon her thighs, and as far as her knees; there being no marked increase of size before delivery, nor diminution afterward. The tumor of the hip was 15 in. long, 10 in. in diameter at its longest part, and 4 in. in diameter at the point of its connection with the perineo-ischiatic region.

About 1850 the patient weighed on a platform scale 269 lbs. Her greatest weight, before marriage, and when in full health, was 108 lbs.; and her flesh being very much reduced, her own weight was estimated at the above date at 90 lbs., and that of the tumor at 179 lbs. From this time, or from the year before, she was confined entirely to her bed as long as she lived.

In June, 1851, when Dr. Buckner saw her, the circumference of the abdomen was 7 ft. 8 in., and the distance from the ensiform cartilage to the pubes, 3 ft. 6 in.; the form of the abdominal tumor being regular and very prominent, so that the outline, if continued, would be rather ovoid than round. The tumor of the hip extended along the thigh, and measured 2 ft. 6 in. in length, and 18 in. transversely. The circumference, longitudinally, was 4 ft., and that of the neck of the tumor was 2 ft. 2 in. It was of a regular, elongated form, and considerably larger at the upper extremity than the lower. Some slight mamillary elevations, however, existed upon the surface; but these were subsequently found not to differ from the rest of the tumor in structure.

During the last year of the patient's life, there was fre-

quently a pustular eruption upon the surface of the posterior or ischiatic tumor, and leading to superficial ulceration ; but this would in time dry up and heal. With this exception, and those already referred to, her general health was usually good, and her functions were well performed ; menstruation being regular as to time and quantity, though painful during the last few years. Toward the close of 1853 the cutaneous affection increased, her health failed, and she died in Jan., 1854.

An autopsy could not be had ; but Dr. Smith, in order to get the body into something like a coffin, removed the ischiatic tumor in the presence of the husband. Within it was a cavity into which he passed his arm to above the elbow. The arm was then passed to about the same extent upward into the pelvis and abdomen ; and, with the other hand upon the tumor, externally, Dr. S. satisfied himself that the abdominal viscera were intact, and that the tumor was external to the peritoneal cavity. The two cavities contained 8 pints of fluid ; the one in the ischiatic tumor being evidently, in the opinion of Dr. S., a process from that of the peritoneum ; and the two tumors, though entirely distinct externally, being portions of one and the same growth. The communication between the peritoneal cavity and the prolongation from it he believed to be through the sacro-sciatic notch ; but to this view of the case Prof. Delamater thought that there were objections. The ischiatic tumor consisted mainly of a soft, adipose structure, interspersed with delicate layers of fibrous tissue ; and, in bulk, the tumor was large enough to fill a common wash-tub. After the removal of the tumor the genital organs and the anus, which were fully in view, were found to be somewhat drawn to one side, but otherwise unchanged. The abdominal tumor was not examined ; but there can be no doubt, as Prof. D. remarked, that it was mainly adipose.

Prof. D. finally remarks that "the continued growth of these tumors was unabated to the end," and basing his computation on the above estimated weight of the tumor, he says "we shall get 268½ lbs. as the ultimate of the solid and fluid constituents of these abnormal productions.

Drs. Johns and Beach estimate the entire weight at 275 lbs., which I have no doubt is within the truth." 1870.

Mr. William P. Bolles, med. student.

2983. Three colored lithographs of a large, movable, fibro-cellular tumor in the groin. — The patient was a young man; disease of some years' duration, and it did not return after removal. 1st. An external view of the inguinal region, etc. 2d and 3d. The tumor before and after it was cut through. The tissue was coarse and tough; and buff-colored lobes projected from the cut surface. Nourished by an artery from the skin; there being no vessels beneath. Microscopically fibroid, with a few cells. 1858.

Dr. H. J. Bigelow.

2984. A large fibro-cellular tumor from the scrotum.

The patient entered the hospital Jan. 3d, 1864 (113, 38). He was forty-two years of age, and the disease was of one year's duration. The tumor, which had the general aspect of a very large hydrocele, consisted chiefly of slippery lobes that eluded the grasp, and was supposed before the operation to be either fatty or fibro-cellular. Behind and near the anus the insertion of the scrotum had a brawny feel, and the termination of the tumor was there undefined. On the 30th it was removed. The first lobe that was exposed declared the fibro-cellular character of the tissue; and, after a dissection, which was rendered tedious by the adhesions, the tumor resolved itself into two principal masses. Each of these was somewhat lobulated, six or more inches in length, three or four inches in diameter, and smallest at the neck. The dissection was carried downward and backward between the bulb of the urethra and the rectum, each of which was exposed, and through the triangular ligament. Their insertion was discovered, fan-shaped and expanded, high up somewhere between the prostate gland and the rectum, where ligatures were passed around the two pedicles and the masses were cut away.

These tumors, Dr. B. remarked, are interesting for their insertion high up in the ischio-rectal fossæ, which was doubtless their point of origin. The microscope showed

them to consist of a fibroid structure, with some attempt at an elongated cell-growth; and lying free within the skin and not involving it, they differ from a similar structure which is occasionally found attached to and corrugating the skin itself.

The tumor reappeared soon after he left the hospital; and when he was readmitted, Jan. 3d, 1867, it was of the size of a large cocoa-nut, and weighed, after its removal by Dr. B., $3\frac{1}{2}$ lbs.; the structure being the same as before. It was dissected from the rectum and about the prostate as high up toward the peritoneum as it was safe to go. The patient recovered well from the operation, and was discharged on the 2d of February. 1864.

Dr. H. J. Bigelow.

2985. A large, fibro-cellular outgrowth of the skin from over the left buttock.

From a woman, twenty-five years of age. The disease was of about six years' duration, growing when she entered the hospital (73, 2), and troubled her only by its weight. The pedicle was large, and abruptly defined; and the mass weighed, after removal, $13\frac{1}{2}$ lbs. The surface was discolored as in elephantiasis, wrinkled, perfectly flaccid, and knobbed to the feel as in lipoma. Confinement to the bed for a few days rendered it smaller and softer; the structure after removal being succulent from serous infiltration. A second quite distinct mass was removed from the subcutaneous tissue; well-defined, somewhat rounded, and about an inch in diameter. Microscopic appearances as in the last case. The wound after the removal of the mass was 13 by 17 in., and the patient became much prostrated, but finally recovered. The disease, however, returned before she left the hospital, near but not in the cicatrix; and, seven or eight years afterward, when Dr. B. saw her, it was about one-third as large as before the operation. 1857.

Dr. H. J. Bigelow.

2986-7. Daguerreotypes of the above case, which was published by Dr. B. in the Med. Jour. (Vol. LXX. p. 174), with a woodcut. 1857.

Dr. H. J. Bigelow.

2988. A subcutaneous tumor, nearly or quite as large as the

head of an adult; rounded, defined, knobbed, and quite solid to the feel. On incision, the structure seems to be fibro-cellular; but in the centre is a cavity, occupying one-third or more of the whole mass, and filled with a completely broken-down, curdy substance, with some of the original tissue. There is also one cyst upon the surface larger than an English walnut. No appearance of vascularity nor of malignancy. 1847. *Dr. J. C. Warren.*

2989. A tumor, of a regular, flattened, oval form, $2\frac{1}{4}$ in. by $1\frac{3}{4}$ in.; microscopically fibrous, and removed from the integuments over the lower front part of the chest of a middle-aged man. It had been forming for some years, and without pain. On section, it appeared like straw-colored fat; pale, homogeneous, and glistening. 1862.

Dr. H. J. Bigelow.

2990. A tumor from the palm of the hand; and showing, microscopically, nothing but fibrous tissue. Diameters about 2 in., $1\frac{1}{2}$ in., and $\frac{1}{3}$ in. Remarkably lobulated, like a fatty tumor, but very dense to the feel after removal.

From a sailor, æt. twenty-three years. (Hospital, 93, 68.) The tumor appeared seven years before, had grown slowly, and was never painful, though the surface was sometimes irritated by his work. Motion of the fingers not affected. On examination, it appeared to be about $1\frac{1}{2}$ in. in diameter, soft, fluctuating like a fatty tumor, not movable, and not affected by the motion of the fingers. Situated between the skin and palmar fascia; readily removed, and the man did well. 1860.

Dr. H. J. Bigelow.

2991. A cast to show the tumor, in the above case, before the operation. Taken by Mr. J. G. Blake, one of the house-pupils. 1860.

Dr. H. J. Bigelow.

2992. A rounded, pedunculated tumor, that hung off from the calf of the leg; about 2 in. in diameter. Microscopically fibrous; a portion was reddened, and had quite a malignant look; but this was attributed to inflammation.

From a man about thirty years of age. Tumor forming for a year or more, and not painful, though much irritated by his clothes. 1852.

Dr. S. Parkman.

2993. An "ear-ring tumor," about the size of an English walnut; dense and fibrous.

From a young adult negress. Disease from the age of four or five years, and attributed to ear-rings that had been put in when she was less than two years old. Troubled her mechanically, and occasionally by an excessive itching. Both ears affected. Removed in April, 1853, Aug. 1859, and 1860, and in March, 1861. Returned each time in about six months after removal. 1861.

Dr. H. J. Bigelow.

2994. A second specimen, about the size of the above; and another, from the other ear, three times as large; dense, white, rounded, and arose by a small attachment from the lobes.

From a negress, about thirty years of age. About three years before Dr. H. excised the tumors, she lent her ear-rings that she wore habitually, to a woman "who had a humor." They were worn for two or three hours, returned to the owner in the evening, and at once replaced. In the night she awoke with swelling and intense pain in the ears, and the rings were removed at once. The symptoms, however, continued; and the tumors were soon as large as at the time of their removal. — At the end of five months there was no return of the disease. 1856.

Dr. James F. Harlow.

For reference to authorities on ear-ring tumors, see Amer. Jour. of Med. Sc., Jan., 1861, p. 143.

2995. A life-like, pen-and-ink drawing of a young negro, who came to the hospital as an out-patient to have a tumor removed from the upper edge of the external ear. It was about the size of the last joint of the forefinger, and resembled perfectly a common "ear-ring tumor" externally and internally; showing that such a tumor may form independently of the cause that so generally exists. — A case of Dr. Hodges'. 1869.

Mr. Wm. P. Bolles, med. student.

2996. A cast, to show the external appearances of a large neuromatous tumor, upon the upper back part of the leg.

The patient was a healthy girl, twenty years of age.

Disease of eight years' duration; for the first five about the size of a chestnut, and afterward increased slowly. On admission into the hospital (73, 212) it seemed to arise abruptly just below the ham, and was there about the size of a fetal head; extending downward, and being gradually lost upon the back of the leg. Severe pain in the leg during the last week, and especially about the tumor, which was tender and fluctuating. Foot cool and numb. Dr. Bigelow punctured the fluctuating portion, which discharged a few ounces of bloody serum, and then removed the tumor, which was fibrous. The patient did well, though with diminished muscular power in the foot. 1862.

Museum Fund.

2997. A neuromatous tumor from the spermatic cord; of a regular form, about as large as the top of the thumb, and fibrous in structure. Situated about half way between the testicle and ring. Loose, but not very movable.

From a gentleman, about twenty years of age. Disease of about two years' duration, and without much if any pain. Ether not used in the operation. As soon as the tumor was removed the patient was instantly seized with intense pain in the region of the kidney of the same side. The pain, however, subsided, without any particular pain in the wound itself, and the wound healed well. At the end of two years there had been no return of the disease. The diagnosis was based upon the severe sympathetic pain that followed the operation. 1862.

Dr. H. J. Bigelow.

Neuromatous tumors. (No. 1909.)

Fibrous tumors in the stomach. (Page 452-4.)

Nasal polypi. (Page 413-14.)

2998. A tumor removed from the jaw of a dog, of an oval form, and 3 in. in length. On incision, a number of cavities are seen, lined by a pale, smooth membrane, and from $\frac{1}{4}$ in. to 1 in. in diameter; also large spiculæ of bone projecting into its substance. Intervening tissue firm and fibrous. Microscopically fibrous, with cells. No appearance of cancer. The disease had been removed once before. 1860.

Dr. J. C. Warren.

2999-3000. Casts of a large tumor that was regarded as a fungoid disease of the right upper maxillary bone. Case reported by Dr. W. in his work on Tumors, with three figures (p. 484).—The patient, a little girl twelve years old, entered the hospital many years ago for an operation, and Dr. W. favored it, though in consultation it was decided to leave her to her fate. The second cast shows a great and rapid increase of the disease. 1847.

Dr. J. C. Warren.

A few years afterward, I saw this child, and there was no trace of disease on careful inspection of the mouth. She had passed into the hands of a quack after leaving the hospital, and, by the repeated application of caustics, he had completely eradicated the disease.

3001. Photograph, before operation, of a case of tumor in the parotid region.

The patient was a negress, æt. fifty-nine years, and the disease was of twenty years' duration. No pain at first. The tumor began behind and below the angle of the lower jaw, and extended upward upon the cheek, and downward and forward among the muscles of the neck. After removal (Aug. 6th, 1866) it was about as large as the two fists, somewhat lobulated, quite defined, uniformly dense, not vascular in appearance, and presented under the microscope a mixed fibrous and glandular structure. The side of the face was slightly paralyzed after the operation; but the woman is now (Aug., 1868) in good health, and there is no evidence of any return of the disease. 1866.

Dr. W. G. Wheeler, of Chelsea.

3002. A "fibro-nucleated" tumor from the left pleural cavity.

The patient was a woman, forty-one years of age. In May, 1858, she was delivered of a large, healthy child, and recovered slowly, but was not well from that time. In Oct. she came under the care of Dr. S., with pain on the left side, cough, some dyspnoea, an inability to lie upon the right side, and with physical signs of effusion into the left side of the chest. Gradually got worse, and died on the 15th of January.

On examination by Dr. Ellis, the left side was found greatly distended by the tumor, which weighed, with the

lung, 9 lbs., and measured $13\frac{1}{2}$, $7\frac{1}{2}$, and $4\frac{1}{2}$ in.; the lung being very small, spread out over the tumor, and entirely deprived of air. Externally the mass was deeply lobulated, of a yellowish color, and resembled a fatty tumor. Internally it was moist, of a dull white color, smooth and uniform in some parts, but decidedly fibrous in many others, the fibres diverging as in the fibrous tumors of the womb. Projecting from the surface, and throughout the whole substance of the mass, were numerous thin cysts, from $\frac{1}{4}$ in. to 3 in. in diameter, containing a bloody fluid, with some grumous matter in the largest. They were lined by a smooth, bluish or reddish membrane, and some of them communicated freely. Microscopically, the external portions were composed of elongated corpuscles, quite granular, free, or so closely packed as almost to give a fibrous appearance to the part, but without distinct nucleoli; resembling those figured in Paget's Surg. Pathology, fig. 61. In the deeper seated and more fibrous portions the appearance was decidedly fibrous; but, on the addition of acetic acid, numerous elongated nuclei became visible. In the left lung were two similar masses, and in the right lung one, of the size of peas. There was also some effusion in the different serous cavities. (Med. Journ. Vol. LVIII. p. 182.) 1858. *Dr. D. H. Storer.*

3003. A pencil drawing, by Dr. S., of the above entire tumor. 1858. *Dr. Charles E. Stedman.*

3004-5. Daguerreotypes of a boy, eleven years old, and showing quite a prominent tumor below the lower jaw. The disease was from nine months' to a year's duration, growing rapidly, somewhat painful, but not troubling him much otherwise, except by its bulk. The case occurred in 1851. 1858. *Dr. H. J. Bigelow.*

3006. Lithographs of the above case. 1st. A copy of the daguerreotype. 2d. The tumor, after removal. 3d. The same, colored. 4th. Microscopic appearances. Dr. B. regarded it at the time as a simple cellular structure, and not glandular, but with a question of encephaloid. In the autumn of 1862, however, there had been no return of the disease, and his health was improved. 1858.

Dr. H. J. Bigelow.

Glandular tumors. (Page 379.)

Exostoses. (Page 281-4.)

3007. Cast of the upper part of the body, and showing a very large enchondromatous tumor of the scapula.

The patient, a farmer, twenty-six years of age, entered the hospital Dec. 10th, 1863 (111, 186) under the care of Dr. H. J. Bigelow, and remained there long enough for examination. He was a healthy-looking man, and said that the disease began six years before; that at the end of four years it was of the size of an orange, and during the last two years had grown much more rapidly. Its antero-posterior, transverse, and vertical diameters were 14 in.; and its circumference at the base 45 in. The form was irregularly rounded; and the hardness almost bony, but with numerous little, hard or elastic projections upon the surface. Skin movable over it, except where inflamed. Skin from the axilla, with the hair upon it, displaced by the growth, and was seen upon the outer and upper part of the tumor. The clavicle was lost beneath the mass; and upon the arm were two knots that will be again referred to. The case was published by Dr. B. in the *Med. Jour.* (Vol. LXX. p. 109), with a wood-cut, and in which the patient is represented as standing before a mirror, so that two views of the tumor are shown.

In January the man visited the medical schools at New York and Philadelphia. Hemorrhage came on, and he died in eighteen days after he returned home. Dr. B., having been notified of the patient's death, and that an autopsy could be had, made an arrangement with Dr. Charles M. Carleton, of Norwich, Conn., who had always shown a strong interest in the case, and in whose neighborhood the patient lived; and, with his assistance, the tumor was removed, and brought here for examination.

The weight of the tumor was 31 lbs.; and in structure it was, to a great extent, as pure an enchondroma as would, perhaps, ever be seen. The lobules were well defined; and the interstices were traversed, as usual, by an abundant fibrous tissue. Where it was firm, or rather dense, the lobules were closely compressed; but in other parts, and especially at the lower part of the tumor, they

were considerably softer, and there they hung more loosely together. To some extent there were no formed lobules, but the mass had an amorphous though somewhat granular appearance; and here it was still softer, though it nowhere had the gelatiniform consistence that enchondroma sometimes has. To a small extent the firmer portion of the tumor had a rich reddish tinge; but there was nowhere any extravasation of blood. At some depth from the surface, and where the structure was quite firm, there existed an irregular cavity that would have held $\frac{3}{4}$ or $\frac{5}{8}$; it contained a brownish synovial-like fluid, and the defined parietes were formed by the enchondromatous structure itself. A smaller and similar cavity existed near the above; and in several of the lobules there was a central softening, brownish discoloration and serous infiltration, as if in preparation for a cavity. The amount of cretaceous matter was quite large; and it was generally scattered irregularly throughout the mass as a creamy-white amorphous deposit. In very many of the nodules, however, it appeared, on section, as a narrow, defined line, and in the form of a more or less complete ring; and, on further examination, this ring appeared, in some of them, to be a section of a more or less complete little sphere. After removing typical specimens from different parts of the tumor, the remainder of the mass was macerated to show the cretaceous transformation.

The clavicle (No. 3017) was perfectly healthy, though surrounded by the morbid growth, except at its outer extremity, where there arose from its upper surface a bony tumor, equal to $1\frac{1}{2}$ in. in diameter, or more. This last was of a somewhat reddish color and cancellated structure, and was, in fact, an exostosis, as distinguished from the cretaceous deposit above referred to; it arose from the outer parietes of the bone, which last, though intimately connected with it, was continuous and healthy in appearance, as appeared on section. In this cancellated growth was one small enchondromatous deposit, and its upper extremity was directly continuous with a large mass of the same.

The shoulder-joint was entirely disorganized. The head

of the humerus was in part covered by cartilage; but one half of it or more was denuded, and to a considerable extent it was pretty deeply carious. The deltoid was quite well marked, and there were the remains of some other neighboring muscles; but the head of the bone lay loosely in a broad, shallow cavity, lined by a soft, red, cellular tissue, and in which no traces of the original joint were to be seen. The humerus, having been removed, showed the two "knots" above referred to (No. 3018). One of them is about as large as the top of the little finger, acuminated in form, and shown, on section, to be simply an outgrowth of perfectly healthy cancellated structure; the thin shell of bone that surrounds it, and the parts external to it, being also perfectly healthy. The other is considerably larger, situated rather lower down, and about the middle of the bone, but in other respects similar to the one described, except that, instead of standing directly out from the bone, it was bent down upon it; and, on section, the cancelli seemed to be filled with an opaque, yellowish-white cerate-looking substance; it contained, however, nothing like an enchondromatous structure. The rest of this bone was healthy; the reddish color of the cancellated portion contrasting strongly with the interior of the "knot" last described. The existence of a pure exostosis, apart and by itself, in a case of enchondroma, is certainly an interesting pathological fact in relation to the nature of this last disease.

The right subclavian artery was considerably larger than the left; and, with the nerves, ran along the surface of the tumor, but without being imbedded in it.

The separation of the mass, at the time of its removal from the body, was readily effected, and the parietes of the chest were left in a perfectly healthy condition; a very important fact in reference to an operation, if one had been attempted during life.

The internal organs of the thorax and abdomen were also healthy externally; excepting a slight enlargement of the vertebral extremity of one of the middle ribs upon the right side, and which ought to have been, but was not, examined.

The patient's mother, who is a woman of intelligence, stated that the tumor had been forming ten or twelve years; but grew slowly until the last three years; then its growth became very rapid, and during the last year it about doubled its size. There had been pain in the "cords of the neck" and down the arm occasionally for years; and sometimes it extended below the elbow. But the patient had no pain in the tumor, and it troubled him only by its weight. His general health had been as good the last ten years as it was the ten preceding. After the hemorrhage the ulcers upon the surface of the tumor enlarged, and became deeper and sloughed; so that after death a cavity was found not far from 7 or 8 in. in diameter, and 1 or 2 in. in depth, with much of the calcareous matter exposed upon the inner surface. The pain in the arm increased, but still there was none in the tumor. He was also unable to move his fingers or the forearm, and there was much numbness, though of this last there had been some before. Meanwhile he was confined to his bed, with loss of flesh, strength, and appetite. (See No. 3019.) 1863. *Museum Fund.*

3008-10. Large photographs of the above case; taken by one of the best artists in the city, whilst the patient was in the hospital. A duplicate of one of them is in the Army Med. Museum, at Washington. 1863. *Museum Fund.*

3011. A small photograph of the same; like the one that was published with the case by Dr. Bigelow. 1863.

Museum Fund.

The next seven specimens were from the above case. 1864. *Dr. H. J. Bigelow.*

3012. A section of the tumor; in spirit. Pure enchondroma; with two cavities in the substance.

3013. Another section; much softer.

3014. Another; showing the cretaceous infiltration. And in the same jar, a specimen similar to No. 3012.

3015. A section, to show the cretaceous change; dried.

3016. A coarse, cretaceous mass, larger than the two fists, that remained after the maceration of the tumor. Other por-

tions of considerable size having been detached in the process. The lower extremity of the scapula is quite healthy to the extent of about 2 in., and closely connected with the mass; there being, otherwise, no trace of the bone. A dry preparation.

3017. A section through the clavicle, and the bony tumor that arises from it; dried.

3018. The humerus, after maceration; with sections through the two "knots."

3019. A cast of a well-marked enchondromatous tumor, just above the knee-joint, outside and toward the front. The tumor is about half as large again as the fist, of a rounded form, quite knobbed, dense, and slightly elastic, immovable upon the bone, and occasionally quite painful.

The patient is the mother of the subject of the above case (No. 3007); seventy years of age, and healthy. The tumor has existed from the age of twelve years, and for the last two has been very painful. Stepping upon a rolling stone strains it, and causes it to swell.—Her son, she says, "had one knee like her own, though not so bad." Nothing, however, was known of this at the hospital. She also states that her daughter had a similar disease of the wrist; commencing when she was three years old, and increasing steadily until she died, at the age of fifteen years, of fever; the tumor being hard and irregular, and, at the time of her death, larger than her mother's fist. There was "no length of arm from her elbow down" and for several years she had had no use of her hand. 1867.

Dr. C. M. Carleton, of Norwich, Conn.

3020. Cast of an enchondromatous transformation of the whole thumb.

The patient was a female, eighty-two years of age, and the disease of three years' duration. Cause unknown. An elastic, translucent tumor was first seen over the inside of the last joint of the thumb. This enlarged gradually, until a year before the operation, when it involved the whole thumb, and formed a rounded, elastic tumor, about 4 in. in diameter; integuments inflamed, and pain considerable. At the time of the operation it had nearly doubled

its size, and was still somewhat elastic; being 8 in. by nearly 5 in. in diameter, and in circumference 13 in. Its weight, after removal, was about 21 oz. The integuments were thickened from inflammation; with a foul ulcer nearly 2 in. in diameter, in the situation of the nail; and a slough, midway, $1\frac{1}{2}$ in. in diameter, and an inch deep; the pain being urgent enough to keep the patient awake.

Having been removed with the metacarpal bone, a single longitudinal section was made through the mass, and exposed an almost uniform, translucent, bluish-white tissue, minutely and irregularly divided into lobules, averaging in size a split pea, and each invested by a distinct fibrous tissue. The mass varied, as to density, in different parts; being greatest toward the centre, where there were some cartilaginous-looking lobules, with considerable traces of the cancellar structure of the first phalanx. Toward the extremity, the structure was gelatiniform and more vascular, though still lobulated; the same soft lobules being interspersed throughout the whole tumor. The skin and a thin layer of cellular membrane invested the mass, and could be readily separated from it; all trace of the original structures within having disappeared, excepting an extensor tendon, and the remains of bone above referred to. At the time of the operation, one quite defined lobe was found to extend into the ball of the thumb. Metacarpal bone healthy, though imbedded for one-half its length in the overlying tumor; anteriorly covered by healthy cartilage; and, the synovial membrane being reflected over the corresponding surface of the tumor, a proper articular cavity still remained. Upon the back of the thumb one of the extensor tendons was to some extent deeply imbedded in the tumor, but was afterward inserted by a broad and very thin expansion in a mass that appeared to represent the last phalanx.

Microscopically, the soft parts showed cells from one to two thousandths of an inch in diameter, and containing one or more nuclei, with considerable granular matter. In these parts a structureless or fibrous tissue was found, in which naked nuclei were imbedded, and interspersed with the above cells. The cartilaginous-looking portions showed

a tendency to the formation of irregular, cartilaginous corpuscles; but there were none seen that were well marked.

The patient recovered well from the operation; and some years afterward there had been no return of the disease. (Amer. Jour. of Med. Sc., July, 1853, p. 84.) 1858.

Dr. H. J. Bigelow.

3021. Lithographs of the above case. 1st. A section of the tumor, colored, and of full size. 2d. Four small figures; two of the hand, as shown in the cast; one of the tumor as first noticed; and one to show the flattening of the tendon over the tumor. 1858. *Dr. H. J. Bigelow.*

3022. An enchondromatous tumor, connected with the first phalanx of the index finger, and about $1\frac{3}{4}$ in. in diameter.

From a girl, æt. fifteen years, who first noticed the growth eight years before, as a small, hard tumor, not adherent to the integument nor to the bone, and not interfering with the movements of the finger. It had increased gradually, without pain; and, when seen, was of a very slightly oval form, somewhat lobulated, and, to the feel, firm and elastic. The whole finger was shortened $\frac{1}{4}$ in., and adducted. Amputated; and healed by the first intention.

A section having been made through the phalanges and the tumor, this last is seen to be a pure enchondroma; and the first phalanx, though considerably absorbed, is healthy in structure. 1867. *Dr. H. G. Clark.*

3023. Cast of a hand, showing a defined enchondromatous tumor upon the back of the first phalanx of the index finger, of a regular ovoid form, and about $1\frac{1}{2}$ in. in length.

The subject was a healthy young man, and the disease of ten years' duration. Removed with the bone-forceps, and returned in two or three years. 1868.

Dr. H. J. Bigelow.

3024. An enchondromatous tumor, removed from one of the ribs. It is considerably larger than the fist, of a somewhat ovoid form, and the appearances, on section, are

highly characteristic. Some appearance of coarse granules, but no cretaceous change.

The patient was a healthy Canadian, thirty years of age; and the disease was of six years' duration. No assignable cause. Tumor very hard at first, but had become less so, though nowhere soft; not discolored, painful, nor tender. The seventh, eighth, ninth, and tenth ribs on the left side, and near the cartilages, were covered by it. Form, circular; measurement across the summit, 7 in., and projection from 1 to 2 in. Growing rapidly; and had been already once removed, with a portion of the cartilage of the rib. Removed with a portion of the ninth rib, to which it was attached; and on the eighteenth day the wound had nearly healed. Case published by Dr. W. in his work on Tumors (p. 152). 1847. *Dr. J. C. Warren.*

3025. Enchondromatous tumor from the palate.

From a man, æt. thirty. (Hospital, 73, 215.) Tumor for five years just in front of the fauces, and toward the right side; never painful. Growth slow until the last three months, and then rapid. It was larger than an English walnut, very hard, slightly movable, and not tender.—Removed by Dr. S. D. Townsend, and found attached only by cellular tissue. After removal, it appeared perfectly defined, of an ovoid form, crisp, and generally very hard, but in one spot very soft. Microscopic appearances of enchondroma strongly marked. In the preparation the tumor has been cut through, and to a considerable extent shows well the characteristic appearances of the disease; the intervening portion having a dense, opaque, fibro-cellular look.—The patient did well. 1859.

Dr. C. Ellis.

3026. An enchondromatous tumor from the parotid region.

The patient was a female, thirty-six years of age, and the disease was of nine years' duration. Tumor of the size of a pea at first, and scarcely grew the first five years, but toward the last the growth was quite rapid. Below the ear, form nearly hemispherical, and slightly lobed; diameter, $2\frac{1}{2}$ in.; everywhere hard and elastic, and firmly adherent, except to the skin. Removed at the

hospital (107, 80), and the patient left on the eleventh day.

The tumor, which has been cut open, is of a rounded form, and has a thin, fibro-cellular investment. In the recent state, a large part looked not unlike boiled tapioca, in which were some moderately firm lumps, and with which there was mixed a great amount of a viscid, transparent fluid; the soft portion being surrounded by a cartilaginous cortex, about $\frac{1}{2}$ in. thick. 1863. *Dr. H. J. Bigelow.*

3027. Daguerreotype of a woman, fifty-two years of age, who had a tumor just below the ear, that had existed for seven years, and had grown slowly until the last two. It was about 2 by 1 in. in extent, quite hard and lobulated to the feel, and never painful. The structure, after removal, was partly firm and cartilaginous in appearance, and partly gelatiniform; generally of a bluish color, translucent, and wanting both in gland structure, and in that of cartilage. Some inflammation followed the operation; but the patient was soon discharged well. (Hospital, 61, 12.) 1866.

Dr. H. J. Bigelow.

3028. An enchondromatous tumor, about the size of an English walnut, removed from the tip of the nose.

The patient was a female, twenty-four years of age. Tumor of four years' duration, and troubled her only by its appearance and bulk. Described by Dr. B. as a mixed cartilaginous tumor; a fibrous stroma, imbedding a few large cells like those of cartilage, as figured by Mr. Paget in his Surgical Pathology. Patient discharged well on the ninth day. (Hospital, 117, 226.) 1864.

Dr. H. J. Bigelow.

Enchondroma in the substance of the bone. (See No. 1488.)

3029. A very large tumor, that originated in or about the right submaxillary gland.

The patient was thirty-eight years of age, and entered the hospital Dec. 18th, 1861 (99, 174). The tumor appeared over the gland nineteen years before, was painless, and grew slowly, but had doubled in size the last year. On admission, it was as large as a child's head; extending from the malar bone to $4\frac{1}{2}$ in. below the mastoid process,

and from this process forward to the larynx. It was knobbed, and mostly hard, but some parts were soft and fluctuating. Skin tense but unbroken. Larynx pushed to one side, but moved independently of the mass.

On the 21st the entire tumor was removed; and, though the mucous membrane of the mouth was pushed before it, and the pharynx and œsophagus were to a large extent in close contact with it, no opening was made into these cavities. There was much venous hemorrhage, and consequent depression; but no large vessel was cut. The ramus of the lower jaw was bent inward by the growth of the mass, and it was necessary to divide it at the angle. It was also necessary, for the command of the tongue, to use the forceps and a double ligature.

On examination of the tumor, Dr. B. found it sufficiently hard and smooth, as if invested by a fibrous capsule; with very marked lobes and fissures, and in the deepest of which had lain the ramus of the jaw. On section, it appeared to be a well-marked specimen of the mixed cartilaginous tumor of Paget; surface flat, with small, honeycomb chambers, and anfractuons and discolored cavities, traversed by bands, and filled with bloody serum. Portions of the mass were dense, opaque, white, and finely mixed with a bluish, enchondromatous tissue. Other portions were more uniformly cream-colored, and softer, without the enchondroma. The enchondromatous portions showed unequivocal cartilage cavities, somewhat imperfect in their structure, and marked with tough and branching fibre. The cream-colored tissue was more distinctly cellular and granular. The cells were extremely irregular; mostly caudate and fusiform, or with processes; but they showed none of the rounded cells of some cancerous growths, to which last the tumor bore no resemblance.

In regard to the nature of the tumor, Dr. B. thought that until the last few years it might have been regarded as benign; but that its late rapid growth would suggest the idea of its return.

On the 13th of Feb. the wound was healing fast, and the man left the hospital; the hearing in his right ear, which had been lost for many years, having been restored.

In September, 1863, the disease returned; and in February, 1864, when he re-entered the hospital, there was one tumor, of the size of an egg, and another smaller one. On the 27th these were removed, and were found to extend to the mucous membrane of the fauces. Sloughing and hemorrhage followed, and on the 7th of March he died. On dissection, the organs were found healthy. The tumor was found by Dr. Ellis to consist, microscopically, of closely aggregated cells; irregular, as if shrivelled, and without distinct nuclei or other marked characteristics. 1864. *Dr. H. J. Bigelow.*

3030. Cast of the above tumor. 1864.

Dr. H. J. Bigelow.

3031. Daguerreotype of a large, mixed, cartilaginous tumor, upon the side of the neck, and of eight or ten years' duration. It was very easily removed; and the patient, a girl, twenty years of age, went home in ten days. At the end of two years the disease had not returned. 1858.

Dr. H. J. Bigelow.

3032. Daguerreotype of the above patient, after recovery. 1858.

Dr. H. J. Bigelow.

3033. A myeloid tumor, removed by Dr. T. It was situated in front of the ankle-joint, and appeared like an enlarged bursa, though painful; firm, rounded, elastic, and about 2 in. in diameter.—The patient was a woman, fifty-five years of age, and had had the disease for several years. (Hospital, 78, 197.)

The tumor was of a dark-reddish color, slightly vascular, rather soft, and bound down by fibrous bands. On section, it seemed to consist of three or four lobules; structure compact; surface smooth; generally of a dull, light brownish-red color, but with numerous small spots of a bright orange-red. Upon the external surface this last color was more extensive. Microscopical examination by Dr. Ellis. 1859. *Dr. S. D. Townsend.*

Myeloid disease of tibia. (See No. 1485.)

3034. Cast of the side of the face, and showing a tumor in front of the ear.

The patient, a female, æt. thirty years, entered the hospital June 26th, 1852 (53, 100). Disease of fourteen years' duration. Removed in three years, as a fibrous tumor, and it was then of the size of a pigeon's egg. Three years afterward it returned. Removed again in April, 1851; size of a hen's egg. In October two tumors appeared, but afterward united. On admission, it had a regularly rounded form, measured $4\frac{1}{2}$ by 3 in., and dipped down behind the ramus of the jaw. Had grown more than one-half since April. Surface smooth, but lobulated and dense, though not elastic to the feel; quite movable; neither painful nor tender, but with an occasional tingling, and for a long time after the last operation, numbness, though no loss of muscular power.

Tumor removed by Dr. H. G. Clark, June 30th, and found to be fibro-plastic. Operation followed by some paralysis of face. In the autumn the disease again returned, and in May, 1853, Dr. C. removed a mass about the size of a filbert; composed, according to Dr. Bacon, "partly of fibrous tissue, and partly of fibro-plastic elements in various stages of growth. No cancer cells found."

Cast taken in June, 1852, by Mr. Albert F. Sawyer, one of the house-pupils. 1852. *Dr. H. G. Clark.*

3035. Photograph of a man, thirty-nine years of age, whose orbit was filled by a hard tumor; the eyelids being adherent, and protruding nearly an inch.

Twenty-three years before, a tumor formed in the orbit, and in about two and one-half years it was removed with the eye. In seven years the disease returned, but for eight or ten years had been stationary. Removed by Dr. Bigelow; but a portion of the tumor was left, as it grew from the posterior part of the orbit, and it was thought unsafe to go any further. Some serious symptoms followed; but the man finally did well, and left the hospital (138, 222) in about four months. 1869.

Mr. B. S. Kent, Jr., one of the house-pupils.

3036. A tumor between the flexor tendon of the middle finger and the bone.

The patient was a boy, nine years of age, and had had the disease for seven years. The tumor centred about the second joint, and was quite prominent; form oval, with flattened sides. The whole joint was enlarged; and for about two years there had been inflammation, with a fluid discharge, but without pain. One surgeon had diagnosed tubercular disease of the bone. Amputated at the first joint; and, in the preparation, a long incision has been made through the bone and tumor. This last looked like a fibro-cellular tissue, with some mixture of fat; but, microscopically, was found to be "fibro-plastic." 1856.

Dr. G. H. Gay.

3037. Three colored lithographic views of a specimen of epulis, removed from the lower jaw; as seen from above, from the outside, and on section. Also uncolored microscopic views; showing the typical appearance of fibro-plastic tissue, as does the maroon color in the other views. 1858.

Dr. H. J. Bigelow.

3038. Erectile tumor of the orbit.

From a man, æt. fifty-eight years, who, in 1840-1, froze the right side of his face severely. Uneasiness and dryness in the right eye followed, and continued until April, when he had iritis. In six weeks this was relieved, but with slight eversion of the eyeball. In 1847 a small tumor appeared below the eye, but varying in size at different times. In 1850 he was treated for an inflammation of the eye, but without any effect upon the tumor; and the same in 1854. In 1860 the tumor protruded the ball, and everted the lower lid; and, being punctured, gave issue only to blood. For the next three years it steadily increased. July 9th, 1864, he entered the hospital (114, 24), and the exophthalmia was then hideous; the tumor being apparently somewhat larger than a hen's egg, and protruding the eye forward, with slight eversion. Upper lid very much distended. Conjunctiva thickened, ulcerated, and suppurating over the everted lid. Traces of the iritis remained, and the sight was impaired in consequence. The tumor was elastic, somewhat movable, rounded, and without lobules; not pulsating, and feeling, as the man said, perfectly "dead." General health robust.

July 10th the tumor was enucleated without difficulty, and without hemorrhage; the eyeball falling back, and requiring a stitch to keep it in proper relation to the lids. It was as large as an egg, smooth and ovoidal in shape, and on section consisted of a cavernous structure, filled with blood, easily evacuated by pressure and washing, by which processes it was reduced in size one-half, and was then seen to consist exclusively of cells, analogous to those of the corpus cavernosum penis, and capable of inflation with a blow-pipe, so as to resemble the section of an emphysematous lung. Under the microscope there were no signs of any vessels, or of any other structure than a cavernous one. The tumor was enclosed in a tough capsule, into which no vessel could be seen entering.

Aug. 8th the overstretched lids had contracted, and the motion of the eye was almost equal to that of the other. Sight better than for seven or eight years past. On the 12th he left the hospital; and a month later the lids had shrunk to their natural proportions, and there was no longer any appreciable deformity.

Dr. H. remarked upon the perfectly encysted character of the tumor, and the absence of any vascular connection, of appreciable size, with the surrounding parts, though its active vascular character still remained. Von Carrion, he said, had described this disease (*Lehrbuch der praktischen Augenheilkunde*, Vienna, 1861, p. 506); and Dr. H. referred to a tumor, in many respects similar to his own, that was removed by Mr. Liston from the popliteal space. (Med. Chir. Trans. Vol. xxvi. p. 120. See Med. Jour. Vol. lxxi. p. 417.)

Dr. R. M. Hodges.

3039. A firm, fleshy, pediculated, and very markedly lobulated mass, nearly as large as the last joint of the little finger; and removed, with the *écraseur*, from near the tonsil of a boy about eleven years of age. Disease of some months' duration. Deglutition and voice not affected. Surrounding parts quite healthy. Microscopically, Dr. B. found it epithelial; and, as a whole, something that he had not before seen. 1860.

Dr. H. J. Bigelow.

3040. Photograph of a case of large cancerous tumor in the neck.

The patient was a man, thirty-one years of age, and the disease had been forming between two and three years; not directly painful, but much pain in the back and side. The tumor extended from the clavicle to the angle of the jaw, anteriorly to the median line, and posteriorly to within $2\frac{1}{2}$ in. of the spine. It had a very lobulated feel; elastic in part, but over the lower half hard, knobbed and slightly reddened. Upon the other side of the neck was another small tumor.

The diseased mass was removed by Dr. C.; a small portion of it being left behind. The carotid art., which passed through it, was tied and divided. On the eighth day the patient fell off, and in three days more he died. (Hospital, 111, 32.) 1865. *Dr. H. G. Clark.*

3041. Cast of the knee, showing externally an encephaloid tumor in the popliteal region, and of the size of a large orange.

The patient was fifty-five years of age, and the disease of four or five years' duration. The tumor, when first noticed, was of the size of an acorn; and there had been no increase nor trouble from it until the last four months, from which time it had grown rapidly. It was hard and fixed, and the skin of a reddish color, at the prominent part; with dull pain, and slight affection of the motion of joint. Amputation by Dr. W. On the ninth day the man began to sink, and in about four weeks more he died with pyemia and pneumonia. (Hospital, 120, 218.) Cast by Messrs. J. Collins Warren, and A. S. Nichols, house-pupils. 1866. *Dr. J. M. Warren.*

3042. Cast, of the trunk and head of a little girl, taken after death, and showing an immense encephaloid tumor. It arises from the right shoulder, and side of the neck, as high as the ear, extending nearly to the spinal column, down upon the scapula, as low as the axilla, and in front to about the second rib. Its vertical diameter is about 13 in., and the transverse $9\frac{1}{2}$ in.; the summit rising to about the level of the head, which is pushed to one side by the great mass. Sent to the Museum by Dr. H., at the request of Dr. J. M. Warren, and with the following account of the case.

The patient was fourteen years old, and entered the New York Hospital Nov. 17th, 1847. The tumor had been first noticed four months before, over the clavicle, and was then of the size of a pigeon's egg. Growth very rapid for some time past, but without pain, until it was of considerable size. It went on increasing, with dyspnœa and dysphagia, and such severe and lancinating pain as to require a free use of opiates. The surface at last opened and discharged a reddish fluid; and the child died, greatly emaciated, on the 29th of June; the whole duration of the disease being only about eleven months.

On dissection, Dr. H. found the humerus detached from the scapula; and the clavicle, with the three upper ribs softened, but not infiltrated with the disease. Weight of the tumor, with the arm, 33 lbs. The right lung showed traces of the disease; and in the upper lobe were miliary tubercles. Otherwise the organs were healthy.

Upon the front of the right arm was a very curious congenital affection, — as shown in the cast, — a flabby and pendulous condition of the skin and integument, extending from the elbow nearly to the acromion process, involving nearly one-half of the circumference of the arm, and growing with the child's growth, but causing no inconvenience. This may have been a form of disease described by Dr. Mott, as pachydermatocele. (Med. Chir. Trans. Vol. xxxvii. p. 155 — with two figures.) 1848.

Dr. Alexander E. Hossack, of New York.

3043-4. Daguerreotypes of a young man, showing a large encephaloid tumor upon the right side of the neck, and encroaching upon the other side. The wound after its removal healed well. 1858. *Dr. H. J. Bigelow.*

3045. A portion of the delicate, bony framework of an immense malignant growth from the back of the pelvis. 1856.

Dr. H. J. Bigelow.

3046. A foot, preserved entire, and showing a tumor arising from below the inner ankle, and toward the heel. The morbid growth, which has not been cut open, is larger than a foetal head, soft to the feel, and lobulated. Integu-

ment not continued over it, though there is no defined ulceration. The foot looks otherwise healthy. 1847.

Dr. J. C. Warren.

3047. A portion of the ulnar nerve, from just above the elbow, and attached to it a small cancerous growth.

The patient was a man, forty-seven years of age, who had had a tumor there for twenty-four years; and, two years before his entrance into the hospital (77, 189), a mass, weighing 2 lbs., had been removed. The disease having returned, Dr. B. amputated the arm at the shoulder-joint. The ulnar nerve entered the upper part of a large cancerous tumor, and just before it was lost in it bulged out to the size of a sparrow's egg. This last was felt very distinctly before the operation; and also a firm cord, running down into the tumor from the axilla, and which was very painful on pressure. The man recovered well from the operation, but died four months afterward. (See Nos. 1530 and 2037.) 1858.

Dr. H. J. Bigelow.

3048. Thibert's model. A very large, cancerous tumor, just above the wrist, and arising from the bones of the forearm. 1847.

Dr. J. C. Warren.

3049. — —. Disease in the above case, greatly advanced; and a large, deep cavity has formed. 1847.

Dr. J. C. Warren.

3050. — —. A tumor connected with the hand, and quite as large as the foetal head. A cancerous disease, apparently of or about the carpus and metacarpus. The skin is stretched over it, with dilated blood-vessels, and the surface is quite knobbed. The fingers, coming out from the mass, are considerably spread by the growth of the disease, but are healthy so far as seen.

Dr. G. Hayward.

3051. — —. Section of the above tumor, showing an opaque, white, anfractuons, malignant-looking structure; with no appearance of natural tissues, excepting the tendons at the wrist-joint.

Dr. G. Hayward.

3052. Section of a portion of a melanotic tumor, that was removed by Dr. G. H. Dadd, veterinary surgeon, from a gray stallion, nine years old. The disease was of eighteen

months' duration, and in the subcutaneous cellular tissue below the shoulder. There were two tumors, of which one weighed 4 lbs., and the other 1 lb. In four weeks the animal was at his work again. 1854.

Dr. H. J. Bigelow.

Melanotic tumors in the eye. (See page 411.)

Malignant diseases and tumors of bones. (See page 288.)

3053. A malignant-looking mass, upon the upper and back part of the forearm; nearly as large as the fist, and blackish upon the surface, as from hemorrhage. 1847.

Dr. J. C. Warren.

3054. A circular, flattened, very defined, fleshy-looking mass, about half as large as the fist; the edges projecting somewhat beyond the base, with which a small portion of integument was removed. Surface generally quite smooth, but somewhat lobulated about the edges, and nowhere covered by proper cutis. Integument immediately beneath the tumor quite healthy; the origin of the mass being apparently quite superficial. 1847.

Dr. J. C. Warren.

3055. A perfectly superficial and fleshy growth from the side of the neck, that is figured by Dr. W. in his work on Tumors, and described by him as "eiloides." It suggests the idea of a protrusion of three or four coils of inflated intestine; the coils being larger than the finger, and the whole diseased surface about 4 in. in diameter.

From a negress, æt. fifteen years, who was not quite healthy. The wound healed well, but in eighteen months the disease reappeared. Dr. W. refused to operate again, and the operation was done by another surgeon. The disease soon returned again, and the patient died.— On dissection, large tumors were found in the abdomen, with disease of the liver, and dropsy.— Dr. W. speaks of this as the only case of this very rare form of disease that he had seen. 1851.

Dr. J. C. Warren.

A very similar specimen to the above was in the Museum of the College of Physicians, in New York, in 1851. It was from the neck of a negress, and was 5 or 6 in. in

diameter; with a second mass, subsequently removed from the same patient.

3056-8. Daguerreotypes of a case of disease of the antrum.

The patient was a farmer, æt. sixty-three years, who had had pain in the jaw for six months. (Hospital, 61, 180.) Three or four teeth were extracted without relief, and swelling followed. The antrum was opened from below, and about $\frac{3}{4}$ ss. of a material like boiled sago was removed; the grains, however, being smaller, and hanging in bunches; microscopically glandular. The cavity was syringed with water; and on the third day the man left the hospital. The swelling, however, still further increased, and he died nearly a year after the operation. — The daguerreotypes were taken some months after he left the hospital.

The disease, Dr. B. remarked, was malignant clinically, though not microscopically. 1858.

Dr. H. J. Bigelow.

3059. A portion of the branch of a black oak, upon which is a rounded, warty growth as large as a man's head; with transverse and long sections. — Having been examined by Mr. Chas. J. Sprague, who is a most accomplished botanist, he remarks that there seems to have been a closure of certain vessels, and an incipient decay of the central tissue, inducing an irregular deposit of woody tissue. The direction of the growth is turned from the ordinary axis, and the divergence then constantly increases; sometimes enclosing a piece of old bark. The change is not due to insects. 1861.

John Feenan, ward-tender at the hospital.

SERIES XXXIX. — PARASITES.

3060. A very fine specimen of tænia, without hooklets; described minutely, and figured, with the head, by Dr. Wienland, in his monograph on the "Tape-worms of Man." Notwithstanding, however, the want of hooklets, Dr. W.

regarded this specimen, though "not without hesitation," as a *T. solium*.

From a man, forty-one years of age, who sometimes ate pork three times in the week, and occasionally ate it raw. Health good till 1854, when he had vertigo, sinking at the stomach, and a strong craving for food. Symptoms continued, and in Aug., 1856, he passed about six feet of the worm. After strict abstinence for a week, he took a cathartic, and passed 17 ft. 9 in. more. In December there was a recurrence of the symptoms; and after kousso, followed by a cathartic, he passed 20 ft. more; one extremity being very slender, but without the head. There was thirst, irregular appetite, pain in the stomach, and general debility. In Jan., 1857, he passed two small pieces at different times. In March the symptoms were quite pressing; and, after a dose of kousso, he passed 21 ft. of the worm, with the head here shown. Altogether the fragments amounted to 71 ft. 3 in. In the course of three months his health was restored, and in 1858 it continued good. 1858. *Mr. T. H. Pinkerton, med. student.*

3061. A second specimen, and regarded by Dr. J. C. White, as *T. mediocanellata*; head very distinct.

The patient was a healthy little girl, nine years old, who passed about 9 ft. of the worm, March 3d, 1863, after the tinct. of rhubarb; having had an inordinately strong appetite for the previous six months, and especially for meat. On the 23d of the same month, after a full dose of pumpkin seeds, followed by active cathartics, she again passed 9 ft., and afterward another portion, with the head. 1867.

Dr. Stephen Salisbury, of Brookline.

3062. A third specimen. — The patient was nineteen years of age, and had passed a *tænia* a year before. When Dr. L. saw him, he had had for two weeks general malaise, constant headache, aberration of mind, anorexia, constipation, and slight fever. Under the use of active cathartics, and a blister to the back of the neck, he was much relieved, and thought himself nearly well; but at the end of two weeks joints of the worm were passed. Half an ounce of kousso was then given, after he had fasted for twelve

hours; in three hours he had a second dose, and 8 ft. of the worm were afterward passed, with the head; but this last was unfortunately lost.

Dr. L. remarked that Dr. Weinland had recorded cerebral or cerebro-spinal symptoms in sixty-eight out of one hundred cases of tænia; but he questioned whether the headache, etc., were due to the worm, in consideration of the great relief before this last was expelled. (*Med. Jour.* Vol. LXXV. p. 426.) 1867. *Dr. G. H. Lyman.*

3063. A fourth specimen; remarkable for the shortness of the joints. From a gentleman, who had often passed fragments of the worm, and whose health was much affected. Discharged after the use of powerful cathartics for several days; turpentine having been previously tried without effect. 1848. *Dr. G. Hayward.*

3064. A fifth specimen; about 22 ft. in length.—From a mechanic, who had been out of health for a long time, but had never passed any fragments of the worm, so far as he was aware. Dr. G., who is a medical electrician, gave him a charge (100 cups — Daniel's battery), and the worm was expelled before the man left the house. His health was restored; and no more was passed. 1863.

Dr. A. C. Garratt.

3065. A sixth specimen; the head, with a small portion only of the worm being shown. Examined by Dr. J. Wyman, and found to be a *T. medicanellata*.

From a painter, æt. twenty years, who had served for three years in the War of the Rebellion, and often, from choice, ate his beef half cooked. For the last few months he had lost his appetite, was costive, felt generally sick, with diminished flesh and strength; no pain. Small pieces of the worm had passed the last month. Dr. P. gave a dose of salts, then milk diet for twenty-four hours, and then 1 oz. of kousso in ℥xiv. of water. This last was taken in three doses, and at intervals of fifteen minutes; and in eight hours the worm (about 12 ft. in length) came away.—Dr. P. insisted strongly upon the preparatory treatment. 1868. *Dr. Luther Parks, Jr.*

3066. A seventh specimen.—From a man, thirty-eight years

of age, and of intemperate habits. In April he had pneumonia, and passed about $4\frac{1}{2}$ ft. of the worm. Joints passed occasionally during the summer; and, about the last of November, on account of an oppression at the epigastrium, he took medicine, and passed a considerable piece. A few days afterward Dr. I. was called, and found him with ascites. Castor-oil and turpentine were given, and 7 ft. of the worm were expelled. General dropsy supervened, and he died very shortly afterward. — On dissection, a granulated liver was found; and, about the middle of the small intestine, 3 in. of the tænia, lying free, though buried in mucus. Dr. Gould examined this last, and found the club-shaped head, the four oval orifices, and in the centre a minute pit, but no marked orifice, and certainly no trace of a coronet of hooklets. His drawing, which is shown with the specimen, proves it to be a *T. mediocanellata*. 1852.

Dr. H. B. Inches.

3067. A small portion of the worm from the last case, showing almost a complete separation of the joints, one from another; and many of them being separated. 1852.

Dr. H. B. Inches.

3068. A portion of a tænia; dried upon glass, to show the arborescent form of the genital apparatus. 1848.

Dr. Waldo J. Burnett.

3069. Botryocephalus; 9 ft. in length. — The patient was eighteen years of age, from Finland, and had always lived there until the last year. Portions of the worm occasionally passed for three years. Appetite voracious; pain at epigastrium; and some loss of flesh. After koussou, followed by turpentine, portions of the worm were passed, that amounted altogether to $22\frac{1}{2}$ ft. 1856.

Dr. Z. B. Adams.

3070. A second specimen. — From a young gentleman, æt. seventeen, who had been in Europe for three years, and for the last few months in Switzerland. Some months after his return he passed a few joints of the worm; and, after a cathartic, about 10 ft. In the course of the following year other portions were discharged; and, after a dose of the male fern, and an active cathartic, $8\frac{1}{2}$ ft. more were

discharged. Both specimens are preserved, and a head is said to have come away with each, though it cannot now be shown. Several years have now elapsed, and there has been no further trouble. 1867.

Dr. H. J. Bigelow.

3071. *Cysticercus cellulosæ*. — Two specimens, with a small portion of muscle, in which the cyst is seen, from which one of them was removed. — From a middle-aged negro, and chiefly in the muscles of the legs; also in the dura mater. 1854.

Dr. J. Wyman.

3072. A second specimen. — From a rather young adult, male, dissecting-room subject, and in whom no organic disease was found. Great numbers of the parasites were found throughout the muscles of the limbs and trunk, some in the integument, and many were seen as well as felt just beneath the skin. In size, they varied from a grain of rice to a coffee-bean. Several specimens are shown; and two in connection with the skin. 1856.

Dr. R. M. Hodges.

3073. Acephalocysts from the liver of a hog. (No. 2388.) 1854.

Dr. H. J. Bigelow.

3074. Hydatids from the liver; from the size of a pea to that of a horse-chestnut.

The patient was a lady, thirty-five years of age, who had had for several years pain and uneasiness in the right hypochondrium. In the spring of 1856 an obscure tumor was discovered there; "feeling like a watch," and deeply seated beneath the integuments. In April, 1857, a large tumor was rapidly developed in the same spot; excessively painful and tender, and compressing the lung so that the resp. murmur could only be heard at the upper part. One night she had several discharges from the bowels, of a clear, colorless, and exceedingly fetid fluid. The tumor disappeared almost wholly, and at once; and there was extreme prostration, with much fever, from which she slowly recovered. About the 1st of June she began to cough, and expectorate frothy mucus; and about the first of September she began to cough up the hydatids; two or three being discharged

at a time, and about twice a week, with a sensation as if they came from the lower part of the right lung. In Oct., 1857, the tumor could no longer be felt. The health steadily improved; and in Sept., 1859, when the case was reported, she was quite well, and had not coughed up any of the hydatids for three months. 1859.

Dr. F. Minot.

3075. Echinococci from the thigh.

The patient was a woman, thirty-five years of age; and upon the front and middle of the thigh was an oval, and very defined tumor, 7 or 8 in. in length, painful, solid to the feel, and prominent above the surface, which was smooth, tense, and shining. Removed by Dr. Jordan, of S. Reading, who found that it dipped down between the bellies of the rectus muscle, and was firmly adherent, so that a portion was left behind; the surrounding tissues being healthy. There was a large, white, enveloping cyst, containing one to one and a half pints of serum; and, by estimate, about sixty of the hydatid cysts, which were free in the cavity, varied from about $\frac{1}{3}$ in. to 1 in. in diameter, and presented the usual appearance of cysts containing echinococci. Microscopically, the characteristic, striated appearance of the cysts was found; and upon the inner surface the parasites themselves. — The specimen, which consists of two of the hydatid cysts, and a portion of the envelope, were sent by Mr. J. Dole, a student of Dr. J. 1868.

Dr. C. Ellis.

Echinococci in the liver. (No. 2387.)

Echinococci in the lung. (No. 2156.)

3076. *Ascaris lumbricoides*; vomited by an old woman at the hospital. 1854.

3077. The same; tied in a knot. It protruded from the anus, and was removed; partially decomposed. 1863.

Dr. J. Homans.

3078. An ascaris from the small intestine of a horse. The animal was about seven years old, had severe nervous symptoms for about twenty-four hours, and was then killed by his owner. — Dr. D. found 2 qts. or more of the worms in the intestine; a considerable portion of them being

coiled up in a close knot, and all within a short distance of each other. 1854.

Dr. D. H. Dadd, Veterinary Surgeon.

3079. Four ascarides, from the peritoneal cavity of a horse; filiform, and about 4 in. in length. Peritoneum healthy. 1854.

Dr. H. I. Bowditch.

3080. *Tricocephalus dispar.*; several individuals, of about forty, that were removed from the cæcum of a patient, who died of cholera. 1849.

Dr. John C. Dalton.

3081. A portion of muscle, containing great numbers of *trichinæ spiralis*. The case occurred in this city in 1842, and several others about the same time. 1857.

Dr. J. B. S. Jackson.

3082. *Eustrongylus gigas*; two specimens from the kidney of a mink, in which it seems, in this vicinity, to be very generally found. 1862.

Mr. Ezra Pray, med. student.

3083. *Filaria medinensis*, about 20 in. in length.

From a sailor, who had been upon the coast of Africa. It came out from the anterior, middle portion of the leg, and was twelve days in being removed; kept wet with glycerine as it was being wound up, so that it did not become dry. Having been put into about $\frac{3}{4}$ ij. of water after its removal, young filariæ were discharged in immense numbers, and for some days were very active. A short time previously another worm had been discharged from the other leg. 1867.

Dr. J. W. Graves.

Filariæ in the air-tubes of a young pig. (No. 2108.)

Filariæ in the air-tubes of a porpoise. (No. 2109.)

3084. Two parasites from the lung of a python *bivittatus*. —
Dr. J. C. White's report: —

"They belong to the order *Cephalocotylea*, and to the genus *Pentastomum*; and are very like, if not identical with the *Linguatula armillata* described by Dr. J. Wyman (No. 907 in the Med. Soc.'s Museum — see catalogue, with figure). The larger is a female, and the other probably a male. The proper specific name does not appear in *Diesing*, unless it be his *P. proboscideum*."

The lung of another python, that was dissected about the same time, contained a similar parasite. 1861.

Dr. J. M. Warren.

3085. Ticks (*Ixodes*) from a dog; several individuals, in their natural, and in their distended state. 1867.

Dr. J. B. S. Jackson.

3086. A tick from the human subject; dried. 1865.

3087. *Æstrus ovis*; four individuals, from the nostrils of a sheep. 1867.

Dr. J. B. S. Jackson.

3088. *Æstrus equi*, from the stomach of a horse. (No. 2180.) 1868.

Dr. J. P. Stickney.

3089. Two parasites (*Lernæa branchialis*, L.) from the gills of a cod. 1869.

Dr. J. B. S. Jackson.

3090. Chigoes from the foot of a negro, in the hospital at Barbadoes. 1867.

Dr. J. B. S. Jackson.

3091. Larva of a sphinx. The ichneumon fly had laid its eggs beneath the surface: these had hatched; the young larvæ had lived upon the fat of the larva of the sphinx, avoiding the vital parts; and, finally, they have come out and spun their cocoons upon the surface of the larva; the health of this last, so far as appears, being sufficiently good. Several of the cocoons have been detached since the specimen was preserved. 1857.

Dr. J. B. S. Jackson.

Achorion Schoenleineii upon the head of a mouse. (No. 1987.)

3092. A long vegetable fungus, growing from the head of a caterpillar. One of the hospital attendants, who brought several specimens from China, stated that the caterpillars are carried from Bombay, and dried, in packages, and that they are used by the Chinese for diarrhœa and dysentery. Mr. Chas. J. Sprague, the botanist, says that this kind of fungus is found in several species of caterpillar, and in some in this vicinity. 1861.

Dr. Wm. B. Gibson.

SERIES XL. — MISCELLANEOUS SPECIMENS.

3093. Cast of an enlarged spleen; colored; the result of portal obstruction in case of cirrhosis. The organ weighed $2\frac{1}{2}$ lbs., and measured $9\frac{1}{2}$ in. by $6\frac{1}{2}$ in. — From a man, æt. twenty-one. (Hospital, 259-96.)

This enlargement is sometimes a valuable diagnostic aid in questionable disease of the liver. 1864.

Museum Fund.

3094. A second and similar cast; from a case of leucocythemia. — The patient was a widow, forty-two years of age, and the enlargement had been known to exist for about two years. The tumor could be seen as well as felt between the cartilages of the ribs and the umbilicus. Through the vagina, also, it could be felt, soft, and as if containing fluid. The woman was very pale, with loss of flesh and strength, a rapid pulse, variable appetite, constipation, dyspnœa, and during the last year, amenorrhœa. There was epistaxis for the last six months, increasing in frequency, and often severe; and diarrhœa during the last week. The nature of the case was misunderstood; and the patient was to have been operated upon, as for ovarian dropsy, if she had not sunk under the constitutional effects of her disease. — The organ weighed 4 lbs. 14 oz., and measured $12\frac{1}{2}$ in. by $5\frac{1}{2}$ in. Dr. H. J. Bigelow examined the blood from the splenic vein, and found the number of white corpuscles in it immense. The condition of the lymphatic glands was not observed. 1868.

Museum Fund.

3095. Cast, by Dr. L., of an enlarged spleen, that, in the recent state, was 12 in. long, 7 in. wide, 3 in. thick, and as compact as the liver. (Hospital, 151, 2.)

From a man, thirty-three years of age, who had been sick about ten months, and had never had intermittent fever. The tumor filled the whole left side of the abdomen, and was first felt about eleven weeks before death. There had been pleurisy twice; and, toward the last, deaf-

ness, ringing of the ears, giddiness, nausea, copious hemorrhage from the bowels, and copious epistaxis. He died the day after leaving the hospital, and the spleen was sent from Lawrence by Dr. Wm. D. Lamb; nothing being said of any other disease. This case occurred about the time that leucocythemia was being made known to the profession. 1847.

Dr. E. Leigh.

3096. Portion of the spleen, showing the yellowish masses that are occasionally met with in connection with organic disease of the heart. The patient had frequently had intermittent fever, and died from disease of the heart (No. 1707). The organ weighed $1\frac{1}{4}$ lbs., was generally firm, and some lighter colored portions were particularly so. The opaque, yellowish masses were moderately firm, and sharply defined; one being an inch in diameter, and the other, 2 in. by 1 in. They came quite to the surface, as usual, so as to be at once seen; and there were some remains of false membrane upon the peritoneal surface, as is so often the case. Microscopically, the masses consisted of small granules, about the size of blood-globules. In the preparation the color has much faded.

For an analysis of eleven cases of this disease of the spleen, and its connection with disease of the heart, see No. 583 in the Catalogue of the Cabinet of the Boston Soc. for Med. Improvement. 1860.

Dr. C. Ellis.

3097. A section of the spleen, showing great numbers of large, rounded, opaque, and more or less curdy tubercular masses. 1862.
3098. A cretaceous body $\frac{1}{2}$ in. in diameter, from the interior of the spleen. 1867.

Mr. Frank A. Wells, med. student.

3099. Section of the spleen, showing extensive melanotic disease.

From a man, æt. twenty-four years, who had been sick about nine months. (Hospital, 36, 174.) He had a large melanotic tumor in the neck, and smaller ones beneath the skin, and amongst the muscles; with similar disease in the renal capsules, the head of the pancreas and liver, besides an extensive encephaloid deposit in this last. The

spleen weighed $13\frac{1}{2}$ oz., and contained several defined, rounded, soft, brownish-black masses, — some of which were half as large as a hen's egg. 1852.

Dr. J. B. S. Jackson.

3100. Section of a spleen, showing an extensive and rather firm encephaloid deposit.

From a woman, æt. thirty-three years, and who reported herself as having been sick only five weeks. The kidneys, stomach, liver, and gall-bladder were cancerous; and the last were crowded with calculi. 1867. *Dr. C. Ellis.*

3101. A mass of glandular substance, that contained three cysts that were filled with blood, and that was removed from the thyroid gland.

The patient was an unmarried woman, æt. twenty-five years; and the disease was of twelve years' duration. It began upon the median line, increased slowly until the last year, and then rapidly. On admission into the hospital (114, 248), it occupied the whole front of the throat, and extended from side to side, 12 in.; uniform in aspect and in its elastic feel, and but little movable. It was supported by a net, on account of its weight, but caused no other discomfort. The patient was rather anæmic, and reported that her grandmother had cancer. — The mass was easily removed, but the hemorrhage was profuse, and the blood seemed to ooze from the whole surface. The patient soon rallied from the operation, though the swelling caused great dysphagia for a time; and in about a month she was discharged well.

Dr. H. remarked that in two other cases the tumor was peeled from a bed of healthy thyroid gland, and the hemorrhage from the whole surface was such as to require ligatures to be applied *en masse*. (Med. Jour. Vol. LXXI. p. 399.) 1864. *Dr. R. M. Hodges.*

3102. Renal capsules diseased, from a case of Addison's disease.

From an unhealthy woman, æt. thirty-seven years, whose skin had been discolored for eight months before her death. Under the care of Dr. Fogg, of Dedham, for the last four or five weeks, who found the face and hands of a dark-

brown color. Debility was the chief complaint, but she kept about until the last two days, when she had nausea; appetite craving; costive.

Both capsules were very much thickened, and one was several times larger than natural. The right was mostly converted into a firm yellow material, with considerable calcareous matter. The left consisted throughout of a yellowish, firm, caseous, or calcareous material, with a considerable amount of thick, puriform fluid. 1867.

Dr. C. Ellis.

3103. A second case; the first that was observed here, and very fully reported by Dr. G. in the *Med. Jour.* vol. *LVI.* p. 480.

The patient was a farmer, æt. forty-four years. Health robust, but had been failing the last year. Loss of flesh, strength, and appetite; frequent nausea and vomiting; pain in abdomen on stooping; irregularity of bowels; coldness, rigidity, and insensibility often in the fingers; dizziness, failure of memory, and listlessness. Gave up work about two months before death. Complexion, during the last eight months bluish, or almost purple, so that disease of the heart was thought of. May 22d, 1857, he arrived here from the eastward, and on his way to the West for his health. He had been very sea-sick; and was found in the morning in his berth insensible, with irregular breathing, a very rapid and feeble pulse, hiccough, inability to swallow, firm closure of the eyelids and contraction of the pupils; hands very cold, and fingers rigidly flexed. In this condition he was carried to the hospital (211, 50), where he died in six hours. The skin looked as if there might be a mixture of Indian and Negro blood, which, however, was not the case; and the discoloration was not confined to the exposed parts. The cheeks were decidedly bronzed. For some weeks a discoloration had been observed within the mouth; and it was seen, bordering the lips, as a circle of dark, but not livid spots.

Dr. Ellis found the renal capsules adherent to the surrounding fat. The left was much thicker than usual, very firm, and of a bluish-white color, though much of it was occupied by soft, yellow deposits, resembling tubercular

matter or concrete pus. The deposit consisted of minute globules or granular corpuscles, varying in size from those of tubercle to those of pus. The firm portion was fibrous. The right capsule was smaller than usual, though thicker at one part, and nowhere flat as usual; disease as in the left, but much less extensive. There was, also, some old disease of the brain, ecchymoses in the lungs, and a large quantity of blood in the heart, that was fluid, and continued so after removal from the body. 1857.

Dr. A. A. Gould.

3104. A third case.—The patient, a female, æt. thirty-one years, had been under the care of Dr. B., for about a year, with debility, a bronzed skin, and other anomalous symptoms; the discoloration terminating near the margin of the hair, and leaving a narrow white line between the two. Occasionally there were attacks of indigestion; and during her recovery from one of these, she indulged very grossly in indigestible food, and died in consequence. Both renal capsules were greatly enlarged; texture firm; and studded thickly with irregular, tubercular-looking deposits, from the size of a small shot to that of a chestnut. Other organs well. 1860.

Dr. H. I. Bowditch.

For other cases of Addison's disease, see p. 395.

3105. A thin cyst in the substance of the renal capsule. Collapsed; but, if distended, would have been nearly as large as an English walnut. Traces of cretaceous matter in the parietes.—From a female dissecting-room subject, about twenty-five years of age, and almost anæmic in appearance. Lungs tubercular. 1857.

Dr. R. M. Hodges.

3106. An iron bar, that was driven through a man's head. He seemed to have entirely recovered from the accident, and lived twelve years and a half afterward, but died finally with cerebral symptoms. (See No. 949.)

The bar is 3 ft. 7 in. in length, and weighs $13\frac{1}{4}$ lbs.; form cylindrical, and diameter $1\frac{1}{4}$ in.; one end is square, as in a common crowbar, and the other tapers to a smoothly blunt point,—this last measuring $\frac{1}{4}$ in. 1868.

Dr. John M. Harlow, of Woburn.

3107. An iron gas-pipe, by which a man was transfixed through the head in May, 1867. (See No. 952.)

Dr. Bigelow mentions (April 1st, 1870) some important facts in regard to this case, and that were not referred to in the papers from which the history (p. 149) was drawn up. He says: "When addressed, his expression was intelligent and singularly pleasant. He evidently apprehended what was said to him, but rarely replied in words. His habitual reply on such occasions was 'mais, oui;' and this, with the word 'tabac,' of which article he was very fond, seemed to constitute his vocabulary. There could be no question that this was a case of what has been called aphasia. As far as could be judged, his intellectual functions were not disturbed. Being brought to a new city, he showed within a few days a singular faculty of finding his way home, through the streets, and from long distances, unaided." Dr. B. has also handed to me a letter from Dr. Jewett, that I had not before seen (dated April 29th, 1868), and in which he says: "To my request that he would go home with me, and work in my garden, he replied, 'No, sir-ee,'—the largest number of words I have heard him connect since the injury."—Dr. B. has heard nothing (1870) of the man since the middle of last summer, but he was then in fine health, and in regard to speech he had decidedly improved. There has never been, he says, any paralysis. 1868. *Dr. H. J. Bigelow.*

3108. A wrought-iron spike, $3\frac{3}{8}$ in. in length, that projected 2 in. from a barn floor, and upon which a man fell head foremost, 16½ ft. The case occurred (Dec. 1868) in the practice of Dr. C., who gave the following history of the case; and, at the request of Dr. J. B. Upham, presented the spike to the museum. (Med. Jour., March 24th, 1870.)

The patient was a laborer, twenty-eight years of age. The spike passed through the upper posterior part of the right parietal bone, and carried a portion of it, an inch square, into the substance of the brain, to the depth of about 2 in.; the fracture extending, also, downward nearly to the ear. The man was "firmly buttoned down to the floor" by the head of the spike, which measured $1\frac{1}{2}$ in. across; and, in their attempts to extricate him, two strong

men had raised the body, and pulled upon it with much force, but in vain. Finally, he was released by splitting away the plank in which the spike was fixed, with an axe and crowbar.

When Dr. C. saw the patient, an hour and a half after the accident, the spike was still in the head. This was removed, with the fragments of bone that had been driven into the brain, and others were raised to their proper position. Immediately the man was able to converse rationally, but there was a complete loss of sensibility and motor power throughout the left side. About seventy-two hours afterward severe pain came on in the left arm and leg, and lasted for half an hour, when almost instantly the sensibility returned, though the power of motion never did. The pain subsided, and he continued in a rational state until the ninth day, without inflammatory symptoms, and with a pulse that never rose above 70. On that day portions of brain were discharged; the man sank rapidly, and on the following day he died.

On examination after death the brain was found completely broken up, to the extent of 4 in., and to the depth of 2 in.

A portion of a two-inch plank, from which the spike projected, has been sent with this last. 1870.

Dr. Sherman Cooper, of Claremont, N. H.

3109. The iron portion of a pitchfork, one of the prongs of which passed through a man's head.

The patient was an Irishman, about sixty years of age, who fell, feet foremost, through a barn loft, and upon the fork, Sept. 12th, 1860. One prong entered the right cheek, passed under the malar bone, came out a line or two above the coronal suture, about $\frac{1}{2}$ in. to the right of the median line, and protruded about 2 in.; the man's feet barely touching the floor. The concavity of the prong was forward and somewhat outward. After the extraction of the prong, which required some force, he walked to a carriage, rode in a drenching rain two miles, and, unaided, alighted and went up one pair of stairs. Dr. Francis A. Howe, of Newburyport, who sent the pitchfork to Dr. Bigelow, and who gives this account of the case, was called, and found

him, seated in a chair, extremely pallid, bathed in a cold perspiration, conscious, but dull, and with a pulse of 52 and feeble. "The man did not speak until some time after the fork was withdrawn, and then only to answer imperfectly a question, and when pressed for a reply; and he remained exceedingly stupid until he became unconscious." Wound in the cheek ragged, and readily admitted the little finger to beneath the arch of the malar bone. The wound in the scalp was small, but bled freely; skull broken, and pushed upward prominently; and a probe was passed downward 2 in. The lower wound was closed, the upper one dressed with cold water; and he was then helped to ascend another flight of stairs.

Before he could be got into bed he vomited freely, became greatly prostrated, and shortly afterward almost completely unconscious.

"At midnight violent reaction came on, and he was thought to be dying. His face was much swollen; respiration stertorous; eyes injected; pupils contracted; surface of the body hot and dry. Pulse 40, hard, and very 'jerky;' and it was impossible by any effort to arouse him. After venesection, to the amount of ℥xxx. , the pulse became softer and more frequent, and the breathing less stertorous; and there were slight indications of returning consciousness." Pounded ice was ordered to his head; a large saline cathartic was given, and half a grain of Tart. antimony every two hours.

The next morning he was much improved, and recognized Dr. H. as he entered the room. Respiration nearly natural. Eyes still more injected, and intolerant of light. Pulse 70, but rather hard. Complained much of pain at the top of his head, but said that he was otherwise comfortable. The cathartic had operated quite freely, and the antimony had caused no nausea.

The ice was continued, and the antimony in smaller doses, and less frequently for five days; and the case was then left in the hands of nature. At the expiration of two weeks he went downstairs, and in three weeks he was able to do light work about the house.

The sense of sight and smell were not affected; but,

having been always a little deaf, he became so much so after the accident that he was unable to hear common conversation.

In August, 1861, Dr. H. saw him again, and when he he was on his way back to Ireland. The hearing was unimproved; and he was incapacitated, mentally, from earning a livelihood. He could do very plain work, by the side of another laborer, as shovelling or hoeing; but, if left to himself he would seem to forget his work, and quit it; and he would often wander listlessly about, up and downstairs, out and in doors; often stopping abruptly and for some time, as if in doubt which way he should go. 1861.

Dr. H. J. Bigelow.

3110. A chaise-hook that was driven through the orbital plate of the frontal bone.

A gentleman was driving himself in a buggy, when his horse took fright, and he was thrown out with great violence. His head struck the hook, which was strongly attached by screws to the hard wood frame of the top of the buggy, above and in front, and which was driven into the left orbit rather toward the median line. In a few minutes he recovered his consciousness, and, with a little assistance, walked about one-eighth of a mile, to a house where he was very soon seen by Dr. B. The hook was almost immovably fixed, and nearly or quite three-fourths buried in the orbit; the flat plate, by which it was attached to the frame of the buggy, lying firmly pressed against the front of the orbital ridge, and with the screws projecting from it. An incision was made to the extent of about an inch, and the hook was extracted without any great difficulty, though considerable force was required; after which he was removed to his home in the country, a distance of about five miles. For the first few days there was much pain and swelling about the wound, with some delirium; and for some weeks a general headache. He was confined to the house only for about ten days, and in about four weeks returned to his business. He suffered more or less from his head, however, for some months, and even now, after the lapse of about eight years, he would not dare, he says, to tax his mind too far. — The point of the hook is

quite blunt, and Dr. B. supposed that it penetrated the frontal sinus, but not the cranial cavity. 1867.

Dr. H. J. Bigelow.

3111. The point of a penknife, $\frac{5}{8}$ in. in length, that was extracted from the temporal bone.

The patient was a little boy, six years old, who fell, with the open knife in his hand, and the point entered the right temple. He ran into the house, with the knife standing off at a right angle; and, after great force had ineffectually been used to extract it, an Irish girl gave a powerful wrench, and broke it off. The whole knife being shown, as well as the point, the blade is seen to be considerably twisted. When Dr. B. saw the child, three hours afterward, there was a puncture in the skin just large enough for the passage of the blade; and, the bone having been exposed, an opening, and no larger one, was seen in the bone. The bone was then pared away; and, the blade being exposed, was seized with a pair of wire pliers, and extracted. A jet of blood immediately followed the extraction; and, after about half a teacupful had been allowed to flow, it stopped spontaneously. The child was about in three or four weeks; and from first to last never had a bad symptom. 1857.

Dr. H. J. Bigelow.

3112. The breech-pin of a gun, that was driven deep into the substance of the brain; recovery, after its removal, rapid and complete.

The following history of the case was given by Dr. S., with the specimen, Nov. 16th, 1869:—

“James Getchell, Jr., æt. seventeen, was lying on his belly shooting at sea-fowl. The gun at the shoulder, and the eye, as usual, glancing along the barrel. At the discharge the pin was blown out, and penetrated the forehead about an inch over the right eye; the screw by which it is secured to the stock, through the shoulder or process, going in with it. He was brought to his home across our harbor, about half a mile, in a semi-conscious state. No part of the pin was visible, and it could be felt only by introducing the finger nearly its whole length; the projection by which it is attached to the stock lying next the surface. It was extracted with difficulty, and partly owing to the

screw. It was estimated that about two large spoonfuls of blood and brain followed. The fragments of bone were extracted by forceps; and he soon recovered, with little suffering; vision in the eye, however, being lost, though the shape of the globe and its motions were preserved. Nothing was required or done except one bleeding, and cathartic. (In those days we bled for everything.) The accident happened about the year 1820 or 1821; a year or two after, he was lost at sea." 1869.

Dr. Joseph L. Stevens, of Castine, Me.

3113. A second case. — The breech-pin of a gun, that was driven through the right eye, and projected in front of the ear; recovery, after its removal, rapid and complete.

This case occurred in the practice of the late Dr. Henry Tuck, of Barnstable; and the following history is from a letter that he wrote to a friend, dated June 20th, 1837. The patient was out shooting, when his gun burst; and, though he was two miles from home, he was able to walk that distance, with the help of his brother. The small end of the pin entered first, and projected immovably about a fourth of an inch near the ear. The iron could not be seen in the socket; but, on passing in an instrument, it was seized and extracted. "It required three or four men" (Dr. T. says) "to hold the patient while he was under the operation of extraction, and nearly all my strength, which is not small, to remove the iron. I pulled upon it with both hands, resting my knee upon his forehead to keep his head from being lifted from the table;" and it will give a stronger idea of the force that must have been used, to state that Dr. T. was a very large and powerful man. The eye was so mangled that it was removed at once. In seven weeks the man was at work upon his farm; and he is still alive.

The specimen is presented by a son of Dr. T., who is now a resident of this city. 1869. *Dr. Henry Tuck.*

3114. A third case. — Cast of the breech-pin of a gun, that was removed from the right upper maxillary bone, after it had been there for eight years.

The case occurred in the practice of Dr. James N. Fra-

ser, of St. Johns, Newfoundland, and a full report of it was published in the *Med. Jour.* (Vol. LXVII. p. 471).

The patient was a robust fisherman, thirty years of age; and the accident was occasioned by the bursting of the gun in his hands on the 14th of Oct., 1848. Violent inflammation followed, with excruciating pain, and he was confined to the house until the following March, with a constant fetid and purulent discharge from the cheek and nostril, and general debility. In May, 1849, the external wound closed, and so remained until November, 1854, when an opening took place, and discharged pus, with powder and rust. In January, 1855, he had violent hemorrhage from the nostril, and it continued occasionally until April. During all this time he was subject to severe headache, and there was a complete loss of the sense of smell, an occasional dimness of vision, and pain in the right eye, with very serious impairment of his health. In August, 1855, an abscess formed in the cheek, and the pain was more intense than ever. On the 17th of June, 1856, he was seen by Dr. F., and the iron was felt through the opening in the cheek; but the mouth could not be opened more than a quarter of an inch, so that the interior could not be examined. The foreign body, the presence of which had never been suspected, was then removed; the screw being imbedded in the antrum, and the part that had been screwed to the back of the stock being in close contact with the pterygoid process of the sphenoid bone. The length of this last portion was $2\frac{3}{4}$ in., and the circumference of the screw $2\frac{1}{8}$ in. After the operation the wound did well, the pain almost wholly subsided, the sense of smell was restored; and, six years afterward, when Dr. S., to whom the cast was sent by Dr. F., heard from him, the man still continued in excellent health, though the action of the lower jaw was still very limited. 1863.

Dr. D. H. Storer.

3115. A piece of rough pine wood, that was removed from a man's cheek; nearly as large as the finger at one extremity, and tapering to a point at the other; length about $3\frac{1}{2}$ in., and nearly broken off about three-fourths of an inch from its small extremity.

On his admission into the hospital (144, 6), he stated that four months before, whilst standing near a circular saw, a piece of wood flew against his face, inflicted a wound an inch or two in length, and then, as he supposed, fell to the ground. The wound soon very nearly healed; but an abscess formed behind the ear and discharged; and there was once a discharge of pus from the meatus. On admission, the cheek was a little thickened, and the foreign body was indistinctly felt. Pain chiefly in the mouth, with a discharge into it, and a sinus in the cheek and behind the ear. On the following day the piece of wood was removed, and in a few days he left the hospital quite relieved. During the operation there was a discharge of blood from the ear, and also from the sinus behind it. 1869.

Dr. R. M. Hodges.

3116. An iron hay-hook, by which a little girl was transfixed. It was purchased of the family by Dr. Stimson, who was called to the child at the time of the accident, and who removed the hook.

The case was attended by Dr. J. P. Maynard, of Dedham, and fully reported by him in the *Med. Jour.* (Vol. LVII. p. 29), with a figure.—The child, eleven years of age, was sliding down a hay-mow, May 9th, 1857, when she fell upon the hook, the point of which passed through the perineum and bladder, and made an external wound, $\frac{3}{4}$ in. in width upon the left side of the umbilicus. The hook measures from the point to the extremity of the barb, $5\frac{1}{2}$ in.; transversely at the barb, nearly 2 in.; and it was supposed to have entered the body to the extent of 11 in. Dr. M. saw the child just after the withdrawal, and found her in a state of collapse; but in the night she began to rally. Urgent vomiting protruded a portion of omentum, which was returned with difficulty; and, the opening being closed, it did not again escape. For a time the urine passed altogether through the wounded bladder, and with it what appeared to be fæcal matter from the small intestine; but this gradually diminished. Small sloughs of cellular tissue, also, for a time came away. On the fifth day violent peritonitis ensued, but this soon subsided; and on the twentieth day there was severe pain. On the 11th of

June the opening in the bladder was touched with the nitrate of silver; and from that time the urine and fæces passed by the natural outlets. On the 21st she walked and rode out without inconvenience; and Dr. M. discontinued his attendance. About the 14th of July diarrhœa came on, followed by vomiting, and she died on the 23d.

On dissection, the laceration of the perineum and the cicatrix near the umbilicus were found, externally. In the upper and anterior part of the vagina was a direct and perfectly cicatrized opening into the bladder, which, when forcibly dilated, was not more than 2 lines in diameter (No. 2482). Upon the vaginal surface it appeared as a marked indentation; but, upon the vesical, it might readily have been overlooked. The bladder contained a calculus (No. 2689), that seemed to have formed about one of the sloughs from the wounded parts; also a puriform secretion, but no urine nor fæces. The organ was thick and muscular, and upon its inner surface of a dull red color. At the fundus it adhered to the ileum about 3 ft. from the cæcum; and between the two was an opening about 2 lines in diameter. Beneath the cicatrix in the skin a portion of omentum was found (No. 2344), about $\frac{1}{2}$ in. in diameter, and closely adherent to the rectus muscle, through which it had passed, and to the integument. There were no peritoneal adhesions, except immediately about the wounded parts, and no acute inflammation; though there were traces of a carbonaceous discoloration of the membrane, that were probably the result of former inflammation, and a trace of pus in the cellular tissue of the pelvis.

In connection with the above case, Dr. M. referred to the collection of "hay-hook cases," published by Dr. Z. Howe in the *Med. Jour.*, March, 1840; to the very remarkable case published by Dr. Sargent, of Worcester, in which a rake-handle passed through the body from the perineum to the clavicle (*Amer. Jour. of Med. Sc.*, Oct., 1853); and to the cases of impalement by various means, that Dr. Coale collected from the journals, etc., and published in the *Med. Jour.* (Vol. LV. p. 387.) 1857.

Dr. Jeremy Stimson, of Dedham.

These cases of impalement from the sliding down from a

hay-mow are by no means very rare here in New England ; and, though recovery seems to be the law, rather than the exception, the liability to their occurrence cannot be made too generally known in the country.

3117. The iron portion of a hay-hook, similar to the one above described. In this case a boy, about ten years of age, slid from a hay-mow, with his thighs bent upon his body ; and the hook, entering the back part of the thigh, midway, passed through the muscles, under Poupart's ligament, through the ileum, behind the liver, through the diaphragm, behind the lung, and between the seventh and eighth ribs. The barb, however, caught on the eighth rib, and the point did not penetrate the skin. The boy died in three and a half hours ; and there was found a hemorrhage into the peritoneal cavity from a wound in one of the ext. iliac veins. The case occurred in the practice of Dr. Godding, of Winchendon ; and the hook, which was removed after death, was sent by Dr. H. who assisted at the examination. 1862. *Dr. A. Hitchcock, of Fitchburg.*

3118. The iron portion of a pitchfork, by one of the prongs of which a boy was transfixed. — He was fourteen years old, and was ascending a hay-mow, with the fork in his hand, when he fell ; and, as he slid down the mow, the fork went first, and he came down upon it ; the prong entering the perineum, and coming out about an inch to the left of the umbilicus. The prong had been broken and mended, and, not being very strong, it was somewhat bent at the time of the accident. The fork was at once withdrawn ; and a small piece of omentum, that protruded, was returned. The boy did perfectly well ; and, when the fork was sent to the museum, he was a stout, healthy young man, twenty-three years of age. 1860.

Dr. Edward F. Barnes, of Marlboro'.

3119. A rake-handle that entered a man's scrotum upon the left side, passed in front of the pubes, along the abdominal parietes, and came out at the right hypochondrium, opposite the space between the tenth and eleventh ribs.

The patient was a laborer, twenty-nine years of age ; and the accident, which happened May 7th, 1860, was caused by his slipping down from a hay-mow upon the rake below.

Considerable force was required to extract it. Hemorrhage slight. The testicle was completely turned out, and almost denuded; but was put back, and the wound did well. On the following day there was extensive ecchymosis, and at the end of a week an abscess formed over the wound midway; but the man's recovery was rapid and complete. (Med. Jour. Vol. LXII. p. 479.) 1860.

Dr. H. B. Burnham, Epping, N. H.

3120. An upright round, from the back of a broken chair, upon which a man was pushed down. It entered 1 in. behind the anus, passed through the thyroid foramen, and protruded beneath the skin near the pubes; the extent of penetration being about 9 in. The diameter of the stick is $\frac{7}{8}$ in., and from the extremity that entered the body a piece had been slivered off.

The patient was carried at once to the hospital (134, 262), and the stick was withdrawn by Dr. H., without any hemorrhage. The accident happened on the 15th of April. On the 17th a piece of cloth was removed, and is shown with the stick. On the 19th large incisions were made in front; the parts beneath being inflamed and sloughy; and on the 22d he died. — The peritoneum was quite healthy; but there was erysipelatous cellulitis, and in one lung numerous pyemic deposits. (Med. Jour., Aug. 6th, 1868.) 1868.

Dr. R. M. Hodges.

3121. A thick, sharp-pointed splinter of wood, $1\frac{1}{2}$ in. long, and a slender piece $\frac{2}{3}$ in. long; removed in an operation for fistula in ano.

The patient was a man, twenty-eight years old. Three months before, a board, upon which he was lying, broke, and sharp pain was instantly felt. Three weeks afterward the part was lanced, and there had been a discharge from that time. No opening was found by Dr. B. into the intestine; and the patient was soon well. (Hospital, 75, 24.) 1857.

Dr. H. J. Bigelow.

3122. A piece of rough pine stick, $3\frac{3}{4}$ in. long, and nearly $\frac{1}{2}$ in. wide at the largest part.

From a little boy, seven years old, who complained that he had fallen and hurt his hip. His mother, who was a woman of sufficient intelligence, examined it carefully, but

found nothing, — no blood and no wound ; and he was not kept from his school or play. Five weeks afterward the stick was felt beneath the skin, just above and parallel to the groin ; the child having complained of soreness there. Dr. H., being consulted, removed the foreign body, and the child did well ; but he was as unable as the mother had been to discover the point of entrance. 1859.

Dr. R. M. Hodges.

3123. An irregular mass of rock, weighing 2 lbs. 5½ oz. ; diameters about 7½ in., 4½ in., and 2 in. Driven into the front part of the thigh of an Irishman who was blasting rocks ; and so buried in the flesh as not to be seen. Dr. C. enlarged the opening and removed the stone. Bleeding very slight, and pain not very great ; no collapse. 1861.

Dr. Benj. E. Cotting, of Roxbury.

3124. Portions of several needles that were removed from the calf of the leg of a hysterical girl ; some before, and others after her entrance into the hospital (95, 252). There were points upon all of them ; and they were undoubtedly introduced by the patient herself. 1868.

Dr. H. G. Clark.

3125. A musket-ball, and probably a round one, removed successfully from the frontal sinus, June 26th, 1863, by Dr. H., when he had charge of the St. James Hospital. in New Orleans.

From a soldier, who was wounded in an assault on Port Hudson on the 14th. There was an opening, large enough to admit a director, over the eyebrow, and a scar near its outer extremity. A small portion of bone is imbedded in the ball. 1867.

Dr. J. Homans.

Rifle, or musket balls, that were collected by Dr. B., who served in the army during the greater part of the Civil War. 1863.

Dr. Henry Bryant.

3126. 1. A shapeless mass of lead, from the cavity of the hip-joint, after death. The ball struck the middle of the thigh upon its outer face, split the shaft of the femur throughout, and then apparently followed up the bone, which was entirely comminuted for 6 in. below the head. Both trochanters were broken off, and the head and neck split into

pieces, some of which were larger than the ball. This was the worst case of gun-shot injury that Dr. B. saw during the war.

3127. 2. A conical ball, very little bruised. It entered the outside of the left thigh, about 2 in. above the knee-joint, and passed out on the inner face, about an inch lower down; then entering the right thigh upon its inner face, and a little above the centre of the condyle, it passed between the integuments and the patella, across the joint, and was taken out near the head of the fibula, with four pieces of cloth, which are shown with the ball. Result, fatal.
3128. 3. A shapeless mass of lead. The ball entered the upper back part of the right arm; fractured the head of the humerus, acromion process, and outer third of the clavicle, passed behind the mastoid muscle, and in front of the trachea, and was extracted from the left shoulder, just beneath the integument.
3129. 4. A round ball, quite bruised to about one-third of its extent. Extracted from the left shoulder. Fracture of the acromion and head of the humerus. Recovery.
3130. 5. A ball, considerably bruised; and to the part that is most so a piece of bone is still firmly adherent. It entered the thigh upon its outer face, about 2 in. above the knee, and was extracted from just behind the outer ankle. Recovery.
3131. 6. One-half or more, of a round ball; the flattened surface being nearly smooth. It entered near the great trochanter, and was extracted from the back of the thigh, midway.
3132. A buck-shot, considerably flattened, with three thicknesses of flannel, removed by Dr. W. L. Bond, of Charlestown, from just above the elbow of a soldier, who was wounded at Port Hudson. 1868.
Mr. V. D. Taylor, med. student.
3133. Four small balls; flattened as if by being rammed down into a pistol. — From a man, æt. sixty-one, who committed suicide. The balls entered near the umbilicus, came out at the right shoulder, about an inch from the spine, and

were found in the man's flannel shirt. Death immediate from loss of blood. 1864.

Dr. Ira Allen, of Roxbury.

3134. Shot removed from the scalp of a dissecting-room subject; generally misshapen, and some of them much flattened. 1862.

3135. Clam-shells broken, and subsequently repaired. 1861.

Dr. B. S. Shaw.

3136-7. A case of surgical instruments, used by Dr. John Warren, during and after the Revolutionary War, and presented by his son, Dr. J. C. Warren, to Dr. B. — Also a tourniquet used by the first Dr. W. 1858.

Dr. H. J. Bigelow.

3138. A tourniquet, invented during the Civil War for the personal use of the soldiers, and with which large numbers of them were supplied. 1870.

Dr. R. M. Hodges.

3139. A bandage, supposed to be nearly a hundred years old; with a note, giving its history. 1858.

Dr. J. M. Warren.

3140. A bandage, picked up at Sebastopol during the Crimean War. 1858.

Dr. R. M. Hodges.

3141. Bullet forceps, used, during the Revolutionary War, by Dr. Lemuel Hayward, father of the late Prof. H., and grandfather of the donor. 1866.

Dr. J. McLean Hayward.

3142. Wutzer instruments, used in the operation for the radical cure of hernia. 1870.

Dr. R. M. Hodges.

A collection of tonsil instruments, presented in 1858.

Dr. J. M. Warren.

3143. 1. Invented by Mr. Caleb Eddy, a civil engineer of this city, upon whose child Dr. J. C. Warren was to operate. Mr. E. got the hint for this very simple and efficient instrument, from a machine that is used for cutting grass at the bottom of creeks.

3144. 2. Another instrument of Mr. Eddy's; modified.

3145. 3. Dr. Gibson's instrument.

3146. 4. The French scissors.

3147. 5. Tieman's instrument.
3148. 6. Dr. Cock's knife and ring; in a case.
3149. 7. Tieman's spring forceps and knife, for dragging out and cutting off the gland; in a case.
3150. An "Indian puzzle" as it has been called, and that has been suggested as an efficient means for the reduction of dislocated fingers. (See Hamilton on Fractures and Dislocations; p. 603, with a figure.) 1869.
Dr. H. J. Bigelow.
3151. A scarificator, for cupping. 1870.
Dr. R. M. Hodges.
3152. A tooth-key; and two other instruments for the extraction of teeth.
Museum Fund.
3153. A long cylindrical stethoscope. Laennec's pattern, and,
3154. One of the many varieties of the same, that have been invented since the time of L. 1864. *Museum Fund.*
3155. A pair of "Perkins's Tractors," that were so famous in Europe as well as in this country, in the early part of this century, for the cure of all sorts of disease; like a stiletto, about 3 in. in length, and cut longitudinally; large at one end, and pointed at the other; convex upon one side, and flat upon the other; one being made of brass, and the other of iron. (See Thacher's Med. Biography, and the Encyclopædia Americana.) 1860.
Dr. Jonathan Ware, of Milton.
3156. The hand of a woman, and of a child, prepared so that, being now quite dried, they can, as Prof. M. states, be restored to their natural condition on being immersed in a liquid, of which he has not yet, but will soon publish the composition. Presented by Prof. M., at the suggestion of the Hon. Geo. P. Marsh, the American Minister.
Prof. Eftzio Marini, of Florence.

THIRD DIVISION.

MISCELLANY.

SERIES XLI.—NATIONAL SKULLS, CASTS OF HEADS, ETC.

All of the specimens in this series were given by Dr. J. C. Warren, and in 1847, unless otherwise recorded.

3157. English skull.

3158. Cast of an English skull. — This is one of twelve casts, that were sent to Dr. W., in 1849, by Dr. Samuel G. Morton, of Philadelphia, as typical specimens. 1849.

3159. "English form." S. and H.

All of the specimens of the races that were in the Phrenological Collection (p. 710) have been transferred to this series; and, with a few exceptions, that will be designated, they are all casts. P. C. signifies Phren. Collection. S. and H., from the collections of Dr. Spurzheim and Mr. Holm. An asterisk (*) indicates a mask; a cross (†) indicates a skull, and the rest are heads.

3160. "Celtic form. Mad. Michat; south of France." S. and H.

3161. "An Casimir." S. and H.

3162. * "Jew; tribe of Benjamin." S. and H.

3163. † "Skull from the burial-ground of London Hospital." S. and H.

3164. Irish skull.

3165. † A Highlander. S. and H.

3166. Skull of a German. Cast; from Dr. Morton. 1849.

3167. Austrian skull.
3168. Copt; cast of the skull, from Dr. Morton.
3169. Skull of a Greek, who was killed at Scio; several recent sabre cuts being seen upon the back. Nasal bones unusually long and prominent.
3170. Skull of a Turk.
3171. † "Turk; St. Bats." S. and H.
3172. Skull picked up at Aboukir, in Egypt.
- 3173-5. Guanche skulls. — They show a depression to a considerable extent along the sagittal suture, and in No. 3173 it is quite marked. In this same skull, also, there is a perforation of the left parietal bone, from old disease; the opening being closed, upon the inner surface, by a new growth of bone.

Casts of pre-historic specimens. 1866.

Museum Fund.

3176. 1. The Neanderthal skull.
3177. 2. The Engis skull.
3178. 3. A lower jaw, from the cave at Arcy, Yonne, France. The original is in the possession of the Marquis de Vibraye, Paris.
3179. Græco-Egyptian skull. Cast; from Dr. Morton. 1849.
3180. Ancient Egyptian skull. Cast; from Dr. Morton. 1849.
3181. † Skull from an Egyptian mummy. Cast. P. C.
3182. Cranium from an Egyptian mummy, that belonged to Ward Nicholas Boylston, Esq., and that was given after his death to the late Dr. S. The æthmoid is broken away, as usual; and in the cranial cavity is a large quantity of a very pure bituminous substance. Parietal foramina, $\frac{1}{4}$ in. in diameter; and there are some appearances of disease upon the surface of the frontal bone. 1859.

Dr. Geo. C. Shattuck.

3183. One of the legs, from the above; with many thicknesses of bandage about it, and applied with the usual regularity. 1859.

Dr. Shattuck.

- 3184-94. Hindoo skulls. Nos. 3184-5 are children; and No. 3194 shows extensive disease of the alveoli, — the surrounding bone being quite healthy.
3195. † The same. P. C.
The next six specimens are skulls, and not casts.
- 3196-8. "Natives of Bengal. Hindoos." P. C.
- 3199-3201. " " Mussulmans." P. C.
3202. " " " Cast.
3203. † "Bengallee." P. C.
3204. Hindoo skull; cast.
3205. Skull picked up on the banks of the Ganges, but probably a Caucasian. Amateness very large. P. C.
3206. Chinese skull.
- 3207-9. " " cast. S. and H.
3210. Chinese skull of Tartar race, according to Dr. Bachi." Cast.
3211. Foot of a Chinese woman; natural skeleton, and about 5 in. in length. The os calcis makes about a right angle with the rest of the foot; its position is very nearly perpendicular, and its form quite irregular outwardly, and at the insertion of the tendo achilles. The bones are, of course, small; but otherwise the foot is well formed, excepting some obliquity of the metatarso-phalangeal articulations. 1863. *Mr. Geo. Sceva.*
3212. Bones of the mate to the above, separated by maceration. Appearances of os calcis the same. Both specimens prepared by Mr. S. 1863. *Mr. Geo. Sceva.*
3213. Model of the extremely small foot of a Chinese woman, as it appears when dressed. 1863. *Mr. G. Sceva.*
3214. "Kalmuc; Royal Museum, Paris." Cast.
3215. "Devotee, according to Dr. Bachi." "
3216. * "Kirkgese; a race in Siberia." S. and H.
3217. † "Burmese; from the camp at Rangoon, where it was dug up." S. and H.
3218. Malay skull. Cast; from Dr. Morton. 1849.
3219. Skull of a dissecting-room subject from Manilla. Cal-

varia wanting. The upper alveolar processes are quite prominent; and there is a want of symmetry posteriorly. 1854. *Dr. R. M. Hodges.*

3220. † "New Hollander." P. C.

3221. Skull of a negro. Cast; from Dr. Morton. 1849.

3222-5. † African. S. and H.

3226-32. African skulls.

See No. 961. The obliteration of the cranial sutures that characterizes the African is finely shown.

3233. The same; strongly characterized. 1848.

Dr. O. W. Holmes.

The African skulls, in the collection, are generally heavy, and some of them quite so.

Nasal opening in the negro. (See No. 1537.)

3234. * "Negro, Angelo—remarkable for his knowledge of languages." S. and H.

3235. "Eustache Belin—a negro. Born in St. Domingo, and died in 1835. Remarkable for courage and benevolence; and gained the first Monthyon Prize in 1832." P. C.

3236. Abyssinian skull.

3237. Cast of the head of a native Hottentot. The man was seventeen years old, had been on exhibition for several months in this city; and finally hung himself. His skeleton is in the Museum of Comparative Zoology, at Cambridge. 1861. *Museum Fund.*

3238. A small specimen of hair from the head of a "Bushman," from S. Africa. Small portions of the hair were very tightly twisted into little coils, so that the whole head seemed, as it were, covered with spines.—From a female, about nineteen years of age, who was exhibited in this city. 1862. *Dr. J. B. S. Jackson.*

3239. * "Madagascar (male)." S. and H.

3240. * The same, (female.) "

3241. † "Madagascar Negress." "

3242. † "Mozambique Negro." "

3243. * "Madagascar and Negro." "

- 3244-5. † "New Zealander." S. and H.
3246. Australian. Cast of skull; from Dr. Morton. 1849.
3247. "Owhyhee.—Tea-pot; native of the spot where Capt. Cook was killed." S. and H.
- 3248-9. * "Tattooed."
3250. Skull of a Sandwich Islander, who hung himself. A large Wormian bone is seen above the right temporal bone. From the dissecting-room. 1856. *Dr. R. M. Hodges.*
3251. A specimen of the coarse, thick, straight, black hair, that characterizes the South-Sea Islanders. From the above subject. 1856. *Dr. R. M. Hodges.*
3252. Chilian. Cast of the skull; from Dr. Morton. 1849.
- 3253-5. † "South American Indian." S. and H.
3256. † Carib. P. C.
3257. Cast of the head of a Flat-head Indian, from the Columbia River. Taken about three weeks after death, and when there had not been much cadaveric change.
- The subject was a male, twenty-two years of age; had been sent to Europe by the missionaries for his education; and died in this city, extensively tuberculous. Measurements: from vertex to soles of feet, 5 ft. $\frac{3}{4}$ in.; from head of humerus to tip of middle finger, in a straight line, 2 ft. $4\frac{3}{4}$ in.; from upper extremity of great trochanter to sole of heel, in a straight line, 2 ft. $9\frac{1}{4}$ in.; 11 in. across the hips; and 15 in. across the shoulders; hand 7 in. long, and foot $9\frac{1}{4}$ in. Hands and feet quite delicate, and nails long and finely formed. The toes overlapped about as much as in Caucasians generally; but there were no corns. 1860. *Museum Fund.*
- Nos. 54, 236, 503, and 1847, were from the same subject; and also the next four specimens. 1860. *Museum Fund.*
3258. 1. The cranium.—Sagittal suture obliterated to a considerable extent, though the subject was young; and this accords with the remark of Dr. J. Thurnam (*Nat. History Review*, April, 1865), that flattening by artificial pressure tends to premature co-ossification. 1860.

3259. 2. Hair from the head.
3260. 3. Skin from the pubes ; with the hair upon it.
3261. 4. The ear, perforated in six places near the margin.
The other had been similarly treated.
3262. Skull of a Flat-head Indian, brought from the North-west coast by Mr. K. 1864. *Mr. John Knight.*
3263. "Chinook ; Columbia River. Col. Perkins."
3264. " " " J. J. Astor."
3265. † "Flat-head Indian." S. and H.
3266. Skull of a North American Indian ; from Salem, Mass.
3267. A second. "Menominee ; from Dr. Morton."
3268. A third. From Nantucket, Mass. The subject was a child.
3269. A fourth. From near Wachusett, Mass., and considerably broken. 1857. *Dr. John White, of Westminster.*
3270. A fifth, considerably broken ; from an island in Boston harbor. (See No. 237.) 1862. *Dr. H. G. Clark.*
3271. A sixth ; not a cast. P. C.
3272. A collection of bones, probably of Indian origin, and labelled, in an illiterate hand, "From Mt. Dorgester"(Dorchester, Mass.?). Of three humeri, one has the olecranon fossa perforated.
3273. A skull. "Found while repairing the fortifications of Fort Independence. Supposed to be of Caucasian race."
P. C.
3274. "Qualish, the last of the Indian tribe at Dedham (Mass) ; was buried in 1774 ; æt. sixty-eight. The bones were found in a perfect state, and every tooth in its place."
1856. *Dr. H. J. Bigelow.*
3275. Cast of the skull of an Indian ; "shot many years since, while prowling round a house in the interior of Massachusetts. Combativeness, destructiveness, and secretiveness uncommonly large. Benevolence deficient." P. C.
3276. † Wyandot Indian, in the Dorfeuille's Museum, Cincinnati. P. C.

3277. † "Pepick, a distinguished Winnebago Chief, who was killed at Chicago, in 1812, at the head of a party of his tribe, by the American troops." P. C.
3278. † Cast of a skull from Fort Mackenzie. P. C.
- 3279-80. Skulls from "Rocky Cavern, in Steubenville, Ohio."
- 3281-5. Skulls from Alton, Ill. A ridge along the sagittal suture is a prominent feature in these skulls.
3286. Aboriginal American. Cast of skull; from Dr. Morton. 1849.
3287. † "Cast of a skull, from a mound in Cincinnati, Ohio, and supposed to be a fair specimen of the crania that properly belong to the mounds of our country." P. C.
3288. "A Peruvian Indian. From a cemetery, in which no interments have been made since the conquest by Pizarro, and near a Temple of the Sun, about twenty miles to the southward of Lima. The organization very closely resembles that of the last specimen." P. C.
3289. † "Said to be that of a North American Indian. Probably a Peruvian."
3290. † Peruvian. Back part of the head, flattened. P. C.
- 3291-3. Peruvian skulls, of the Inca race. The first was brought from Lima, by Capt. Hull, U. S. N.
- 3294-6. The same. Nos. 3290 and 3294 are very much distorted posteriorly. 1849.
3297. "Peruvian, from Deville." Cast of skull; and very greatly compressed antero-posteriorly.
- 3298-9. "Peruvian, sacrificed to the Inca." Casts.
3300. "Peruvian." Cast.
- 3301-2. Ancient Peruvian; the frontal region of which is flattened. Casts; from Dr. Morton. 1849.
- 3303-5. The same. Casts of the skull.

The following table gives the measurement of most of the above specimens. To get the internal capacity of the skull, it was filled with shot (No. 2 B), and these were then transferred to a tin canister; the shot being well shaken and rammed down in each. The space that

they occupied was then indicated by a wooden cylinder, that was fitted to the canister, and graduated to half an inch. No. 3169 was measured with rice. The longitudinal diameter shows the distance from a point about 1 in. above the fronto-nasal suture, to the most prominent point of the occiput, upon the median line. The next column gives the distance from this last point to the anterior edge of the foramen magnum. To get this measurement, and to which Dr. Wyman attaches so much importance in his "Observations on Crania," the two points that indicate the long. diameter were brought very nearly, if not exactly, into a horizontal line; plumb lines were then dropped to the ant. edge of the foramen and the post. point of the occiput, and the distance between the two was measured. This was the method used by Dr. W. for the occipital region; and by a very simple and ingenious contrivance, he made his measurements with great accuracy. It was very desirable to get this measurement in the case of the casts that were sent by Dr. Morton to Dr. Warren, as typical specimens; and it was taken, as the position of the condyles showed pretty exactly where the anterior edge of the foramen would have been. The last column shows the distance, over the top of the skull, from the fronto-nasal suture to the posterior edge of the foramen magnum.

	No.	Int. capacity.	Long. diameter.	Occiput.	Over vertex.
English,	3157	99½	7½	3 ⁹ / ₁₆	14½
“ cast,	3158		7 ⁹ / ₁₆	3 ³ / ₁₆	15½
Irish,	3164	97	7¼	3 ¹ / ₁₆	15½
German; cast,	3166		6¾	3 ³ / ₈	14½
Austrian,	3167	97	7¾	3½	15½
Copt; cast;	3168		7¼	3 ¹ / ₁₆	14½
Sciot,	3169	97	7½	3½	15¾
Turk,	3170		7 ³ / ₈		14½
Guanche,	3173	70	6¾	3½	14
“	3174	77	7	3 ³ / ₁₆	14½
“	3175	80½	7	3 ⁵ / ₁₆	13½
From Aboukir,	3172	93½	7½	3	14¾
Engis skull; cast,	3177				
Græco-Egyptian; cast,	3179		7½	3½	14½
Ancient “ “	3180			3 ⁷ / ₁₆	15½
Egyptian mummy,	3182		7½		

	No.	Int. capacity.	Long. diameter.	Occiput.	Over vertex.
Hindoo,	3184	80½	6½	3½ ¹ / ₆	14½
"	3185	69½	6½	2½	13½
"	3186	79½	6½	3½ ¹ / ₆	14
"	3187	71½	6½	2½	13½
"	3190	86½	6½	3½ ³ / ₆	14½
"	3191	65½	6½ ³ / ₆	2½ ⁷ / ₆	13
"	3192	69½	6½	2½ ¹ / ₆	13½
"	3193	74½	6½	3½ ¹ / ₆	13½
"	3194	73½	6½	2½	14
Chinese,	3205	89½	6½	3½	14½
Malay; cast,	3217		7½	3½ ³ / ₆	15½
Negro; "	3220		7½ ⁵ / ₆		15½
African,	3225	87	7½	3½ ⁰ / ₆	15½
"	3226	85	7½	3½ ⁵ / ₆	14½
"	3227		7	3½ ³ / ₆	14½
"	3228	96	7½	3½ ³ / ₆	15½
"	3229	73	6½	3½ ³ / ₆	14
"	3230		7½	3½	14½
"	3231	93	7½ ¹ / ₆	3½	14½ ¹ / ₆
"	3232	92	7½	3½ ¹ / ₆	14½
Abyssinian,	3235	74½	6½	3½ ³ / ₆	13½
Australian; cast,	3245		7½	3½	15
Sandwich Islander,	3249		6½	3½	13½
Chilian; cast.	3251		7½	3½	15½
Flat-head Indian, from the Columbia River,	3257	93	6½	2½ ⁵ / ₆	13
Flat-head Indian, from the Columbia River,	3261	83½	6½ ³ / ₇	2½ ⁰ / ₆	13
Flat-head Indian, from the Columbia River,	3262	77	6½	3	13½ ⁰ / ₆
Flat-head Indian, from the Columbia River,	3263	87	6½	2½ ³ / ₆	13½
N. A. Indian; Massachusetts,	3265		7	3	14½
" " " about	3266		6½	3½ ³ / ₆	14
" 3 yrs. old, "	3267		6½	3½	14½
" " " "	3273	85	7	3½ ⁵ / ₆	14½
" Ohio, "	3278		7½	3½ ¹ / ₆	15½
" " " "	3279		7		13½
" Illinois, "	3280		6½	2½ ⁷ / ₆	13½
" " " "	3281	90	7½	3	14½
" " " "	3283	100	7½	3½ ¹ / ₆	15½
" " " "	3284	82½	6½	3	14
Aboriginal American; cast,	3285		6½	2½	14½
Peruvian; Inca race,	3290	88	6½	3½	14½
" " " "	3291	63	5½	2½	12½
" " " "	3292	92½	6½	2½	14½
" " " "	3293	82	6½	2½ ⁷ / ₆	13½
" " " "	3294	79½	6½	2½ ⁰ / ₆	12½
" " " "	3295	67½	5½	2½ ³ / ₆	12½
" Ancient race,	3300		5½		13½
" " " "	3301		6	4½	14½

SERIES XLII. — ZOÖLOGY.

3306. Cast, by Dr. J. Wyman, of one of the anterior hands of a Chimpanzee. 1851. *Dr. O. W. Holmes.*
3307. A bat; from this neighborhood. 1862.
Mr. Wm. Andrews, Janitor of the College.
3308. An iguana, from S. America; stuffed. 1862.
Museum Fund.
3309. A lizard from Texas (*Phrynosoma cornuta*); and commonly known as the "horned frog;" dried. 1862.
Museum Fund.
3310. A gar-pike; from the Western waters; about 3 ft. long; dried. 1860. *Dr. J. B. S. Jackson.*
3311. A flying-fish; from Barbadoes; in spirit. 1868.
Dr. J. B. S. Jackson.
3312. A series of five asterias; in spirit, and showing the gradual re-development of the rays that have been lost. One individual is seen to have lost two of its rays, and the new ones are unequally developed. 1852. *Dr. J. Wyman.*
3313. The same; dried. 1852. *Dr. J. Wyman.*
3314. Bot-flies; in spirit. (*Cestrus equi*.) 1868.
Mr. Wm. P. Bolles, med. student.
-

SERIES XLIII. — MEMENTOS.

3315. A human scapula, from the catacombs of St. Calixtus, — a burial-place of the Christians of the first or second century, and just outside of the walls of Rome. Other bones were got, but they crumbled. A palm-branch that was cut in the stone over the bones, and a small cup for the blood, showed the individual to have been a martyr. Also the body of a human vertebra from a columbarium outside of the walls of Rome, and that had been recently opened when Dr. H. visited it in 1859. A full account of the catacombs of Rome is given in a series of articles in the

Atlantic Monthly Magazine, commencing March, 1858.—
Reference, etc., from Dr. H. 1861.

Dr. J. McLean Hayward.

3316. A humerus, dug up upon the field of Waterloo, by Dr. J. H. H., father of Dr. H. 1858.

Dr. J. McLean Hayward.

3317. "Femur, tibia, and ulna of men killed at the Wadsworth fight, at Sudbury, Mass., April, 1675. The bones were dug up where they were originally interred." 1852.

Mr. Henry Shaw, med. student.

3318. A skull from the battle-field of Gettysburg. According to the head-board it was that of a member of the Georgia Volunteers. 1863.

Dr. J. P. Ordway.

3319. Three rifles, obtained in Virginia by Dr. F., who served in the army during the whole of the Civil War. One has been shot through the barrel near the muzzle. A second has been shot through rather farther back, and the end is bent to a right angle with the body of the barrel. The third was shot through the end of the stock, near the muzzle. 1863.

Dr. John W. Foye.

3320. A bombshell, weighing 96 lbs., and said to have been the last that was thrown across the Potomac River by the Confederate Army, before the blockade of that river was raised in April, 1862. The distance that it was thrown was about two miles and a half. 1868.

Dr. J. W. Foye.

3321. A cannon-ball, that was thrown across the Potomac River during the Civil War, and fell within the lines of the Northern army. It was red-hot, so that the soldiers boiled their coffee over it. Its weight is 40 lbs.; and it was sent on by Dr. B., who lost his life whilst serving in the army, professionally, during the Civil War. 1861.

Dr. Luther V. Bell.

3322. Biography of Walton, a celebrated highwayman, bound in his own skin. He was in the State Prison for life, and died of phthisis in 1857; and, his body having been carried to a dissecting-room, Mr. W., who was then a medical student, had a portion of the skin tanned. 1858.

Francis H. Williams, Esq.

SERIES XLIV. — PHRENOLOGY.

The following specimens, excepting a few that will be designated, were collected by the Boston Phrenological Society; and, after its active existence terminated, they were purchased by Dr. J. C. Warren, and presented by him to the Medical College in 1847. The first specimens were from the Collections of Dr. Spurzheim, and of Mr. J. D. Holm, of London; and the following memoranda and descriptions are from the Phrenological Society's Catalogue.

The masks have an asterisk (*) prefixed; the skulls have a cross (†); and the heads have no distinctive mark.

3323. Dr. J. F. Gall.
 3324. Dr. G. Spurzheim, cast in 1803.
 3325. " " 1825.
 3326. Madame Spurzheim, after death, in 1829.
 3327. * Napoleon Bonaparte.
 3328. * Lord Chatham.
 3329. * Lord Brougham.
 3330. * Horne Tooke.
 3331. * Charles XII.
 3332. General Foy, M. C. D., and
 3333. Manuel, M. C. D., orators and independent characters.
 3334. S. Neukomm, cast in 1814.
 3335. * " " 1821.
 3336. * " " July, 1834.
- (See Phrenological Journal, Vol. vi. p. 487.) Marked No. 28 in list of Dr. Gall's collection. Increase of the organs of ideality and music.
3337. * Samuel Taylor Coleridge, cast in 1810.
 3338. " " 1827, æt. fifty-four.
 3339. " " after death, July, 1834.
- Biography in Galignani's edition of poetical works.

3340. * William Godwin, cast in 1805, by G. Dawe.
3341. " " Aug., 1830, æt. seventy-four.
Increase in the organ of Benevolence. Author of History of the Commonwealth, Caleb Williams, Political Justice, Thoughts on Man, etc.
3342. St. Jullien, cast in 1824. Literateur.
3343. " " 1833. Private Secretary of Napoleon.
3344. George Wright, painter and engraver, cast in 1828.
3345. " " " 1833.
Increase in constructiveness.
3346. Giulio Regondi, cast in 1832.
3347. " " 1834, æt. thirteen. Musical genius.
3348. E. H., cast in 1827.
3349. " Aug., 1834. Increase in the organ of music.
3350. J. W. H., cast in May, 1827.
3351. " " Aug., 1834. Increase in the anterior lobes, etc.
3352. F. Mendelssohn Bartholdy, of Berlin, cast in 1829. Grandson of the philosopher, Moses Mendelssohn.
3353. " Cast in July, 1833, æt. twenty-four. Amateur musical composer.
3354. Sophia Pyke, cast in 1829. Became an actress.
3355. " 1823. Organs of imitation, music, and ideality increased.
3356. Sarah Newell, miniature painter, cast in 1829.
3357. " " 1832.
3358. Mr. J. H., surgeon, cast in 1829.
3359. " Aug., 1832. Increase of the organs of ideality, language, and amativeness.

TEMPERAMENTS.

Horace Vernet. Nervous temperament. Historical painter. (No. 3475.)

3360. Miss Crump. Sanguine.
 3361. Sukey Hilling. Lymphatic.
 3362. Lady Angela Stirling. Lymphatic, with sanguine.
 Augustus de Morgan. “ bilious. (No.
 3502.)

INSANE.

3363. Monsieur L'Abbé, so she styled herself. A religious fanatic, with a great deal of vanity and cunning.
 3364. Theroine, Robespierre's mistress. Violent; and occupied with political subjects; quite fanatic.
 3365. Insane woman.
 3366. Mitaty. Believed in demons.
 3367. Carter. (See Phrenological Journal, Vol. vi. p. 490, marked No. 33 in Dr. Gall's collection.)
 3368. Mr. C.'s boy, æt. fourteen; addicted to stealing and lying, which he could not resist; fell into despair and hung himself.
 3369. Kleft's boy. Of some talent, but melancholy. Hung himself.
 3370. Brain of a suicide.
 3371. G. Thompson, and
 3372. — Evanson. Surgeons; great sufferers to despondency; strong inclinations to commit suicide.

ALIMENTIVENESS.

3373. Buisson.
 3374. † “ Large alimentiveness.
 Harris, No. 3428, and A. de Morgan, No. 3502, large alimentiveness.
 3375. Mrs. H. Small alimentiveness; particularly moderate in eating and drinking.

DESTRUCTIVENESS.

3376. John Thurtell.
 3377. † “
 3378. Lecouffe; son.

3379. † Part of skull of ditto, with the temporal muscle taken off on one side, and left on the other, in order to show the inefficiency of judging by sight, and not by pressure.
3380. † Lecouffe; son.
3381. “ brain. (See Phrenological Journal, Vol. VI. p. 483.) No. 8 in Dr. Gall's collection.
3382. Lecouffe; widow.
3383. † “
3384. “ brain. (See Phrenological Journal, Vol. VI. p. 486.) No. 20 in Dr. Gall's collection.
3385. Henry Feldtman. (See Phrenological Journal, Vol. VI. p. 494.) No. 49 in Dr. Gall's collection.
3386. Burke. (See Phrenological Journal.)
3387. Hare. “
3388. Bishop. (See Lancet and Phrenological Journal.)
3389. Williams. “ “
3390. Guichet. (See “ “ Vol. VI. p. 486.) No. 18 in Dr. Gall's collection.
3391. † Griffiths, executed at Lancaster.
3392. † Mary McInnes.
3393. † Bellingham.
3394. William Corder, æt. twenty-four. Executed for the murder of Maria Marten, at Polstead, Suffolk, May, 1828. (See English newspapers of this period.)
3395. Leger. (See Phrenological Journal, Vol. VII. p. 184.) No. 303 in Dr. Gall's collection.
3396. Asselino; murdered his mistress. Guillotined in France.
3397. † Destructive amative madman.
3398. Murderess.
3399. Elizabeth Cook, alias Ross. Executed at the Old Bailey, London, for burking.
3400. Mrs. H'r, a lady of respectability, who, with a string, strangled her cat, for having stolen the fish.
3401. Bohours.
3402. † “ (See Phrenological Journal, Vol. VI. p. 599.) No. 204 in Dr. Gall's collection; marked Boutsours.

3403. * Dobie, and
 3404. * Thompson. Executed at Edinburgh, for rape. (See Times, May 4th, 1830.)

AMATIVENESS.

3405. * Millère. Committed rape.
 3406. Hagmane. Highly educated man, seduced his own daughter, who was twenty-eight years of age.
 3407. † Amative Fortune Teller, who deceived almost all the nobility of Vienna. She kept two gentlemen. Cerebellum very large.
 3408. † Demarara Planter. Brought home by Capt. Beechy, R. N.; after a series of debauchery, and even sodomy, he shot himself.

3409. John Miller. Back part of head.

3410. Catharine Welsh. Executed at the Old Bailey, London, for drowning her child, at Fulham, 14th April, 1828.

The child was illegitimate, and her husband refused to live with her unless she put it out of the way.

While walking near the place where the body was found, she was observed to suffer severely from conflicting feelings; and suckle the child and caress it with all the fondness of a mother previous to the fatal occurrence. The organ of philoprogenitiveness is large, but that of physical love, and the whole region of the animal propensities very large, while that of the moral and religious sentiments, and of the reflective faculties are proportionally small.

PHILOPROGENITIVENESS.

3411. Infanticide. French.
 Mitaty. Large philoprogenitiveness. (No. 3366.)
 3412. Dr. B. de Sanctis, small “

ATTACHMENT.

3413. Heloise. (See Phrenological Journal, Vol. vi. p. 499.) No. 78 in Dr. Gall's collection.
 3414. Nicholas Steinberg. Murdered his mistress and four

children, and afterward committed suicide, 9th Sept., 1834. Phrenological development in the News, 21st Sept. (herewith) by J. D. Holm.

COMBATIVENESS.

3415. Captain Varal, of Napoleon's Imperial Guards, had fought ninety-six duels, and was engaged to fight six more when the cast was taken, 1831.
3416. † Georges Cadoudal, a conspirator against Bonaparte, with the Pichegrus; employed by the English government. (See Phrenological Journal, Vol. VI. p. 483.) No. 86 in Dr. Gall's collection.

SECRETIVENESS.

3417. Chevalier le Leivre. (See Phrenological Journal, Vol. VI. p. 492.) No. 42 in Dr. Gall's collection.
3418. Baume; was employed by the Jesuits when a child.

ACQUISITIVENESS.

3419. Ratta and
3420. Malaguti, entered the shop of an Exchange Broker named Joseph, and dropped a bag of gold; when Joseph stooped to pick it up, they struck him violently, and left him senseless, taking with them all the gold they could lay their hands upon; this they buried in a field, which they frequented so continually that it excited suspicion. They were executed at Paris. Malaguti was an excellent mechanic, and invented a grinding machine, in which they intended to conceal their stolen property, and return to their country (Italy).
3421. Smithers, set fire to his house in Oxford Street, London, for the purpose of defrauding the Insurance Office. (See account of his development, by Dr. Elliotson, in the *Lancet* and Phrenological Journal, 1832.) Executed at the Old Bailey.
3422. Dumb thief of Vienna. This boy was one of those in whom Dr. Gall observed the situation of this organ; he wished to become a tailor, in order that he might have an

opportunity of stealing. Described by Dr. Gall, Vol. iv. p. 203, l. 12.

3423. St. Simon, a man of very unsettled mind; he wished to become very rich at the commencement of the French Revolution. He was guided by vanity, under Napoleon, and tried to prove he was a descendant of Charles the Great, and published on that subject; under the Bourbons he wrote on Political Economy, and formed a school in which the industrious were to be at the head of the administration. Many young men followed his opinions. He likewise established a new system of marriage.

3424. Gætan Louis Fontana. Cast, July, 1833. A disciple of St. Simon.

CONSTRUCTIVENESS.

3425. Louis Palmerino. Inventor of a new kind of manual calculating engine.

3426. * Brunel. Architect of the Thames tunnel, etc.

3427. Serquet. Harp-maker.

3428. Harris. Chronometer-maker.

3429. * Voigtlander. Mathematician and mathematical instrument-maker.

3430. * M. Streicher. Teacher of music, and maker of instruments.

3431. Conrad Bruntz. Inventor of a new kind of mill, and player on several instruments. (See account of his organization in *Lancet*, 1834.

Wright. Engraver. (3345.)

Babbage. Inventor of the calculating engine. (3483.)

3432. Pierre Couty. Mechanical talent.

CAUTIOUSNESS.

3433. Cautious maniac.

Madame de Laborde Bussoni. Large caution, causing her to be very despondent. (3516.)

Steinburg, 3414, and Evanson, 3372; large caution.

LOVE OF APPROBATION.

- Mons. L'Abbé, insane on love of approbation. (3363.)
 3434. Denon, whose vanity is even shown in the physiognomy
 of the bust
 A. R. W. (3527.)

SELF-ESTEEM.

3435. Schlabendorf. (See Phrenological Journal, Vol. vi. p.
 484.) No. 12 in Dr. Gall's collection.
 3436. Dr. Chervin. Independent character.

BENEVOLENCE.

3437. John Bacon; good-natured fellow, never seen in an ill-
 humor.
 Mrs. Booth (3526), and Miss Noble (3524). Humane
 and benevolent ladies. Good phrenologists.

VENERATION.

3438. Roland. (See Phrenological Journal, Vol. vi. p. 488.)
 3439. " Top of skull. No. 30 in Dr. Gall's collection.
 3440. " Brain.
 3441. Religious enthusiast.
 3442. Rowland Hill.

FIRMNESS.

3443. Hirschfield. Small firmness, indecisive.
 A. R. W. (3527), and
 Schlabendorf (3435).

CONSCIENTIOUSNESS.

3444. Lemare. Teacher of languages; he took an active part
 in the French Revolution, but desisted when injustice was
 practised; large conscientiousness.
 Spurzheim (3325), and
 Coleridge (3338).

HOPE.

3445. B. Smith. His large hope and acquisitiveness made him a great speculator.
 Evanson. Small hope. (3372.)

MARVELLOUSNESS.

3446. Destaisniers.
 3447. Dr. T. Abuses much his marvellousness.
 3448. Visionary.
 3449. * Varley. Astrologer and inventor of the "Idographi"? Idoscope.
 3450. * Hey. A gentleman who considered if he tried, could ruin government by gaining all the prizes in the lotteries; constantly inventing machines; immense hope.
 3451. * Mitchell. A soi-distant prophet and a visionary.

IDEALITY.

3452. Sestini. (See Phrenological Journal, Vol. vi. p. 590.)
 3453. † " Skull. No. 148 in Dr. Gall's collection.
 3454. " Brain.
 3455. Sir Walter Scott.
 3456. Thomas Campbell.
 3457. * William Roscoe. Author of the Life of Leo X.
 3458. Dr. Bowring.
 3459. Deacon. Editor of the Portsmouth Journal.
 3460. Legouve. (See Phrenological Journal, Vol. vi. p. 483.) No. 44 in Dr. Gall's collection.
 3461. Miss Stirling Graham.
 3462. Mrs. Hall. Authoress of the Buccaneer, and Irish Sketches.
 Coleridge (3338); and A. R. W. (3527), a highly accomplished and elegant lady.

WIT.

3463. Mrs. Hope. Large mirthfulness.

Madame Bussoni, large wit (3516); and Mrs. Hall (3462).

IMITATION.

3464. † Charles Matthews.
 3465. † Edmund Kean.
 3466. Goldschmidt. Great imitator.
 3467. Massey. Mouth; the most difficult position in which he could retain it.
 3468. † Junger. Actor.
 Sophia Pyke (3355).

INDIVIDUALITY.

3469. Miss Harriet Martineau.
 3470. Dr. Pinel.
 3471. * Bécclard. The anatomist; large individuality and form.
 Roscoe (3457), and R. B. Sheridan (3520).

FORM.

3472. Girodet. Historical painter.
 3473. Taylor. Collector of paintings, etc.
 3474. † Bacon. Sculptor.
 3475. Horace Vernet.
 3476. Cohen. Lithographer.
 3477. Vander Kleft. Amateur sculptor and painter.
 3478. Bailly. Sculptor.

SIZE.

3479. McAdam. Civil Engineer.
 3480. * Wyvill. Draughtsman.
 3481. S. L. Kent. Can tell accurately how many yards of a carpet will cover any sized room.

WEIGHT.

3482. La Place.
 3483. * Babbage. Mathematician.

COLOR.

3484. † Norbel. Colorist.
3485. Nottingham genius. Dr. Spurzheim saw this man occupied as a bricklayer's laborer, at Nottingham; by the advice of Dr. S. he studied the fine arts, and is now teacher of music and painting.
3486. Sir William Beechey. Portrait painter to the king.
3487. Hippolyte Bruyères. A rising historical painter of Paris. Son-in-law of the late Dr. Spurzheim.
3488. * Ottley. Small color.
3489. George Owen, Attorney. Cannot distinguish between red and green.
3490. * Milne. }
 3491. " } Cousins. Small color.

LOCALITY.

3492. Capt. Walker. Traveller.
3493. * Fraser. "
3494. Travelling servant from Munich; the first individual in whom Dr. Gall noticed the organ of locality.
3495. * Humboldt.
3496. * Scheidler.
3497. Buckingham, M. P. Traveller in Asia and Africa.
3498. Dr. Clarke. Traveller in Russia, Sweden, and Norway.

CALCULATION.

3499. † Descartes.
3500. * Vienna Calculator, in whom Dr. Gall first discovered the organ of number, which is very large.
3501. * Whewell. Mathematician, of Cambridge.
3502. Augustus de Morgan.
3503. * Nottingham Calculator.
 La Place (3482), and Babbage (3483).
3504. * A relative of Mme. Spurzheim.

EVENTUALITY.

3505. Hering. Surgeon.
Roscoe (3457), and Sheridan (3520).

ORDER.

- A. R. W. (3527), and Mrs. H. (3375). Large order.

TIME.

3506. * J. Barrett. Librarian of Trinity College, Dublin
(See Phrenological Journal, Vol. vi.)
Cohen. Very deficient time. (3476.)

TUNE.

3507. * Haydn.
3508. * Dussek. Musical composer for piano.
3509. Gretry. (See Phrenological Journal, Vol. vi. p. 586.)
No. 186 in Dr. Gall's collection.
3510. Blagrove. Violinist, fifteen years old; then leader of
the orchestra at Birmingham.
3511. Madame Schröder Devrient. Celebrated German singer.
3512. Richmond. Imitates the musical snuff-box with his voice.
Large imitation, music, and constructiveness.
3513. * Lambley. Died insane on music.
3514. * Litz. (See Phrenological Journal, Vol. vi. p. 497.)
No. 65 in Dr. Gall's collection.
3515. * Joseph, 2d. (See Phrenological Journal, Vol. vi. p.
487.) No. 27 in Dr. Gall's collection.
3516. Madame Bussoni. An accomplished Italian singer and
composer.
3517. † Frederick the Great.
3518. * Miss Paton, æt. eight.
3519. * Ann Omerod, of the blind school at Liverpool
Mendelssohn Bartholdy (3353), and Giulio Regondi
(3347).

LANGUAGE.

3520. R. B. Sheridan.
3521. Thelwall. Lecturer on elocution.
3522. Cicero.
Godwin (3341), Coleridge (3339), St. Jullien (3343),
and Angelo (3234).
3523. Miss Sheridan. Authoress of the Comic Offering.
3524. Miss Noble.
3525. Mrs. Grimstone. Authoress of Cleone, etc.
3526. Mrs. Booth.
3527. A. R. W.
3528. Miss Macauley.
Mrs. Hall (3462), Miss Stirling Graham (3461), Miss
Crump, authoress of the Mummy (3360), Lord Chatham
(3328), and Horne Tooke (3330).
3529. * Sir J. E. Smith, the botanist.
3530. * Dr. Macartney. Small language.

COMPARISON.

Gall (3323), Spurzheim (3325), and Babbage (3483).

CAUSALITY.

Gall (3323), Spurzheim (3325), English Form (3159),
Godwin (3341), and La Place (3482).

3531. Dr. Eljotson.
3532. Extraordinary long brain.

3533. * Sir Isaac Newton. Probably from a statue. Locality,
number, size and weight, large.
3534. Burke, the statesman.
3535. Talleyrand.
3536. L'Abbé Pompière.
3537. Cardinal de la Fare.

3538. Bory de St. Vincent.
3539. Bigouret. Member of the Council of 500.
3540. * Tasso. Ideality and wonder large. (See Ed. Phrenological Journal, No. 25, p. 487.)
3541. * Wordsworth, the poet.
3542. N. P. Willis.
3543. * Mr. P——. A young poet, of Yale College.
3544. François Cordonnier; poet.
3545. * John Muller. German historian. Dr. Gall considered this as a perfect model of the organization which disposes to philosophical studies. Organ of language unusually large.
3546. * Voltaire. From a statue. Language, mirthfulness, and ideality large.
3547. * Lawrence Sterne. Mirthfulness large.
3548. Henry Mackenzie. Author of the Man of Feeling.
3549. † Bichat, the anatomist. Skull remarkable for want of symmetry in the hemispheres.
3550. Pinel.
3551. Châussier.
3552. Broussais.
3553. Dr. Benj. Rush. Intellectual organs, and love of approbation very large.
3554. * President Day, of Yale College. Order, locality, individuality, and language, large.
3555. † Whitfield, the celebrated preacher. Taken, by Dr. N. B. Shurtleff, from the original skull at Newburyport.
3556. William Sigourney, of this city, a celebrated wit. 1847.
Dr. J. C. Warren.
3557. Prof. Nuttall, the ornithologist.
3558. Bust of Dr. Gall.
3559. “ Dr. Robertson.
3560. “ Dr. Spurzheim. 1867. *Dr. H. J. Bigelow.*
3561. Portrait of “ 1867. *Dr. R. M. Hodges.*
3562. Original cast of the skull of Dr. Spurzheim. Taken by Dr. S. 1848. *Dr. N. B. Shurtleff.*

3563. Rev. John Pierpont, }
 3564. Wm. B. Fowle, Esq., } Members of the Phren. Society.
- 3565-6. Dunbar & Ditchfield, members of the Anthropological Society.
3567. * Garrick. Probably from a statue. Imitation, ideality, and mirthfulness largely developed.
3568. H. J. Finn. Comedian. Comparison very large. Back of head inaccurate.
3569. † General Wurmser. He commanded the Austrian army in Italy, and was defeated by Bonaparte. His prodigious courage, and attachment to his friends were prominent traits in his character. Organs of combativeness and adhesiveness remarkably large, and cautiousness small.
3570. * Dr. Park, of London. Locality large.
3571. * Holman, the blind traveller, and well known by his volume on travels. Locality large.
3572. * Zerah Colburn. Organ of number, large. A youth; and
3573. The head of an adult, marked "Zerah Colburn."
3574. * George Bidder. A remarkable calculator. Number very large.
3575. * M. G——. Lieutenant in the Navy, and remarkable mathematician. Number large.
3576. * Oldham, an ingenious mechanic; at the age of thirty-six. Imitation and constructiveness large.
3577. * —— . At the age of fifty-one, and showing an increase of the organ of constructiveness.
3578. * Martin Martins. Ideality and reflective organs large.
3579. Knox, a lawyer. "Sentimens superieures developés."
3580. * David Gould. Individuality, locality, order and size, large. .
3581. * Joannis (Français). Individuality large. Jesuit, from the collection of Dr. Gall. Comparison predominant.
3582. Tolotoy, a Russian Princess. Temperament very nervous; noble and courageous; love of children largely developed.

3583. Underwood, an Englishman. "Caractère déterminé."
3584. † An obstinate man. Firmness large.
3585. † Timid female. Dr. Spurzheim used to show this in contrast with that of Gen. Wurmser (No. 3569). Combativeness small, and cautiousness large.
3586. † Dr. Hette, of Vienna. Strong antipathy to the society of women, and lived always alone, or in houses inhabited only by old men. Timid; cerebellum small; secretiveness, cautiousness, hope, reverence, and approbation, large.
- 3587-8. Pleguier and Carbonneau. Political conspirators under Louis XVIII. Firmness and pride.
3589. Asa Low, paper manufacturer of Vermont. Causality, mirth, and acquisitiveness, remarkably large. Order, large.
3590. * R. R. Jones, of Liverpool. Great love of languages, but intellect inferior. Language very large, and reflective organs small.
3591. * Abraham Courtney, a blind man, and formerly well known in this city. Remarkable for his love of travelling, and faculty of finding places; being familiar with all the streets and lanes in Boston, Cincinnati, and New York. He travelled by himself in nearly every State of the Union, after he became blind. Locality uncommonly large.
3592. † Mr. S——. Mirthfulness large. Hope small.
3593. * Canova; taken after death. The organs of form, size, individuality, locality, constructiveness, ideality, and all that were necessary to the greatness of his genius, are largely developed.
3594. Chapotal. A pastry cook. Sculptor for the School of Medicine.
3595. * Stone. Architect. Size, locality, and number, large.
3596. † Milliner of Vienna; and known to Dr. Gall as very expert in her trade. Constructiveness and love of approbation, large.
3597. Penniman, of this city. Ornamental painter.
3598. * N. S. Josselyn; portrait-painter. Size, locality, and imitation, large.

3599. * William H. Brown ; distinguished, in this city, for his remarkable skill in cutting profile likenesses of the whole person. Size, form, and constructiveness, large.
3600. * Karner Vaider. Famous for cutting caricatures, extempore, and with scissors only. Organs of imitation, mirthfulness, form, size, and constructiveness, large.
3601. * Von Weber. Musical composer. Time, tune, ideality, and wonder, large. (See Ed. Phrenological Journal, p. 300, No. 14.)
3602. Ostinelli, a well-known and distinguished violinist for many years, in this city.
3603. Osburne. An Irishman, and musician.
3604. Gelineck, of Paris. Harpist.
3605. * W. M. Goodrich, an organ-builder of E. Cambridge. Celebrated for the excellent tone and construction of his instruments. Tune, constructiveness, and benevolence, large. Taken by Dr. N. B. Shurtleff.
3606. Dr. Dodd, the English divine. Executed for counterfeiting.
3607. Mark Winslow, of this city. Notorious for manufacturing and altering counterfeit money. Sentenced to the State Prison for life, but cut his throat in the Leverett Street Jail. Secretiveness very large, and hope small.
3608. Fortier. A rogue and gambler.
3609. Mitchell, a boy condemned to the State Prison in Maine for cruelty. Destructiveness very large.
- 3610-13. Papavoine, Assilinau, Ulbach, and Croquelit ; assassins.
3614. Orchard, brigand. Attacked a diligence.
3615. Chevalier de Lyon. The poisoner of many women.
3616. Antoine Le Blanc. Taken after death by Dr. N. B. Shurtleff. He murdered the family of Mr. Sayre, in Morristown, N. J., for money. Organs of destructiveness, secretiveness, and acquisitiveness, enormously developed ; and adhesiveness large. Perceptive faculties very deficient.
3617. John Pallet, murderer of Mr. Mumford. Taken after

death, and marked according to the former marking of Mr. Combe. (See Ed. Phrenological Journal.)

3618. Cæsar Reynolds. Taken after death by Dr. N. B. Shurtleff. A negro, who was executed at Hartford, Conn., for the murder of the keeper of the Connecticut State Prison. Head remarkable for the size of the occipital region, and the smallness of the frontal. Organs of firmness and destructiveness very large; those of the reflective faculties being small, and the lower perceptive faculties rather large.
3619. William Teller, an accomplice of Cæsar. His head shows a larger development of the reflective faculties, though smaller affective. Teller, it is said, first conceived the idea, and devised the plan of escaping from prison. The keeper was to have been gagged; but Cæsar, who was to have carried out the plan, was not content with this, but under the influence of his destructive feelings, committed the murder, for which both were executed. Cast of head taken, after death, by Dr. N. B. Shurtleff.
3620. Henry Joseph, the "black cook," and murderer of Capt. Crosby. Executed in this city, Dec. 2d, 1834. Organs of self esteem, love of approbation, combativeness, and destructiveness, large. Taken by Dr. Shurtleff.
3621. † Cast of the skull of the same.
3622. † Madeline Albert. A young girl, of Moulines, in France, who, for some trifling provocation, killed her mother and two sisters with a hatchet; and afterward showed no contrition for the crime.
3623. Boutillier. Executed, in Paris, for murdering his mother, in order to obtain her titles and property. He afterward assumed a false name; but, being convicted of various robberies, he was sent to the galleys, and there recognized as the murderer of his mother. Dr. Gall says that "this head is remarkable for an extreme development of the organs, from which arise the worst propensities—(secreteness, acquisitiveness, and destructiveness); while, at the same time, the organs of intellect, and of their superior sentiments are deficient."
3624. Martin. Murderer of his father; and remarkable for

- his insubordination and extreme obstinacy. Firmness, self-esteem, acquisitiveness, and destructiveness, large.
3625. Brown. Executed at Providence, for highway robbery, in 1834.
3626. Amos Miner. Executed at the same time and place with Brown, for murder.
3627. † Walmsley. Executed in New York, for piracy, and in company with Gibbs, who was convicted of the same crime.
3628. Estirant, a St. Simonian. Disgusted with life, and committed suicide.
3629. Aingrain. Insane.
3630. Col. Nichols, as he was often called, of South Reading. Head taken by Dr. N. B. Shurtleff. Great self-esteem, and a remarkable memory for names and places; but could not take care of his property, and was generally regarded as half-witted.
- 3631-2. Heads, from the antique.
3633. * Pindar, from the antique.
- 3634-5. Head and brain, marked phrenologically. 1847.

Dr. J. C. Warren.

A P P E N D I X .

*SPECIMENS RECEIVED WHILST THE VOLUME WAS BEING PRINTED,
AND TOO LATE FOR INSERTION IN THEIR PROPER PLACE.*

3636. An articulated male skeleton, from Paris. 1869.

Museum Fund.

3637-8. Sword of a sword-fish, and cranium of the goose-fish (*Lophius Americanus*, Cuv.). Prepared by the late Dr. Geo. W. Swett, a graduate in the medical class of 1868. 1869.

3639. Non-union of the atlas upon the median line, anteriorly and posteriorly. 1869.

Mr. Horatio Bridge, med. student.

3640. Bifurcation to a slight degree, of each of the fourth ribs, at the anterior extremity. Each has two cartilages; and these unite upon the left side before they reach the sternum, but not upon the right side. An arterial and a muscular anomaly were also observed in the same subject. From the dissecting-room. 1870.

Mr. William J. Morton, med. student.

3641. A hand, of which the muscles have been fully dissected, and that has been prepared so that they retain their softness and flexibility; and, to a fair extent, their color. It was received by Dr. D. Jan. 15th, 1870, and two weeks after it had been amputated for caries of the wrist-joint. A saturated solution of the chloride of sodium, in pure glycerine was made without heat, and with a little of the chloride in excess. The hand having then been dissected, every part of it was very thoroughly washed with the solution, and it was then laid away for three or four weeks, in a cloth saturated with the same; the process being repeated more or less thoroughly once or twice, at intervals of

about a week, and the tendons being wet with pure glycerine if they became at all dry.

The above is one of several processes that are original with himself, and with which Dr. D. is now experimenting in the preparation of the soft parts. 1870.

Dr. Thomas Dwight, Jr.

3642. *Musculus sternalis*; flexible preparation by Dr. Beach. For a drawing of this specimen, see No. 255. 1869.

Dr. R. M. Hodges.

3643. A very highly finished and handsomely mounted drawing, in water colors, of a second specimen.

From a female dissecting-room subject, about fifty years of age. The muscle had no distinct tendon at the upper end, but blended with the superficial fascia, as at the lower end it blended with the sheath of the rectus muscle. It existed only upon one side. Dissected by Mr. Wm. P. Bolles; and drawn by him for Dr. H. 1869.

Dr. R. M. Hodges.

3644. *Ductus arteriosus* very largely open, in a kitten four months old. Both ventricles are thickened, and the left is seen to be immensely so; but there is no other malformation. The animal was always thin, feeble, indisposed to play, and died at last a natural death. Impulse of the heart regular, strong, and accompanied with a loud souffle. 1870.

Dr. M. S. Carpenter, of Mansfield.

3645. A drawing in water-colors, of a new-born child, and showing a black discoloration of the left upper extremity. From a photograph.

The mother was a half-witted, Irish girl, and nothing was known of her situation until shortly before her confinement. The case occurred in the practice of Dr. G. J. Arnold, of Roxbury. (*Med. Jour.* Vol. LXXIV. p. 371.)

The discoloration began not far above the wrist, and extended upwards as far as the neck, over the whole scapular region, and somewhat upon the chest. The color was an intensely dark-brown; and to a very considerable extent, and especially upon the arm, it was as black as the skin of the blackest negro. Upon the back of the elbow, only, the color was less intense. Where the color was the

darkest the surface was uneven, more or less nodulated, and felt, on pinching it up, thickened and quite firm. The margin between the discolored and natural skin was almost continuously of a light-brown color, quite definite in extent, generally about 2 lines, or more, in width; but upon the chest, and to a small extent, it was about two-thirds of an inch in width. About the top of the shoulder there was quite a development of soft hair. Upon the back of the pelvis, and left side of the trunk, there was a patch equal to an inch or more in diameter, as black as the above, and with hair upon the surface; also a patch upon the right thigh, about half as large. Over the trunk and limbs were scattered numerous spots, of a comparatively light-brown color, generally 2 lines, or more, in diameter, and that, individually, would have been called moles. Only one of these last was found upon the head, and that was upon the upper lip, and very pale. 1870.

Mr. W. P. Bolles, med. student.

3646. A second collection of double trout, recently hatched, and from the establishment, in Barnstable, already referred to (No. 903).

On comparing them together, the following varieties were observed: In one there were two heads and two tails, but the bodies are fused. — In six the two individuals were connected only by the umbilical vesicle. In one of these, one was very much atrophied, and the other largely developed; in another there was also a very considerable disproportion, and the same was observed, more or less, in some of the other varieties. In another specimen of the above variety, one was single, but had no eyes; the other divided anteriorly, and one head had two eyes, but the other had none. — One had two heads, with four eyes, but was otherwise single. — Six were united by the posterior portion of the body, or by the tails only, and otherwise separate or double. In one specimen one is very large, and the other much atrophied. In another specimen of the last variety, one head has two eyes, and a central one between them. In three other specimens of the same variety, one head has two eyes, and the other four. — In one specimen the body is single posteriorly, but with two cau-

dal fins; anteriorly, it is triple, and each of the three heads has two eyes. In another, of the same variety, one of the heads has one eye only. In another of the same the central head has two eyes; one of the others has a rudimentary eye, and the third has none. — In another variety the head and body are single, but the tail is double. — One specimen shows a very strong curvature, as was the case with several that were received with the first collection.

The different varieties are shown in separate tube phials.
1870. *Dr. A. Coolidge.*

3647. Three photographs of a man, already referred to (No. 909), in whom there is a third lower extremity, and the penis is double. Two of them were obtained by Dr. M., in Portugal, are much larger than the one already in the museum, and give a front and back view of the individual. The third, which is smaller than the other two, represents him as seated in a chair. 1869.

Dr. David Mack, Jr., Surgeon U. S. N.

3648. A piece of bone, removed from the cranium, by trephine; and connected with it a broken fragment, nearly as large as the thumb-nail.

From a man, æt. twenty-seven years, and who entered the hospital Aug. 13th, 1867 (77, 2), in a state of insensibility and collapse, with a contusion over the left temple, and a small punctured wound in the centre; the accident having probably happened during the previous night. On incision, a defined opening was found in the skull, with a discharge of brain. A piece of bone having then been removed by the trephine, there was found, after some examination of the part, the small fractured portion projecting inward, and hinged to the inner surface of the bone. At the time of the operation, and subsequently, there was much hemorrhage, with much discharge of brain, and much motion of the left lower extremity, but none of the right side of the body; and on the evening of the 15th the man died. — On dissection, an extensive effusion of blood was found into the membranes. 1869.

Dr. G. H. Gay.

3649. Cast of the forearm and hand, to show the appearances

in case of transverse fracture of both bones, just above the wrist-joint.

The patient was a man, fifty-two years of age, who entered the hospital Oct. 21st (141, 235). There were other serious injuries, and he remained until the 3d of Feb. The cast was taken, just before he left the hospital, by Mr. Henry T. Boutwell, one of the house-pupils; the deformity, at that time, being of course, much less than at first. 1870.

Dr. H. J. Bigelow.

3650. Fracture of the neck of the femur, with inversion.

The following history of this case, with remarks upon it, is from Dr. Bigelow's work of Dislocation and Fracture of the Hip (1869):—

“This accident is of rare occurrence. Smith and Hamilton each cite but one case. Indeed, the structure of the bone, as has been shown, is such as to insure an almost uniform eversion of the shaft. A specimen from a dissecting room has enabled me to examine this rare lesion, and to identify the conditions under which it probably occurred. In this subject, an old woman, the limb was flexed a little, shortened to the extent of 3 in., and inverted so that the patella faced inward; the limb was in slight abduction, and could be neither everted nor brought to the median line. The trochanter was felt to be much thickened. Upon examination of this exceptional specimen, the neck of the bone was found to be firmly united at right angles with the shaft, which was split open, and spread so widely as to receive the whole impacted neck, leaving a fissure an inch or more long, and a quarter of an inch wide between the anterior wall and the neck, and extending nearly to the outer wall of the shaft, while another similar fissure exists behind the neck. The principal posterior fragment comprised the two trochanters, with the intertrochanteric ridge, and also a large fragment of the external portion of the shaft,—while above, the region of the great trochanter seemed to have been comminuted, and driven downward and inward. Anteriorly, the fracture had occurred, as usual in impacted fracture, along the oblique spiral line, although differing from that injury; the neck being deeply driven in behind this wall, from which it had slipped,

instead of turning upon it as a hinge. The whole upper part of the bone, above the trochanter minor, seemed to have been bent inward, so that the posterior intertrochanteric line, instead of inclining obliquely to the axis of the shaft, was vertical. The inversion was due to the extent of the comminution, which had separated the walls of the shaft so as to receive in the interval the whole neck, instead of the posterior wall only, as commonly occurs, thus producing an anterior as well as a posterior impaction. The shortening resulted both from the horizontal position of the neck, and from an additional upward displacement of the shaft, caused by the comminution. A good deal of callus had been thrown out in various directions, and the movements of the limb must have been quite restricted. A curious spicula stood at right angles with the shaft, near the lesser trochanter, and may have been a displaced fragment, or the ossified insertion of the psoas tendon. The same bony spicula exists in another specimen before me, and is not uncommon.

“In examining the accompanying illustrations (of which there are two), it will be seen that the intertrochanteric ridge is split off, as often happens, but in this it has carried with it the outer and posterior walls of the shaft, with the two trochanters.

“Smith (Treatise on Fractures, etc., Dublin) cites a similar case of inversion (Case XLVI.), which the accompanying figure shows to have resulted from a similar cause. The posterior intertrochanteric ridge, with the greater part of the two trochanters, has been detached in a mass, and so widely that the neck of the bone has slipped from its anterior hinge. In both specimens the impaction is arrested near the outer wall of the shaft. The entire neck in my specimen can be seen through the lateral fissures, while in that of Smith its extremity is detected through an interval of the fragments, near the great trochanter. A similar specimen, numbered 248, in the Mütter Museum in Philadelphia, shows neither inversion nor eversion.” 1870.

Dr. H. J. Bigelow.

3651. Fracture of the neck of the femur, within the capsule. The neck is almost entirely absorbed, and the head is con-

nected with the shaft just above the small trochanter, by fibrous bands, $\frac{1}{3}$ in. or more in length. Specimen dried.

From an old man, seventy-five years of age, who fell down two steps on the 9th of Nov., 1858. On the following Christmas he could go from one room to another; and he was afterwards able to walk an eighth of a mile, with the aid of two canes, and until he lost his eyesight. Limb shortened about $2\frac{1}{2}$ in. Death occurred in May, 1869. 1870.

Dr. E. D. Miller, of Dorchester.

3652. A patella, fractured transversely, and very closely united by fibrous tissue. — From a gentleman, fifty-three years of age. When nine years old he was thrown from a wagon, and struck his patella upon a stone with great violence. The knee was always perfectly stiff, and appeared, after death, to be completely ankylosed. 1870.

Dr. William Ingalls.

3653. Nearly one-half of the outer portion of the right astragalus, broken off vertically, and removed.

From a man, thirty years of age, who was thrown from a wagon in Dec., 1857. When Dr. G. saw him, there were pain and swelling about the ankle, with slight crepitus. The foot was bent forcibly inwards, as in varus, and the toes pointed downwards; depression over the dorsum of the foot; and over the external malleolus an opening of the size of a pea, from which blood issued. The lower end of the tibia was broken, but the fibula was uninjured. In front of the lower end of the tibia, anteriorly, there was felt to be a cavity, and about over the cuboid bone was felt the displaced portion of astragalus; the integuments being stretched and thin.

The bone was at once removed; and though he had, within a fortnight, two attacks of inflammation, that went on to suppuration, he finally did well, and has for some years moved about as freely as any man. 1869.

Dr. G. H. Gay.

3654. A portion of the pelvis, with the upper part of the femur, from a case of old dislocation into the foramen ovale.

From a man, who fell from a great height, whilst intoxicated, and was subsequently under the care of Dr. A. B.

Bancroft, of Chelsea. About three months after the accident Dr. Gay saw the patient, and found the thigh flexed, the knee flexed, abducted and everted, and the limb lengthened at least 2 in. The great trochanter was depressed, with a hollowing in that region; and there was a visible roundness between the perineum and the small trochanter, with tension of the muscles of the inner and upper part of the thigh. The reduction was effected with much difficulty; the knee springing up a little, on pressure downwards, after the operation, and the limb being lengthened about half an inch. After the operation the bone was not kept in place; and a few weeks afterward the man died with a large abscess upon the back of the hip and thigh.

. The parts having been removed, entire, were brought to Dr. B. for examination. The head of the femur lay behind the acetabulum, and upon the pyriformis muscle. The obturator int. was lacerated, and had about disappeared. When the head of the bone was placed in the thyroid foramen, it was beneath some of the fibres of the obturator ext., and also beneath the pectineus. The inner band of the Y ligament remained, with a small portion of the external band, and was very much thickened; and, otherwise, the whole capsular ligament was torn through, so that only shreds of it were to be seen. The ligamentum teres had disappeared; the whole inner surface of the acetabulum was more or less abraded, and the lower margin was in a great measure destroyed. One third or more of the head of the femur is also destroyed as by caries, and the remainder of the articular surface is smooth, but entirely denuded of cartilage. The indications of an attempt to form a new socket are very marked; there being a very thick mass of fibrous tissue, with some ossific deposit along most of the margin of the thyroid foramen, toward the rami of the pubes and ischium, and some rough ossific deposit upon the body of this last, with more or less of the same elsewhere. There is no deposit of new bone, however, upon the head or neck of the femur. Upon the dorsum of the ilium, and where the head rested, the

surface of the bone is slightly roughened. — Specimen in spirit, and prepared by Dr. H. H. A. Beach. 1870.

Dr. H. J. Bigelow.

3655. A large portion of the calvaria, very curiously and extensively eroded upon both surfaces, and, to more or less extent in different parts, continuously. At some points the bone is perforated. Very little proper caries; no thickening, and nowhere any deposit of new bone. The dura mater was somewhat adherent, but there was no other disease. 1869.

Dr. H. H. A. Beach.

3656. A portion of the spine, showing extensive caries of the two last dorsal, and two first lumbar vertebræ; from a case of aneurism. (Hospital, 287, 33.) Dissected by Mr. James J. Putnam, one of the house-pupils; and prepared by Dr. T. Dwight, Jr., to show the prominence of the intervertebral substances, with very little shrinking. 1870.

Dr. F. Minot.

3657. The humerus in two portions, with extensive caries, and necrosis of the lower portion.

From a man, æt. twenty-six years, who entered the hospital July 15th, 1858 (79, 168), with a large abscess about the shoulder. Five weeks before, after working hard, he was attacked with constitutional symptoms, and inflammation followed. He had had an abscess in the same part five years before, but no further trouble from it after it had discharged. On the 17th an opening was made, and the discharge was profuse. On the 20th pain came on about the elbow, and became afterwards excruciating, with swelling. Aug. 6th a deep incision was made; very offensive pus was discharged, and the bone was felt entirely denuded as far as the finger could reach. On the 26th, the bone gave way; and on the 28th the limb was removed at the shoulder joint. The hemorrhage was considerable; but the man did well, and was discharged on the 27th of October.

The upper fragment is $7\frac{1}{2}$ in. in length, extensively absorbed towards its lower extremity, rough from caries, and tapering almost to a point. Otherwise it is irregular upon the surface, with numerous large pores, but without

much caries, though an opening of some size leads into the interior of the bone, which looks hollowed out as if by the abscess. The head of the bone is sufficiently healthy. The lower fragment is $4\frac{3}{4}$ in. in length, and a large portion of it is exfoliating, though still firmly connected. Surface of the dead portion partly quite smooth and unchanged, but partly porous as from preliminary inflammation. Articular surface, and the bone just above the joint, extensively carious. 1869. *Dr. G. H. Gay.*

3658. Disease of the radius. — The bone, midway, is very much enlarged, rough upon the surface, and shows several openings that communicate with a central cavity, in which is a sequestrum that must be about 3 in. in length. The enlargement is fusiform, and the whole bone is more or less enlarged, excepting the very upper extremity. The ulna and lower part of the humerus are healthy; but Dr. L. found some disease of the carpal bones.

From a healthy man, fifty-five years of age, who in February, 1868, had a very severe attack of inflammation of, or about, the bone. In May, Dr. L. saw him, and opened the parts freely, with great relief; but extensive necrosis took place. In December, 1869, there was a very copious hemorrhage, and on the 20th the limb was amputated above the elbow. On examination, it was found greatly swollen, and infiltrated with serum and blood; and near the wrist the radial artery had been completely severed by the sharp and pointed extremity of the sequestrum. Result successful. 1870. *Dr. G. H. Lyman.*

3659. About $1\frac{3}{4}$ in. of the upper extremity of the femur, removed during life. Head of the bone nearly destroyed by caries; surface rough, as is the neck in part. Structure very light; no new growth.

From a delicate little boy, nine years old, who entered the hospital April 22d, 1857 (75, 95). Duration of disease three years; and abscesses the last eight months. Limb drawn up and flexed, and extension gave great pain. Oct. 26th, shortening about 3 in.; several extensive fistulæ; and the head of the bone was felt denuded. The general

health, however, was better. Oct. 31st the bone was removed, and on the 16th of Nov. the boy died. 1869.

Dr. G. H. Gay.

3660. Photograph of a little girl, seven years of age, and showing the thigh bent to a right angle, the effects of hip disease.

When Dr. B. saw her last November, there seemed to be ankylosis; but, under ether, there was just a perceptible motion. The disease began about four and a half years before. For about two years it was active, and afterward a subsidence, so that there had been no pain for several months, and she was able to go about on crutches. General health always delicate. The rectus, tensor vaginae femoris, sartorius and adductor longus were divided, and immediately afterward the adhesions were broken down, so that the angle of flexion was reduced to about 45° ; and this was the only operation that was performed. For the next two or three months an apparatus was kept applied; and, at the end of that time, the limb was perfectly straight. For some weeks past (April 12th) she has been able to walk without either crutch or cane, and there is considerable motion in the joint.

Photograph of the above case, after treatment; and in this figure, as well as in the last, the dress has been removed so as to show the exact condition of the limb. 1870.

Dr. Buckminster Brown.

3661. A sequestrum, from a femur, that had been amputated; 9 in. in length, and involving a large part of the circumference of the bone. 1869.

Dr. G. H. Gay.

3662. Excision of the knee-joint; the patella adhering to the outer condyle. — The patient, æt. eleven years, entered the hospital Aug. 23d (142, 13). Duration of disease one year; and knee bent to an angle of about 45° . Operation Oct. 20th; followed by incessant vomiting, and death in about forty-eight hours. The whole joint was perfectly disorganized. 1869.

Dr. G. H. Gay.

3663. One of the small cuneiform bones from the foot, that is extensively and deeply carious; and, being perfectly loose, was readily picked out. The disease, which was chronic,

was confined to this bone; and the patient (a man in the hospital) was at once relieved. 1869.

Dr. G. H. Gay.

3664. Portion of the rib of an ox, from Texas; with a hole through it, about $2\frac{1}{2}$ in. by 1 in. in extent. Outline regular, and no appearance of a former injury. 1870.

Dr. J. Wyman.

3665. A portion of the lower jaw, removed for what was supposed, before the operation, to be an encephaloid disease.

From a woman, æt. sixty years, who entered the hospital Nov. 29th, 1856 (73, 200). When eighteen years old she had a disease of the jaw; a fungoid mass as large as a hen's egg was removed, and the bone was scraped. From that time she had no further trouble until Jan. 1st, 1856, when she felt a sudden snap or tearing sensation along the under and posterior surface of the chin. In a day or two a small tumor appeared, and became as hard as bone; and in August it appeared in the mouth.

On examination, a rounded and very defined tumor was found in the place of the incisor teeth, of a deep red color, exquisitely tender, and looking like an abscess that was ready to burst. Externally, there was a slight fulness; and the tumor appeared behind the jaw, but not in front. On being opened, it discharged blood very freely, but nothing more. The bone was then (29th) removed between the canine and bicuspid teeth, on each side, and the hemorrhage was profuse; but on the 16th of Dec. the patient left the hospital, and several years afterwards, when she was heard from, nothing was said of any return of the disease.

The bone is enlarged upon each side of the median line, and looks as if it had been absorbed by a tumor that had formed in its substance. A large cavity is the result, of which the inner surface is irregular, but well defined, and of good consistence. Superiorly, it is uncovered; lateral parietes thin, and to a large extent deficient; base thin, and below it is a second cavity, of considerable size, and almost but not quite opening into the one above. Beyond

the disease the bone looks quite healthy; and there is nowhere any new deposit. 1869. *Dr. G. H. Gay.*

3666. A hollow shell of bone, about the size of an English walnut, and that enclosed a tumor, that was removed from the upper jaw. The parietes are very thin, deficient to a considerable extent, and for the most part coarsely cribriform. Structure compact.

The patient was a perfectly healthy man, forty-five years of age, and entered the hospital March 25th, 1857 (75, 74). Tumor upon the outside of the gum, and above the first upper bicuspid tooth; well defined, smooth, rounded, hard and painless. It had existed for two and a half years, "felt like gristle," and enlarged very slowly. About six weeks before entrance, on exposure to a cold wind, he felt a sharp pain in it, and four teeth were removed, but without relief. On the day of his admission the tumor was removed; in two weeks he left the hospital, and he now (1870) reports that he has never had any return of the disease. The tumor was regarded as fibro-plastic. 1869.

Dr. G. H. Gay.

3667. The lower $6\frac{1}{2}$ in. of the femur, that looks as if it had been surrounded by some malignant growth, to the extent of about 5 in. The surface is rough, and superficially absorbed; and to some extent posteriorly there is the short, bristly growth, perpendicular to the surface, that is so often seen in malignant disease. Above and below the seat of disease there is a periosteal deposit, that is raised from the surface, as if it had been continued over some morbid growth; and to a considerable extent the bony fibres are arranged with great regularity perpendicular to the surface of the bone, as those are that arise from the bone itself. 1869.

Dr. G. H. Gay.

3668. Cast of an amputation at the right ankle-joint, performed by the method of M. Soupart (*A. Guerin. Elements de Chirurgie Operatoire*, fig. 105; 3d ed. Paris, 1864).

The patient was forty years old; and the operation was performed for an incurable ulcer of the foot, of eleven years' duration. Cast taken eight weeks after the opera-

tion. In a case already reported (No. 1626) the same amputation had been performed. 1870.

Dr. R. M. Hodges.

3669. A portion of the heart, showing a clot adherent to the mitral valve, and that was the cause of instantaneous death.

From a woman, æt. fifty-eight years, who was recovering from a mild attack of pneumonia, and had had no cardiac affection previously, so far as known. She awoke in the night, and apparently as well as she had been; asked what o'clock it was, and died instantly.

The clot was about as large as the top of the thumb; and acted, as Dr. E. thought, like a ball valve, to prevent the passage of the blood. It had evidently formed before death, though only recently; surface partially decolorized, and the interior, on incision, resembled the lees of red wine. The mitral valve was somewhat diseased; but the heart was otherwise healthy; and the lungs, though not hepatized, showed that they had been inflamed. 1870.

Dr. C. Ellis.

3670. A large mass of a white, dryish, crumbling material, and partly cretaceous, in the place of the bronchial glands. Cut open and dried; with a portion of the trachea and bronchi. From a woman who had disease of the heart. 1869.

Dr. H. H. A. Beach.

3671. Photograph of a case of elephantiasis Arabum, for which amputation was performed by Dr. S., at the junction of the middle and upper thirds of the thigh.

The patient was a woman, fifty years of age, and the disease had been coming on for a little more than six years; having commenced with an attack of erysipelas in the foot, after working very hard in a damp cellar. There was ulceration upon the inside of the leg, with a watery discharge; and last July a large abscess formed upon the upper part of the leg, that nearly proved fatal. The limb was generally much congested, and very sensitive, so that opiates were required. At the time of the operation, which was done at the request of the patient, the ankle measured 2 ft. 1½ in. in circumference; the calf of the

leg, 3 ft. 1½ in.; two inches above the knee, 3½ ft., and at the line of amputation, 2½ ft. Weight of the limb after removal, 100 lbs. Very little blood was lost, and the operation was well borne; but soon after the woman was placed in bed, a sudden pallor came over her, and she died in an instant.

Dr. J. Collins Warren, of this city, examined a portion of the fresh tissue, and found the cutis vera and subcutaneous tissue blended and very much thickened by a dense fibrous tissue, that seemed to arise from the outer coats of the blood-vessels, which were very numerous and large. There were also vessels that appeared like enlarged lymphatics. The papillæ were much enlarged, but the hair follicles and sebaceous glands were not seen; and there were only traces of the sweat glands, with one duct, so far as seen.

The case will be published, in full, by Dr. S., in the *Amer. Jour. of Med. Sciences.* 1870.

Dr. Isaac Smith, Jr., of Fall River.

3672. The trachea dried, and showing a piece of bone, as large as the top of the little finger, impacted in the right primary bronchus.

The patient was a farmer, sixty-seven years of age, and quite healthy, though with an occasional cough. On the 14th of February he suddenly choked whilst eating, and coughed violently. Through the day the cough was almost incessant, and it continued more or less so as long as he lived; being much worse when lying down, and less during the day. Breathing short, difficult, and rattling; but he did his usual work, and, on the 27th, walked to church and back, — a distance of two miles. On the 2d of March he gave up his work, and on the 6th he died. Dr. A. saw him on the afternoon of the 5th, and found him in a state of approaching collapse, and with dyspnoea, but no hoarseness. Over the whole of the right side there were subcrepitant râles, except below the scapula, where the air did not seem to enter; and over the whole right back there was dulness on percussion. — On dissection, there were found quite a number of small tubercular-looking deposits in the right lung, and most of them softened; but, as there was

nothing of the kind in the left lung, the disease may have been recent, and connected with the obstruction in the bronchus, as in the cases described by Dr. Ellis. (Med. Jour. Vol. LV. p. 356.) 1870.

Dr. Z. B. Adams, of Framingham.

3673. A stone from the stomach of a fish, that was taken in a harbor on the west coast of Mexico. Its length is 12 in., its greatest width 6 in., and its thickness, $2\frac{1}{2}$ in.; weight, 6 lbs. 14 oz. (avoir.) Surface generally smooth, but to a considerable extent and deeply eroded by shell-fish. The fish was taken about the year 1854, on board the U. S. Ship Portsmouth, and "was about 4 ft. long, stout and thick, with small teeth, and scales as large as the thumbnail; name not known." Dr. B. did not see the fish opened, but the stone was brought to him as soon as it was removed. The condition of the stomach was not observed. To explain the fact Dr. B. states that the stones upon the shelving coast, where the fish was taken, were covered with soft star-fishes, and the stone was probably swallowed with the food. 1870.

Isaac Brinckerhoff, M. D., Surgeon U. S. N.

3674. Photograph of a child, æt. three years and three months, showing the abdomen immensely distended, and with great general emaciation. — The enlargement was first noticed last June, and it died in February. There was no pain, and no vomiting nor loss of appetite until the last few days.

On dissection, a defined, rounded tumor was found, that weighed 15 lbs. Upon the surface a considerable portion of one of the kidneys was seen, and from this organ the morbid growth seemed to have originated; the organ, so far as it appeared, being perfectly healthy, but soon entirely lost in the tumor. The structure of this last varied in different parts, but it generally had a cancerous appearance, and in some parts this was strongly marked. Microscopically, however, there was some difference of opinion. (Med. Jour., April 7th, 1870.) 1870.

Dr. Charles Goodwin, of Wakefield.

3675. A large, rounded, urinary calculus, nearly covered with

very prominent and pointed groups of small nodules, and removed by the lateral operation, by Dr. Bigelow. It measures about 2 in. by $1\frac{3}{4}$ in., and weighed $43\frac{1}{2}$ dwts., — nearly $2\frac{1}{2}$ oz. avoird. On section, an oval nucleus is seen, $\frac{5}{8}$ in. in length, and with regular, concentric laminæ. The rest is also laminated, but the lines are very irregular and wavy, as in the mulberry calculus. The color is a reddish brown, the structure compact, and the internal surface of one-half has been polished.

Dr. White reports the chemical composition as follows: "Nucleus and greater portion of bulk, uric acid. Oxalate of lime the greater proportion of external layers, and to some extent throughout body of calculus." A thin and comparatively light-colored deposit over a large part of the external surface also consists of uric acid and oxalate of lime.

The patient was a healthy old man, about seventy-three years of age. For three or four years he had had some urinary symptoms, and for the last few months they had increased so that, as his wife finally said, he would die from his pain if he was not relieved. On passing the sound, Dr. B. recognized a mulberry calculus, by the hardness and the asperities upon the surface; but it was only felt when the point of the instrument was brought into contact with the anterior parietes of the bladder. The stone was removed, by the lateral operation, about the last of March, and the patient died, from the shock to his system, in eighteen hours. Examination of the body not allowed.

Upon the surface of the stone is a pretty well defined annular depression, that divides it into nearly two equal parts, and of which one was probably contained within a pouch, whilst the groove was formed by its neck. As the stone was so very rough, Dr. B. thought the acute symptoms would have been of longer duration, if it had been free in the bladder. 1870.

Dr. H. J. Bigelow.

3676. A calculus, removed by the lateral operation. It is of a regular, elongated form, $1\frac{1}{4}$ in. in length, and $\frac{3}{4}$ in. in diameter. On section, the structure is mainly laminated and

compact; but upon more than one-half of the surface there is an addition of a coarse deposit, not laminated, quite defined, and varying from about $\frac{1}{8}$ to $\frac{1}{4}$ in. in thickness. Dr. White finds the body of the stone to consist of uric acid and ur. of ammonia, with a little ox. and phosph. of lime. The outgrowth consists of carb. and phosph. of lime, with triple phosph. of ammonia and magnesia. The external surface is rough or granulated, corresponding to the outgrowth, and the rest is smooth.

The patient was a little boy, six years old, who was sent to the hospital Feb. 23d, from an almshouse in the country, with club foot (142, 121). March 19th it was reported that from the time of admission he had wet his bed in the night; and a woman who brought him to the hospital stated that he had had the same trouble so long as he had been at the almshouse. Urine passed frequently, with considerable pain, and sometimes it stopped; turbid in appearance, and contained pus, with the triple phosphate. On the 27th the calculus was felt, and on the 30th it was removed. April 13th: since the operation the urine has passed almost wholly through the wound, but since yesterday almost wholly by the urethra. 29th: the child is in every way doing well. 1870. *Dr. R. M. Hodges.*

3677. A prolapsed uterus, of which casts have been taken. (No. 2736.) It has been prepared by Dr. B., according to the method of M. Van Vetter, of Boulogne, and seems likely to retain its natural suppleness, and without decomposition.

The organ having been drawn up so as to fairly expose the fundus and body, a probe is found to enter about 5 in. from the os, and shows that there is elongation as well as prolapse. The relations of the organ to the bladder, and also to the peritoneum, anteriorly and posteriorly, are perfectly represented in one of Cruveilhier's figures (*Anat. Path.* Liv. xvi. pl. 4); and a considerable portion of each of the peritoneal protrusions, and also of the bladder, would have been removed, if a transverse incision had been made directly through the upper part of what would generally have been called the prolapsed uterus. There

seem to be two small fibroid tumors of the womb, but they are probably of no account.

The preparation above referred to, consists of glycerine 7 oz., brown sugar 1 oz., and nitrate of potash $\frac{1}{2}$ oz.; but, as Dr. B. finds that the specimen is liable to mould, he adds of pure carbolic acid, ʒij . The specimen is saturated with this preparation for ten or fourteen days, and then hung up to drip in a loosely covered jar, and in a warm and dry place. 1870. *Dr. H. H. A. Beach.*

3678. Cast of the thumb, showing an enchondromatous tumor in front of the last phalanx, and about the size of a large nutmeg. — The patient was a woman, twenty-five years of age, who entered the hospital Jan. 7th (143, 112). Tumor of two and a half years' duration; of a regular, rounded form, translucent, soft, though not fluctuating, painless, and only interfering mechanically with the motion of the joint. Growth slow at first, but more rapid the last year. It was very easily removed by Dr. Cabot, and the patient left on the 13th, with the wound nearly healed. — Cast taken by Mr. T., one of the house-pupils. 1870. *Mr. Frederick H. Thompson, med. student.*

3679. Eight and a half inches of the humerus, removed at the shoulder-joint, for neuralgia.

The patient was an active and powerful man, seventy-one years of age, and served as an artillerist in the Civil War. In 1864 his hand was severely injured by the premature discharge of a cannon, and was amputated at the wrist-joint. Subsequently the forearm was amputated twice, and the arm twice, for the intense and almost constant pain that he suffered, not in the limb that remained, but in the hand and fingers that had been removed; eight or nine grains of morphine being injected subcutaneously and daily, before Dr. H.'s operation, — and the left arm being scarred from the deltoid to the wrist. Since the last amputation of the arm, the nerves, also, had been dissected out from near the deltoid attachment; and, on dissection of the stump, since the last operation, the only nerve that Dr. H. could find, was the musculo-spiral. About a year after the first operation the humerus was

fractured ; and Dr. H. supposed that some nervous filament may have been involved between the fragments, and been the cause of the neuralgia. After the fracture, also, there appeared a pulsating tumor below the clavicle. Dr. H. found it to be ill defined, not far from the size of a small lemon, and situated beneath the pectoral muscle, but not rising above the clavicle. He regarded it as an aneurism, and thought that it might perhaps explain the pain. On the 5th of April he removed the stump, according to Baron Larrey's method. Twenty ligatures were required ; the wound was washed with alcohol, and dressed with dry charpie. Hardly a drachm of pus was formed, and on the sixth day the edges of the wound had united, except where the ligatures hung out. On the day after the operation, seven grains of morphine were required for the pain, and taken by the mouth ; afterwards only one grain daily, and rather from habit than on account of pain ; and at the end of three weeks there had been no return of this last. The aneurism, meanwhile, has diminished in size and pulsation.

Dr. H. having sawed the bone lengthwise, there is seen to be a very marked interstitial atrophy ; the parietes being very thin, and the cavity closed by a light cancellated structure. The fracture has united regularly, though not exactly in line. 1870. *Dr. J. Homans.*

3680. Ossified crystalline lens.

The patient, a girl, eighteen years old, was hit in the eye, with a stick, four years ago. For the first two years there was much pain, with failure of vision ; and, at the end of that time she had lost all perception of light. The pain, however, then subsided, and she had not much afterwards, until a short time previous to the operation. For a year past the lens had been opaque, and seemed to be in the anterior chamber ; with occasional inflammation of the eye.

When seen at the City Hospital, on the 25th of March, by Dr. W., the cornea was somewhat cloudy, and the size and tension of the globe a little diminished ; iris atrophied ; lens in the anterior chamber, and evidently hardened

and shrunken. Immediate removal advised, to obviate danger to the other eye from sympathetic inflammation, in case it should become displaced, and irritate the ciliary nerves.

After section of the lower part of the cornea, an attempt was made to grasp the lens; but it slipped into the posterior chamber, and disappeared in the softened vitreous humor, rendering it necessary to search for it with a curette. Upon removal, it was found completely cretaceous, and diminished in size about one-third.

After the operation the incision in the cornea closed at once, and without any increased opacity; the globe retained its size, notwithstanding a discharge of some of the vitreous humor, and the girl went home in a few days.

The contrast between this cretaceous transformation, to which the lens is liable, and a true bony growth that may form in the bottom of the globe, as shown in No. 2046, is very striking. 1870. *Dr. H. W. Williams.*

THE FOLLOWING CASE WAS ACCIDENTALLY OMITTED:—

3681. Deep and extensive excavation in the tibia.

The patient was a feeble man, sixty years of age, and entered the hospital Dec. 2d, 1866 (127, 222). When a boy, and without known cause, there came on a swelling over both tibiæ, followed by abscesses, and there had been a discharge ever since, with an occasional discharge of small pieces of bone. For the last five years he had done no work, as his health failed. One year before admission the skin over the right leg became red and tense; an ulcer soon formed, and in a few months there sprang up from its surface an exuberant and rapidly increasing growth. When seen, it had a spongy and vascular look, and was elevated $1\frac{1}{2}$ in. — overlapping the base, and measuring in extent 6 by 3 in. The limb was amputated by Dr. H. below the knee Dec. 8th; and the patient, sinking from inflammation of the stump, and increased trouble in the other leg, died Jan. 10th.

The outgrowth, which was not regarded as malignant,

and showed no such appearances microscopically, was easily torn from its attachments, and left a rather defined cavity in the upper, anterior part of the bone, 5 in. in length, and involving almost its whole width and depth. The affected surface is rough, but the structure is generally sufficiently compact; and, otherwise, the bone is but little affected. 1867.

Dr. R. M. Hodges.

INDEX.

- Abscess.** Integument, 392; bone, 233; psoas and lumbar, 258; breast, 604; brain, 382; lung, 433; liver, 499, 500; prostate, 616.
- Acephalus**, 86.
- Acephalous fetus**, 89-96, 99.
- Acromion process.** Non-union, 21, 22.
- Addison's disease**, 395; renal capsules, 681-3.
- Air-passages.** Healthy, 59-60; croup, 427; diphtheria, 427; bronchial polypi, 428; inflammation, 427-9; tubercular disease, 429-30; glanders, 430; syphilis, 430; polypoid growths, 430, 431; foreign bodies, 424-6, 743; parasites, 424.
- Albino**, 50.
- Amputation.** Shoulder-joint, 162; hand, partial, 177; finger, by a ring, 320; hip-joint, 299, 194; knee-joint, 270, 226; foot, 320, 321; foot, Soupart's operation, 321, 741; stump, 313, 314, 316, 389.
- Anchylosis.** Spine, 248, 249; elbow, 263; carpus, 264; hip, 268, 269, knee, 274-6, 218, 246; ankle, 280; tarsus, 277, 280; fleshy, — hip, 269, 739, — knee, 333, 334, — treatment, 269, 739.
- Aneurism.** Heart, 345, 346; aorta, 355-62; primary branches of aorta, 363, 364, 368; splenic artery, 367, 368; at elbow, 365, 366; at groin, 368, 369; popliteal artery, 366, 370; dissecting aneurism, 351, 355; traumatic, 363; varicose, 370; exciting causes, 356, 366; heart healthy, 359; arteries obliterated, 361; bones carious, 260; lumbago in abdominal aneurism, 363; cure, 363, 366.
- Aorta.** Laceration, 347; dilatation, 351. See *Aneurism*.
- Antrum.** Tooth from, 56; tumors, 651, 671.
- Appendices epiploicæ**, 492.
- Appendix cæci.** Development, 63; intestine strangulated by, 470; foreign bodies, 490; typhlo-enteritis, 475, 476.
- Arteries.** Distribution, 29-36; anomalies, 40-3, 730, 347, 113; rupture, 366. See *Aneurism, dissecting*. Wounded by sequestrum, 738; ligature, 347, 348, 366; fibrinous clots, 349; varicose arterial tumor, 371; structural disease, 350, 351.
- Arthritis chronic.** Vertebrae, 248, 249; shoulder, 249, elbow, 249-50; wrist, 252; hip, 250, 252; knee, 252; tarsus, 253.
- Atrophy.** Bones, 305, 306; kidneys, 523.

Biliary calculi, 504-516; fused, 510; fill the gall-bladder, 504, 505; tumor, 511; from the intestine, 508, 509; discharged from the umbilicus, 515.

Blind-fish, 52.

Boils, 392; melanosis, developed from, 408.

Bone. Abnormal development, 574, 409, 367.

Bones. Healthy, 1-24, 729; malformation, 17-24, 729; fractures, 141-206, 732-5; separation, without fracture, 199, 177, 160, 145; incised wounds, 145, 700, 195; dislocation, 206-14, 735.

Bones diseased, 214-318, 737-41; inflammation, 214, 215, 217, 737; osteo-myelitis, 233; chronic inflammation, 214, 218-23, 738; unhealthy inflammation, 223, 224, 226, 227; abscess, remains of, 233-5; old ulcer, effects of, 222; fistula, 234; periosteal growth, 227-30, 264; deformity, 307-12; yielding to pressure, 312, 635, 418; eburnation, 252; syphilis, 285, 286, 392; cyst, 286; enchondroma, 288, 653-9; myeloid, 286; malignant disease, 288-305, 741; growth around tumors, 740, 741. See *Caries*, *Necrosis*, *Anchylosis*, and *Exostosis*.

Brain healthy, 45. See *Monstrosities* and *Idiots*. Wound, 145, 149, 381, 684, 685, 688; apoplexy, 381; inflammation, 381, 382; chronic abscess, 382.

Breast, female. Inflammation, 604; inflammation of nipple, 604; epithelial disease, 604; encysted disease, 605, 606; glandular hypertrophy, 605, 607; cretaceous formation, 606; malignant disease, 608, 609.

Breast, male. Development, 76; morbid enlargement, 621; malignant disease, 622.

Bronchial glands. Tubercular, 377; opening into bronchus, 377; opening into oesophagus, 377.

Bronchial polyp, 428.

Burn, 392; cicatrix, 393, 394.

Bursal disease, 328-31.

Calculi. Urinary, 533-72, 744, 745; renal, 572; in ureter, 521; urethral, 572; prostatic, 617; salivary, 420, 421; intestinal, 489, 490; biliary, 504-16.

Capsular ligament. In dislocation, 735; ossified, 250.

Carbuncle, 392, 393.

Caries, 230, 231; spine, 253-9; elbow-joint, 260, 261; hip-joint, 265-7; knee-joint, 231, 232, 270-4; ankle-joint, 276; tarsus, 233; from aneurism, 260.

Cartilage. Costal, fractured, 318; thyroid, fractured, 426; absorption, 206, 735, 276, 333; of Meckel, 54.

"*Cattle disease*," 434, 437.

Cheloides, 403-404.

Cicatrix. Surface of body, 393; from burn, 393, 394; dissected out, 394; growth of horn from, 398.

Club-foot, 322-328.

Colloid disease. Bone, 287; stomach, 457; omentum, 493.

Contusion, 391.

Croup, 427.

Cysticercus, 675; from the hog, 328.

- Decidua.* Uterus, gravid, 80; uterus, not gravid, 598; decidua reflexa, 81.
- Diaphragm.* Imperfect development, 98, 113, 498; cadaveric softening, 443; laceration, 319.
- Diphtheria*, 427.
- Dislocation.* Vertebrae, 206, 207; shoulder, 207-9; elbow, 209; carpus, 210; hip, 211, 212, 735, 268, 250; hip, foetal, 94; patella, 212; knee, 212; knee, foetal, 94; foot, 213.
- Diverticulum*, 64, 65; tubercular ulcers, 480.
- Ductus venosus.* Termination, 29.
- Duodenum.* Malformation, 104; ulcer, 477, 488; opening from gall-bladder, 506, 507.
- Dysentery*, 473.
- Ear.* Polypus, 413; caries, 230.
- Echinococcus*, 435, 503.
- Eioides*, 670.
- Electrical eel*, 54.
- Elephantiasis.* Lower extremity, 400, 401, 742; upper extremity, 401; scrotum, 401; external female genital organs, 603; face, 401.
- Emphysema.* Pulmonary, 432; beneath sternum, 390; beneath peritoncum, 492.
- Empyema*, 436.
- Encephalocele*, 99-101.
- Enchondroma*, 653-63, 288, 747.
- Epiglottis destroyed*, 429.
- Epilepsy.* Trephined for, 156-8.
- Epiphyses.* Separation by violence, 199; separation by inflammation, 215.
- Episternal bones*, 30.
- Excision.* Humerus, upper portion, 162; elbow, for injury, 170, 172, 173; elbow, for disease, 261, 262; thumb, articulation, 177; femur, upper portion, 265, 738; knee, 271-4, 739; knee, subsequent union, 271; tibia, portion of shaft, 200; ankle-joint, 279; tarsal bones, 277-8.
- Exostosis*, 280-5.
- Extremities.* Deficiency of development, 110-114; excess of development, 136-9.
- Extroversion of bladder*, 108.
- Eye.* Healthy, 51; blind-fish, 52; after long blindness, 413; protrusion, 409; lens cretaceous, 748; bony growth from globe, 409; non-malignant disease, 410; malignant disease, 411-13.
- Fallopian tubes.* Rupture, 580; dropsy, 581; tubercular disease, 581; adhesions, 581; cyst, external, 581.
- Fat.* From the bowels, 488; exudation from liver, 501; balls from cysts, 635.
- Fauces*, 58; inflammation, 421; contraction, 422; tumors, 660, 666; malignant disease, 423.
- Felon*, 241.

- Femur.* Structure of neck, 9, 11.
- Finger.* Congenital enlargement, 138, 139; torn off, 319; amputated by a ring, 320. See *Extremities*.
- Fetus.* Measurement, 82, 83; blighted, 631, 96; from a case of extra-uterine gestation, 624, 626, 627. See *Monstrosities*.
- Fontanelle posterior.* An exception, 3.
- Foramen ovale in the adult,* 36.
- Foreign bodies.* The air-passages, 424-6, 743; alimentary canal, 487-90, 744; urinary bladder, 531, 532; wounds by, 683-97.
- Fractures,* 141-206; spine, 141-4; lumbar vertebra, 144; cranium, 145-59, 732; lower jaw, 159; sternum, 160; ribs, 160; scapula, 160; clavicle, 160, 161; furculum of a fowl, 161; humerus, 161-70; elbow-joint, 170-3, 162; olecranon, 170, 171; coronoid process, 173; forearm, 174-6; forearm, wrist-joint involved, 175; hand, 177; pelvis, 178, 179; neck of femur, 180-93, 734; neck of femur, with inversion, 733; neck of femur, with bony union, 186-9; shaft of femur, 194-9; femur, into knee-joint, 197; inner condyle, 199; patella, 200, 735; leg, 200-6; foot, 206, 735; partial, 180, 173, 174; fissured, 161; defined, 154, 155; gun-shot, 156, 161, 172, 177, 178, 181, 198, 199; fracture of a diseased bone, 236, 312, 223, 290; wound of lateral sinus, 154; followed by inflammation, 182, 203; followed by necrosis, 176, 237; separation of dead bone, 197, 198, 203; of femur, with ankylosis of hip, 269; union irregular, from neglect, 204, 205; operation for non-union, 163-8, 176, 195.
- Gall-bladder.* Filled by calculi, 504, 505; ulceration, 504; ulceration into duodenum, 506, 507; degeneration, 504.
- Gall-ducts.* Calculus in, 504; dilatation, 505; ulceration, 505.
- Genital organs, external, female.* Healthy, 77; malformed, 78, 69, 105, 109, 113; foreign body, 600; fetal bones, 625; wound, 600; contraction, 626; epithelial discharge, 601; tumors, 602, 603, 640; syphilitic growths, 604; melanosis, 604.
- Genital organs, external, male.* Healthy, 73-5; malformed, 75, 76, 104. See *Penis* and *Scrotum*.
- Glanders.* Nostrils, 413; skin, 403; epiglottis, 430.
- Gout,* 334, 335.
- Gun-shot injuries,* 695-7. See *Fractures*. Breech-pin of gun, driven into head, 688, 689.
- Gums hypertrophied,* 416, 417.
- Hair.* From cysts, 574, 635; hair-balls from stomach, 487, 488.
- Hare-lip,* 108, 94.
- Heart.* Healthy, 26-9; malformed, 36-40; malformed in double monsters, 115-17, 124, 128, 130; wound, 336; rupture, 336, 337; rupture of valve, 339-40; fibrinous clot, 344, 345, 742; enlarged, 340, 342; valvular disease, 339-43; parietes crataceous, 343, 344; aneurism, 345, 346; fatty, 346; tuberculoid disease, 346; melanosis, 346.
- Hernia.* Inguinal and scrotal, 495, 496; crural, 496; umbilical, 497; ventral, 498; diaphragmatic, 498; intestine, effect of strangulation, 497; intestine,

- recovery after sloughing, 496; conservative power of nature, 497; omentum excised, 497.
- Horns*, 397-9.
- Hospital gangrene*, 393.
- Housemaid's knee*, 329.
- Hydrocele*, 610; of the neck, 632, 633.
- Hydrocephalus*, 384-7.
- Idiots*, 45-7.
- Instruments, surgical, etc.*, 697, 698.
- Impalement*, 684, 685, 691-4.
- Imperforate anus*. Opening into urethra or vagina, 66, 67, 69.
 " rectum, 68.
- Intestine*, 62-4; malformed, 64-9, 104-5; in monsters, 115, 116, 118, 125, 129, 104, 108; laceration, 466, 477; distention, 467, 468; muscular coat hypertrophied, 467; hernia of mucous membrane, 467, 468; prolapse and excision, 468; intussusception, 469, 470; internal strangulation, 470; ecchymosis, 472; inflammation, 472-80; inflammation in dysentery, 473; ulceration, 477-80; lymph, 473; gangrene, 477; follicles developed, 471; follicles inflamed, 471, 473-5; typhoid fever, 473-5; polypus, 481; stricture, 481; tubercular disease, 480; malignant disease, 483-6; foreign bodies, calculi, etc., 487-90; foetal bones, discharged from, 625. See *Hernia, duodenum* and *tupho-enteritis*.
- Joints*. Loose bodies, 331, 332. See *Dislocation, Cartilage, Caries*, and *Anchylolysis*.
- Kidneys*. Healthy, 71; malformed, 71, 72; laceration, 516; ulceration, 522; Bright's disease, 522, 523; atrophy, 523; cicatrized appearance, 523; cyst, 519; encysted transformation, 516-18; encysted, congenital, 519; hydronephrosis, 519, 520; hydronephrosis, with suppuration, 520; malignant disease, 527, 744; calculi, 572; calculus, with fistula, 522; parasites, 677.
- Lacteals*, 43; tubercular, 377.
- Larynx*, 59; cartilages ossified, 59, 60; inflammation, 428, 429; croup and diphtheria, 427; ulceration, 429, 430, 421; syphilis, 430; polypoid growth, 430, 431; cancer, 423.
- Leucocythemia*, 379, 380.
- Lip*. Fissure, 108, 94; horn, 399; cancer, 406.
- Lithotomy*, 572.
- Liver*, 70; absence of, 70; malformation, 70; malformation in double monsters, 115-17, 125, 128, 130; laceration, 498; veins dilated in cardiac disease, 373; abscess, 499, 500; cyst, 500; granulated, 501; fatty, 501; syphilitic, 502; malignant disease, 502, 503; parasites, 503, 504, 675.
- Lupus*, 404, 405.
- Lungs*. Healthy, 60, 61; emphysema, 432; blood effused, 433; inflammation, 433; spurious melanosis, 433; "cattle disease," 434; cretaceous formations, 434,

- 435; tubercular cavity, 434; compression, 432; pneumothorax, 436; parasites, 435, 677.
- Lymphatics*, 43, 44; enlarged, 375-377; glands diseased, 377-80, 742.
- Malignant pustule*, 393.
- Maxilla inferior*. Each half in two pieces, 110; fracture, 159; removal for neuralgia, 389; tumors, 280, 281.
- Maxilla superior*. Removal for nasal polypus, 415; depression for nasal polypus, 415; tumors, 281.
- Melanosis*. Skin, 407; eye, 411-13; developed from a boil, 408.
- Membranes of the brain*. Healthy, 44; effused blood, 383; cysts, 383; hydrocephalus, 384-7; inflammation, 384; ossification, 387; cretaceous tumor, 387; malignant disease, 388.
- Mementos*, 708, 709.
- Menstruation during infancy*, 79.
- Mesenteric glands*. In typhoid fever, 377; tubercular, 378; cretaceous, 378.
- Moles*, 50, 730.
- Molluscum*, 401.
- Monstrosities*. By deficiency, 86-114; by excess, 114-139, 625; formation of double monsters, 126; mental impressions, 90, 92, 97.
- Mortification*. From diseased arteries, 320; from frost bite, 320.
- Muscles*. Artificial preparation, 729; variation, 25, 26, 730; rupture, 319; drawn out, 319, 320; atrophy from lead, 321; fatty degeneration, 321; parasites, 328, 675, 677.
- Myeloid*. Tibia, 286; tumor over ankle, 663.
- Nails*. Hypertrophy, 408.
- National crania, etc.*, 699-707.
- Necrosis*, 236-41; from inflammation, 236-40; exfoliation in case of fracture, 197, 198, 203; from tight bandage, 176; from phosphorus, 243; sequestra, 241-5, 739; artery wounded by sequestrum, 738; sequestrum, infiltrated by salivary salts, 243; preceded by absorption, 203; formation of new bone, 238; bone, after separation of sequestrum, 245-7.
- Nerves*, 47, 48.
- Neuralgia*. Lower jaw removed for, 389; five amputations for, 747; neuromatous tumors, 389.
- Nævus*, 372, 402.
- Nostrils*, 58; polypus, 413-15; glanders, 413; foreign bodies, 416; larvæ of œstrus, 678.
- Œsophagus*, 61; case of cut throat, 440; laceration, 439; stricture, 441; ulceration, 440; malignant disease, 442, 443.
- Omentum*. Protrusion through wound, 493; removed in hernia, 497; malignant disease, 493-15.

Obstetric toad, 86.

Odontoid process. Non-union, 18.

Ovaries. Abscess, 572; cysts, 573-8; cysts, inflamed, 575; osteoid tumor, 580; fibrous enlargement, 579; removed during life, 578, 579.

Ovum, 81; cystic disease, 628; blighted, 629.

Parasites, 671-8.

Penis, 73-5; phymosis in infancy, 73; malformation, 75, 76, 104; double, 732; slough of mucous membrane, 617; lacunæ enlarged, 618; abscess, 618; ulceration, 618, 619; stricture, 618, 619; false passage, 618; venereal warts, 619; malignant disease, 619-21.

Pericardium. Inflammation, 335, 336; cretaceous deposit, 336.

Periosteum. Blackish, in fowls, 24; bony deposit, 227-30, in malignant disease, 291.

Peritoneum. Perforation into, from stomach, by cadaveric softening, 443 — by ulceration, 447-9; perforation from intestine, 474-6, and into intestine from peritoneum, 491; inflammation, 491; granulations, 491; emphysema beneath membrane, 492; malignant disease, 493; ascariides, 677; free body, 491.

Pelvis deformed, 311, 307.

Peyer's patches. Form, 63; in fever, 473-5.

Phosphorus. Necrosis from, 243.

Phymosis. Normal, in the new-born, 73.

Pituitary body. In the acephalous foetus, 88; projection through base of skull, 99.

Placenta, 84; attached to top of head, 109; cretaceous, 632.

Pleura. False membrane, 436; cretaceous, 437; chest contracted, 437, 311, 312; pneumothorax, 436; tumor, 651.

Polypus. Nose, 413-15; ear, 413; air-passages, 430, 431; intestine, 481; womb, 586-91.

Pregnancy, extra, uterine, 622-4, 626, 627.

Pyemia. Abscesses in liver, 499; bone, 216.

Prostate. Enlarged, 612-16; abscess, 616; calculi, 617.

Renal capsules. Small in the acephalous foetus, 99; fusion in monstrosities, 98; cyst, 683; Addison's disease, 681-3.

Rectum. Malformed, 65-9.

Rhinencephalus, 111; in an acephalous foetus, 99.

Rhinolite, 416.

Rhinoplasty, 404, 405.

Scrotum. Effused blood, 609; abscess, 609; urinary abscess, 609; follicular disease, 396; tumors, 640, 646, 401.

Siren, 112.

Skin, 49, 50; tattooed, 49; Addison's disease, 395; naevus, 402; psoriasis, variola,

- seborrhoea, sycois and favus, 395, 396; glanders, 403; cheloides, 403, 404; lupus, 404, 405.
- Skull.* Fractured, 145-59; thickened, 219, 220; deformed, 308-10. See *Monstrosities*.
- Spavin*, 253.
- Spine.* Lateral curvature, 307, 308, 322; caries of vertebræ, 253-9; caries without curvature, 258, 259. See *Monstrosities*.
- Spina bifida*, 102; over sacrum, 104-8.
- Spinal cord and membranes*, 47; diseased, 388.
- Spleen.* Malformation, 140; enlarged, 679; inflammation, 680; tubercular disease, 680; malignant disease, 680, 681.
- Stomach*, 61, 62; in double monsters, 115-18, 128, 130; hour-glass contraction, 443; cadaveric softening, 443; laceration, 444; ecchymosis, 445; hemorrhagic erosion, 445; ulceration, 445; chronic ulcer, 445-51; polypoid growths, 452; tumors, 452-5; cancer, 457-66; situation of tumor, in cancer, 458; foreign bodies, 443, 744; larvæ of œstrus, 444.
- Stump*, 321, 741; neuralgic, 389, 390; bones from, 313-18.
- Surinam toad*, 85.
- Suture.* Sagittal closed in the fœtus, 309.
- Symphysis pubis.* Relaxed during gestation, 81.
- Syphilis.* Chancre on thumb, 402; bone, 285, 286, 392; teeth, 420; larynx, 430; liver, 502; inoculation, 402; vegetations on labia, 604, and prepuce, 619.
- Teeth*, 55-57; anomalies, 55, 56, 419; in ovarian cyst, 574; incisors of rodents deflected, 418; iron balls in tusks of elephants, 417, 418.
- Testicle.* Blood effused, 611; encysted disease, 611; tubercular disease, 611; malignant disease, 611, 612; castration, 610; disease of tunica vaginalis, 610.
- Thyroid cartilage.* Malformed, 59; fractured, 426.
- Trachea.* Case of cut throat, 440; croup and diphtheria, 427; variola, 429; tubercular ulceration, 429, 430; opening, by ulceration, from œsophagus, 441; polypoid growth, 431; foreign bodies, 424-6, 743.
- Trout, double*, 131, 731.
- Tubal pregnancy*, 622, 623.
- Tumors.* Encysted, 632-8, 414; fatty, 639, 640; fatty and fibrous, 641, 642; fibro-cellular, 646, 647; fibrous, 648; ear-ring tumors, 649; neuromatous, 649, 650, 389; from parotid region, 651, 660; fibro-nucleated, 651; cellular, 652; exostoses, 280-3; enchondromatous, 653-63, 747; myeloid, 663; fibro-plastic, 663, 664; epulis, 665; thyroid, 681; erectile, 665, 371, 373; varicose arterial, 371; epithelial, from throat, 666; ciloides, 670; malignant, 666-70; warty growth, from an oak, 671.
- Typhoid fever.* Rose spots, and sudamina, 395; gangrene of surface, 393; intestine, 473-5; mesenteric glands, 377.
- Ulcer.* Inflammatory, chronic and gangrenous, varicose, callous, fungous, scrofulous, scorbutic, dartous, 391, 392.

- Umbilical cord.* Knots, 632; bifid, in case of twins, 84.
- Urea,* uric acid, urate of ammonia, and hippuric acid, 73.
- Ureter.* Double, 72; dilated in hydronephrosis, 519, 520, 105; in cancer, 524; calculi, 521; impervious, 105.
- Urinary bladder.* Malformation, 105, 108; transfixed, 524; distention, 525; sacculated, 526; inflammation, 525; abscess opening into it, 480; tumor, 527; malignant disease, 528-31; foreign bodies from, 531, 532. See *Calculi*.
- Uterus,* 77, 78; malformation, 78, 105, 113; gravid, 80, 81; after delivery, 80; rupture, 625; decidua, 80, 598; inversion and removal, 582; hypertrophy and removal, 582; prolapse, with elongation, 584; abscess, in substance of, 584; opening into, and external to organ, 584; cyst, in substance, 585; polypus, 586-91; fibroid tumor, 591-8, — spontaneous discharge, 593, — degeneration, 594, 595, — sloughing, 596, — subsidence of, 596; removed by abdominal section, 596-8; tubercular, 599; malignant disease, 599, 600.
- Uvula.* Fissure in the acephalous fetus, 99.
- Variola.* Face, 395; trachea, 429.
- Venomous serpents.* Poison gland, 57; bite of viper, 393.
- Veins.* Varicose, 372, 373; inflammation and results, 373-5; phlebolites, 375, — in the splenic vein, 368; malignant disease, 375.
- Vesicula seminalis.* Tubercular, 612.
- Wounds,* 391.

